

Microbiological basis for endodontic treatment: can a maximal outcome be achieved in one visit?

MARTIN TROPE & GUNNAR BERGENHOLTZ

A growing perception in endodontic circles is that root canal therapy requires one treatment visit only. This perception has resulted in patients, referring dentists and endodontists questioning whether ‘standard of care’ requires a one-visit procedure.

Treatment in one visit certainly has many advantages. It is less time-consuming, resulting in less cost for the patient and potentially more profit for the dentist. In addition, numerous studies have shown that postoperative pain is equally low when the treatment is performed in one or multiple visits (1–3). In fact, an argument could be made that additional discomfort due to local anesthetic or trauma from a rubber dam application, experienced after a second visit, makes one-visit endodontics overall less painful than multivisit treatment. With the obvious advantages of one-visit endodontics and the short-term outcomes (profit, patient acceptance and short-term pain results) favoring its use, it is not surprising that this treatment mode has become prevalent.

However, in medicine and dentistry, long-term outcome is the standard by which treatment methods are compared. We assume that when accepting one-step endodontic treatment, the dentist believes the long-term outcome mirrors the positive postoperative pain comparisons, and the patient trusts the dentist to choose the treatment that is best for him/her. Are these assumptions reasonable? To assess this question, it seems sensible to identify the treatment objectives

of endodontic therapy and consider the potential for these objectives to be attained in just one session. In this paper we aim to review available evidence relevant to that aspect and we will base our argument on the fact that successful endodontic treatment requires control of any prevailing root canal infection.

Endodontics: a microbial issue

Like all health care clinical disciplines, dentistry is focused on the prevention or elimination of disease. Specific to endodontics is the prevention or elimination of pulp space infections and associated inflammatory sequelae.

Takehashi et al. (4) convincingly established the role of bacterial infection in pulpitis and apical periodontitis. The pulps in germ-free and conventional rats were exposed and left open to the oral environment. Subsequently, the germ-free rats developed minimal pulpal inflammation and substantial healing of the exposure site, despite the physical damage and the impaction of food. The conventional rats demonstrated a severe inflammatory response that resulted ultimately in pulpal necrosis, pulpal abscess and apical periodontitis. Hence, this particular animal experiment not only emphasized the key role of bacterial infection in pulpal and periapical disease, but also demonstrated the important fact that, in the absence

of infection, healing and repair of a pulpal wound is predictable.

Vital pulp vs. necrotic pulps

The preconditions are different depending on the status of the pulp. In an infected vital pulp due to a caries exposure, for example, the infection is normally found only at the wound surface, where it has resulted in a localized inflammatory response. This means that more apically, and in particular in the most apical portion of the tissue, bacterial organisms are usually not present. Pulpectomy in such a case, that is, removal of the pulp and its replacement with a root filling, is carried out on the presumption that the pulpal condition is irreversible and may lead to tissue breakdown and subsequent root canal infection. The concern from a treatment aspect should then naturally be to maintain sterile apical conditions in order to optimize the healing potential. In other words, a pulpectomy procedure is to be viewed as a prophylactic measure basically aimed at preventing the development of a pulpal infection, thereby preventing both apical periodontitis and possible systemic effects as well.

In a necrotic pulp, on the other hand, the preconditions are more uncertain, especially if the entire pulpal space has become infected. An apical inflammatory lesion is normally present that may or may not be associated with manifestations of acute infection. However, a non-infected pulp necrosis, which may follow ischemic injury to accidental trauma, is cause for less concern. Though decomposed pulp tissue and stagnated tissue fluid in the pulp chamber have been ascribed major pathogenic roles in the past, there is overwhelming evidence, both clinical and experimental, to the contrary. Möller et al. (5) may have provided the most compelling evidence that empty or necrotic canal spaces do not produce apical pathosis unless infected. In a controlled experiment, the pulps of 78 monkey incisors were lacerated with a Hedström file under sterile conditions. The access openings of 26 teeth were immediately sealed and not infected, while 52 teeth were exposed to the oral environment for 6–7 days prior to sealing the access opening. None of the non-infected specimens developed apical periodontitis, even after 6–7 months of observation, while 47 of the 52 (90%) infected teeth did.

By comparing teeth subjected to trauma with and without post trauma radiographic bone lesion apic-

ally, both Bergenholtz (6) and Sundqvist (7) substantiated the strong association between pulp space infection and periapical pathosis. Both studies utilized state-of-the-art anaerobic techniques for processing the bacterial root canal samples undertaken. Bergenholtz (6) evaluated 84 teeth that had been traumatized without concomitant exposure of the pulpal chamber, but with some teeth having slight loss of tooth substance. Sixty of these 84 teeth showed evidence of apical periodontitis and 51 of these (85%) harbored cultivable bacteria. Sundqvist's (7) material comprised 32 incisors with pulpal necrosis, which had remained completely intact after the trauma. Nineteen of these teeth demonstrated apical periodontitis, of which 18 teeth (95%) presented with positive cultures for bacteria.

Mechanisms of bacterial action in endodontic infections

Carefully conducted electron microscopic studies have indicated that it is from within the confines of the root canal system that bacteria initiate and maintain periapical pathosis (8, 9). It is generally held that bacteria rarely invade the periapical tissues unless there is severe inflammatory breakdown, such as in periapical abscesses. Hence, aspirates from endodontic abscesses often contain a variety of bacterial forms, including Gram-negative anaerobic rods, Gram-positive anaerobic cocci and facultative anaerobic streptococci (10–12). However, the view that root canal bacteria only invade with acute manifestations of periapical lesions has been questioned by observations of the presence of bacteria in silent and seemingly well-balanced periapical lesions. It is well known that organisms belonging to the genus of *Actinomyces* occasionally colonize inside organized periapical lesions (13). Several reports have further drawn attention to the possibility that other bacterial species may establish themselves in the body of the inflammatory process. Tronstad et al. (14) cultured organisms similar to those normally cultivated from infected root canals in eight therapy-resistant lesions. Very recently, Sunde et al. (15) used *in situ* hybridization with probes specific for the domain of bacteria and species-specific probes, including techniques for spatial distribution. They reported that asymptomatic periapical lesions contained a variety of microbial morphotypes.

However, from a clinical perspective the true preva-

lence of these extraradicular infections is not yet known. Neither has it been established that they pose a significant treatment problem. Indeed, there are cases reported which have failed to heal following repeated and well-conducted endodontic treatments and which have contained either *Actinomyces* or other bacterial colonizations (16–18). Until further evidence is available as to the significance of extraradicular infections, it seems reasonable to view the organisms located within the confines of the root canal space as the main target for treatment.

Root canal bacteria cause apical periodontitis by a mechanism of growth and multiplication. This releases a variety of substances (breakdown products of intra- and extracellular origin, enzymes, cell wall materials, etc.) into the periapical tissue compartment. The best studied of these substances are bacterial endotoxins (LPS) from the cell wall of Gram-negative organisms. Schein & Schilder (19) found that the pulps of teeth with apical periodontitis harbored high levels of LPS, and speculated this may be a mechanism by which bacteria produce the apical lesion. Dahlén & Bergenholtz (20) confirmed a strong association between LPS levels and the prevalence of Gram negative bacteria in infected pulp necroses. Animal experiments have further demonstrated that endotoxins placed in empty sterile root canals produce significant periapical lesions (21, 22). Schonfeld *et al.* (23) corroborated that the presence of endotoxin was highly correlated to the presence of inflammation in the periapical region. and Yamasaki *et al.* (24) has shown, in a rat model, that an apical inflammatory lesion may develop long before the pulp is totally necrotic. These findings lend strong support to the concept of bacterial metabolites and breakdown products playing a significant role in the pathogenesis of apical periodontitis.

For sustainable growth in root canals, bacteria require a nutritional supply. As many of the bacteria have proteolytic capabilities (7, 25–28), the main nutritional source is likely to be inflammatory exudates produced at the bacteria–inflammatory tissue interface. That interface may be either within the apical portion of the root canal or in the periapical tissue environment (8). Hence, if the root canal treatment is successful in restricting the number of organisms, the inflammatory lesion is likely to diminish or subside. This limits its potential to provide nutrition to any remaining organisms. This mechanism brought

about by the treatment procedures is likely to be critically important for whether a periapical inflammatory lesion heals completely, partially or not at all subsequent to therapy.

Anatomical constraints

From a treatment aspect, the complexity of an infected pulp necrosis is not solely related to the mere presence of bacterial organisms throughout the pulp chamber, but also to the fact that they may be lodged in areas inaccessible for instrumentation and disinfection. Such spaces include lateral canals, isthmuses, crevices and dentinal tubules. Oval-shaped canals, especially, present the clinician with the difficult task of cleaning the entire circumference, as necrotic tissue and debris are often left behind in these canals (29).

Bacteria in dentinal tubules is yet another challenge. Ando & Hoshino (30) employed a technique whereby they were able to determine the extent to which bacteria of an infected pulp necrosis enter dentinal tubules. Utilizing extracted teeth with deep caries, they first carefully disinfected the tooth surface and then took consecutive dentin samples for cultivation from the periphery of the roots towards the pulpal chamber. It was reported that bacteria regularly had penetrated the innermost layers of the dentin. Obligate anaerobes such as *Eubacterium*, *Propionibacterium*, *Actinomyces*, *Lactobacillus*, *Peptostreptococcus* and *Veillonella* were typical isolates. From a sample of 21 teeth, Peters *et al.* reported similar findings (31). Bacterial penetration of the innermost layers of dentin was noted in most teeth. Also, in a large number of the teeth they recovered bacteria from a quite peripheral position of the root dentin.

Bacteria accommodated by the dentinal tubules are certainly not easily accessible for the disinfection procedures employed in endodontic therapy. Rationales for targeting these organisms is that, should the root filling be incomplete, they may grow back into the available space and possibly maintain the periapical lesion. This particular mechanism of endodontic treatment failure is, however, not well studied.

Endodontic procedures and their effectiveness

Collectively, the observations reviewed so far make a strong case for the view that the overall problem the

clinician is faced with in endodontics is related to bacterial infection of the root canal system. A key issue in the discussion is the extent to which all necessary treatment steps can be undertaken in one session to control any prevailing root canal infection, including buildups for proper aseptic technique, access opening, identification of all canal orifices, bio-mechanical preparation and final filling procedure. Added to all this is the establishment of a systemic and dental diagnosis and informing the patient of potential treatment alternatives, costs and prognosis.

A case can certainly be made for one-step treatment with vital pulps, provided certain requirements are fulfilled. It is important that adequate asepsis can be maintained and that the instrumentation procedure results in complete removal of the soft tissue of the pulp. Improper instrumentation may result in tissue remnants on the canal walls (32); if these are concomitantly contaminated, conditions for bacterial growth are established. Tissue remnants also prevent the creation of a well-sealing root canal filling. In other words, the time available to carry through the basic elements of the procedure is decisive for whether or not to complete a pulpectomy with a root filling in one and the same session.

For teeth with non-vital pulps and apical periodontitis, the concern is primarily the extent to which adequate disinfection can be attained in one treatment session only. The current methods available for bacterial reduction in endodontic therapies include mechanical instrumentation to clean and widen the root canal space, and chemical disinfection by irrigation and intracanal medication, known as an antimicrobial dressing.

Bacterial elimination by mechanical instrumentation alone

Mechanical instrumentation is a primary means of bacterial reduction in endodontic treatment. Byström & Sundqvist (33) tested instrumentation with saline irrigation in the reduction of intracanal bacterial counts. Fifteen single-rooted teeth with necrotic pulps and periapical lesions were instrumented for up to five appointments. While mechanical instrumentation reduced the number of bacterial counts 100–1000-fold, no teeth cultured bacteria-free after the first appointment. The bacteria remaining in the canals multiplied between appointments, and they

were not possible to consistently remove even after multiple treatment episodes. Ørstavik et al. (34) reported similar findings using reaming and saline irrigation. Only 13 of 23 teeth in their study were rendered bacteria-free.

These two studies used stainless steel files with a standardized or modified step back technique. Dalton et al. (35) attempted to assess the usefulness of the newer NiTi rotary instruments in removing bacteria from infected root canals. They used a sterile saline irrigant and two instrumentation methods. One group was instrumented with stainless steel K type files, and the other with 0.04 taper NiTi engine-driven rotary files. Only 28% of the teeth were rendered bacteria-free and no significant difference was seen between the two groups. However, the number was reduced significantly when each culture was taken as the canal was instrumented to larger sizes (Fig. 1; 35).

These studies indicate that significant reduction occurs due to the instrumentation of infected root canals. An additional effect may have been attained using saline as an irrigant, which is mildly antibacterial, according to the observations of Möller (36) and Casciato & Rosenblatt (37). The anaerobic flora might have been exposed to oxygen from the instrumentation and irrigation procedures, which may have contributed further to the reduced bacterial counts. Regardless, predictable bacterial elimination does not appear possible with the tested measure.

Bacterial elimination by mechanical instrumentation and chemical disinfection by irrigation

While the use of irrigants in conjunction with mechanical instrumentation is important to loosen and help remove debris and bacteria, it has also been considered critical that the irrigating solution provide antibacterial effects. There are several presumed important purposes of such a property. One is to enhance bacterial killing overall. Another is to provide disinfection in areas of the canal that are inaccessible to mechanical cleansing. Active irrigants may also dissolve remaining tissues and/or inactivate products of bacteria. The ideal irrigant would readily dissolve all remaining canal tissue, kill all remaining bacteria, and detoxify all bacterial substances within the canal and dentinal tubules, all without risking appreciable host tissue damage.

Dakin (38) evaluated more than 200 chemical compounds for antimicrobial activity and tissue reaction. A buffered 0.5% sodium hypochlorite solution (NaOCl) was found to exhibit excellent antimicrobial activity and to minimally affect the wound healing process. This solution gained widespread use in and after World War I as the ideal medicament for wound debridement. Subsequently, the agent was introduced in endodontics and appears today to be universally accepted.

Byström & Sundqvist (39) compared the antibacterial properties of 0.5% NaOCl and sterile saline irrigants in infected root canals.

NaOCl irrigation plus mechanical instrumentation rendered 33% of the canals bacteria-free after the first appointment. In a later study, Byström & Sundqvist (40) compared the use of 0.5% and 5% NaOCl and found no difference in outcome. *Shuping et al.* (41) used a rotary instrumentation technique with 1.25% NaOCl as an irrigant and was able to double the number of negative cultures found in the Byström & Sundqvist studies. Still, only 61% of the teeth in that study were rendered bacteria-free by culture (Fig. 2; 41).

Although irrigation with NaOCl provides a number

Log₁₀ CFU means

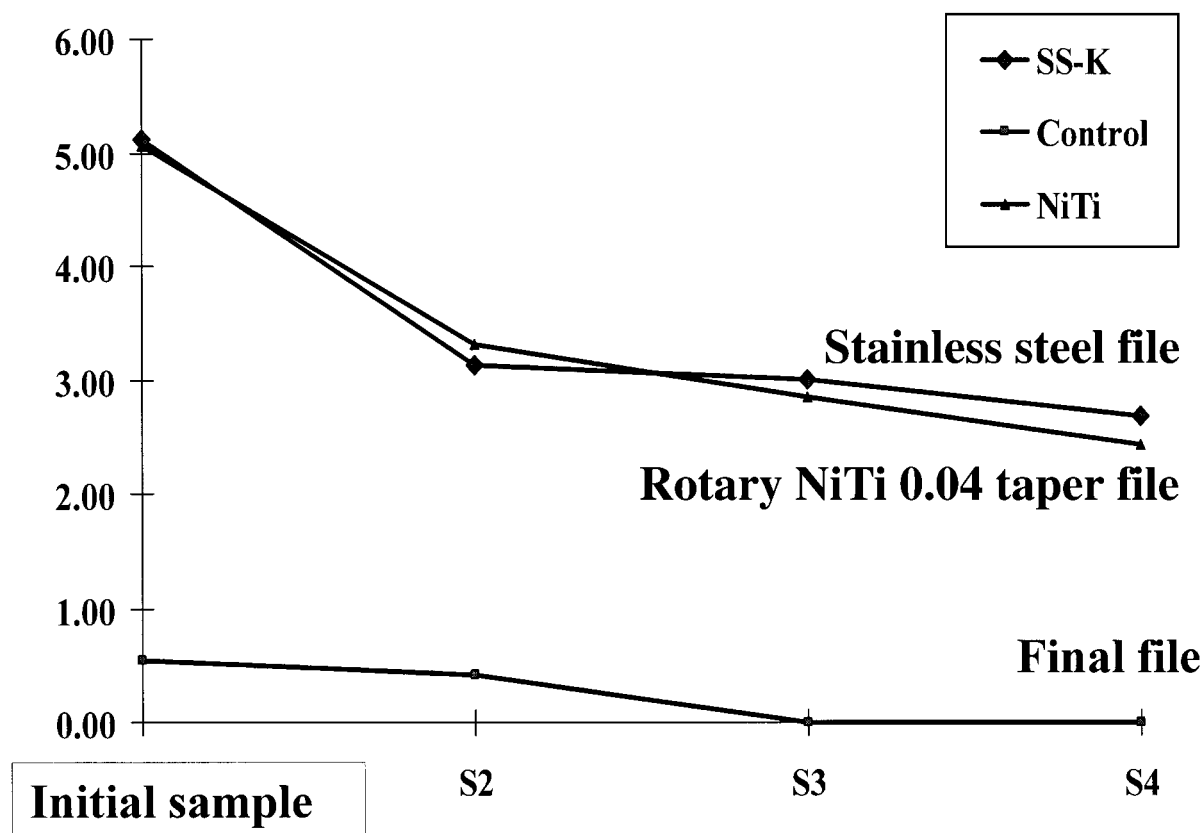


Fig. 1. Data on bacterial reduction with mechanical instrumentation and saline irrigation in the study by Dalton et al. (35). The graph shows bacterial reduction after instrumentation of canals with stainless steel or rotary NiTi 0.04 taper files. Saline was used as the irrigant. Log₁₀ transformation for CFU counts was performed to normalize the data prior to statistical evaluation. Anaerobic culturing was performed at opening file sizes of S1 and successive sizes of S2 and S3, until the final file size S4 was obtained. For stainless steel files, S4 size was #35 or #40. For NiTi rotary files S4 was #6 or #7. In all except one canal with radiographic signs of apical periodontitis, bacteria were found in the initial (S1) sample. There was a significant reduction in bacteria at every successive instrumentation size (S1 vs. S2 vs. S3). Negative cultures were obtained in only 24% of canals at S4. There was no difference between instrumentation with stainless steel and instrumentation with NiTi rotary files. In the vital controls, one tooth had minimal bacterial growth at S1 and no bacteria could be cultured at S4.

of features attractive to root canal therapy, it appears that it is not possible to attain complete bacterial elimination by this adjunctive measure. This means that if one-step endodontics is practiced in infected cases, a substantial number of root canals will still harbor bacteria. It has yet to be demonstrated that changes in either the irrigant or instrumentation tech-

niques can improve this situation. High concentrations of NaOCl are frequently used but this can certainly be questioned from a risk-benefit point of view. Inadvertent extrusion through the apical foramen can cause substantial tissue damage and painful conditions, while its antibacterial capacity does not appear to be proportionally enhanced. Pashley et al.

Bacterial Reduction

Log₁₀ mean values

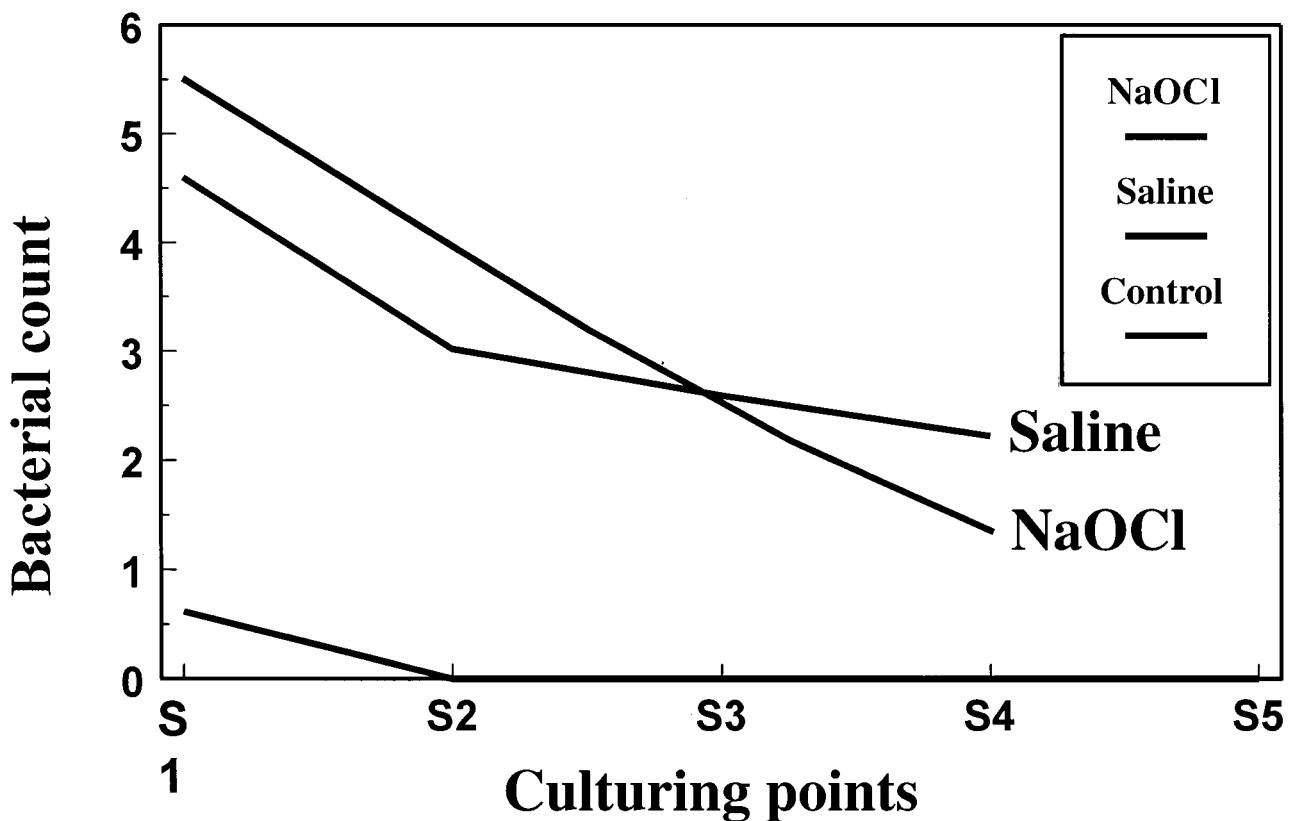


Fig. 2. Data on bacterial reduction with mechanical instrumentation and 1.25% NaOCl irrigation in the study by Shuping et al. (41). This graph shows the results when instrumentation was performed with NiTi 0.04 tapered rotary instruments with NaOCl as the irrigant (gray) compared to saline (blue) in the previous study. The mean log₁₀ values of the saline study were 4.60 ± 1.84 (S1), 3.02 ± 1.99 (S2) and 2.59 ± 1.92 (S3). At this point the bacterial numbers of the NaOCl study were similar to the numbers of the saline study (Fig. 1). Only after S3 were bacterial numbers reduced in the NaOCl study compared to the saline study. The S4 mean log₁₀ value of the saline study was 2.22 ± 2.16 . Of the canals, 62% cultured negative after 'complete' instrumentation and irrigation with 1.25% NaOCl. The paired *t*-test used to detect differences in log₁₀ value means showed a statistically significant decrease in the pattern of reduction between S1 and S4 of this study when compared to the saline study ($P < 0.05$).

(42) evaluated the reaction of various tissues to different NaOCl concentrations. Full strength (5.25%) NaOCl was found to be severely caustic to healthy tissues and lacked the margin of safety seen with 0.5–1.0% dilutions.

It has been argued (43) that improved instrumentation techniques are more effective than the one employed in the study by Shuping et al. (41). Based on the studies referred to, it seems that even with the most modern instrumentation techniques, attainment of complete bacterial elimination would be far-fetched.

Intracanal medication

Intracanal medication has been widely used in attempts to kill any bacteria remaining after instrumentation and irrigation. Many different medicaments have been used over the years. All require more than a few minutes' exposure in the canal to be effective, and this has limited their use to multiple appointment endodontic therapy.

Gergely & DiFiore (44) made a survey of medicaments in use at American dental schools. Common were calcium hydroxide, eugenol, iodine potassium iodide, glutaraldehyde, formocresol, camphorated parachlorophenol, metacresylacetate, beechwood creosote, and various antibiotic combinations. The clinical benefit of these agents has been questioned. Messer et al. (45, 46) found that medicaments that rely on vapor formation had a short duration of action. Cotton pellets soaked in Camphoratal Mono chlorophenol (CMCP) placed in pulp chambers lost nearly 90% of their active parachlorophenol within the first 24 h. Lewis (47) has reviewed the dangers of using formaldehyde-containing medicaments, showing the systemic spread of the agent as well as its mutagenic potential.

Byström et al. (48) found that calcium hydroxide left in place for 4 weeks was a more effective medicament than either CMCP or camphorated phenol. Calcium hydroxide was able to render 97% of their canals culture-negative, whereas the other medicaments achieved this in only two-thirds of the treated canals. Sjögren et al. (49) demonstrated that a 7-day usage of calcium hydroxide medicament was sufficient to reduce canal bacteria to a level that gave a negative culture. When Shuping et al. (41) added calcium hydroxide medicament after instrumentation

with NaOCl irrigation they were able to render 93% of the canals bacteria-free after the NiTi instrumentation technique was used for instrumentation (Fig. 3; 41).

The effectiveness of calcium hydroxide in completely removing bacteria in infected root canals in less than 4 weeks is under debate. Reit & Dahlén (50) found persistent infection in 26% of canals after 2 weeks' exposure to calcium hydroxide. Ørstavik et al. (34) observed the persistence of bacteria in 35% of the root canals after 1 week of dressing with calcium hydroxide. Barbosa et al. (51) have reported similar findings. In the study of Sjögren et al. (49), instrumentation was followed by ultrasonic energy applied to the irrigating solution before the calcium hydroxide was placed in the canal. It is not known to what extent bacterial reduction by the use of ultrasonics took place and how this contributed to the efficacy of the calcium hydroxide in just 7 days.

Others have questioned the routine use of calcium hydroxide based on the resistance of certain bacteria to its effect. Stevens & Grossman (52) and Haapasalo & Ørstavik (53) showed that *E. faecalis* is not effectively killed by calcium hydroxide; this organism was an isolate in some of the positive samples in the study of Reit & Dahlén (50). In a clinical series of primary treatments of teeth with necrotic pulps and asymptomatic periapical lesions, Molander et al. (54) failed to demonstrate enhanced antibacterial effect of a treatment strategy that included medication with both iodine potassium iodide and calcium hydroxide. In 44% of their 50 cases who had received the iodine potassium iodide treatment, both facultatives and anaerobes were recovered by culture. The addition of calcium hydroxide resulted in only 80% negative cultures, although *E. faecalis* could be recovered in only two (4%) of these cases. The findings of that study thus confirmed the observations of Engström et al. (55) that iodine potassium iodide, subsequent to biochemical preparation, fails to give predictable negative cultures.

These observations suggest that although the use of intracanal medication will lower the bacterial count in infected root canals, it fails to obtain total elimination of bacterial organisms on a consistent basis. Calcium hydroxide water slurry has shown promise in some studies; in others, it has not been proven as effective. From this strict perspective, firm justification for a multiple treatment approach cannot be claimed.

Bacterial entombment in the root canal filling

One of the common arguments for filling teeth at the first appointment is that remaining bacteria are not critically important, as the root filling material will entomb them. As yet there are few reports available either refuting or supporting this concept. In a study in dogs, Katebzadeh et al. (56) instrumented teeth with vital uninfected pulps to large sizes. The canals were then experimentally infected, as evidenced by apical lesions that subsequently developed radiographically. Some of the canals were obturated in this infected state, while others were disinfected before root canal filling. When healing was evaluated histologically, it was seen that although healing was seen in the canals obturated without prior disinfection, they did not heal as well as those canals disinfected prior to obturation. The result of that study suggests

that entombment of bacteria by root canal filling may be a viable method of separating the bacterial products within the canals from the surrounding periradicular tissues. However, the obturation methods in use today do not appear to be able to achieve this predictably. The finding of the Katebzadeh et al. study is not surprising given the observation from leakage studies that root fillings do not predictably provide bacteria-tight seals (57–60). Thus, entombment may not be effective enough to rely on for maximal success.

The 5-year follow-up report of Sjögren et al. (61) on 53 teeth instrumented and filled in one appointment needs attention in this context. Teeth with a positive culture result had a less successful outcome. The teeth were all subjected to a culture before root filling. Of the 22 teeth filled with a positive culture, 68% were deemed successful. The remaining 31 teeth that were observed had a negative culture result at the time of filling and 94% were successful. The dif-

Bacterial Reduction

Log₁₀ mean values

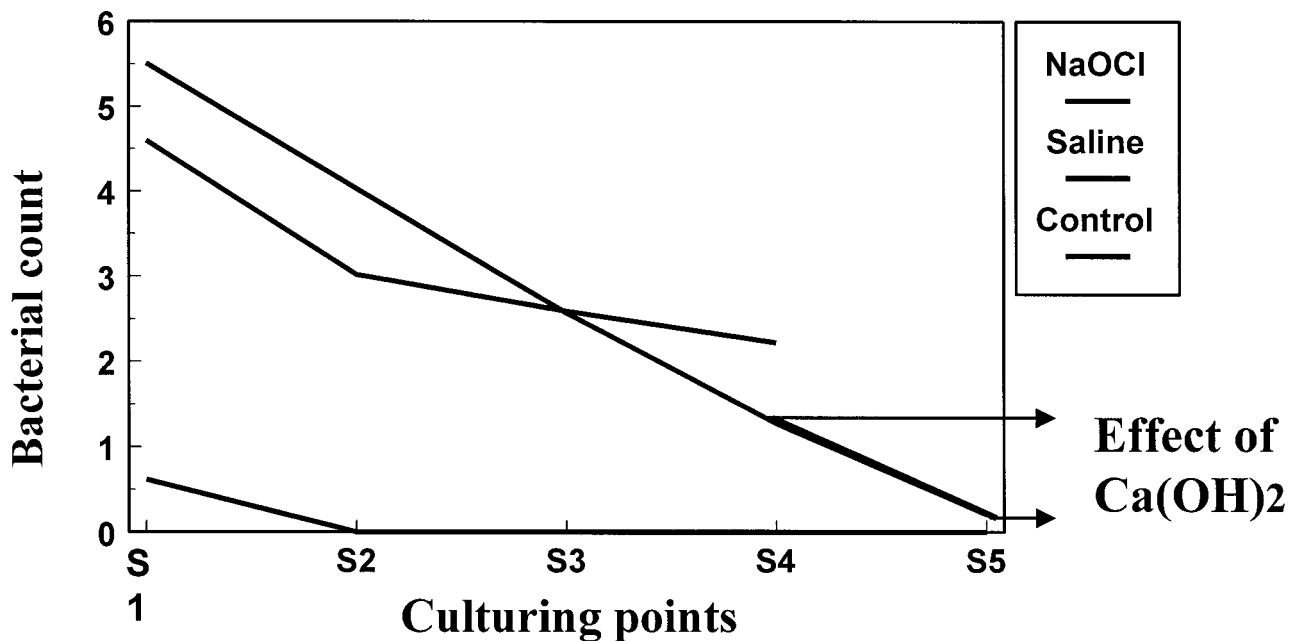


Fig. 3. Bacterial reduction in the study by Shuping et al. (41) with the addition of calcium hydroxide. When calcium hydroxide was added to the canals instrumented and irrigated with 1.25% NaOCL (Fig. 2), 93% cultured negative (S4 to S5).

ference in success rate reached statistical significance within the 5% level. No other factor seemed to affect the clinical result, and this led the authors to conclude that permanent filling of infected root canals should be postponed until canals have been medicated with an antimicrobial dressing.

The clinical importance of a negative culture for the outcome of endodontic therapy has been questioned. Both false positive and false negative samples may affect the result and microbes lodged in dentinal tubules may not be disclosed by conventional sampling procedures (62). However, aside from clinical follow-up studies, the method is the only one available for the clinical assessment of the bacterial status of teeth and therefore it has served an important role in the scientific evaluation of endodontic treatment methods.

Management of the apex

Since the entombment of bacteria by root filling plays an important role in the successful outcome of endodontic therapy, factors that enhance or decrease the effectiveness of the root filling should be considered. An important consideration in this context is the management of the apex during the instrumentation phase. Anatomic studies have shown that the location of the foramen is unpredictable and it may often exit some

distance from the anatomic apex (63, 64). If instrumentation is careless and conducted without proper establishment of a working length within the confines of the root canal, there is an obvious risk of over-instrumentation. An over-instrumentation carried out with successively larger files will often enlarge the foramen in such a way that an oval-shaped opening is created to the apical environment. This error appears to be one of the most negative factors mitigating against a successful outcome of endodontic therapy (55, 65). The condition may result in a number of hazards.

In case of an infected necrotic pulp, the nutritional supply of remaining bacteria in the apical region of the canal may be dramatically enhanced: not only will the number of bacteria increase but also the number of specific pathogens. Normally, bacteria live under rather sparse conditions in the root canal environment. Following the enlargement of the foramen, however, serum factors from exudate released from the periapical inflammatory process may provide bacteria with a nutritional boost. This in turn may unbalance the host defense, causing an endodontic flare-up. The purging of the apex with infected file tips as well the movement of infected debris into the periapex contributes to this potential effect.

Over-instrumentation may also impair the possibility of obtaining a proper apical obturation of the root

Preoperative Status

	No Lucency	Lucency
Strindberg (1956)	89%	68%
Seltzer et al (1963)	92%	76%
Kerekes & Tronstad (1979)	94%	84%
Sjögren et al. (1990)	96%	86%

Fig. 4. Treatment success of teeth with vs. without apical periodontitis in various studies. Figures indicate percent of teeth without diagnosable periapical radiolucency at follow-up.

canal. In particular, if an oval-shaped opening has been created, round guttapercha cones will not fit the space. At best, a sealer can make up the gap, but often an unfilled space will remain between the filling and the root canal walls, allowing for bacterial growth (66). In order not to jeopardize the integrity of the apex, instrumentation should stay short of the foramen at all times. In a pulpectomy procedure it has been proven advantageous to stop instrumentation 1–2 mm off the radiographic apex (67, 68). In teeth with non-vital pulp, instrumentation should ideally be closer to reduce the risk of leaving bacteria in an uninstrumented portion of the canal.

To finally resolve the issue of whether or not one-step treatment can be regarded as a viable treatment approach, randomized clinical trials comprising an adequate number of cases with sufficient observations periods are necessary. Reports have started to appear (69, 70) but as of yet, the data provided have been inconclusive.

Clinical perspectives

A long accepted ideal of endodontic therapy is that root canals should be bacteria-free by the completion of the instrumentation phase. Only when this objective is achieved should permanent root filling take place.

Teeth with vital pulp/teeth with necrotic pulp without clinical or radiographic signs of apical periodontitis

Based on the reports presented in this overview, these canals can in principle be regarded as free of bacteria at the initiation of treatment. Thus, provided a strict aseptic technique is utilized and enough time is available for all treatment steps to be performed optimally, permanent filling of the canal may take place at the first visit.

	Culture result	
	+	-
Engström et al (1964)	76%	89%
Zeldow & Ingle (1963)	83%	93%
Byström et al (1987)		95%
Sjögren et al. (1997)	68%	94%
Bender et al (1964)	Similar	

Fig. 5. Treatment outcome of teeth filled after a negative vs. positive culture in previous reports. Figures indicate percent of teeth without periapical lesion at follow-up.

Teeth with necrotic pulp and apical periodontitis

In these teeth it appears that *complete* removal of bacteria on a consistent basis, even with the use of an intracanal medicament of a reasonably low tissue toxic potential, is at present an elusive goal. However, it would be a serious mistake to disregard bacterial reduction as a critical step for the successful outcome of endodontic therapies. If we compare outcomes of endodontically treated teeth with or without a preoperative diagnosis of apical periodontitis (71–74) (Fig. 4), more favorable results have consistently been found in teeth without apical periodontitis. In addition, in many studies teeth filled after a negative culture show a better outcome than those filled after a positive culture, although this has not always been statistically ascertained (55, 61, 75–77) (Fig. 5). While the negative culture, as already stated, may not represent a bacteria-free canal, it is reasonable to assume that it represents fewer bacteria than those in teeth filled after a positive culture. This is not to be construed as an argument for the re-introduction of bacterial culture as a routine in endodontic therapies, but to emphasize that only when the fewest number of bacteria possible have been attained after the instrumentation phase should permanent root filling take place.

How can this objective be reached?

Although there has been considerable debate in the literature as to the degree of effectiveness of intracanal

medicaments after thorough instrumentation, none has claimed that intracanal medicaments are ineffective in further reducing the number of bacteria after instrumentation and irrigation. Calcium hydroxide is the current intracanal medicament of choice when an intracanal medicament is used. The water slurry serves some important functions in easing the bacterial load on the periapical tissue. It pre-occupies the instrumented root canal space, curbing the nutritional supply of any remaining organisms lodged in the root canal system. By the same mechanism, their regrowth is hampered. Although not generating distant antibacterial effects, it is lethal to bacterial organisms in its close vicinity by virtue of its release of hydroxyl ions (see further review by Siqueira et al. (78)). Therefore, calcium hydroxide serves as an ideal intracanal dressing to be used in between appointments. Furthermore it offers convenient scheduling of patients so that ample time is available for observation of tissue healing in progress (Fig. 6).

Final conclusions

Based on the above considerations, the following recommendations for a clinical routine in the practice of endodontics seem defensible:

- 1 One step treatment can be carried out in vital cases and non-vital traumatic cases without signs of apical periodontitis provided sufficient attention is given to each element of the treatment procedure.
- 2 In infected cases, mechanical instrumentation should be completed within the first visit and with

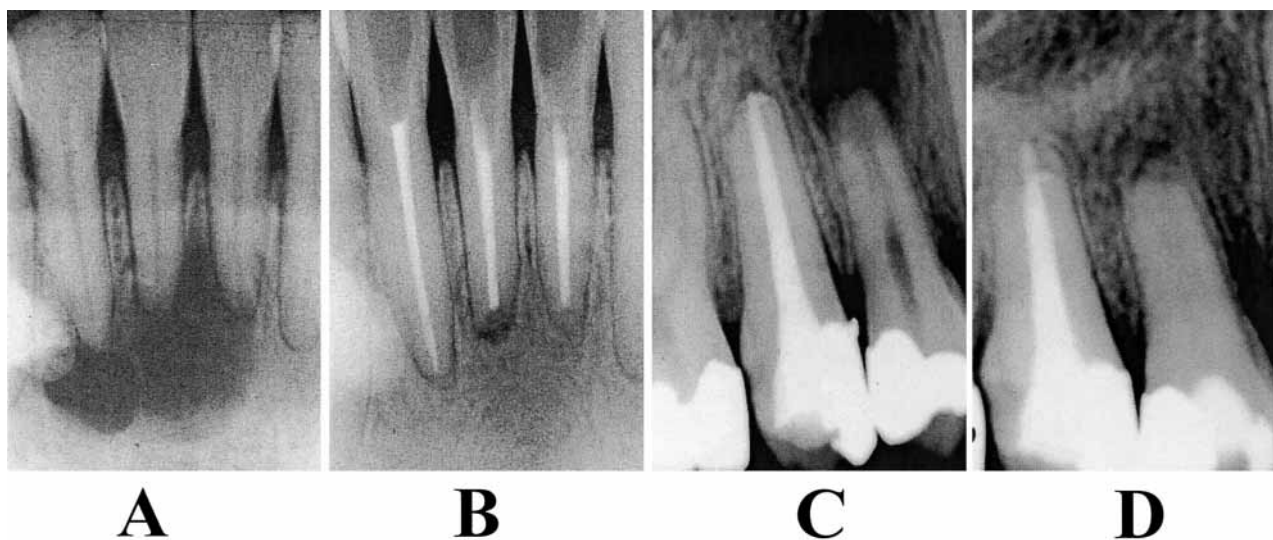


Fig. 6.

the aid of an antibacterial irrigating solution of minimal tissue toxic potential (e.g. 0.5–1% NaOCl). Calcium hydroxide should be placed in the canal to observe any emerging clinical symptoms that may necessitate reopening of the tooth and/or to observe healing in progress. The time frame for the application may vary depending on the condition of the tooth. The direct effect of the treatment on the resolution of prevailing clinical symptoms, including pain, swellings and sinus tract, can be observed for 1 week to 1 month. To follow healing in progress of a case with questionable prognosis, the observation period may have to be extended over 3–4 months. In most cases the convenience of the scheduling decisions and root filling should only be carried out if proper conditions prevail for permanent root filling (absence of apical suppuration, exudation or bleeding, proper canal instrumentation).

3 One-step endodontic treatment appears to be an obtainable goal in infected cases with apical periodontitis. Work should nonetheless continue to improve our disinfection protocol. Work should also be focused on improving our permanent filling materials to predictably seal any remaining bacteria from providing pathogenic effects on the surrounding periodontal tissues. Once such methods are available, less of an emphasis on disinfection procedures may be necessary.

References

- Oliet S. Single visit endodontics: a clinical study. *J Endodon* 1983; **9**: 147–153.
- Mulhern J, Patterson S, Newton C, Ringel A. Incidence of postoperative pain after one appointment endodontic treatment of asymptomatic pulpal necrosis in single rooted teeth. *J Endodon* 1982; **8**: 370–375.
- Trope M. Flare-up rate of single-visit endodontics. *Int Endod J* 1991; **24**: 24–27.
- Kakehashi S, Stanley H, Fitzgerald R. The effect of surgical exposures of dental pulps in germ-free and conventional laboratory rats. *Oral Surg Oral Med Oral Pathol* 1965; **20**: 340–349.
- Möller AJ, Fabricius L, Dahlén G, Heyden G. Influence on periradicular tissues of indigenous oral bacteria and necrotic pulp tissue in monkeys. *Scand J Dent Res* 1981; **89**: 475–484.
- Bergenholtz G. Micro-organisms from necrotic pulps of traumatized teeth. *Odont Revy* 1974; **25**: 347–358.
- Sundqvist G. Bacteriological studies of necrotic dental pulps. *Odontological Dissertations*, no. 7. Umeå: University of Umeå, 1976.
- Nair PNR. Light and electron microscopic studies of root canal flora and periapical lesions. *J Endod* 1987; **13**: 29–39.
- Molven O, Olson I, Kerekes K. Scanning electron microscopy of bacteria in the apical part of root canals in permanent teeth with periapical lesions. *Endod Dent Traumatol* 1991; **7**: 226–229.
- Williams BL, McCann GF, Schoenknecht FD. Bacteriology of dental abscesses of endodontic origin. *J Clin Microbiol* 1983; **18**: 770–774.
- Oguntebi B, Slec AM, Tanzer JM, Langeland K. Predominant microflora associated with human dental periapical abscesses. *J Clin Microbiol* 1982; **15**: 964–966.
- Lewis MAO, MacFarlane TW, McGowan DA. Quantitative bacteriology of acute dento-alveolar abscesses. *J Med Microbiol* 1986; **21**: 101–104.
- Happonen R-P. Periapical actinomycosis. a follow-up study of 16 surgically treated cases. *Endod Dent Traumatol* 1986; **2**: 205–209.
- Tronstad L, Barnett T, Riso K, Slots J. Extraradicular endodontic infections. *Endod Dent Traumatol* 1987; **3**: 86–90.
- Sunde PT, Olsen I, Eribe ER, Moter A, Tronstad L. Bacteria of asymptomatic periapical endodontic lesions identified by anaerobic cultivation and genetic methods. *Eur Soc Endodontol* 2001: Abstract RP 3.
- Sundqvist G, Reuterving CO. Isolation of *Actinomyces israelii* from periapical lesion. *J Endodon* 1980; **6**: 602–606.
- Sjögren U, Happonen RP, Kahnberg KE, Sundqvist G. Survival of *Arachnia propionica* in periapical tissue. *Int Endod J* 1988; **21**: 277–282.
- Tronstad L, Kreshtool D, Barnett F. Microbiological monitoring and results of treatment of extraradicular endodontic infection. *Endod Dent Traumatol* 1990; **6**: 129–136.
- Schein B, Schilder H. Endotoxin content in endodontically involved teeth. *J Endodon* 1975; **1**: 19–21.
- Dahlén G, Bergenholtz G. Endotoxin activity in teeth with necrotic pulps. *J Dent Res* 1980; **59**: 1033–1040.
- Dwyer TG, Torabinejad M. Radiographic and histologic evaluation of the effect of endotoxin on the periapical tissues of the cat. *J Endodon* 1981; **7**: 31–35.
- Dahlén G, Magnusson BC, Möller A. Histological and histochemical study of the influence of lipopolysaccharide extracted from *Fusobacterium nucleatum* on the periapical tissues in the monkey *Macaca fascicularis*. *Arch Oral Biol* 1981; **26**: 591–598.
- Schonfeld SE, Greening AB, Glick DH, Frank AL, Simon JH, Herles SM. Endotoxic activity in periapical lesions. *Oral Surg Oral Med Oral Pathol* 1982; **53**: 82–87.
- Yamasaki M, Kumazawa M, Kohsaka T, Nakamura H, Kameyama Y. Pulpal and periapical tissue reactions after experimental pulpal exposure in rats. *J Endodon* 1994; **20**: 13–17.
- Sundqvist G. Taxonomy, ecology, and pathogenicity of the root canal flora. *Oral Surg Oral Med Oral Pathol* 1994; **78**: 522–530.
- Haapasalo M. The genus *Bacteroides* in human dental root canal infections. Taxonomic, ultrastructural, and clinical studies. Thesis. University of Helsinki, 1986.
- Farber PA, Seltzer S. Endodontic microbiology. *J Endod* 1988; **14**: 363–371.

28. van Winkelhoff AJ, Steenbergen MTJ, de Graaff J *Porphyromonas (Bacteroides) endodontalis*: Its role in endodontal infections. *J Endod* 1992; **18**: 431–4.
29. Wu MK, Wesslink PR. A primary observation on the preparation and obturation of oval canals. *Int Endod J* 2001; **34**: 137–141.
30. Ando N, Hoshino E. Predominant obligate anaerobes invading the deep layers of root canal dentin. *Int Endod J* 1990; **23**: 20–27.
31. Peters LB, Wesslink PR, Buijs JF, van Winkelhoff AJ. Viable bacteria in root dentinal tubules of teeth with apical periodontitis. *J Endod* 2001; **27**: 76–81.
32. Walton RE. Histologic evaluation of different methods of enlarging the pulp space. *J Endod* 1976; **2**: 304–311.
33. Byström A, Sundqvist G. Bacteriologic evaluation of the efficacy of mechanical root canal instrumentation in endodontic therapy. *Scand J Dent Res* 1981; **89**: 321–328.
34. Ørstavik D, Kerekes K, Molven O. Effects of extensive apical reaming and calcium hydroxide dressing on bacterial infection during treatment of apical periodontitis: a pilot study. *Int Endod J* 1991; **24**: 1–7.
35. Dalton BC, Ørstavik D, Phillips C, Pettiette M, Trope M. Bacterial reduction with nickel-titanium rotary instrumentation. *J Endod* 1998; **24**: 763–7.
36. Möller ÅJR. Microbiological examination of root canals and periapical tissues of human teeth. Thesis. *Odont Tidskr* 1966; **74** (Special issue): 1–380.
37. Casciato D, Rosenblatt J. Survival of anaerobic bacteria in common laboratory diluents. *J Clin Microbiol* 1979; **9**: 627–628.
38. Dakin HD. On the use of certain antiseptic substances in the treatment of infected wounds. *Br Med J* 1915; **ii**: 318–320.
39. Byström A, Sundqvist G. Bacteriologic evaluation of the effect of 0.5 percent sodium hypochlorite in endodontic therapy. *Oral Surg Oral Med Oral Pathol* 1983; **55**: 307–312.
40. Byström A, Sundqvist G. The antibacterial action of sodium hypochlorite and EDTA in 60 cases of endodontic therapy. *Int Endod J* 1985; **18**: 35–40.
41. Shuping G, Ørstavik D, Sigurdsson A, Trope M. Reduction of intracanal bacteria using Nickel-titanium rotary instrumentation and various medications. *J Endodon* 2000; **26**: 751–755.
42. Pashley EL, Birdsong NL, Bowman K, Pashley DH. Cytotoxic effects of NaOCl on vital tissue. *J Endodon* 1985; **11**: 525–528.
43. Card S, Trope M, Sigurdsson A, Ørstavik D. The effectiveness of increased apical enlargement in reducing intracanal bacteria. *J Endodon* 2001; **27**: 237 (Abstract #PR22).
44. Gergely JM, DiFiore PM. Intracanal medication in endodontic treatment: a survey of endodontic programs. *Gen Dent* 1993; **41**: 328–331.
45. Messer HH, Chen RS. The duration and effectiveness of root canal medicaments. *J Endodon* 1984; **10**: 240.
46. Messer HH, Feigal RJ. A comparison of the antibacterial and cytotoxic effects of parachlorophenol. *J Dent Res* 1985; **64**: 818–821.
47. Lewis BB, Chestner SB. Formaldehyde in dentistry. a review of mutagenic and carcinogenic potential. *J Am Dent Assoc* 1981; **103**: 429–434.
48. Byström A, Claesson R, Sundqvist G. The antibacterial effect of camphorated paramonochlorophenol, camphorated phenol and calcium hydroxide in the treatment of infected root canals. *Endod Dent Traumatol* 1985; **1**: 170–175.
49. Sjögren U, Figdor D, Spångberg L, Sundqvist G. The antimicrobial effect of calcium hydroxide as a short-term intracanal dressing. *Int Endod J* 1991; **24**: 119–125.
50. Reit C, Molander A, Dahlén G. The diagnostic accuracy of microbiologic root canal sampling and the influence of antimicrobial dressings. *Endod Dent Traumatol* 1988; **15**: 278–283.
51. Barbosa CA, Goncalves RB, Siquera Junior JF, DeUzeda M. Evaluation of the antimicrobial activities of calcium hydroxide, chlorhexidine, and camphorated paramonochlorophenol as an intracanal medicament. A clinical and laboratory study. *J Endodon* 1997; **23**: 297–300.
52. Stevens RH, Grossman LI. Evaluation of the antimicrobial potential of calcium hydroxide as an intracanal medicament. *J Endodon* 1983; **9**: 372–374.
53. Haapasalo M, Ørstavik D. *In vitro* infection and disinfection of dentinal tubules. *J Dent Res* 1987; **66**: 1375–1379.
54. Molander A, Reit C, Dahlen G. The antimicrobial effect of calcium hydroxide in root canals pretreated with 5% iodine potassium iodide. *Endod Dent Traumatol* 1999; **15**: 205–209.
55. Engström B, Hard AF, Segerstad L, Ramström G, Frostell G. Correlation of positive cultures with the prognosis for root canal treatment. *Odontol Revy* 1964; **15**: 257–270.
56. Katebzadeh N, Hupp J, Trope M. Histological periapical repair after obturation of infected root canals in dogs. *J Endod* 1999; **25**: 364–368.
57. Torabinejad M, Ung B, Kettering JD. *In-vitro* bacterial penetration of coronally sealed endodontically treated teeth. *J Endodon* 1990; **12**: 566–569.
58. Trope M, Chow E, Nissan R. *In vitro* endotoxin penetration of coronally unsealed endodontically treated teeth. *Endod Dent Traumatol* 1995; **11**: 90–95.
59. Saunders WP, Saunders EM. Coronal leakage as a cause of failure in root canal therapy: a review. *Endod Dent Traumatol* 1994; **10**: 105–108.
60. Chailertvanitkul P, Saunders WP, Mackenzie D. An assessment of microbial coronal leakage in teeth root filled with gutta-percha and three different sealers. *Int Endod J* 1996; **29**: 387–392.
61. Sjögren U, Figdor D, Persson S, Sundqvist G. Influence of infection at the time of root filling on the outcome of endodontic treatment of teeth with apical periodontitis. *Int Endod J* 1997; **30**: 297–306.
62. Molander A. On testing microbial presence in the root canal. Thesis. Göteborg University, 2000.
63. Kuttler Y. Microscopic investigation of root apices. *J Am Dent Assoc* 1955; **50**: 544–552.
64. Burch JG, Hulen S. The relationship of the apical foramen to the anatomic apex of the tooth root. *Oral Surg Oral Med Oral Pathol* 1972; **34**: 262–268.
65. Bergenholtz G, Lekholm U, Milthorpe R, Engström B. Influence of apical overinstrumentation and overfilling on retreated root canals. *J Endod* 1979; **5**: 310–314.
66. Nair PN, Sjögren U, Krey G, Kahnberg KE, Sundqvist G. Intraradicular bacteria and fungi in root-filled, asymptomatic human teeth with therapy-resistant periapical lesions:

- a long-term light and electron microscopic follow-up study. *J Endodon* 1990; **16**: 580–588.
67. Engström B, Lundberg M. The correlation between positive culture and the prognosis of root canal therapy after pulpectomy. *Odontol Revy* 1965; **16**: 193–203.
 68. Ketterl W. Kriterien für den Erfolg der Vitalexstirpation. *Dtsch Zahnärztl Z* 1965; **20**: 407–416.
 69. Trope M, Delano E, Orstavik D. Endodontic treatment of teeth with apical periodontitis: single vs multivisit treatment. *J Endod* 1999; **25**: 345–350.
 70. Weiger R, Rosendahl R, Löst C. Influence of calcium hydroxide intra canal dressing on the prognosis of teeth with endodontically induced periapical lesions. *Int Endod J* 2000; **33**: 219–226.
 71. Strindberg L. The dependence of the results of pulp therapy on certain factors. An analytical study based on radiographic and clinical follow-up examinations. *Acta Odontol Scand* 1956; **14**: Supplement 21.
 72. Seltzer S, Bender IB, Turkenkopf S. Factors affecting successful repair after root canal therapy. *J Am Dent Assoc* 1963; **67**: 651–662.
 73. Kerekes K, Tronstad L. Long-term results of endodontic treatment performed with a standardized technique. *J Endod* 1979; **3**: 83–89.
 74. Sjögren U, Hagglund B, Sundqvist G, Wing K. Factors affecting the long-term results of endodontic treatment. *J Endodon* 1990; **16**: 498–504.
 75. Zeldow BJ, Ingle JI. Correlation of the positive culture to the prognosis of endodontically treated teeth. A clinical study. *J Am Dent Assoc* 1963; **66**: 9.
 76. Byström A, Happonen R, Sjögren U, Sundqvist G. Healing of periapical lesions of pulpless teeth after endodontic treatment with controlled asepsis. *Endod Dent Traumatol* 1987; **3**: 58–63.
 77. Bender IB, Seltzer S, Turkenkopf S. To culture or not to culture? *Oral Surg Oral Med Oral Pathol* 1964; **18**: 527–540.
 78. Siqueira Junior JF, Lopes HP. Mechanisms of antimicrobial activity of calcium hydroxide: a critical review. *Int Endod J* 1999; **32**: 361–369.