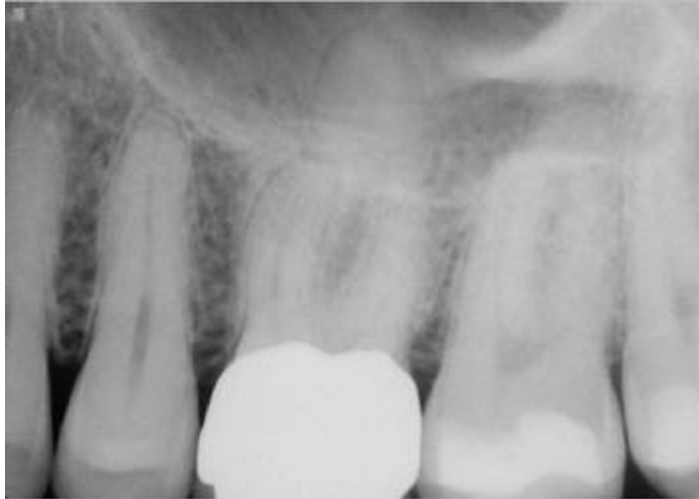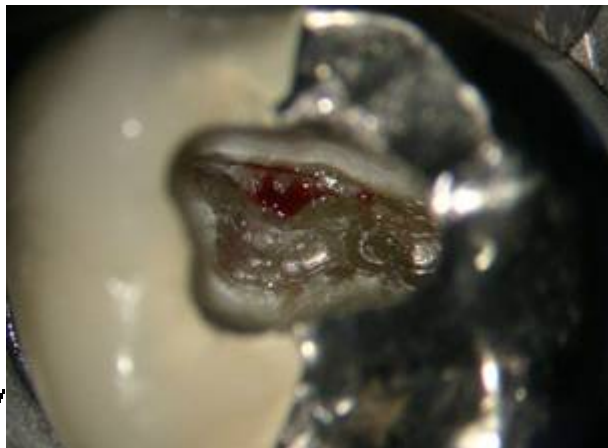


Here's a case I just closed up and will see after a month of CH for completion:


Let's go through the sequence of access steps that I use. My way certainly isn't the only way, but after years of trying different methods, using different ultrasonic tips and burs, this is what I prefer to do at this time. I may do something different next year if I find it makes things easier and better:



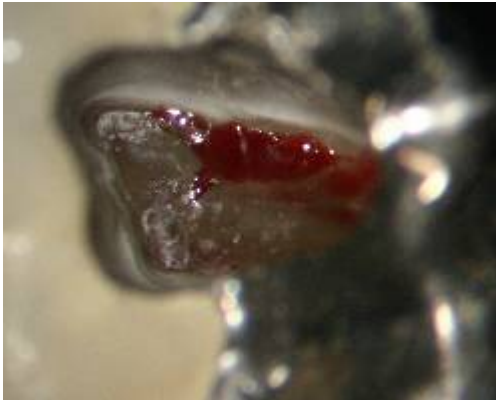Here's the preop radiograph. I found a surprise resorption defect internally at the ML line angle that was probably an early stage Heithersay. I filled it with Geristore at the end of the appointment. There were no tentacles of vascularized dentin extending peripherally or apically so I didn't bother using trichloroacetic acid and simply prepped it out and placed Geristore internally with a Colacote matrix pushed through the perforated area. I plan to flap it on the second appointment and recontour it with the scope. It will be like a deep Class V lingual restoration.



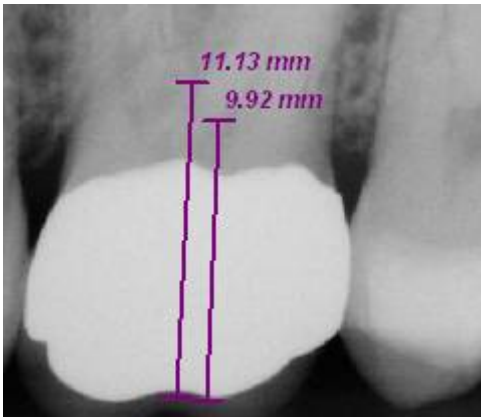
Here's the initial access performed with a combination of Great White metal carbide bur for the lingual metal portion (initial access), and a football diamond for extending toward the buccal into porcelain and "bowling out" the corners. Note the rock solid pulp stone with some peripheral bleeding from scant vascularity.

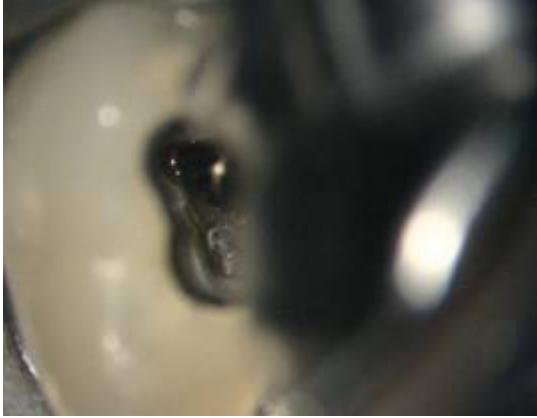


Next step, use of the Brassler composite finishing pear which more precisely and discretely bowls out the corners where the canal orifices will be found.

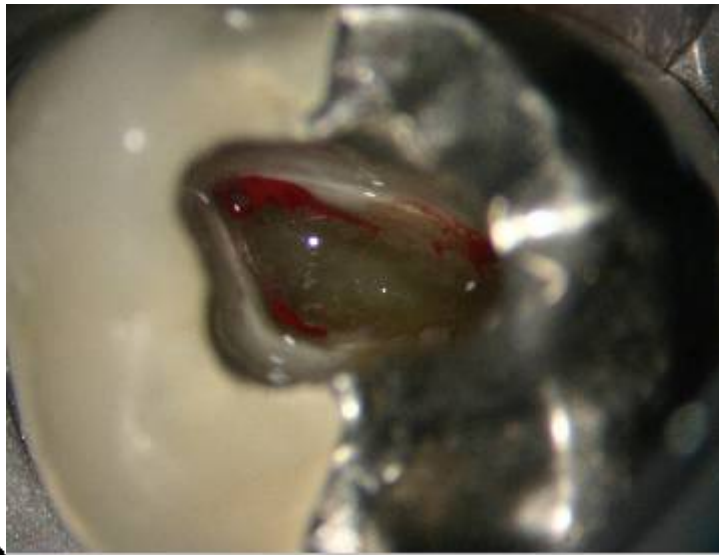


You can start to see a hint of the white dots at each corner. A break in the pulp stone at the MB2 area resulted in some additional bleeding. We know it's not a perf because I measure the floor of the pulp chamber to the occlusal surface to be 9.9 mm on the bite wing radiograph. I could go to 11 mm before perforation of the furca and this level was only about 6-7 mm.







I next carefully used the blunt nosed composite finishing cone bur to "dot" each corner and trough the outline.



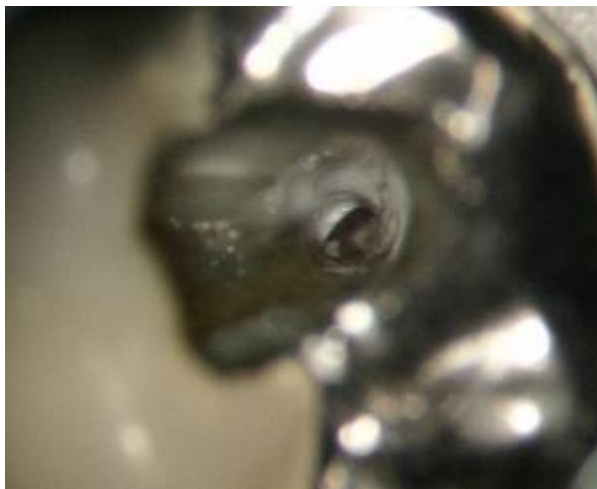
Hmmmm.....Here's an interesting bleeding point that doesn't relate to normal pulp chamber anatomy, and sure enough exploration of this area revealed mottled, striated dentin with interspersed vascularity indicative of an early limited EICR apparent after debridement.






system first.

I continued on and isolated the easy-to-find palatal canal



The three main corners were established and three primary canal system cleared with files (precurved with sequenced recapitulation), then 1-4 Gates Glidden burs.



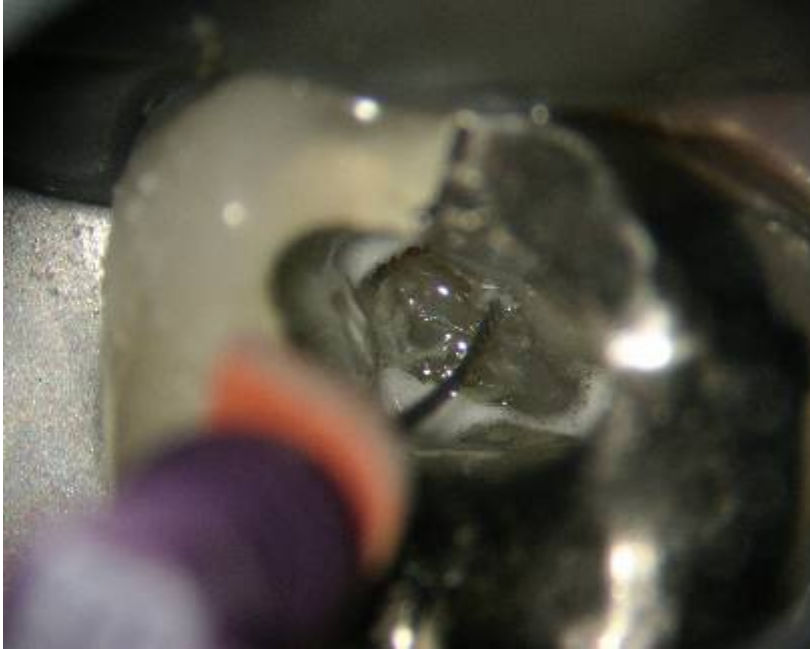demonstration primarily

I next placed a file in the MB2 for

that every molar has an MB2, so that

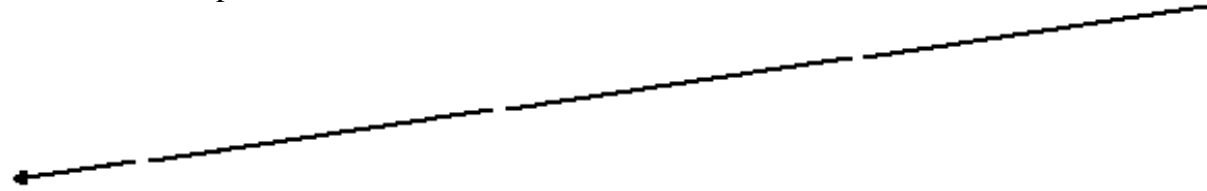
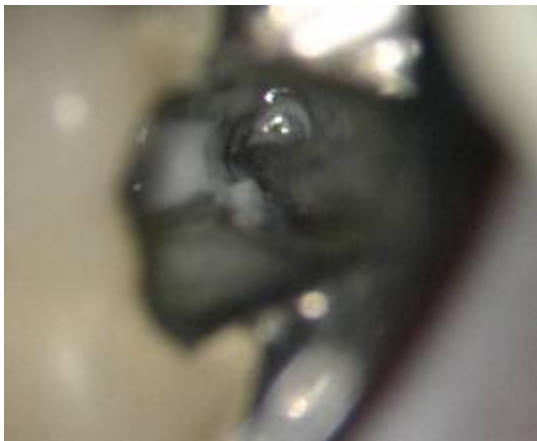for a treatment report pic. I do this to continually show

if one of my referrals sends a case to one of my competitors and they don't get an MB2, they'll get a subliminal message that they should have referred that case to our office. 😊😊😊



The job isn't done until all the irritational dentin is removed along with all pulp stones. Here's a long striation of irritational dentin that needs to be removed along the distal wall of the palatal canal. This is where second palatal canals would be found.

The job isn't done until all the irritational dentin is removed along with all pulp stones. Here's a long striation of irritational dentin that needs to be removed along the distal wall of the palatal canal. This is where second palatal canals would be found.






Here's a big chunk of the palatal pulp stone chipped off into the palatal canal prior to removal.



And these pics show the final extension after preliminary cleaning and shaping. The resorption defect was repaired with Geristore. I try to completely clean and shape all canals prior to placing calcium hydroxide.



This is just common sensical practical elimination of pathologic biological material that was not meant to be inside a pulp chamber and root canal system. They won't teach you this in a horsecrap hands-on course sponsored by a product company because it doesn't sell a file, takes too much time, and doesn't involve a sexy overpriced gadget. Very few endodontists or general dentists eliminate pulp stones and sheets of irritational dentin when they treat cases because they

don't think it's important and it cuts into their production. It's about time someone explains that this is why the literature is such crap. Outcome studies, technique comparisons studies, and product review pieces are typically performed by people with agendas who have little or no idea what "complete endodontic therapy is".

The access preparation is the most important step in facilitating quality endodontic treatment. If you rush this step the resultant treatment will be shit; you will miss canals; you will incompletely clean the apical third, and have debris pushed to the side of uncleaned fins. In this day and age you can have the technology to show an "all-rotary" case on a radiograph demonstrating a smooth geometrically esthetic shape like the advertisements in the throw-away dental magazines. Clearly the time spent on complete access extension, prudent coronal flaring, and meticulous recapitulations with precurved series of hand files results in a much cleaner case. Anyone who denies this or concludes in an article that there is no difference is intellectually dishonest and selling you a used car. The literature and lecture circuits are grossly populated by those selling used cars with nothing under the hood.

Courtesy Dr. Terry Pannkuk - ROOTS