

Accumulated hard tissue debris levels in mesial roots of mandibular molars after sequential irrigation steps

F. Paqué, C. Boessler & M. Zehnder

Division of Endodontology, Department of Preventive Dentistry, Periodontology, and Cariology, University of Zürich Center for Dental Medicine, Zürich, Switzerland

Abstract

Paqué F, Boessler C, Zehnder M. Accumulated hard tissue debris levels in mesial roots of mandibular molars after sequential irrigation steps. *International Endodontic Journal*, 44, 148–153, 2011.

Aim To investigate the impact of sequential irrigation procedures on accumulated hard tissue debris (AHTD) levels in canal systems in mesial roots of human mandibular molars after instrumentation.

Methodology Based on pre-scans in a micro-computed tomography (μ CT) system, 20 extracted human mandibular molars with joining mesial root canals and an isthmus between these were selected. Canals were instrumented using the ProTaper rotary system until the F3 instrument reached working length. A 1% NaOCl solution was applied during instrumentation, followed by a final 5-mL flush to working length. Subsequently, canals were irrigated with 5 mL of 17% EDTA. Thereafter, passive ultrasonic irrigation (PUI) was performed using 1% NaOCl on three occasions each for 20 s. Percent values of total canal system

volume filled with AHTD were calculated based on high-resolution scans after each irrigation step. Data was compared using repeated measure ANOVA followed by paired *t*-test for individual comparisons. Bonferroni's correction was applied for multiple testing; the alpha-type error was set at 1%.

Results Instrumentation of the root canals in conjunction with 1% NaOCl irrigation left 6.9 ± 4.2 vol.% of the total canal system volume filled with AHTD. This value was significantly ($P < 0.01$) reduced to 4.9 ± 3.6 vol.% after EDTA irrigation. Subsequent PUI resulted in a further significant ($P < 0.01$) reduction to 3.7 ± 2.8 vol.%.

Conclusions In this quantitative study on AHTD reduction, a significant effect of EDTA and PUI was shown. However, approximately half of the debris that accumulated during instrumentation remained in the canal system.

Keywords: debris, EDTA, irrigation, NaOCl, PUI, ultrasonic.

Received 25 August 2010; accepted 8 October 2010

Introduction

Chemo-mechanical root canal preparation aims at making the root canal system ready for the subsequent filling procedure (Grossman 1943). The goal is to get the root canal system as clean as possible to then be able to seal it and thus prevent survival of microorgan-

isms, re-infection and the resulting inflammatory host reactions (Schilder 1974). In the context of cleaning root canals, much emphasis has been placed on the generation and subsequent removal of the so-called smear layer, a structure adhering to the canal wall, which is produced during mechanical preparation (Torabinejad *et al.* 2002, Violich & Chandler 2010). Smear layer consists of dentinal filings, and may include biofilm and pulp tissue remnants (Gwinnett 1984). A smear layer can be observed on scanning electron images of root canal walls (McComb *et al.* 1976). However, during SEM evaluations, roots have to be dried in ethanol and fractured. In the vast

Correspondence: Dr Frank Paqué, Department of Preventive Dentistry, Periodontology, and Cariology, University of Zürich Center for Dental Medicine, Plattenstrasse 11, CH 8032 Zürich, Switzerland (Tel.: +41 (44) 634 3468; fax: +41 (44) 634 4308; e-mail: frank.paque@zzmk.uzh.ch).

majority of studies, single-rooted teeth were used, because these are easy to fracture and allow semi-quantitative comparisons of different concepts to remove the smear layer (Hülsmann *et al.* 2003). However, scanning electron microscopy images provide limited information. The two-dimensional assessment of root canal walls is ambiguous, because the appearance of the canal wall can vary considerably between teeth (Lottanti *et al.* 2009). In addition, single-rooted teeth, with the exception of trauma cases in young patients that require little instrumentation to begin with, are not amongst those teeth that commonly require root canal treatment (Kirkevang *et al.* 2007).

In a recent methodological study, the possibility to quantitatively assess inorganic debris in molar teeth was presented (Paqué *et al.* 2009). This method is based on micro-computed tomography (μ CT) scans and can be used to monitor the accumulation and, theoretically, also the removal of radio-opaque structures in root canal recesses during and after instrumentation. In contrast to scanning electron microscopy studies on smear layer, this method is quantitative, three-dimensional and can be applied in teeth with complex anatomy. The three-dimensional 'smear layer' observed on μ CT scans was termed accumulated hard tissue debris (AHTD) (Paqué *et al.* 2009). However, no irrigation during instrumentation of the root canals was used in that methodological study to maximize the AHTD.

It was the goal of the present investigation to study the impact of sequential irrigation procedures on AHTD levels in root canal systems in mesial roots of human mandibular molars after instrumentation. The standard irrigation protocol (Yamada *et al.* 1983) using sodium hypochlorite (NaOCl) during and after instrumentation followed by a flush with a chelating solution (17% EDTA) and a final NaOCl flush was investigated. In accordance with current clinical practice, irrigants were administered at working length using slim side-vented needles, and the final NaOCl application was ultrasonically activated (van der Sluis *et al.* 2007).

Materials and methods

Experimental teeth

Human mandibular first and second molars from a collection of extracted teeth were pre-scanned using a high-resolution μ CT system (μ CT 40, Scanco Medical, Brüttisellen, Switzerland). Based on these pre-scans, 20

mandibular molars with joining mesial root canals and an isthmus between these of at least 2 mm in the coronal-apical direction were selected.

Chemo-mechanical preparation

Root canals of the molars were accessed by using a diamond-coated bur, and mesial canals filled with 1% NaOCl were prepared using ProTaper instruments (Dentsply Maillefer, Ballaigues, Switzerland). Prior to preparation, working length was determined by inserting a K-file ISO size 8 until the tip of the instrument became visible at the tip of the root; 1 mm was subtracted from this length. Teeth were then mounted on scanning electron microscopy stubs (014001-T; Bal-Tec AG, Balzers, Liechtenstein) in epoxy resin (Stycast; Emerson & Cuming, Oevel, Belgium) to allow exact repositioning during repetitive scanning procedures. The apices were sealed using sticky wax before the mounting procedure. ProTaper SX, S1 and S2 were used to flare the orifice, coronal and middle parts and to create a straight-line access.

A glide path was established using size 10, 15 and 20 K-files. Subsequently, rotary instrumentation was accomplished using S1, S2, F1, F2 and F3 to working length. After each instrument canals were irrigated with 1 mL of 1% NaOCl and apical patency was verified using a size 10 K-file. After instrumentation both canals were irrigated with 5 mL of 1% NaOCl using a 30-gauge side-vented irrigating tip (Max-i-Probe, Hawe-Neos, Dentsply, Bioggio, Switzerland) to working length over a 2-min period. Subsequently, the teeth were re-scanned.

After the first re-scanning procedure, canals were irrigated with 5 mL of 17% EDTA for 2 min using the delivery system described above and then teeth were re-scanned a second time. Subsequently, canals were subjected to passive ultrasonic irrigation (PUI) by inserting a pre-bent size 15 K-file (Endosonore, Dentsply Maillefer) to 1 mm from working length. The ultrasonic unit used was an EMS Piezon master 400 (EMS, Nyon, Switzerland), the settings were: $\frac{1}{4}$ of power, no flow. Canals were filled with 1% NaOCl and activated 3 times for 20 s with intermittent replenishment of the NaOCl solution. Subsequently, teeth were subjected to the final scan.

μ CT scans

Four high-resolution scans were performed per individual tooth as described above: (i) prior to treatment,

(ii) after instrumentation and irrigation with 1% NaOCl, (iii) after irrigation with 17% EDTA and (iv) after PUI. Teeth were scanned at 70 kV and 114 μ A with an isotropic resolution of 20 μ m resulting in 600 to 800 slices for each root. A fixed threshold was applied to separate dentine from root canals and binary images of the root canals were produced. The outer root contour was automatically registered. Three-dimensional (3D) scans were co-registered with each other with rigid 3D rotation and translation, determined by maximizing the cross-correlation of the overlaid 3D data sets of the outer hull of the tooth which is unchanged by the root canal treatment. This co-registration was performed with accuracy better than 1 voxel as has been described (Paqué *et al.* 2009).

Volumes of matched root canals before and after preparation were calculated using specially developed software (IPL V5.06B, Scanco Medical). Hard tissue debris was identified and calculated as follows: voxels that were identified as soft-tissue, liquid or air (canal volume) in the pre-operative scan but then were filled with radiopaque material in the post-operative scan were assumed to be filled with hard tissue debris (Fig. 1a). Counting those voxels, multiplied with the volume of one voxel thus resulted in volume of apparent hard tissue debris filling the original root canal space. Voxels representing canal wall areas that were removed during instrumentation but then filled with debris could not be included in this calculation, because it is not possible to unambiguously discern between AHTD and dentine on the scans.

For visualization of the complete mesial canal system before and after root canal preparation the volume of interest for each tooth was selected extending from the furcation region to the apex of the roots (Fig. 1b). Subsequently, the voxels that turned from radiolucent to radiopaque reflecting the AHTD were superimposed on the original canal anatomy. AHTD could thus be visualized in the complete mesial canal system (Fig. 1c).

Data presentation and analysis

Data are presented as vol.%, indicating % of the original canal volume filled with apparent hard tissue debris. Values were rounded to one digit. Box-plots revealed that data distribution was normal (even). Consequently, parametric statistics were applied to compare AHTD levels after the different treatment steps: Repeated measure analysis of variance (ANOVA) was applied to detect whether there was a significant impact of the different irrigation steps on the outcome. Inter-

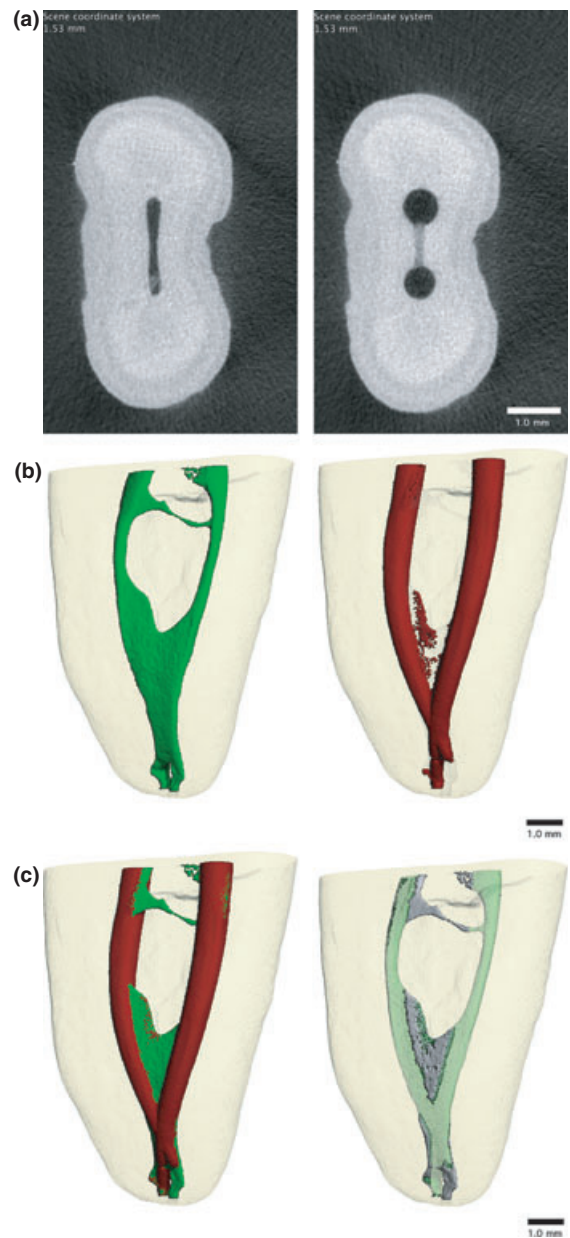


Figure 1 Individual μ CT scans from the apical root third before and after root canal preparation (a). Three-dimensional reconstruction of the whole canal system before (left) and after (right) treatment (b). Uninstrumented canal areas (static voxels) depicted in green (c, left). Accumulated debris can be depicted and calculated by superimposing the areas that did not contain radiopaque material prior to treatment and then were filled after instrumentation over the original canal anatomy (c, right).

group comparisons were made using paired *t*-tests followed by Bonferroni's correction for multiple testing. The alpha-type error was set at 0.01.

Results

Three-dimensional reconstructions of the entire mesial root canal system showed accumulated debris not only in isthmuses, but also in fins, ramifications and accessory canals (Figs 2 and 3). The sequential irrigation steps had a significant impact on hard tissue debris

levels ($P < 0.01$). Instrumentation of the root canals in conjunction with 1% NaOCl irrigation followed by a final 5-mL flush using 1% NaOCl left 6.9 ± 4.2 vol.% of the total canal system volume filled with AHTD. This value was significantly ($P < 0.01$) reduced to 4.9 ± 3.6 vol.% after EDTA irrigation. Subsequent PUI resulted in a further significant ($P < 0.01$) reduction to 3.7 ± 2.8

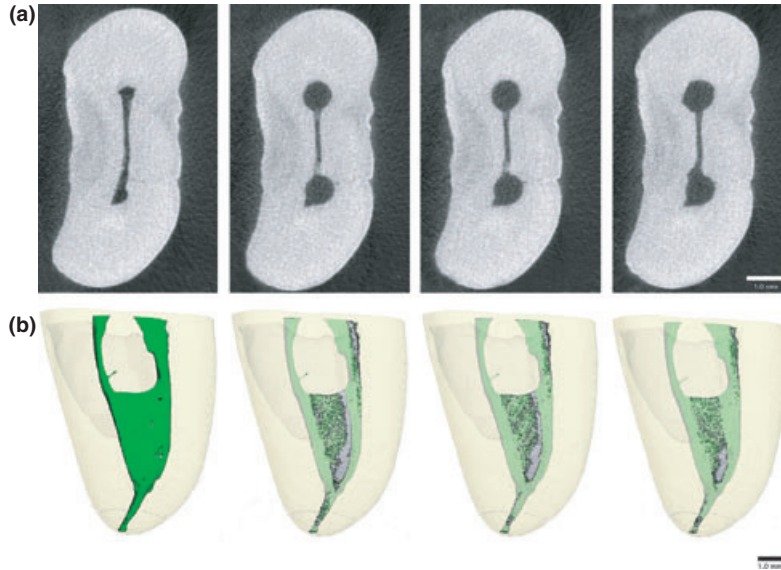


Figure 2 Individual μ CT scans from the apical root third of a typical specimen before and after root canal preparation and irrigation with NaOCl, subsequent irrigation with EDTA and final passive ultrasonic irrigation using again NaOCl (a, from left to right). The corresponding three-dimensional reconstructions of the whole canal system are depicted below (b).

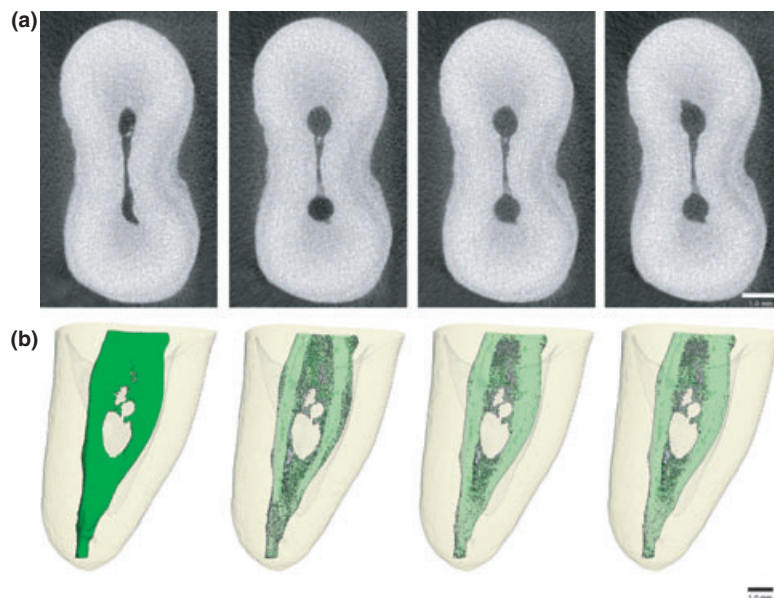


Figure 3 Individual μ CT scans from the apical root third of another specimen before and after root canal preparation and irrigation with NaOCl, subsequent irrigation with EDTA, and final passive ultrasonic irrigation using again NaOCl (a, from left to right). The corresponding three-dimensional reconstructions of the whole canal system are depicted below (b).

vol.%. The overall debris reduction after EDTA irrigation and PUI (when the value after instrumentation was taken as 100%) was $50.8 \pm 18.7\%$, indicating that half of the debris accumulated during instrumentation could not be removed by the subsequent irrigating steps.

Discussion

This study appears to be the first, in which the accumulation and subsequent removal of hard tissue debris during chemomechanical root canal treatment were assessed three-dimensionally. It was shown that the irrigating protocol that has been advocated based on two-dimensional analyses of the canal walls of single-rooted teeth does result in a significant reduction of AHTD. However, about half of the debris that was created during instrumentation could not be removed.

It would appear that the current approach using μ CT scans is more relevant than assessing the cleanliness of canal wall surfaces. Scanning electron microscopy is invariably limited to single-rooted teeth with straight roots, which need to be fractured. Clinical observations, however, show that persistent apical periodontitis is most frequent in molar teeth with their relatively complex anatomy (Kabak & Abbott 2005, Kirkevang *et al.* 2007). A further advantage of the μ CT approach over previous methods is its non-invasiveness. It thus allows the assessment of sequential treatment steps longitudinally. However, as any other research approach, the current method is not free of limitations. First and foremost, the clinical relevance of AHTD is unclear. The idea that debris could shelter microorganisms (Sen *et al.* 1999) or inhibit the activity of antiseptics (Haapasalo *et al.* 2000, Portenier *et al.* 2001) is deduced from laboratory studies. Nevertheless, histologic observations in mesial roots of clinically treated mandibular molars have revealed biofilms embedded in apparent hard tissue debris in canal recesses (Nair *et al.* 2005). A further limitation of the current method is the fact that μ CT scans can only detect the inorganic aspects of accumulated debris, not the organic counterparts (Paqué *et al.* 2009). Consequently, chemical effects of proteolytic solutions such as NaOCl cannot be determined. This also means that the effect of PUI on AHTD observed in this study was based exclusively on physical ultrasonic effects such as streaming. Sonochemical effects on NaOCl could not be analysed, because these would be limited to soft tissues and other organic materials (Al-Jadaa *et al.* 2009). Consequently, the concentration of the NaOCl solutions

used in this study was probably of minor importance, as were potential interferences between EDTA and NaOCl. Whilst EDTA reduces the available chlorine in solution, NaOCl does not affect the calcium chelation by EDTA (Grawehr *et al.* 2003).

Future studies should look at different ways to keep AHTD levels minimal. One way to achieve this would be to use non-aggressive chelating solutions during instrumentation to minimize the initial accumulation of hard tissue debris (Lottanti *et al.* 2009).

Conclusion

This study demonstrated the accumulation and the subsequent partial removal of hard tissue debris when a frequently recommended instrumentation and irrigation regimen was applied.

References

- Al-Jadaa A, Paqué F, Attin T, Zehnder M (2009) Necrotic pulp tissue dissolution by passive ultrasonic irrigation in simulated accessory canals: impact of canal location and angulation. *International Endodontic Journal* **42**, 59–65.
- Grawehr M, Sener B, Waltimo T, Zehnder M (2003) Interactions of ethylenediamine tetraacetic acid with sodium hypochlorite in aqueous solutions. *International Endodontic Journal* **36**, 411–7.
- Grossman LI (1943) Irrigation of root canals. *Journal of the American Dental Association* **30**, 1915–7.
- Gwinnett AJ (1984) Smear layer: morphological considerations. *Operative Dentistry Supplement* **3**, 2–12.
- Haapasalo HK, Siren EK, Waltimo TM, Orstavik D, Haapasalo MP (2000) Inactivation of local root canal medicaments by dentine: an in vitro study. *International Endodontic Journal* **33**, 126–31.
- Hülsmann M, Heckendorff M, Lennon A (2003) Chelating agents in root canal treatment: mode of action and indications for their use. *International Endodontic Journal* **36**, 810–30.
- Kabak Y, Abbott PV (2005) Prevalence of apical periodontitis and the quality of endodontic treatment in an adult Belarusian population. *International Endodontic Journal* **38**, 238–45.
- Kirkevang LL, Vaeth M, Horsted-Bindslev P, Bahrami G, Wenzel A (2007) Risk factors for developing apical periodontitis in a general population. *International Endodontic Journal* **40**, 290–9.
- Lottanti S, Gautschi H, Sener B, Zehnder M (2009) Effects of ethylenediaminetetraacetic, etidronic and peracetic acid irrigation on human root dentine and the smear layer. *International Endodontic Journal* **42**, 335–43.
- McComb D, Smith DC, Beagrie GS (1976) The results of in vivo endodontic chemomechanical instrumentation – a scanning

- electron microscopic study. *Journal of the British Endodontic Society* **9**, 11–8.
- Nair PN, Henry S, Cano V, Vera J (2005) Microbial status of apical root canal system of human mandibular first molars with primary apical periodontitis after “one-visit” endodontic treatment. *Oral Surgery, Oral Medicine, Oral Pathology, Oral Radiology and Endodontics* **99**, 231–52.
- Paqué F, Laib A, Gautschi H, Zehnder M (2009) Hard-tissue debris accumulation analysis by high-resolution computed tomography scans. *Journal of Endodontics* **35**, 1044–7.
- Portenier I, Haapasalo H, Rye A, Waltimo T, Ørstavik D, Haapasalo M (2001) Inactivation of root canal medicaments by dentine, hydroxylapatite and bovine serum albumin. *International Endodontic Journal* **34**, 184–8.
- Schilder H (1974) Cleaning and shaping the root canal. *Dental Clinics of North America* **18**, 269–96.
- Sen BH, Safavi KE, Spångberg LS (1999) Antifungal effects of sodium hypochlorite and chlorhexidine in root canals. *Journal of Endodontics* **25**, 235–8.
- Torabinejad M, Handysides R, Khademi AA, Bakland LK (2002) Clinical implications of the smear layer in endodontics: a review. *Oral Surgery, Oral Medicine, Oral Pathology, Oral Radiology and Endodontics* **94**, 658–66.
- van der Sluis LW, Versluis M, Wu MK, Wesselink PR (2007) Passive ultrasonic irrigation of the root canal: a review of the literature. *International Endodontic Journal* **40**, 415–26.
- Violich DR, Chandler NP (2010) The smear layer in endodontics – a review. *International Endodontic Journal* **43**, 2–15.
- Yamada RS, Armas A, Goldman M, Lin PS (1983) A scanning electron microscopic comparison of a high volume final flush with several irrigating solutions: Part 3. *Journal of Endodontics* **9**, 137–42.