

The hybrid concept of nickel–titanium rotary instrumentation

Helmut Walsch, MS, Dr. med. dent.*

*Department of Endodontics, School of Dental Medicine, University of Pennsylvania,
240 South 40th Street, Philadelphia, PA 19104-6030, USA*

The development of nickel–titanium (NiTi) rotary instruments is undoubtedly a quantum leap for the field of endodontics. Nevertheless, those who have gained some experience in the use of such instruments will confirm that each file system has its own special advantages and disadvantages and that particular rules for its usage need to be followed. With most NiTi systems, it is easy to reach working length and prepare the apex to a small size such as International Standards Organization (ISO) size 20. When the apex is prepared to larger sizes, however, the limits of a particular system quickly become apparent. The idea of the hybrid concept is to combine instruments of different file systems and use different instrumentation techniques to manage individual clinical situations to achieve the best biomechanical cleaning and shaping results and the least procedural errors. The hybrid concept combines the best features of different systems for safe, quick, and predictable results.

Nickel–titanium rotary instrument systems

Some NiTi rotary instrument systems that presently can be used for this hybrid concept are introduced here, and their main features are described. Among these systems, two main categories of NiTi rotary instruments need to be differentiated: active and passive instruments. Active instruments have active cutting blades similar to the K-FlexoFile (Fig. 1A), whereas passive instruments have a radial land between cutting edge and flute (Fig. 1B). The radial land touches the canal wall on its entire surface, guiding the instrument—stable and balanced—within the canal. In general, active

* Heiterwanger Strasse 6, 81373 München, Germany.

E-mail address: hewalsch@yahoo.com

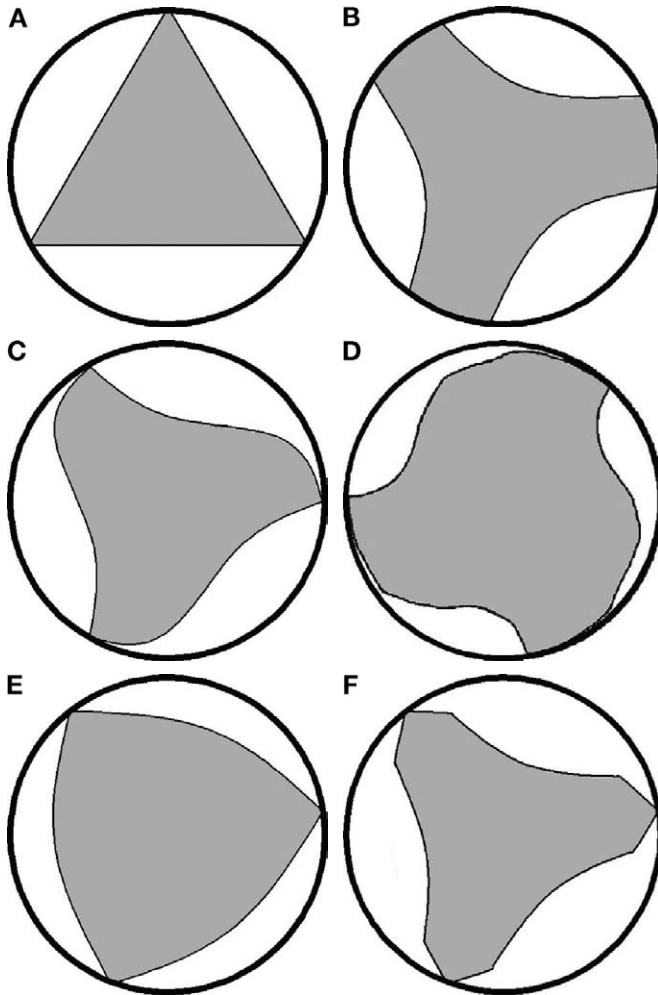


Fig. 1. File cross-sections. (A) K-file, RaCe. (B) ProFile, GT, LightSpeed. (C) Hero 642. (D) K3. (E) ProTaper, Flexmaster. (F) ProTaper F3.

instruments cut more effectively and more aggressively and have a tendency to straighten the canal curvature. In addition, the more positive the rake angle of the blade, the more aggressive the cutting action of the instrument. Passive instruments perform a scraping or burnishing rather than a real cutting action, remove dentin slower, and have less of a tendency for canal straightening.

Key features of all instruments introduced here are three blades and a passive, noncutting tip. ProFile (Dentsply Tulsa Dental, Tulsa, Oklahoma), GT (Dentsply Tulsa Dental), LightSpeed (LightSpeed Technology Inc., San Antonio, Texas), and others belong to the family of passive

instruments. Flexmaster (VDW, Munich, Germany), RaCe (Brasseler USA Savannah, Georgia), ProTaper (Dentsply Tulsa Dental), Hero (MicroMega SA, Besancon, France), K3 (SybronEndo, West Collins Orange, California), and others are active instruments.

Representatives of passive instruments

ProFile instruments come as ISO-sized instruments with a taper of 0.06 in size 15 to 50, a taper of 0.04 in size 15 to 80, and a taper of 0.02 in size 15 to 45. Also available are Series 29 ProFiles for which the increase in size is 29% from one instrument to the next. They come in 0.04 and 0.06 tapers from size 2 (0.129 mm) to 10 (1.0 mm) (Table 1).

GT files for crown down and apical preparation have undergone several size modifications. At present, they come as sets of differently tapered instruments and constant tip sizes (20, 30, and 40). The size 30 and 40 sets consist of four instruments with tapers of 0.10, 0.08, 0.06, and 0.04. The size 20 set consists of five instruments with an additional taper of 0.12.

LightSpeed, in contrast to these instruments, features a design similar to that of a Gates-Glidden (GG) bur. It has a small cutting head with minimal cutting surface and has a thin parallel shaft. These instruments come in half sizes from 20 to 70 and in full sizes from 80 to 100. Their cross-section through the cutting head is similar to that of a ProFile or a GT file (see Fig. 1B). LightSpeed instruments are used in a pecking motion with higher rotational speeds than all other NiTi rotary instruments. When using LightSpeed, no instrument size must be left out. The main advantage of this system clearly is its undefeated ability to manage curves with large instrument sizes because of its shaft flexibility. LightSpeed instruments have been shown to maintain severe canal curvatures [1], and even large apical preparations can be performed with little deviation [2]. Disadvantages are the high number of instruments per set and the need for a step back preparation in combination with constant recapitulation to avoid apical debris retention.

Table 1
Series 29 instrument sizes

Size No.	Size (mm)	Color code
2	0.129	Silver
3	0.167	Gold
4	0.216	Red
5	0.279	Blue
6	0.360	Green
7	0.465	Brown
8	0.600	Silver
9	0.775	Orange
10	1.000	Red

Representatives of active instruments

RaCe instruments come in the following taper/size combinations: as Pre-RaCe instruments—0.10/40, 0.08/35, 0.06/30 and 40; and as RaCe instruments—0.06/20 to 30, 0.04/25 to 35, 0.02/15 to 40 and 50 and 60. Their cross-section is triangular with large flutes (see Fig. 1A). These instruments are very flexible. Their main feature is that the helical angle after some revolutions has short interruptions (becomes 0°), whereby the blades are straight for a short distance and parallel to the long axis of the instrument (alternating cutting edges). The purpose of this feature is to reduce the screw-in effect of the instrument.

When an active instrument is rotating within a curve with a small radius, a clicking sound can sometimes be heard. One reason for this clicking could be that the file breaks loose the dentin into which it was engaged. Another possible reason is the following: during the rotation of a file in a considerably curved root canal, from the moment when the blade touches the inner wall of the elbow of the curve to the moment when the flute is touching that point, the instrument straightens slightly. While the file continues to rotate coronal of the elbow of the curvature, it stands still at the elbow with the flute contacting the elbow until the amount of torque load onto the instrument exceeds the torque needed to force the instrument to rebend to get the blade to “jump” over the elbow again. This “jumping” from flute to flute can cause the clicking noise.

The flutes of NiTi rotary instruments with regular helical angles (screw-like form) will only touch the inner surface of the elbow of a canal curvature for a short distance. The straight part (straight flutes, no helical angle) of a RaCe instrument might touch the inner surface of an elbow at a longer distance, causing more straightening of the file compared with a regular file. The amount of torque needed to cause the instrument to jump may be higher. The particularly high flexibility of RaCe instruments, however, may compensate for this effect.

Hero 642 instruments come in tapers of 0.06 and 0.04 in sizes 20 to 30 and in taper 0.02 in sizes 20 to 45. Hero Apical instruments are accessory instruments for apical enlargement. They come in tapers 0.06 and 0.08 in size 30 and have short cutting areas. The cross-section of Hero instruments is shown in Fig. 1C. These instruments are relatively flexible. The recommended usage, called the “three wave concept,” follows the idea of varying the instrument tapers [3].

K3 instruments come in 0.06 and 0.04 tapers in sizes 15 to 60. Fig. 1D shows their cross-section, revealing that these are very strong instruments.

FlexMaster instruments come in tapers of 0.06 and 0.04 in sizes 20 to 40 and in taper 0.02 in sizes 20 to 70. They have a convex triangular cross-sectional form, shown in Fig. 1E. These instruments are relatively strong.

ProTaper instruments have a convex triangular cross-sectional form, very similar to that of FlexMaster (see Fig. 1E), and also are relatively strong.

ProTaper instruments are unique among all NiTi rotary instruments in that they have different tapers along a single instrument (multitapered instruments). The set consists of six instruments: three shaping instruments (SX, S1, S2) and three finishing instruments (F1, F2, F3). The main difference between the S and F instruments is that S instruments have an increasing taper from tip to top, whereas the F instruments have a decreasing taper from tip to top. Shapers mainly cut in the middle third of the root canal with their tips, following the glide path so as to create an access for the finishers that will cut in the apical third of the root canal. A set of ProTaper instruments used sequentially will only cut along a short distance in the canal, touching little canal wall surface. This effect will reduce the torque load and increase the cutting efficiency of each individual instrument. The convex flutes of the largest instrument (F3) have been cut out to a more convex form, reducing the stiffness and increasing the flexibility of this strong instrument (Fig. 1F). The tip size of F3 is 30; the taper at 3 mm from the tip, however, is 9%. At 2 mm from the tip, the diameter is size 48; at 3 mm, it is size 57.

Nickel–titanium instrumentation rules

To increase the safety of NiTi rotary instrumentation techniques, some basic rules should always be obeyed. The following most important rules apply for the use of any NiTi rotary instruments:

- The lowest recommended rotational speed seems safest [4,5].
- Use file lubrication (RC-prep [Premier Dental, Plymouth Meeting, Pennsylvania] or similar).
- Support operator's hand at the neighboring teeth to compensate for patient moving, increase file control, and avoid the screw-in effect.
- Keep canals flooded with sodium hypochlorite during instrumentation.
- Use no apical pressure.
- Rotate files continuously.
- Minimize cutting time.
- Make each file insertion deeper with the same file.
- Withdraw immediately at desired length.
- Clean and check files after each insertion.
- Irrigate, recapitulate, and reirrigate after each file insertion.
- Check patency frequently.

Most of these rules seem even more critical for active instruments than for passive ones. Active instruments can lead to procedural errors faster than passive ones in inexperienced hands.

Experience using the instruments on extracted teeth before clinical use is mandatory. It has been shown that with increasing experience, the frequency of instrument deformations and fractures decreases [6].

To understand the concept of a hybrid sequence of biomechanical instrumentation, three different approaches to enlarging a root canal (crown down, step back, and apical widening) are summarized in the following sections.

Crown down

The crown down idea is to step apically by using a series of files while decreasing instrument size or instrument taper. The next smaller file will perform its cutting action deeper in the canal, leaving the engaging surface of each instrument minimal and, therefore, decreasing the torque load of each instrument. Repeating the use of such a series of files will also result in either gaining deeper access into the canal or enlarging the canal further by each sequence. Fig. 2 shows the decreasing taper approach with a classical GT file set. The tip size of each instrument is ISO 20, with tapers of 0.12 (blue), 0.10 (red), 0.08 (yellow), and 0.06 (silver). The arrows in Fig. 2 indicate the areas where the individual instruments engage the dentinal walls. Crown down minimizes coronal interference, eases instrument

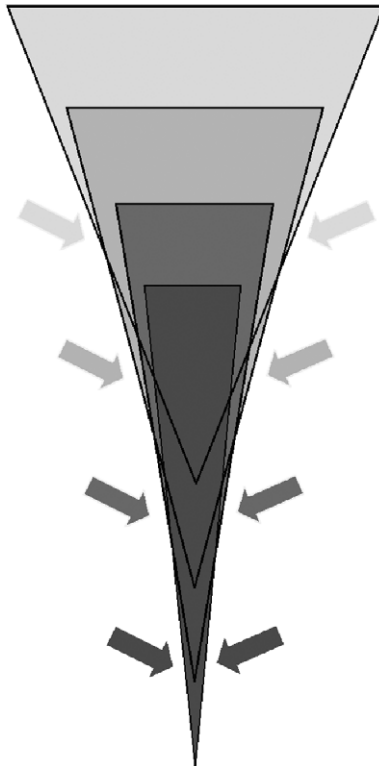


Fig. 2. Crown down approach with decreasing taper. Arrows indicate corresponding cutting area.

penetration, increases apical tactile awareness, reduces canal curvature, minimizes change in working length during apical instrumentation, allows irrigation penetration to preparation depth, removes bacteria before approaching the apical canal third (therefore preventing iatrogenic apical contamination), reduces the contact area of each instrument (therefore reducing torque and increasing cutting efficiency and safety), and reduces the instrument tip contact and the incidence of procedural errors.

Step back

The step back idea is to enlarge apically first and then step coronally by sequentially increasing instrument sizes or taper (flaring) for each instrument of a file series. A direct comparison between crown down and step back has shown that using crown down will result in less tip contact, less force, and less torque compared with step back. As a result, crown down is safer than step back [7]. Nevertheless, step back is essential for different steps of instrumentation.

Apical widening

The apical widening idea simply describes using a series of files in increasing order to enlarge the apex by using all files to the same length. This approach is particularly important for the last steps of apical instrumentation.

Ideal preparation

The ideal preparation form for the hybrid concept takes its pattern from the definition by Herbert Schilder [8] and is slightly modified: “a three-dimensional continuously tapering cone in multiple planes *with sufficient apical enlargement* preserving foramen position and size” (modification in italics).

The different steps of the biomechanical instrumentation [9] should be performed in a crown down manner in the following order: access cavity, straight line access, working length determination, master apical file (MAF) size determination, glide path creation, body shaping, and apical preparation (apical pre-enlargement, apical enlargement, apical LightSpeed instrumentation, apical finishing). The benefits of working in this order include less risk of iatrogenic contamination, more visibility and control over the area of dentinal wall removal, better access for irrigants, and less procedural errors.

For best cutting efficiency, the general instrumentation approach preferably should be performed crown down; however, a combination with step back and apical widening is often needed.

With tapered instruments, taper lock (staying with a constant instrument taper) should be avoided whenever possible because varying the taper

during instrumentation will reduce the contact area of the instrument with the root canal wall and, therefore, reduce the torque load and increase the cutting efficiency and safety.

Different canal—different approach

For all steps of root canal preparation, there is no “one perfect system” of NiTi rotary instruments for all cases. Different canals require different approaches. Not every clinical situation can be managed with one particular system, and different systems have different properties that should be used where they work best within the hybrid concept. Therefore, an understanding of where each instrument performs its cutting action in the canal is needed.

A chronologic description of all the steps of biomechanical instrumentation using the hybrid concept is given below.

Straight line access

After achieving an ideal access preparation outline, removing calcifications, and gaining access into the root canals, the coronal third of the canals needs to be straight lined to minimize the coronal aspect of the curvature (Figs. 3, 4). A straight line form can be gained by removal of the dentinal overhang in the outer aspect of the orifice and coronal third of the canal. The straight line form eases the penetration of the irrigation solution and following instruments. It will decrease the coronal interference and, therefore, increase control over the instruments.

Straight line access can be achieved with GG burs in descending order from size 4 to 1 or with orifice shapers. A GG bur size 1 compares to a file size 40 to 50, a GG bur 2 to size 60 to 70, a GG bur 3 to size 80 to 90, and a GG bur 4 to size 100 to 110. This sequence can be repeated, and in cases with little curvature, a considerable part of the body shaping (a later step of instrumentation) is already completed because a high percentage of dentin removal has been accomplished. In cases with more curvature, more body shaping needs to be performed with NiTi rotary instruments later on, as described later. In calcified cases, the GG sequence needs to be reversed, from size 1 to 4.

Working length

The next step is the working length determination. There are five methods available (differently angulated radiographs, electronic apex locator, tactile sense, paper point control, patient sensation); a combination of at least the first two should be used on a regular basis.

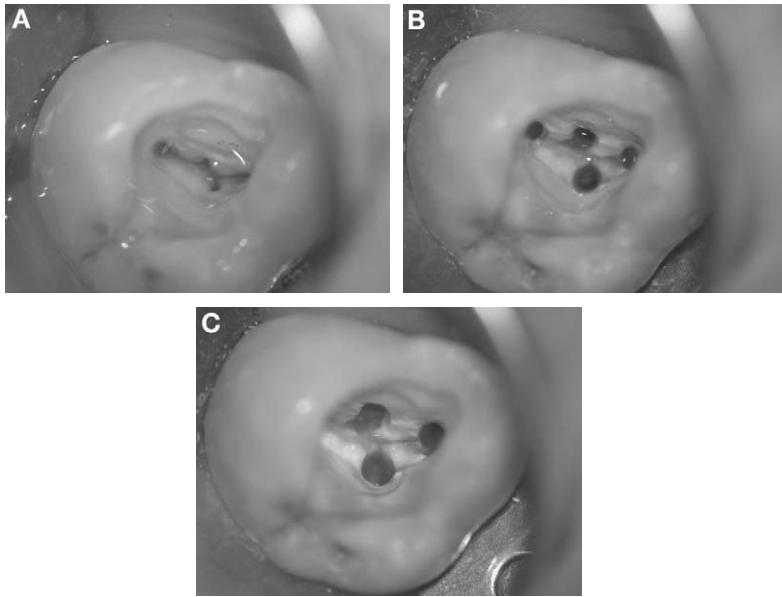


Fig. 3. Straight line access in an upper molar. (A) Before straight line access. (B) After straight line access. (C) After completion of instrumentation; buccal canals.

Master apical file size

The apical canal enlargement to the desired MAF size, should—among other criteria—be based on the original apical canal diameter: “the optimal enlargement of each canal should be calculated...based on the initial size of file that binds at the apical portion of the canal” [10] and “the apex should be enlarged at least three sizes greater than its original diameter” [11]. The apical cross-section of a root canal in most cases, however, is not round in shape but consists of a minor and a major aspect (minimal and maximal diameter). In determining the minor initial canal diameter at the working length, the use of a LightSpeed instrument has been shown by Levin et al [12] to be more accurate than a K file (one versus three ISO sizes too small, on average). Another similar study reported a measurement of up to three ISO sizes too small with LightSpeed and up to four ISO sizes too small with a K file [13]. Both studies are in agreement that there is a tendency to underestimate the original apical diameter. Anatomic investigations confirm that in many cases, the original apical diameter is size 30 or 40 or even larger [14–17]. Moreover, there is currently no way to estimate the major original apical canal diameter clinically.

It is advisable to determine the minimal apical diameter with a LightSpeed instrument after determining the working length. Starting from a small instrument size, by increasing the file size, one will find the first smallest

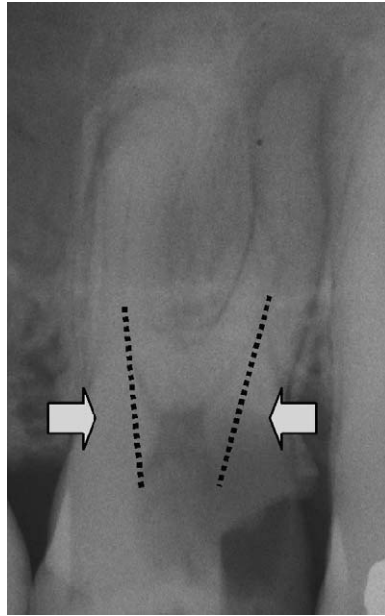


Fig. 4. Straight line access on radiograph. Dotted lines and arrows indicate areas of dental overhang to be removed.

instrument binding at the working length. From this size, the apex should be enlarged at least three to four ISO sizes bigger; however, averages cannot apply in every case. A clinical judgment needs to be made to define the MAF size. All information available about the anatomy of the canal system and the technical difficulty of the case should be taken into consideration. The ideal apical preparation would result in a consistently round form because this allows for better cleaning of the entire canal wall and better apical seal [18,19]. In many cases such as ribbon-shaped canals, this goal cannot be achieved; however, clinicians should try to reach as close as possible to this goal whenever possible, which often means enlarging the canal wider than previously thought.

Glide path

Before using any NiTi rotary instruments, a glide path for these instruments up to ISO size 20 with stainless steel K hand files (0.02 taper) needs to be created so that the fragile tips of small-sized NiTi rotary instruments can follow the path without exploring the canal or cutting. Even light pressure or a small amount of torque would otherwise fracture these instrument tips.

A suitable hand instrumentation technique for stainless steel files smaller than size 15 is watch-winding and pull, requiring cleaning the files after each pull. The best technique for sizes 15 to 20 is the balanced force technique [20].

Body shaping

The next step is a fast and effective removal of the coronal and middle canal third. The classic GT file set (see Fig. 2) has been successfully used for this purpose in decreasing taper order in a crown down manner. This sequence can be repeated several times if necessary until working length is reached. Often, the original apical canal diameter is larger than size 20, so the resulting canal form is flared, with an apical diameter of at least size 20.

Active instruments such as ProTaper can perform this step even more effectively. The ProTaper shaping instruments SX, S1, S2 are ideal for this purpose. They first shape the canal to a flared form with more taper coronally than apically, similar to the shape of the Eiffel Tower in Paris, France. Then, the taper is increased gradually deeper down into the canal. This technique is also considered a crown down approach: the taper is moved crown down, leaving a canal form that allows ideal access for the apical preparation.

Apical preparation

Apical preparation consists of four steps (apical pre-enlargement, apical enlargement, apical LightSpeed preparation, and apical finishing) that are described in the following sections. All four steps may not be necessary in each individual case, because different canals require different approaches.

Apical pre-enlargement

The idea of apical pre-enlargement is to cut quickly and effectively the apical canal third to a size to which the canal at working length can quickly and safely be enlarged. In easy cases, this can be done with active instruments that cut aggressively. ProTaper finishing instruments F1 to F3, for example, will leave an ideal preparation form, provided that F3 reached the working length. This instrument sequence will move the canal taper even further apically (crown down). ProTaper plays a major role in this hybrid concept: a full sequence of these instruments can subsequently perform both body shaping and apical pre-enlargement with ease.

Only the apical 2 to 3 mm need to be further enlarged. The more difficult the case (the more severe the curvature or the smaller its radius), the more the clinician should decide to use passive instruments. In very difficult cases, NiTi rotary instruments also can be used by hand.

Table 2

Diameter comparison between the multi-tapered ProTaper F3 instrument and 3 consistently nickel–titanium instruments with tapers of 2%, 4%, and 6% in size 35

Distance from tip (mm)	Diameter of ProTaper F3		Diameter of consistently tapered NiTi instruments in size 35		
	(9%)	(7%)	(6%)	(4%)	(2%)
0	0.30	—	0.35	0.35	0.35
1	0.39	—	0.37	0.36	0.36
2	0.48	—	0.39	0.38	0.36
3	0.57	—	0.41	0.39	0.37
4	—	0.64	0.43	0.41	0.38
5	—	0.71	0.46	0.42	0.39

Apical enlargement

After pre-enlarging the apex safely, it often needs to be enlarged more, based on the decision of which size MAF should be used for the individual canal. Apical enlargement can be performed with active or passive tapered instruments, depending on the difficulty of the canal curvature.

Tables 2 through 5 show diameter comparisons at different levels from the tip of the multi-tapered ProTaper F3 instrument and other NiTi rotary instruments with consistent tapers of 0.06 (6%), 0.04 (4%), and 0.02 (2%). Table 2 compares an instrument with a tip size of 35, Table 3 with size 40, Table 4 with size 45, and Table 5 with size 50. Areas in which the consistently tapered instruments are larger than the ProTaper F3 instrument are highlighted in gray. Provided that a ProTaper F3 instrument has reached the working length, it becomes obvious that a size 35 instrument (regardless of the taper) used after a ProTaper F3 instrument to the same length in the canal only cuts at the very tip (up to less than 1 mm from the tip) because at 1 mm from the tip, the size prepared by ProTaper F3 is already size 39 (see Table 2). Table 5 shows that a size 50 instrument with a 0.06 taper will cut along the 4 mm from the tip, whereas a size 50 instrument with a 0.02 or 0.04 taper will cut only at the apical 3 mm. The

Table 3

Diameter comparison between the multi-tapered ProTaper F3 instrument and 3 consistently tapered nickel–titanium instruments with tapers of 2%, 4%, and 6% in size 40

Distance from tip (mm)	Diameter of ProTaper F3		Diameter of consistently tapered NiTi instruments in size 40		
	(9%)	(7%)	(6%)	(4%)	(2%)
0	0.30	—	0.40	0.40	0.40
1	0.39	—	0.42	0.42	0.41
2	0.48	—	0.45	0.43	0.42
3	0.57	—	0.47	0.45	0.42
4	—	0.64	0.50	0.46	0.43
5	—	0.71	0.52	0.48	0.44

Table 4

Diameter comparison between the multi-tapered ProTaper F3 instrument and 3 consistently tapered nickel–titanium instruments with tapers of 2%, 4%, and 6% in size 45

Distance from tip (mm)	Diameter of ProTaper F3		Diameter of consistently tapered NiTi instruments in size 45		
	(9%)	(7%)	(6%)	(4%)	(2%)
0	0.30	—	0.45	0.45	0.45
1	0.39	—	0.48	0.47	0.46
2	0.48	—	0.50	0.49	0.47
3	0.57	—	0.53	0.50	0.48
4	—	0.64	0.56	0.52	0.49
5	—	0.71	0.59	0.54	0.50

idea of this comparison becomes clear: after having reached the working length with a ProTaper F3 instrument, it is not difficult to enlarge the apex even wider because other NiTi rotary instruments like FlexMaster or other active or passive tapered instruments in sizes such as 40 with a 0.06 or 0.04 taper and even size 50 with a 0.02 taper can be used subsequently with minimal coronal interference, minimal cutting surface, and therefore, minimal torque load.

Provided in a clinical case that the desired MAF size is 45 and a 0.06 taper should be achieved, according to Table 4, only the apical 3 mm need to be enlarged. To minimize the torque each instrument has to carry, a size/taper sequence in the following order can be used: 35/0.04, 35/0.06, 40/0.04, 40/0.06, 45/0.04, and 45/0.06. If all instruments are used to working length, then this corresponds to the apical widening concept. Accumulation of dentinal shavings at the apex is almost completely avoided. The number of instruments for this step of instrumentation seems large, but each instrument cuts only minimally and its cutting action is accomplished quickly after only one to three rotations. This process can easily be done using the instruments by hand, and it is safer and faster than changing the files in a motorized handpiece.

Table 5

Diameter comparison between the multi-tapered ProTaper F3 instrument and 3 consistently tapered nickel–titanium instruments with tapers of 2%, 4%, and 6% in size 50

Distance from tip (mm)	Diameter of ProTaper F3		Diameter of consistently tapered NiTi instruments in size 50		
	(9%)	(7%)	(6%)	(4%)	(2%)
0	0.30	—	0.50	0.50	0.50
1	0.39	—	0.53	0.52	0.51
2	0.48	—	0.56	0.54	0.52
3	0.57	—	0.59	0.56	0.53
4	—	0.64	0.62	0.58	0.54
5	—	0.71	0.65	0.60	0.55

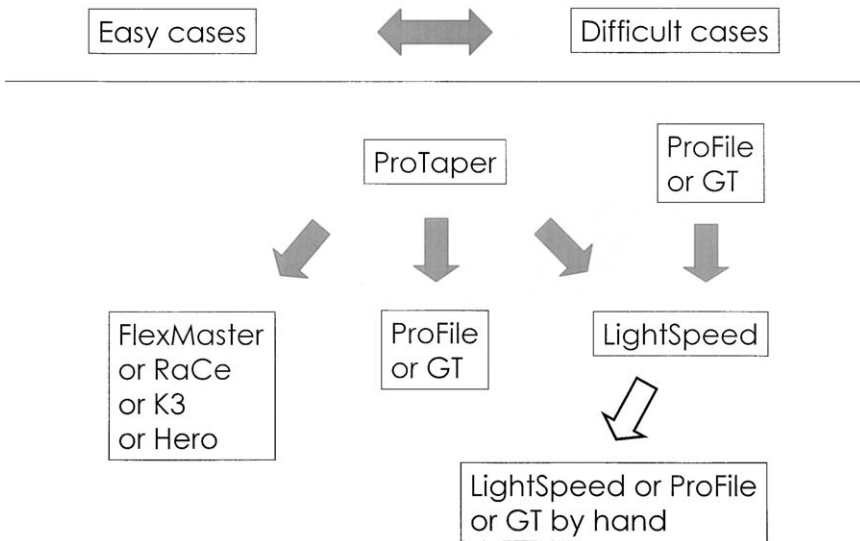


Fig. 5. Hybrid sequences overview.

The more severe the curvature, the smaller the taper of the apical preparation should be and the more the clinician should decide to use passive instruments. At several millimeters from the working length, the difference in size between the existing ProTaper preparation and the size of the instrument used for the apical enlargement becomes so big that this instrument can slightly straighten in the canal curvature and therefore does not need to be bent so hard to follow the curvature. In some cases, the severity of the curvature may not have allowed the use of the same instrument around the particular curvature without previous apical pre-enlargement as described earlier.

Apical LightSpeed preparation

This step is necessary when the desired MAF size is bigger than a size that can be prepared with tapered instruments in a curved canal [21].

The apex will be enlarged to the desired size starting with a LightSpeed instrument that is one LightSpeed size larger than the last instrument that previously reached the working length. The instruments are all used to working length in increasing size order, and no instrument should be left out. Because the resulting apical canal form is cylindrical, a step back is needed to create a taper in the apical part of the canal. Step back increments of 0.5 mm for each LightSpeed size will result in a 0.05 taper; 1-mm increments will give a 0.025 taper. The form of this “pseudo-taper,” however, leaves steps in the canal wall. The irrigation needle or the gutta percha cones might not be able to smoothly bypass these steps on the outer wall of the canal curvature.

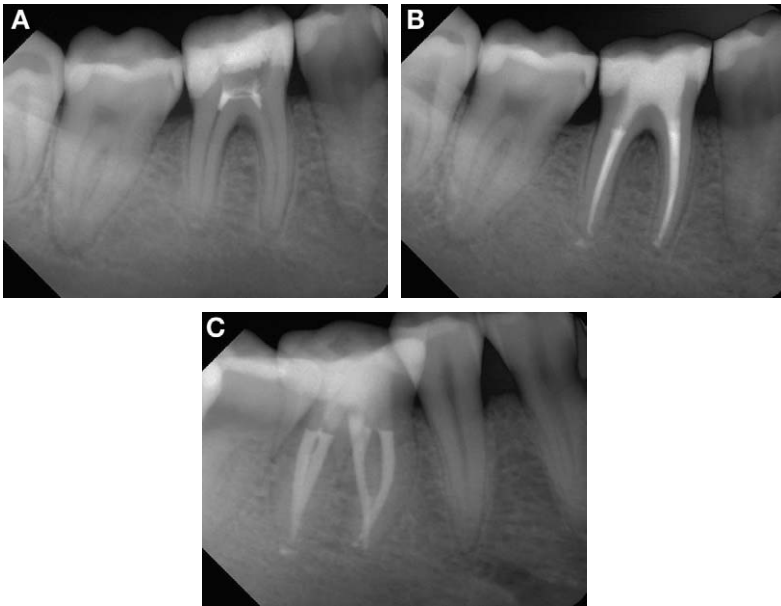

Fig. 6. (A–C) Sample case 1. See text for detail of the case.

Apical finishing

Apical finishing can be performed using the LightSpeed MAF size instrument or another passive instrument in a 0.02 or 0.04 taper and a size that follows to working length easily. The instrument will be forwarded to working length in a clockwise rotating or a watch-winding motion one or two times by hand. This smooths the steps in the outer wall of the curvature and merges the step back taper into the more coronally located taper.

Hybrid sequences overview

The whole idea of the hybrid concept can be condensed to the overview shown in Fig. 5. The left side represents easy cases. Toward the right side, the cases become more difficult. The body shaping and apical pre-enlargement, in most cases, can be managed with ProTaper instruments, and in extremely difficult cases, with passive instruments. The apical enlargement according to the difficulty of the case can be performed with active or passive instruments, and if the MAF size demands, then it can be performed with LightSpeed. The apical finish after LightSpeed step back can follow by hand with the LightSpeed MAF size or another passive instrument that can follow to working length without much effort. As new instruments are developed, they can be integrated into this hybrid concept.

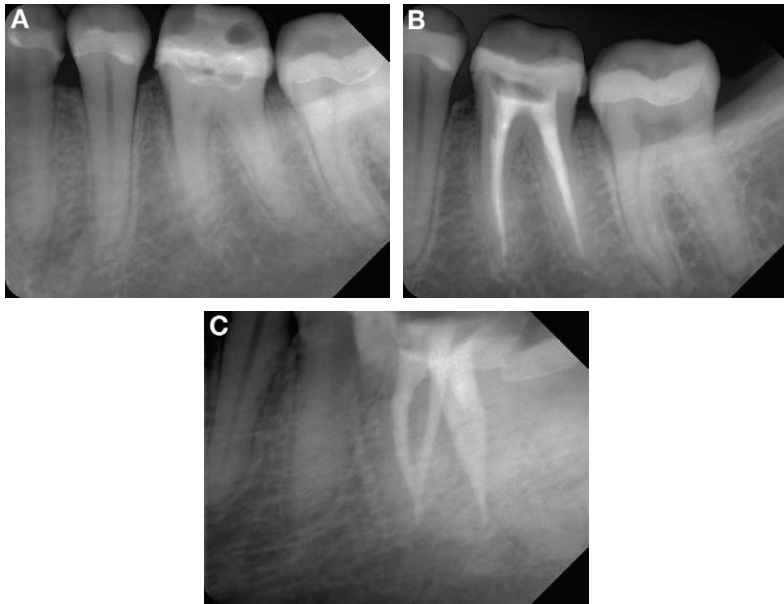


Fig. 7. (A–C) Sample case 2. See text for detail of the case.

Sample cases

Figs. 6 through 10 show several clinical cases in ascending order of difficulty. The protocols of instrumentation used for each case are described below.

In case 1 (Fig. 6), having a mild curvature, straight line and radicular access were performed with GG burs in descending order from 4 to 1. Instrumentation to ProTaper F3 completed body shaping and apical pre-enlargement. Apical enlargement was done with Flexmaster instruments of size/taper 35/0.04, 35/0.06, 40/0.04, and 40/0.06. Taper lock was avoided. Active instruments were used exclusively according to the low-grade difficulty of the case.

Case 2 (Fig. 7) also had a mild curvature. Straight line and radicular access were performed with GG burs in descending order from 4 to 1. Body shaping and apical pre-enlargement were managed with ProTaper to F3. Apical enlargement was performed with passive ProFile instruments. For the distal canals, ProFile instruments of size/taper 35/0.04, 35/0.06, 40/0.04, 40/0.06, 45/0.04, 50/0.04, and 55/0.04 were used. The isthmus has been completely opened with ultrasonic instruments and Hedström hand instruments. The mesial canals were completed with ProFile instruments of size/taper 35/0.04, 35/0.06, 40/0.04, and 45/0.04.

Case 3 (Fig. 8) was moderately curved. Straight line and radicular access were performed with GG burs in the following order: 1 to 3, 4 to 1.

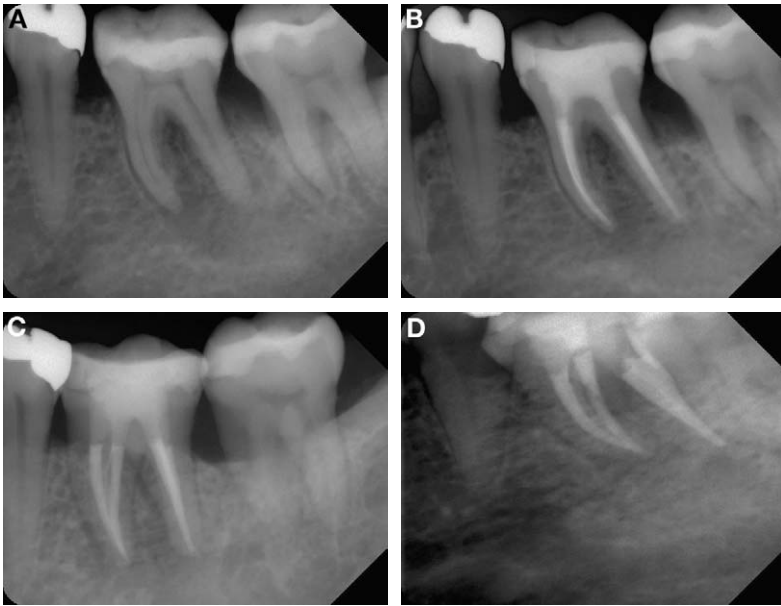


Fig. 8. (A–D) Sample case 3. See text for detail of the case.

ProTaper was used to F3 for body shaping and apical pre-enlargement. Because of the degree of the mesial curvature, apical enlargement could not be performed with tapered instruments. Therefore, LightSpeed instruments were used for this step: mesial to size 45, distal to size 55. A step back was performed: distal to size 70, mesial to size 60. A ProFile instrument of size/taper 45/0.06 was used by hand in a watch-winding motion to smooth the step back steps.

Case 4 (Fig. 9) represented a severe curvature. After gaining access into the mesio-buccal canals with small hand instruments and GT files of size/taper 20/0.10, 20/0.08, and 20/0.06, straight line and radicular access were achieved with GG burs in the order of 1 to 3, 4 to 1. Body shaping and apical pre-enlargement in the buccal canals was performed with ProTaper instruments to F2; F3 went only 3 mm short of working length. The apex was then enlarged to LightSpeed size 35, step back to size 55, and the steps were smoothed with a ProFile instrument of size/taper 35/0.04 by hand.

Case 5 (Fig. 10) had a very large and long palatal canal that was completely calcified coronally. After gaining access into the canal lumen with ultrasonic instruments, straight line access and body shaping with GG burs size 5 to 3 was done to 4 mm short of working length. Apical enlargement was performed with a ProTaper F3 instrument by hand, which went passively. Then, LightSpeed was used to size 80, step back to size 90 and 100, and the canal was smoothed with LightSpeed size 80 by hand.

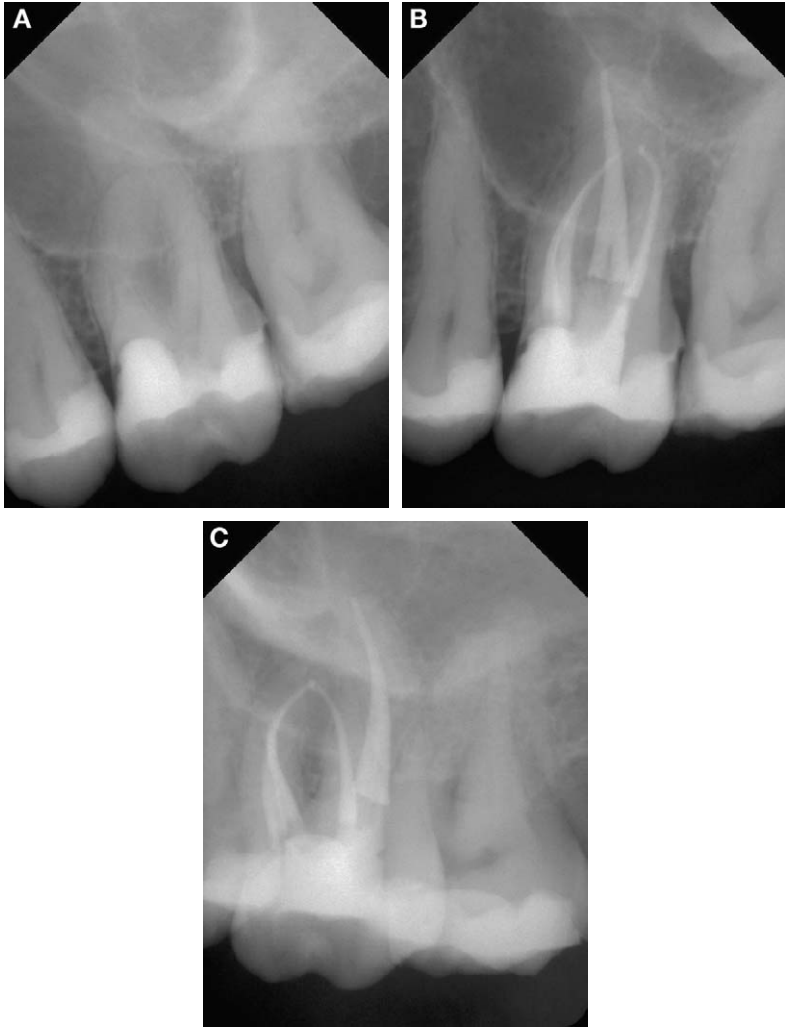

Fig. 9. (A–C) Sample case 4. See text for detail of the case.

Limitations of the hybrid concept

Coronally located canal curvatures, particularly when there is a considerable canal length located apically of the curvature, cannot be managed properly with tapered NiTi rotaries. NiTi hand files used in a step back approach or the use of LightSpeed instruments seems to be the best option for such cases.

Extremely severe curvatures (radius <2 mm) should not be followed with any engine-driven instruments. NiTi K hand files with 0.02 taper or LightSpeed instruments should be used, and only by hand.

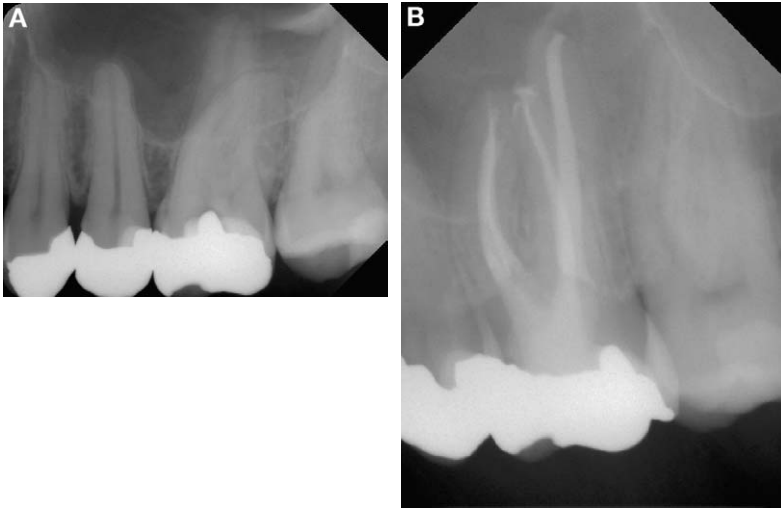

Fig. 10. (A, B) Sample case 5. See text for detail of the case.

In S-shaped curvatures, engine-driven instruments should be used only to the point where the first curvature turns into the second one (where the curvature changes its direction). Beyond that level, hand instrumentation is recommended.

Ribbon-shaped canals are the classic case for circumferential filing by hand. NiTi rotary instruments used with a motor can deflect at uneven parts of the canal wall, be pulled away from their paths, and become jammed or separated.

C-shaped canals should only be hand instrumented because of their unpredictable anatomy.

Apical canal bifurcations often do not allow any straight instrument to follow into either branch of the furcation. Pre-curving stainless steel files seems to be the best solution. Never pre-curve NiTi rotary instruments.

Merging canals, like those often found in the mesial roots of mandibular molars, sometimes do not join at the apex but join more coronally. One of the two canals will often reach from the orifice to the apex (main canal), whereas the other will meet the first one in a severe angle (merging canal). Following the merging canal to working length means forcing the instrument through a kink. With small hand files and tactile sense, the main canal should be identified and instrumented to working length. Then, the merging point needs to be identified, and instrumentation of the merging canal should be performed only to the merging point, followed by recleaning the main canal to working length.

Summary

Each individual case requires an individual instrumentation approach. Different instruments of different NiTi rotary instrument systems and other

instrument systems can be combined in a hybrid concept, based on an understanding of where each instrument performs its cutting action in the canal and when and how to use each instrument to its best ability. Depending on the desired MAF size and the difficulty of the case, different hybrid instrumentation sequences can be used, with some limitations.

References

- [1] Knowles KL, Ibarrola JL, Christiansen RK. Assessing apical deformation and transportation following the use of LightSpeed root canal instruments. *Int Endod J* 1996;29:113–7.
- [2] Thomson SA, Dummer PMH. Shaping ability of LightSpeed rotary nickel-titanium instruments in simulated root canals. Part 2. *J Endod* 1997;23:742–7.
- [3] Vulcain J, Calas P. The three wave concept of HERO 642. *Endod Pract* 1999;2:20–31.
- [4] Gabel WP, Hoen M, Steiman HR, Pink FE, Dietz R. Effect of rotational speed on nickel-titanium file distortion. *J Endod* 1999;25:752–4.
- [5] Dietz DB, Di Fiore PM, Bahcall JK, Lautenschlager EP. Effect of rotational speed on the breakage of nickel-titanium rotary files. *J Endod* 2000;26:68–71.
- [6] Baumann M, Roth A. Effect of experience on quality of canal preparation with nickel-titanium files. *Oral Surg Oral Med Oral Pathol* 1999;88:714–8.
- [7] Blum JY, Machtou P, Micallef JP. Location of contact areas on rotary ProFile instruments in relationship to the forces developed during mechanical preparation of extracted teeth. *Int Endod J* 1999;32:108–14.
- [8] Schilder H. Cleaning and shaping the root canal. *Dent Clin N Am* 1974;18:269–96.
- [9] Moodnik RM, Dorn SO, Feldman MJ, Levey M, Borden BG. Efficacy of biomechanical instrumentation: a scanning electron microscopic study. *J Endod* 1976;2:261–6.
- [10] Weine FS. *Intracanal treatment procedures, basic and advanced topics*. 5th edition. St. Louis (MO): C.V. Mosby; 1996.
- [11] Grossman LI. *Endodontic practice*. 8th edition. Philadelphia: Lea & Febinger Co.; 1974.
- [12] Levin JA, Liu DT, Jou YT. The accuracy of two clinical techniques to determine the size of the apical foramen [abstract]. *J Endod* 1999;25:294.
- [13] Wu MK, Barkis D, Roris A, Wesselink PR. Does the first file to bind correspond to the diameter of the canal in the apical region? *Int Endod J* 2002;35:264–9.
- [14] Kuttler Y. Microscopic investigation of root apices. *J Am Dent Assoc* 1955;50:544–52.
- [15] Kerekes K, Tronstad L. Morphometric observations on the root canals of human anterior teeth. *J Endod* 1977;3:24–9.
- [16] Kerekes K, Tronstad L. Morphometric observations on the root canals of human premolars. *J Endod* 1977;3:74–9.
- [17] Kerekes K, Tronstad L. Morphometric observations on the root canals of human molars. *J Endod* 1977;3:114–8.
- [18] Luks S. Guttapercha versus silver points in the practice of endodontics. *N Y State Dent J* 1965;31:341–50.
- [19] Hwang HK, Jou YT, Kim S. Sealing ability of isthmuses by different obturation techniques [abstract]. *J Endod* 1998;24:283.
- [20] Roane JB, Sabala CL, Duncanson MG. The balanced force concept for instrumentation in curved canals. *J Endod* 1985;11:203–11.
- [21] Hülsmann M. *Wurzelkanalaufbereitung mit Nickel-Titan-Instrumenten. Kombinierte Technik*. 1st edition. Berlin: Quintessenz Verlags-GmbH; 2002.