

# A Micro CT study of the mesiobuccal root canal morphology of the maxillary first molar tooth

P. Verma & R. M. Love

Department of Oral Diagnostic and Surgical Sciences, University of Otago School of Dentistry, Dunedin, New Zealand

## Abstract

**Verma P, Love RM.** A Micro CT study of the mesiobuccal root canal morphology of the maxillary first molar tooth. *International Endodontic Journal*.

**Aim** To observe the morphology of the root canal system of the maxillary first molar mesiobuccal root using micro computed tomography and compare it to current canal classifications.

**Methodology** Twenty mesiobuccal roots were resected from randomly selected extracted human maxillary first molar teeth and prepared for scanning using a SkyScan micro CT scanner (SkyScan 1172 X-ray microtomograph, Antwerp, Belgium) at a slice thickness of 11.6  $\mu\text{m}$ . Three-dimensional images were produced and analysed to record the number and configuration of the canals, the presence of accessory canals, connections between the canals and number of canal orifices and foramina.

**Results** The majority of roots had complex root canal systems with a second mesiobuccal canal present in

90% of the roots examined. Intercanal communications were observed in 55% of the roots. A single apical foramen was found in 15% of roots, two foramina were present in 20% and three or more foramina were present in 65%. In half of the roots, there were two orifices at the furcation level; 40% had one orifice and 10% had three orifices. Accessory canals were present in 85% of the roots. Only 60% of root canals could be classified using the classification of Weine *et al.* (1969) and 70% using the classification of Vertucci (1984).

**Conclusion** Micro computed tomography offers an ability to examine root canal anatomy in fine detail and confirms that the morphology of the mesiobuccal root of the maxillary first molar teeth is complex and that present morphology classifications do not fully reflect the complexity.

**Keywords:** anatomy, mesiobuccal root, micro CT, root canal.

Received 27 May 2010; accepted 26 August 2010

## Introduction

Knowledge of canal morphology and its frequent variations is a basic requirement for endodontic treatment. It is generally accepted that a major cause of failure of root canal treatment is an inability to recognize and therefore adequately treat all of the canals of the root canal system (Weine *et al.* 1969, Vertucci 1974). Thus, the most predictable treatment outcome is achieved when the clinician has an

accurate knowledge of root canal morphology to guide both surgical and non-surgical endodontic therapy.

The mesiobuccal root of the maxillary first molar often presents challenges to the clinician especially in recognizing and locating a second mesiobuccal canal. Knowledge from laboratory studies is essential to provide insight into complex root canal anatomy (Cleghorn *et al.* 2006), and many investigators have used different methods to ascertain the number of canals, ramifications of the main root canal, localization and number of foramina and presence of apical deltas. The advent of three-dimensional (3D) imaging has provided the clinician with increased insight into tooth morphology and facilitated interactive image manipulation and enhancement to visualize the area of

Correspondence: Professor Robert M. Love, Department of Oral Diagnostic and Surgical Sciences, University of Otago, PO Box 647, Dunedin, New Zealand (Tel.: +6434797121; fax: +6434797046; e-mail: robert.love@dent.otago.ac.nz).

interest as a 3D volume. There has been only one published study that has investigated the morphology of the mesiobuccal root of the maxillary first molar with micro CT (Grande *et al.* 2008), showing the viability of the method.

The non-destructive approach of micro CT makes it possible to study the anatomy more accurately whilst overcoming the shortcomings of earlier morphological study techniques. Another advantage of this method is that the internal anatomy of teeth can be reconstructed and observed from various angles. The aim of this study was to determine the complexity of the root canal system of the mesiobuccal root of the maxillary first molar using micro CT and compare it to current classifications.

## Materials and methods

### Specimen selection and preparation

The sample consisted of twenty extracted maxillary first molar teeth from adults with fully formed apices that had not been endodontically treated. The age, sex and race of the patients were unknown, and ethical approval was gained from the University of Otago Ethics committee. The teeth were stored in 10% formalin, and then the roots were cleaned to remove adherent hard and soft tissues, and the mesiobuccal root was resected at the furcation level.

### Scanning

Each root was scanned using a SkyScan micro CT scanner (SkyScan 1172 X-ray Microtomograph, Antwerp, Belgium). The mesiobuccal root was mounted in a 7-mm-diameter plastic container on the scanning platform with the root oriented vertically, and the transmission X-ray image was set for 180 degrees of rotation. The system consisted of a sealed X-ray tube operated at 80-kV/125  $\mu$ A and a precision object manipulator for moving the sample translational in two dimensions as well as rotational movement. The system also had a twelve-bit digital cooled CCD camera with fibre optics (pixel size 11.2–11.6  $\mu$ m, object to source 105.95 mm, camera to source 217.9 mm). An aluminium filter of 0.5 mm thickness was used. The scanning duration varied from 38 to 40 min, and after completion of the scanning procedure, the specimens were placed back in formalin solution.

The image format that was selected was tagged image file format (TIFF) to maximize image quality.

Transmission X-ray images were recorded at 0.4° rotational steps for 180° of rotation. The resulting two dimensional shadow/transmission images (16 bit TIFF) were used to reconstruct axial cross-sections.

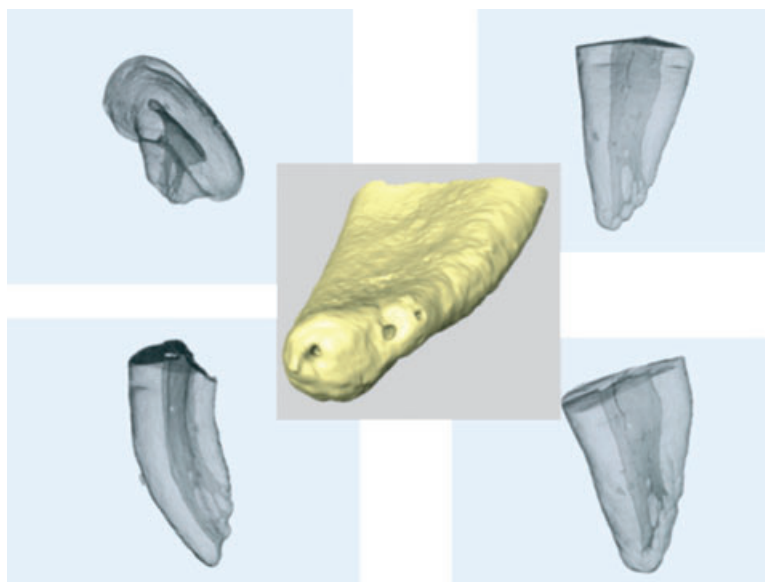Each raw data set was then reconstructed into images using SkyScan's cluster reconstruction software (NRecon/NRecon Server). One preliminary image was scanned in the automatic setting and another with histogram adjustment as appropriate for complete processing; this process optimizes the contrast over the density range of the interest, i.e. root and the root canal. Cross-sections were then reconstructed using a modified Feldkamp cone-beam algorithm (NRecon, Version 1.5.1.4; 11.6  $\mu$ m average pixel size, image size: 900  $\times$  900 pixel).

### Three-dimensional (3-D) reconstruction

The series of cross-sectional images (voxel size of 11.6  $\times$  11.6  $\times$  11.6  $\mu$ m) were imported into a 3-D visualization software package (Amira 4.1; Mercury Computer System Inc., Chelmsford, MA, USA), and the data downsized into half using a file-converting programme T Converter (ECAD-2-12210 PMC; Mercury Computer System Inc.). The registered images were then processed to generate 3-D rendering of the external surface of the root and the internal root canal. During reconstruction, the tooth image was rendered transparent so that the internal morphology could be viewed. The three-dimensional images of the root were viewed on full-screen mode, and pictures were taken at various angles (Fig. 1). Areas of interest were magnified to make observations regarding tooth morphology.

### Observations on root canal morphology

The reconstructed images obtained from the software were analysed by a single observer. The following were recorded: number of canals present; number of apical foramen: defined as the circumference or rounded edge, like a funnel or crater that differentiates the termination of the cemental canal from the exterior surface of the root (Vertucci 2005); presence of an apical delta in the apical third of the root canal: defined as a complex ramification of branches of the pulp canal located near the anatomical apex with a main canal not being discernible; presence of accessory canals: defined as any branch of the main pulp canal or chamber that communicates with the external surface of the root (Vertucci 2005); number of root canal orifices at the resected level of the root; and when a second



**Figure 1** Representative three-dimensional images reconstructed with Amira software.

mesiobuccal was present, the number and location of intercanal communications were recorded: an intercanal communication was defined as a branch of the pulpal space that ran between the main canals but did not communicate with the root surface.

Additionally, the canal configurations were classified according to Weine *et al.* (1969) and Vertucci (1984) classifications. Canals which did not fit into these classification parameters were grouped as non-classifiable.

## Results

### Number of canals

The majority of the mesiobuccal roots had multiple root canals ( $n = 18$ ) with the remaining two roots having one single canal along the entire length of the root. In the 18 roots with multiple canals, two had completely independent mesiobuccal canals, whilst in another two roots, three canals were present with separate orifices at the resected root level, whilst the majority of roots ( $n = 14$ ) had two canals that either joined into one canal, or one canal divided into two or multiple canals, or showed multiple intercanal communications (Fig. 2).

### Apical foramen and delta

Multiple apical foramina were found in most ( $n = 17$ ) of the roots. Only 15% ( $n = 3$ ) of roots had one

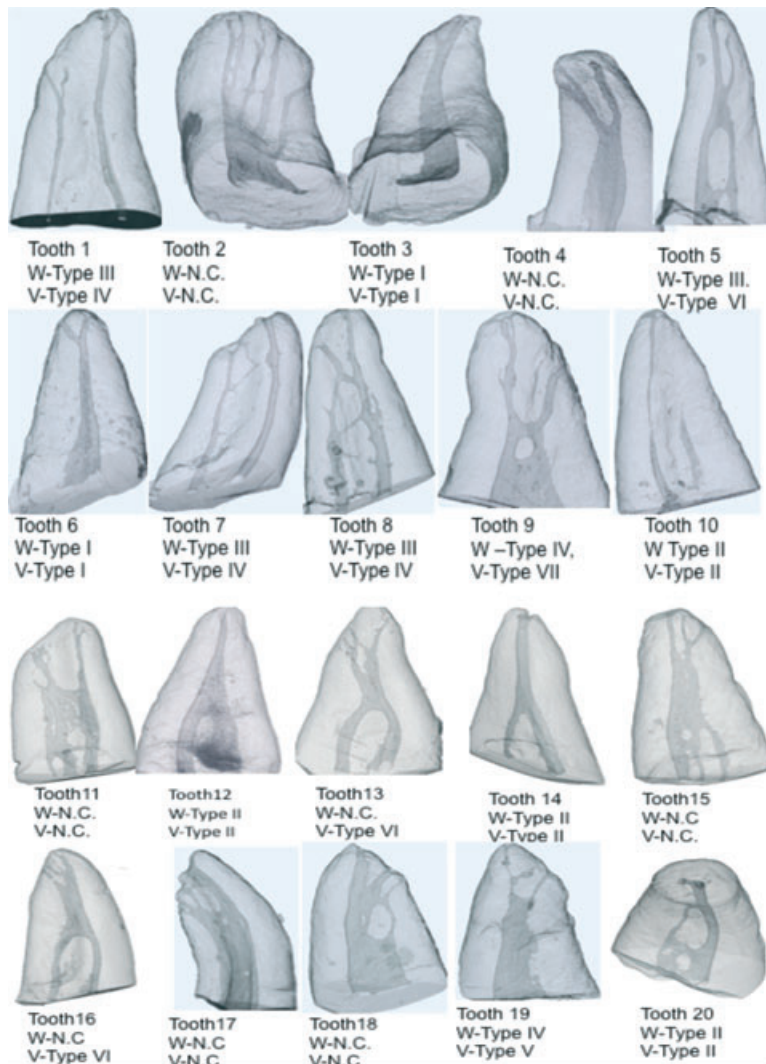
foramen, 20% ( $n = 4$ ) had two foramen and 65% ( $n = 13$ ) of the roots had three or more foramen. An apical delta was present in 40% ( $n = 8$ ) of the specimens (Fig. 3).

### Accessory canals

Accessory canals were present in 17 (85%) of the roots with the majority of the accessory canals located in apical third of the root (Fig. 3). There was no accessory canal seen in the cervical region of the roots, and only one root had an accessory canal in the middle third.

### Number of orifices

There was one orifice at the resected root level in 40% ( $n = 8$ ) of the teeth; when a single orifice was wide, it usually resulted in the root canal dividing in the middle or apical third of the root. A single orifice led to one canal in two (10%) of the roots (Weine *et al.* 1969 Type I), one canal that divided into two canals in another two (10%) of the roots (Weine *et al.* 1969 Type IV) and one canal dividing into multiple canals which could not be classified according to the classification of Weine *et al.* (1969) in four (20%) of the roots. Two orifices were present in ten (50%) of the teeth, and these led to two separate canals in four (20%) of the roots (Weine *et al.* 1969 Type II), and in another four (20%), two canals joined to become one. (Weine *et al.* 1969 Type III). In two roots (10%), it led to two canals joining to become one, which again divided to multiple canals



**Figure 2** Classification of root canal systems according to Weine *et al.* (W:I-IV) and Vertucci (V:I-VIII) and non-classifiable (NC).

and thus could not be classified according to Weine *et al.* (1969). Three orifices were present at the resected root level in two (10%) of the roots. In one tooth, it led to three canals that joined to become one and again divided into three separate canals towards the apex. In the other root, three canals joined to make two canals at the apex. A correlation between the number of orifices and canal configuration could not be made.


**Classification**

All four of the root canal classifications observed by Weine *et al.* (1969) were represented in the sample with Type 2 and 3 being more prevalent; however, only 60% of the roots had root canal configurations that

could be classified (Table 1, Fig. 2). When the root canals were classified according to Vertucci (1984), it was possible to classify 70% of the root canals (Table 2, Fig. 2).

**Intercanal communication**

Intercanal communications were found in 55% (*n* = 11) of the roots, and these were located in all areas of the roots (Table 3). In the apical area, communications formed narrow bands, running from the main canal to another (Fig. 4a). Intercanal communications in the coronal and middle third occurred as either narrow bands running from one canal to another, leading to formation of loops or two canals



**Figure 3** Representative images of the apical third of the roots showing a range of the number of foramina, and presence of apical deltas and accessory canal foramina.

**Table 1** Root canal configuration using the classification of Weine *et al.* (1969)

<i>n</i>	Type I	Type II	Type III	Type IV	Non-classifiable
20	2	4	4	2	8
	10%	20%	20%	10%	40%

joining to form one band, which again divided into two (Fig. 4b,c). In some teeth, intercanal connections were present both in the coronal and middle section or middle and apical sections.

## Discussion

The mesiobuccal root of the maxillary first molar has generated more research and clinical investigation than any other root (Cleghorn *et al.* 2006). However, there is a lack of consistency in the literature regarding

the number of canals and their configurations. This wide range in reported prevalence for the second mesiobuccal canal is perhaps a result of the divergent methods employed for detection including laboratory studies (radiography, sectioning, staining and root clearing) or the lack of use of magnification (loupes, surgical operating microscope) in clinical studies. In recent years, micro computed tomography (micro CT) has emerged as the latest technological tool for in-depth studies of root canal anatomy (Bjørndal *et al.* 1999, Peters *et al.* 2000). Nielsen *et al.* (1995) demonstrated that it was possible to reproduce tooth anatomy accurately using this non-invasive technique. The accuracy of micro CT with respect to periapical bone destruction has been evaluated by correlating histological sections with the micro CT images (Balto *et al.* 2000), whilst a three-dimensional (3-D) finite element model of an incisor (Ichim *et al.* 2006) and a premolar

**Table 2** Root canal configuration using Vertucci's classification (Vertucci 1984)

n	Type I	Type II	Type III	Type IV	Type V	Type VI	Type VII	Type VIII	Non-classifiable
	1	2-1	1-2-1	2	1-2	2-1-2	1-2-1-2	3	
20	2	3	0	3	2	4	0	0	6
	10%	15%	0%	15%	10%	15%	5%	0%	30%

**Table 3** Frequency of intercanal communications in different regions of the root

	Coronal	Middle	Apical
Intercanal communications (n = 11)	(n = 4) 36%	(n = 8) 73%	(n = 5) 45%

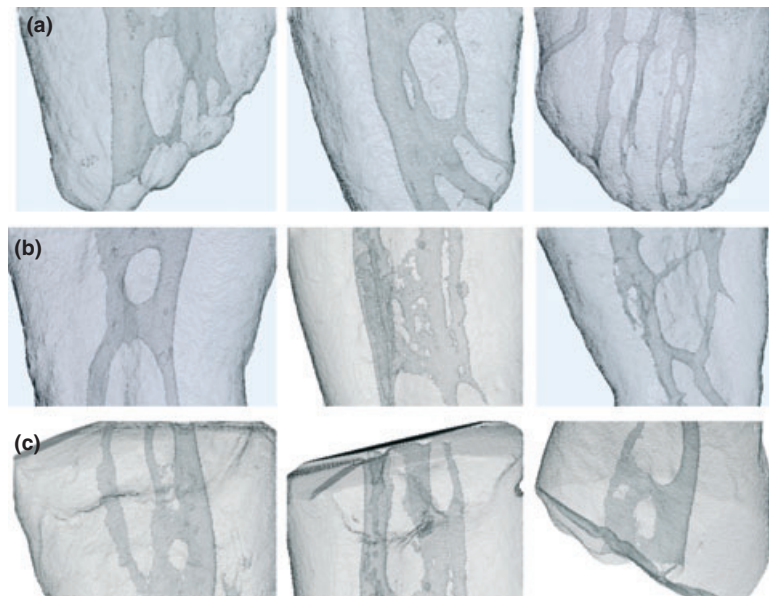
(Verdonschot *et al.* 2001) has been developed with the help of micro CT.

The present study appears to be the first to scan root canals at a spatial resolution of 11.2–11.6 µm, which gave a detailed assessment of canal morphology. Owing to the fact that such a high spatial resolution results in a large amount of data, only 20 specimens were scanned; however, the morphological characteristics displayed by the sample were consistent with previous data, and this verifies the sample size. The advantage of such a high resolution is a greater accuracy of the rendered images. This results in better imaging of small isthmuses, intercanal connections, accessory canals and multiple apical foramen.

Previous laboratory-based studies using either sectioning, clearing or radiography provided limited information and report a varying incidence of the

second mesiobuccal canal from 25% (Pecora *et al.* 1992) to 96% (Kulild & Peters 1990). In a comprehensive literature review, in a weighted average of all these types of laboratory studies (n = 3119 teeth), Cleghorn *et al.* (2006) reported the prevalence of a second mesiobuccal canal was 60.5% of maxillary molar teeth. In contrast, a micro CT study reported that two canals were present in 80% (n = 24) of mesiobuccal roots (Grande *et al.* 2008); similarly, this study showed a high prevalence (90%, n = 18) of two or more canals in mesiobuccal roots, thereby showing the accuracy of the technique even with small sample numbers.

The high resolution of the micro CT technique may explain the high percentage (65%) of apical deltas and multiple apical foramina in the root sample; though, a relationship between the number of anatomical foramina and the root canal configuration could not be found. The high percentage of more than one foramen is in agreement with another study which reported two foramen in approximately 70% of maxillary first molar mesiobuccal roots (Marroquin *et al.* 2004). Similarly, Grande *et al.* (2008) reported three or more foramen in 40% of the mesiobuccal roots of 30 maxillary first



**Figure 4** Representative images of intercanal communications in the apical (a), middle (b) and coronal third (c) of the root canal.

molars, and a high percentage of three or more foramen (80%) in the mesiobuccal root was also found in a scanning electron microscope study of the apical foramina of the maxillary first molars (Gutierrez & Aguayo 1995).

Accessory canals were present in 85% of the roots and were mostly located in the apical third of the root, which is in agreement with other studies (Vertucci 1984, Degerness & Bowles 2008, Grande *et al.* 2008).

The detailed anatomy revealed by micro CT made it difficult to classify all canal configurations according previous studies, in which canals were classified following to sectioning (Weine *et al.* 1969) or clearing (Vertucci 1984). This discrepancy could be attributed to the fact that sectioning or clearing studies do not reveal the detailed anatomy provided by micro CT.

Studies have reported that a single canal at the apex of the mesiobuccal root was found in approximately two-thirds of roots, and two canals were present in one-third of roots (Cleghorn *et al.* 2006, Grande *et al.* 2008). These findings are in contrast to the present study, which showed that 30% of the roots had a single canal in the apical part and the rest (70%) had two or more canals at the apex, which is in agreement with a cross-sectional study of the apical 5 mm of the mesiobuccal root that reported there was a single canal in 36% of the roots and two canals in 64% of the roots (Tam & Yu 2002). These differences could be because of the high resolution (11.6  $\mu\text{m}$ ) of the micro CT used in this study.

Intercanal communications may be poorly accessible to chemomechanical instrumentation and may act as bacterial reservoirs, resulting in persistent periapical pathosis. The literature often uses the term isthmus to mean the same as intercanal connection, transverse anastomosis or intercanal communication. This is because most of the studies were conducted using histological cross-sections to see the connection between the two canals and the typical appearance in this view is an isthmus. The present study found intercanal communications in over half ( $n = 11$ ) of the roots examined. This is in agreement with Vertucci (1984) who reported a 52% incidence of transverse anastomosis, and other studies showing that they are located mostly in the middle third of the root (Tam & Yu 2002, Teixeira *et al.* 2003, Grande *et al.* 2008).

## Conclusion

This study confirmed the anatomical complexity of the maxillary first molar mesiobuccal root canal system

and that the presently used morphology classifications do not fully reflect this complexity.

## References

- Balto K, Muller R, Carrington DC, Dobeck J, Stashenko P (2000) Quantification of periapical bone destruction in mice by micro-computed tomography. *Journal of Dental Research* **79**, 35–40.
- Bjørndal L, Carlsen O, Thuesen G, Darvann T, Kreiborg S (1999) External and internal macromorphology in 3D-reconstructed maxillary molars using computerized X-ray microtomography. *International Endodontic Journal* **32**, 3–9.
- Cleghorn BM, Christie WH, Dong CC (2006) Root and root canal morphology of the human permanent maxillary first molar: a literature review. *Journal of Endodontics* **32**, 813–21.
- Degerness R, Bowles W (2008) Anatomic determination of the mesiobuccal root resection level in maxillary molars. *Journal of Endodontics* **34**, 1182–6.
- Grande NM, Plotino G, Pecci R, Bedini R, Pameijer CH, Somma F (2008) Micro-computerized tomographic analysis of radicular and canal morphology of premolars with long oval canals. *Oral Surgery, Oral Medicine, Oral Pathology, Oral Radiology & Endodontics* **106**, e70–6.
- Gutierrez JH, Aguayo P (1995) Apical foraminal openings in human teeth. Number and location. *Oral Surgery, Oral Medicine, Oral Pathology, Oral Radiology & Endodontics* **79**, 769–77.
- Ichim I, Kuzmanovic DV, Love RM (2006) A finite element analysis of ferrule design on restoration resistance and distribution of stress within a root. *International Endodontic Journal* **39**, 443–52.
- Kulild JC, Peters DD (1990) Incidence and configuration of canal systems in the mesiobuccal root of maxillary first and second molars. *Journal of Endodontics* **16**, 311–7.
- Marroquin BB, El-Sayed MA, Willershausen-Zonnchen B (2004) Morphology of the physiological foramen: I. Maxillary and mandibular molars. *Journal of Endodontics* **30**, 321–8.
- Nielsen RB, Alyassin AM, Peters DD, Carnes DL, Lancaster J (1995) Microcomputed tomography: an advanced system for detailed endodontic research. *Journal of Endodontics* **21**, 561–8.
- Pecora JD, Woelfel JB, Sousa Neto MD, Issa EP (1992) Morphologic study of the maxillary molars. Part II: internal anatomy. *Brazilian Dental Journal* **3**, 53–7.
- Peters OA, Laib A, Rueggeger P, Barbakow F (2000) Three-dimensional analysis of root canal geometry by high-resolution computed tomography. *Journal of Dental Research* **79**, 1405–9.
- Tam A, Yu DC (2002) Location of canal isthmus and accessory canals in the mesiobuccal root of maxillary first permanent molars. *Journal of the Canadian Dental Association* **68**, 28–33.
- Teixeira FB, Sano CL, Gomes BP, Zaia AA, Ferraz CC, Souza-Filho FJ (2003) A preliminary *in vitro* study of the incidence

- and position of the root canal isthmus in maxillary and mandibular first molars. *International Endodontic Journal* **36**, 276–80.
- Verdonschot N, Fennis WM, Kuijts RH, Stolk J, Kreulen CM, Creugers NH (2001) Generation of 3-D finite element models of restored human teeth using micro-CT techniques. *International Journal of Prosthodontics* **14**, 310–5.
- Vertucci FJ (1974) The endodontic significance of the mesiobuccal root of the maxillary first molar. *US Navy Medicine* **63**, 29–31.
- Vertucci FJ (1984) Root canal anatomy of the human permanent teeth. *Oral Surg Oral Surgery, Oral Medicine, Oral Pathology* **58**, 589–99.
- Vertucci FJ (2005) Root canal morphology and its relationship to endodontic procedures. *Endodontic Topics* **10**, 3–29.
- Weine FS, Healey HJ, Gerstein H, Evanson L (1969) Canal configuration in the mesiobuccal root of the maxillary first molar and its endodontic significance. *Oral Surgery, Oral Medicine, Oral Pathology* **28**, 419–25.