

Radiographic manifestations of periapical inflammatory lesions

How new radiological techniques may improve endodontic diagnosis and treatment planning

HANS-GÖRAN GRÖNDAHL & SISKU HUUMONEN

Diagnosis, treatment planning, and treatment monitoring in endodontics depend to a very large extent on results from radiographic examinations. The often complex anatomy in respect to the teeth themselves as well as their surrounding structures may render those tasks difficult. New tomographic techniques hold promises for improvements in all those areas, in particular techniques that can display the object in all its three dimensions and remove disturbing anatomical structures to make it possible to evaluate each root and its closest surroundings in detail. They also provide images, taken at different points in time, that are similar in geometry and contrast making it possible to evaluate differences occurring in the fourth dimension – time. Image-processing techniques applied to digital images obtained with conventional periapical radiography can be of some help towards improved diagnosis provided that optimal irradiation geometry has been used during image acquisition. When conventional radiographs are used and conventional means employed for their evaluation, one should take radiographs from more than one direction to ensure that at least some three-dimensional information will be obtained. When evaluating images over time they must be compared side by side to provide best possibilities of subjectively detecting changes occurring over time.

The radiological examination is an integral and essential part of endodontic management, from the initial diagnostic work-up to the monitoring of treatment results. Unfortunately, it is not infallible because of many, quite different, reasons. We believe the most important is the limitations of conventional radiological examinations to fully describe the three-dimensional (3D) anatomy of the teeth and their surrounding structures. Those techniques make all structures in the anatomical 3D space become compressed into a two-dimensional image (Fig. 1). Therefore, not only do they display limited aspects of the anatomy, but because of the complexity of the anatomy itself and the characteristics of the central perspective irradiation geometry, geometric dimensions as seen in the radiographs can be very different from the actual ones. The so-called paralleling technique is usually, and rightfully, recommended over the bisecting-angle

technique to ensure not only more accurate diagnoses but also better possibilities for root-length measurements. However, for a multi-rooted tooth in which the roots diverge in the bucco-lingual no single radiograph allow all roots to be imaged according to the bisecting-angle rule. As a consequence, significant image distortions can result. Nevertheless, from images with all these inbuilt restrictions the observer must try to visually recreate the underlying three dimensions, a far from easy feat in many cases.

It is possible to overcome at least some of the limitations of conventional radiology by using at least two radiographs obtained from different, usually horizontal, directions. In our normal daily life, we would never be content with a single view if, for example, asked to describe a mug as that in Fig. 2. We would, probably without even thinking of it, look at it from different angles maybe by rotating it. It is,

therefore, always amazing to see how many dentists that are content with single radiographic views for describing the anatomy of teeth and surrounding bone and, based on that, make a diagnosis and a treatment plan.

An important principle in radiological imaging is to perform the examinations so that diagnostically necessary 3D information is obtained. As regards teeth it is usually meaningless to take radiographs in directions

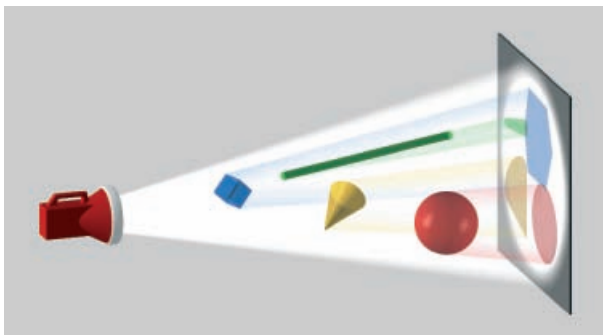


Fig. 1. In central perspective images, structures in the three-dimensional (3D) domain become compressed into a two-dimensional (2D) representation making the images of the structures become distorted and superimposed on each other. From the 2D image, observers must try to mentally recreate the 3D reality. Reproduced with permission from (1).



Fig. 2. To best describe a three-dimensional object one must look at it from different directions, sometimes many.

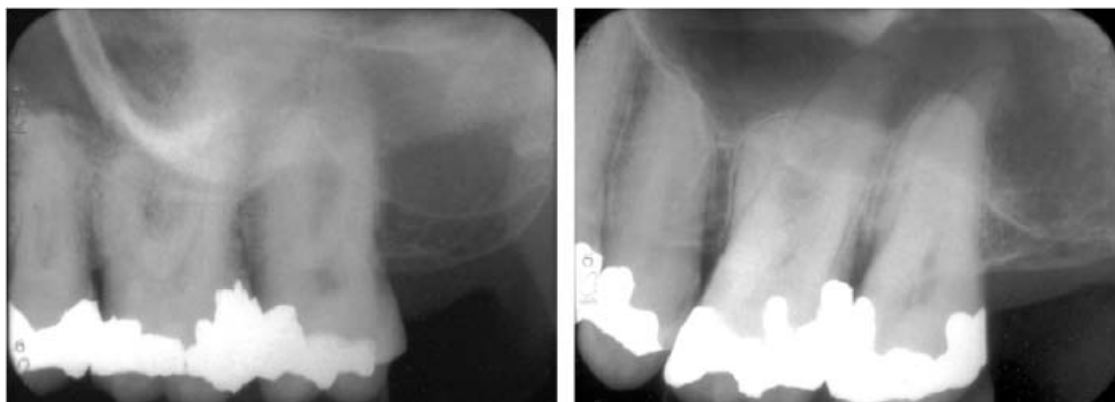

Fig. 3. In the left image, some roots and apices are obscured by anatomical noise (the zygomatic bone and arch). In the right image, as a result of better irradiation geometry (paralleling technique and orthoradial projection) the roots and apices are seen against a more homogeneous background (the maxillary sinus).

that are perpendicular to each other, a technique that for most medical applications is common. Instead we have to rely on radiographs taken with different angulations in the same plane. In some cases, as when clinical signs and symptoms strongly suggest a condition that ought to be radiologically evident but not seen in the radiographs already taken, one may have to take more radiographs from different perspectives. However, there is a limit to how much information that can be obtained by means of conventional radiographs regardless of how many.

Another important principle in radiology is that structures of diagnostic interest should be displayed onto as homogeneous a background as possible. However, teeth are surrounded by jawbone and other facial bones, some at a distance from the roots and apices of the teeth and therefore unlikely to contain information of endodontic, diagnostic interest, e.g. the bone in the chin and the zygomatic bone (Fig. 3). Not infrequently, however, these structures become superimposed onto the anatomic features of diagnostic interest, sometimes to the extent that the latter become concealed. Irrelevant information, in this case as a result of anatomical noise (anatomic structures concealing structures of interest) has thus been sampled during the radiological process. The most common reason is that non-optimal irradiation geometry has been used. In cases of multi-rooted teeth, especially when the roots are situated close to each other, it can be difficult or impossible to radiographically separate them from each other by means of conventional methods.

From the above, it is evident that conventional radiological examinations often suffer from limitations

as regards the 3D depiction of the examined region and in the possibilities of displaying the structures of interest against a homogeneous background, that is, one free from disturbing image features because of neighboring anatomical structures. Particularly when examining multi-rooted teeth multiple projections will increase the rate of detection of periapical lesions. This can be explained by the higher probability of less anatomical noise affecting the images of the different roots, an effect similar to that described for chest radiography (2). With multiple projections, stereoscopic viewing can be used. This has been described as improving the signal-to-noise ratio and resulting in better visualization of anatomical details (3).

Equally important as taking account of the three dimensions in the spatial domain, both when performing a radiological examination and, not least, when interpreting its information, is to take the fourth dimension – time – into consideration. This requires radiographs to be compared over some time interval to be as similar as possible in respect to geometry as well as density and contrast. Otherwise, the information gleaned from comparisons of serial radiographs might consist more of irrelevant information (noise) – that can be quite misleading – than actual subject-related temporal differences reflecting true biological change. Also, the density in a summation image resulting from conventional radiography is caused both by the lesion itself and the anatomical structures on either side in the direction of the X-rays. This means that lesions surrounded by thick or dense bone over time must increase or decrease more in size than a lesion surrounded by thinner or less dense bone to give rise to the same observable gray-level difference in the radiograph.

When Bender & Seltzer (4, 5), Schwartz & Foster (6) described the difficulties in detecting lesions in trabecular jaw bone that had not encroached upon the surrounding cortical bone, endodontists might have started to wonder about the value of radiography in endodontic diagnosis. However, it has been speculated that when lesions affected the lamina dura (as endodontic lesions do) the area of rarefaction becomes more apparent when the trabeculae are resorbed at the junction of cancellous and cortical bone. Also, most root apices are close to the cortical bone, which is therefore quickly affected by apical inflammatory lesions (5). However, for some teeth, particularly the lower premolars and molars, the apices sometimes are found between the buccal and lingual cortical bone

plates (Fig. 4). In those cases, the difficulties described can be real (Fig. 5) and a possibility of producing cross-sectional radiographic slices should be particularly valuable.

It should be needless to say that when radiographs have been taken at different points in time they must be carefully compared, but experience tells this is not always the case. It cannot be said too often that there is no better way to detect differences occurring over a time interval than to compare serially obtained radiographs placed side by side (Fig. 6).

Ideally, it should be possible radiologically to examine any dentate region of the jaws so that individual roots could be assessed without the disturbance caused by superimposed structures. Likewise, it should be possible to evaluate the bony areas surrounding each root

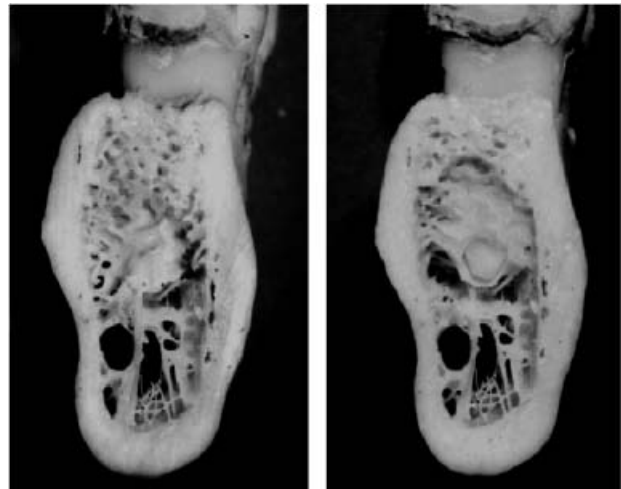


Fig. 4. Cross-sectional view of mandible before (left) and after removal of bone around the distal apex of the molar.

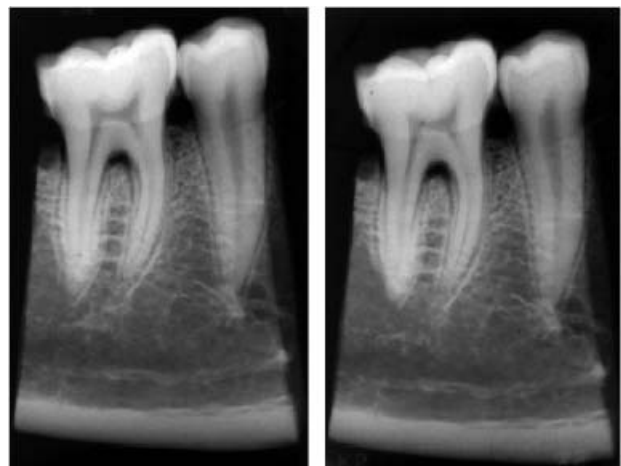


Fig. 5. Radiographs before and after bone was removed.

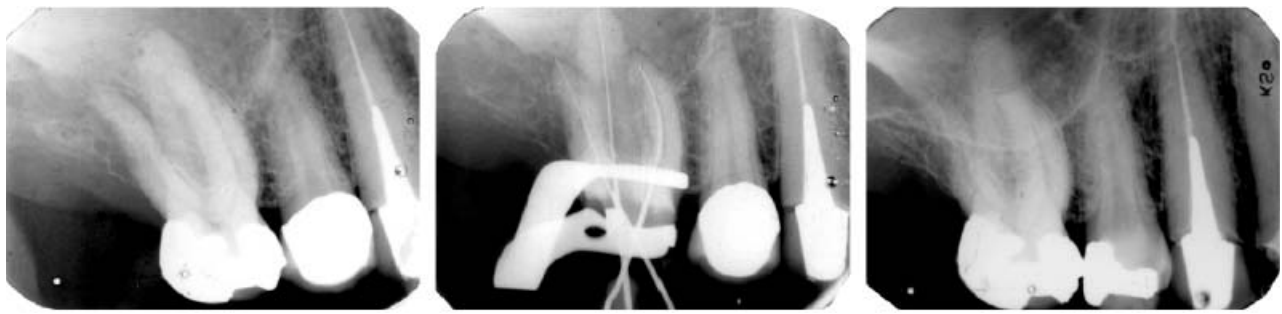


Fig. 6. In a patient presenting with pain in the upper right molar region a dentist believed he found the reason for it in a periapical lesion that he saw in the left one of these images and initiated endodontic treatment. A comparison with a previously taken radiograph (right image) might have made him perceive the absence of the lower border of the maxillary sinus and the presence of soft tissue within it indicating a different cause of the patient's problem than an inflammatory periapical lesion. Eventually it was found that the patient suffered from a malignant lymphoma.

and, in the presence of one or more periapical lesions, it should be possible to assess each separate lesion in respect to its borders and its relation to surrounding anatomical structures. It should be possible to make reliable (accurate and precise) measurements of any desired distance and to obtain accurate information from comparisons of images from different points in time.

Advances in computer science both as regards hardware (cheaper, faster and with more memory) and not least software (image-processing algorithms) have enabled a development of radiographic machinery moving us towards the ideal situation as far as radiological examinations of endodontic problems are concerned. In this chapter, we will describe some techniques that can be of value for the endodontist, in particular when the conventional intraoral radiological examination does not suffice in providing diagnostic information that can aid in the selection of a management that can best help both dentist and patient. The latter is the ultimate goal of any diagnostic procedure.

Radiographic examinations complementing intraoral radiography

In all types of radiological diagnosis, there is a need to see the borders of the lesion and at least some of its surroundings. When a lesion has reached a size that makes it impossible to capture by intraoral radiographs other means must be used. In the lower jaw, panoramic radiography can then be useful. This can also be used in the upper jaw but its more complex anatomy often

make other types of radiographs necessary such as those primarily aimed for examinations of the maxillary sinus (Fig. 7).

Conventional tomography

In conventional tomography, structures on either side of a selected object layer are blurred because of a synchronized motion of X-ray source and detector, so that structures inside the layer of interest appear sharply depicted. In the resulting tomograms, the blurred structures may be seen as homogeneous, low-contrast shadows or, if the blurring is sufficiently effective, not at all. The tomographic motion pattern and the amplitude of the motion affect the quality of the tomographic images. Spiral tomography, in which the X-ray tube and the detector move in a spiral pattern is an effective type of motion particularly well suited for the production of tomograms within anatomically complex regions such as the facial skeleton.

For radiography of the facial skeleton, so-called multi-modality units have been developed that permit different imaging modes and principles to be used. They include a spiral tomographic imaging mode with which e.g. dento-alveolar structures can be visualized free from disturbing, surrounding structures (Fig. 8). It has been demonstrated that the visualization of periapical bone lesions, particularly in the premolar and molar regions, is better than that achieved with intraoral periapical radiography (7). Not surprisingly, differences between those techniques were smaller for lesions in the anterior jaw regions.

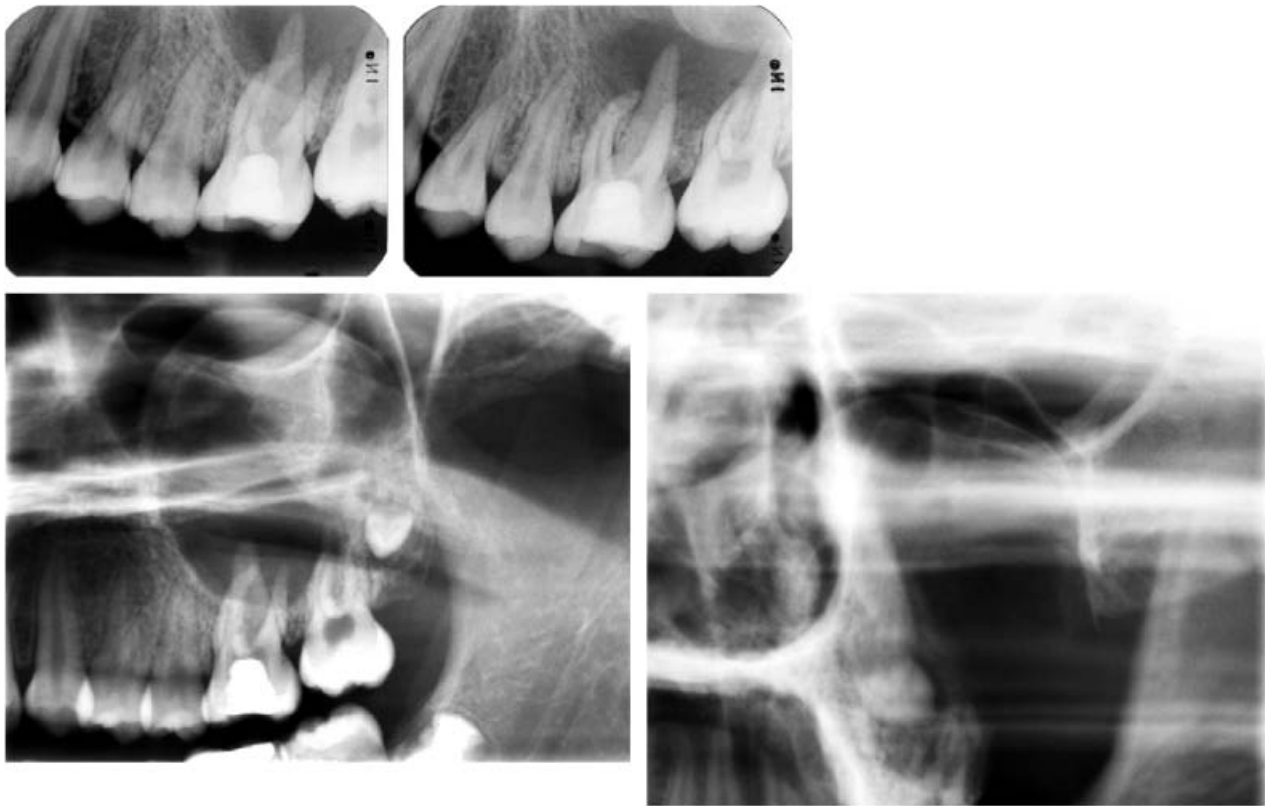

Fig. 7. In this 12-year-old girl presenting with pain in the upper left molar region intraoral radiographs did not describe a suspected lesion in its entirety. The absence of a clear anterior and lower border of the maxillary sinus and the homogeneous density of the region of the sinus indicate the presence of an extensive lesion. A lateral sinus scanogram (left lower radiograph) and an anterior sinus scanogram (lower right radiograph) demonstrate the presence of a large cystic lesion that, as a result of being infected, had a lower lateral border that had become resorbed. Lower two radiographs were obtained with a Scanora multimodality unit (Soredex Co., Helsinki, Finland).

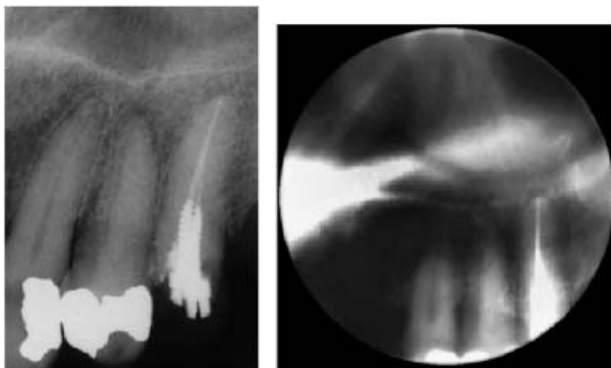


Fig. 8. Cropped intraoral radiograph (left) of a premolar tooth, and a spiral tomogram (right) that better visualizes the lesion at its apex. Courtesy of Tapio Tammissalo.

Computed tomography

Computed tomography (CT) has several advantages over conventional tomography in that it effectively eliminates the superimposition of images of structures on either side of the area of interest. When examining

jaws, axial sectioning is usually carried out to avoid artifacts caused by posts, crowns, and metal fillings and because it provides the best patient comfort. Data from a single CT examination consisting of multiple, contiguous scans can be reconstructed and viewed as images in the coronal, sagittal or cross-sectional planes, depending on the diagnostic task.

The axial views provide possibilities for the interpretation of bucco-palatal details of the anatomy and pathology (Figs 9 and 10). It can be used to measure distances in the bucco-lingual direction, e.g. between the mandibular canal and a periapical lesion, or the thickness of the buccal cortex to reveal information that can be of value before periapical surgery. CT can even show the morphology of the root canal system provided it does not contain metallic root canal posts. However, the geometric resolution of CT is insufficient to reveal the exact shape of the root canals (8).

Cotti & co-workers (9) followed an extensive periapical lesion. They found that CT was superior to

panoramic radiography in obtaining detailed information of the size of the lesion and its spatial relationship to anatomical landmarks. Also, the healing was better visualized in CT than in panoramic radiographs. It can be remarked that panoramic radiography, for several reasons, is not the method of choice for the study of periapical lesions (10, 11). Velvart & co-workers (12) noted that the relation between periapical lesions and the mandibular canal, as studied before endodontic surgery, could be reliably assessed by means of CT.

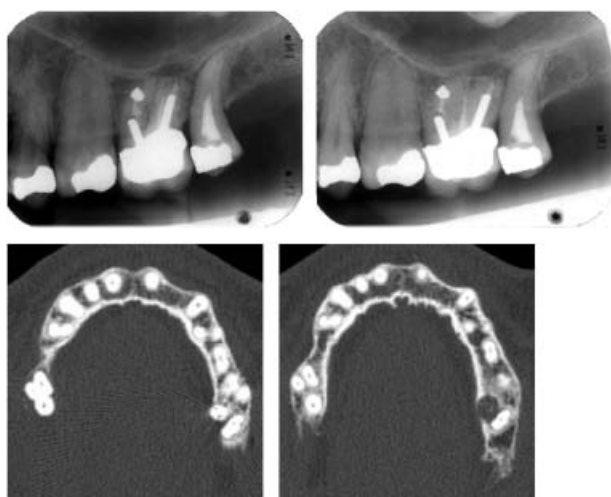


Fig. 9. Intraoral radiographs of the upper left first molar and two cropped computed-tomography images showing more detailed information about the condition of the tooth, e.g. the large lesion at the palatal root.

High-resolution limited cone beam CT

A high-resolution limited cone beam CT has been developed specifically for dental applications (13–15). By means of a cone-shaped X-ray beam that travels 360° around the patient with the motion center placed in the area of interest and the X-ray detector on the opposite side of the circle, radiographic data are sampled and transferred to a computer. After a short reconstruction time (85 s) the information is displayed on the monitor as contiguous tomographic layers in all three planes. Thus, one can examine a tooth in axial, frontal and sagittal layers. Those layers actually emanate from a cylindrical volume with a height of 30 mm and diameter of 40 mm and can be placed in any desired direction. Different thicknesses (0.125–2.0 mm) as well as different distances between the layers can also be chosen depending on the diagnostic task. Normally we use 1 mm thick slices and 1 mm intervals.

It may take some training to understand these images mostly because they represent thin layers of what has been imaged rather than a summation of all structures between X-ray focus and film that we are more familiar with.

The development of the limited cone-beam CT no doubt is a significant step towards improved pre- and postoperative diagnosis in the endodontic and many other dental fields as a complement or even replacement to conventional radiography (Figs 11 and 12). Each root and its surroundings can be evaluated and very accurate measurements taken with the inbuilt

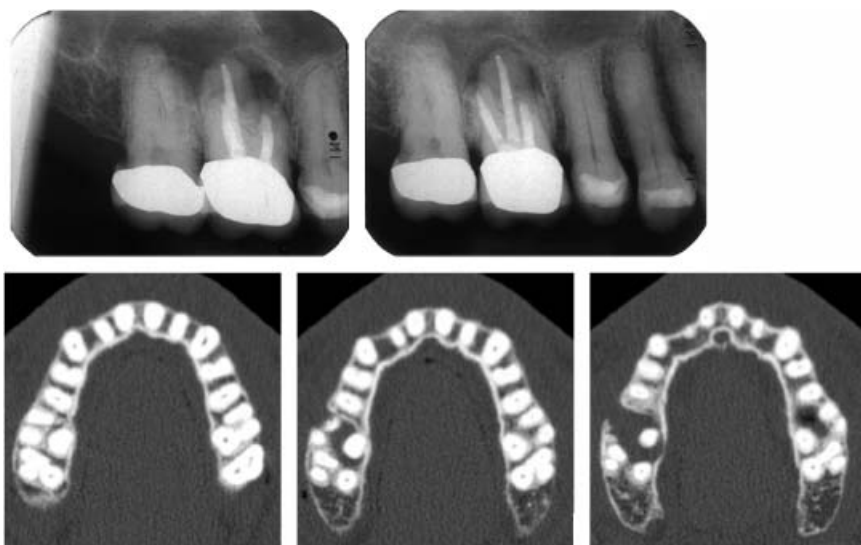


Fig. 10. Some of the axial slices obtained at computed tomography, using a low-dose technique, to evaluate the conditions around the apices of the upper right first molar, before endodontic surgery. Not only can lesions now be clearly seen at all root apices. The relation between the roots and the location of their apices relative to the buccal and palatal bone plates can be accurately assessed.

measurement tool. Regions, or teeth, to be compared over time need not be radiographed in exactly the same way, as the case is in conventional radiography. Similarity between images can namely be achieved *post hoc* both in terms of geometry and contrast. The elimination of overlying structures will therefore

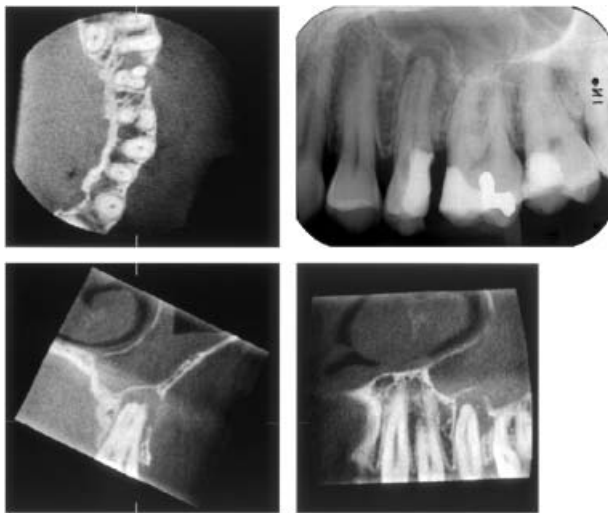


Fig. 11. In this patient, the upper left second premolar showed a large periapical lesion with a breakdown of part of its buccal border and of that expanding into the maxillary sinus in which there is an extensive soft-tissue reaction. Note also, in the axial view, that the tooth had no less than three roots. In the periapical radiograph, little of all this information was obtained.

significantly increase the possibilities of reliably monitoring treatment effects.

It does happen that fractures occur in roots with root-canal posts. In many cases it is only the development, at the root surface at a level of the tip of the post, of an inflammatory lesion with or without communication to the marginal bone crest that indirectly signals the presence of a fracture. The fracture itself is often not seen until a dislocation of a fracture fragment has occurred and sometimes the inflammatory lesion is situated in a position that makes its detection in ordinary intraoral radiographs difficult or even impossible. In such cases the limited cone-beam CT might be helpful (Fig. 13).

In cone beam CT, artifacts from metallic objects and, to some extent, root canal fillings can be quite disturbing. For that reason, internal root resorption and root canal perforations cannot always be diagnosed. Therefore, a combination of periapical radiography and cone beam CT occasionally might be necessary.

The cone beam CT technology is also used in X-ray machines that acquire data from a large volume (16). Such a technique has been used for the planning of minimal invasive endodontic surgery via the vestibular approach (17). Information derived from cone beam CT was considered essential in the surgical procedure and particularly useful for selecting direction of the surgical approach and length of instruments. It was

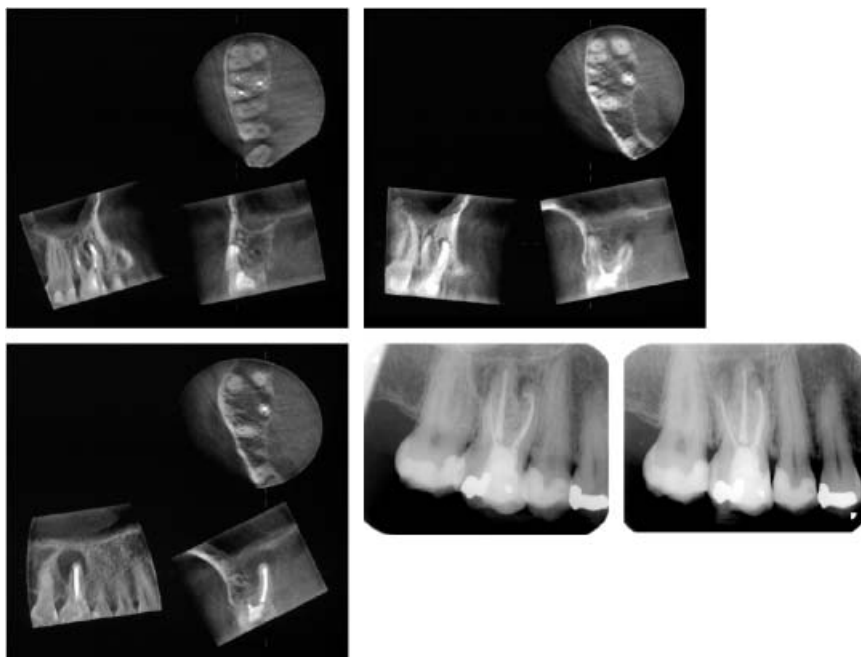


Fig. 12. Compared with periapical radiographs, limited cone beam computed radiography displays the roots and their closest surroundings without overlying structures and without distortions. Measurements can be accurately made.

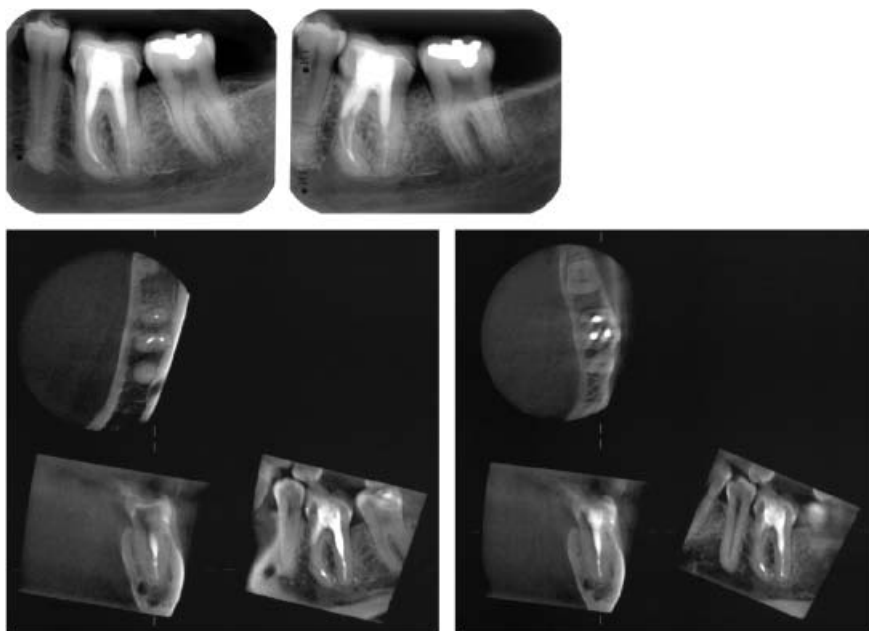


Fig. 13. Periapical radiographs show little more than a diffuse periodontal ligament space at the upper distal surface of the first molar. Limited cone beam computed tomography slices reveal an oblique root fracture in the distal root with associated inflammatory reaction, a post in the mesio-buccal root adjacent to its surface, and root-canal filling material deposited in the upper part of the mandibular canal. The fracture was confirmed at surgery.

found useful when determining whether the maxillary sinus was interposed between the roots of the first molar and if pathological conditions were present within the sinus.

Cone beam CT, especially the limited cone beam technique, yields lower doses than does CT (18). However, the doses from CT can be effectively reduced by strict limitation of the volume being examined and lowering of the mAs value (19). The technique can then be used when the probability is high that clinically indispensable information can be derived. The limited cone beam technique yields radiation doses similar to that from two to three intraoral radiographs (18) and thus not more than what may be the case from a normal intraoral radiographic examination. The difference in information is, however, usually considerably larger.

Tuned-aperture CT

Tuned-aperture CT (TACT) is a technique that creates 3D information from a series of conventional central perspective projections, such as periapical radiographs, by using special software to reconstruct a 3D volume (20). This can be examined in an interactive mode through sequential viewing of slices through the volume in thicknesses freely chosen postexposure. There are no constraints regarding the position of the X-ray source. TACT has been shown to be an effective diagnostic tool in a variety of clinical conditions (for review see Nair (21)). In respect to endodontic

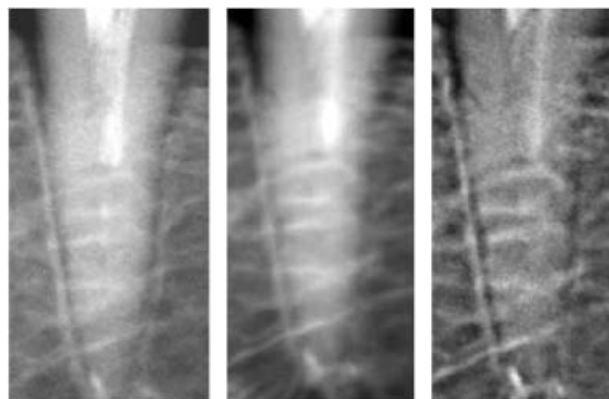


Fig. 14. An oblique root fracture 2–3 mm below the marginal bone crest (left tooth surface) in a regular two-dimensional image (left) and in two versions of tuned-aperture computed tomography images (middle and right images). Courtesy of Dr Madhu Nair.

problems, it has been demonstrated that vertical root fractures even without displacements can be diagnosed with a very high accuracy, well above what can be achieved by conventional radiography (Fig. 14) (22). However, TACT is not, at least yet, commercially available for dental applications.

Digital image capture and processing in intraoral radiography

Digital imaging is an emerging area in diagnostic radiology that, potentially, may be of benefit in endodontic practise. Digital systems give the clinician

the ability to rapidly acquire and then manipulate images so that they become best suited for the diagnostic task. Different technologies are used to capture the radiographic information: charge-coupled devices (CCDs), complementary metal-oxide semiconductors (CMOSs), and photostimulable phosphor plates (PSPs).

Comparable diagnostic performance of PSP, CCD, CMOS, and film-based radiography has been noted for various endodontic purposes (23–27), especially when examinations have been made in the laboratory where all conditions can be carefully controlled and no anatomical and other patient-dependent constraints exist. From studies on images taken in the clinic it has become evident that problems may arise mainly because of two reasons: difficulties in placing the detectors correctly in the mouth and the limited dynamic range of CCD and CMOS sensors that results in a narrow exposure window. This means that exposures can easily become too low or too high for the entire object area or that it becomes too high or too low in parts where the mass within the object is considerably different from that of their surroundings. PSP systems have a much wider dynamic range than both CCD and CMOS systems (28), and as they are as thin as film they are easier to position in the mouth so that the irradiation geometry, the most important parameter in diagnostic image quality, can become on a par with that achieved when film is used (29).

The spatial image resolution of digital images varies considerably between detectors. Much emphasis has been put on this although the maximum spatial resolution not only is determined by the spatial density of the pixels in the detector, but is also a function of many other parameters (30) not least the monitor on which the radiographs are viewed. As X-rays can only detect differences in an object that are caused by its inherent mass differences it might be worthwhile to focus more on the contrast resolution of the systems. If mass differences cannot be detected the spatial resolution has no role whatsoever to play.

An important part of digital imaging lies in the possibilities to manipulate the images so that their properties become optimized for the diagnostic problem to be solved. In contrast to film radiographs, digital images are dynamic in the sense that they can be changed through different types of image processing. This is achieved by mathematical algorithms that enhance image information of interest to make it more

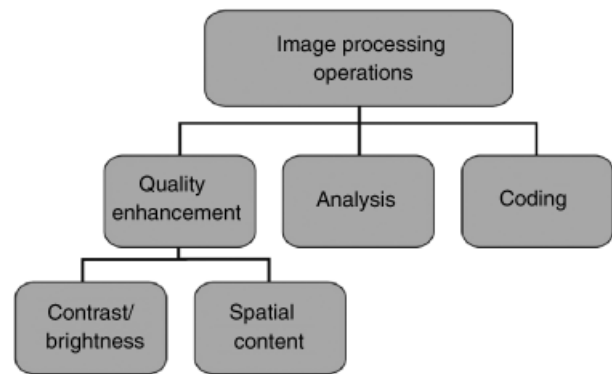


Fig. 15. Image-processing operations can be used to enhance the diagnostic quality of the radiographs, numerically analyze certain aspects of the image, and to code the image into a different form. The latter includes operations aiming at decreasing image size (image compression) making image archiving less space demanding and communication quicker.

readily perceived. No new information is added. Instead, some is usually suppressed. Knowledge in image processing and what it entails is no doubt of value for the user of digital radiographic systems. This is not the place to supply such knowledge and only a few remarks will be made about digital image processing (Fig. 15). For more information, the reader is referred to some excellent papers on the subject by Analoui (31, 32).

All the CT techniques mentioned earlier rely to a very large extent on advanced image processing and, undoubtedly, image processing will play an increasingly important role as the development of digital systems continues. In the dental office less advanced image processing methods are available as integral parts of the digital radiography systems. We will just mention the possibilities of changing image brightness and contrast that can be quite helpful diagnostically. Image brightness variations are not perceived linearly by the human eye–brain system but logarithmically (Fig. 16). Therefore, the same physical brightness difference e.g. between a pathological lesion and its background, is easier perceived against a darker background than against a light one (Fig. 17). This means that the perceived contrast increases just by decreasing the brightness of an image (Fig. 18). The possibilities to vary the brightness of an image is therefore often of great diagnostic value (Figs 19 and 20).

Contrast between a lesion and its surroundings also depends on the irradiation geometry, simply because a lesion imaged over less amount of surrounding tissue makes up more of the image information content. It is

always best to have as good images as possible in the front end of the diagnostic process, another reason why it is usually better to view the object from different angulations to start with (Fig. 20).

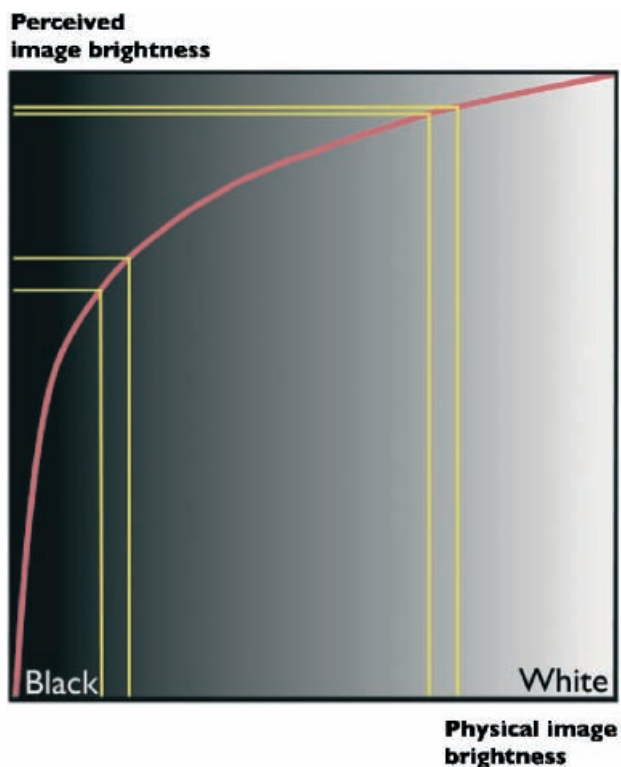


Fig. 16. The human eye's response to brightness differences is logarithmic. Therefore, the same physical brightness difference is differently perceived if it occurs against a light background than a dark one. A lesion can therefore be easier to detect when a radiograph is made darker.

Color coding has been proposed as a mean of detecting differences between sequential images by means of image addition to detect bone changes (33). Assigning a color to a range of gray creates colorized images, but the process discards information (Fig. 21). Color coding can be used to help to find possible lesions; in diagnosis, however, a gray-scale image was preferable (34).

Densitometric image analysis and subtraction have been applied to enhance the detection of small osseous changes over time. The purpose of subtraction is to eliminate all unchanged structures from a pair of radiographs, displaying only the area of change standing out against a neutral gray background. The technique requires a high degree of similarity both in irradiation geometry and contrast that can be difficult to achieve during clinical conditions. Image-processing techniques have been developed that can correct for errors due to projection differences that occur when the sensor translates or rotates relative to the object or when the object rotates around its z-axis relative to the X-ray source (35–37). Errors caused by vertical or horizontal rotation of the object relative to the source cannot be corrected for. Several methods for contrast correction have been proposed in the past (38). Follow-up studies of the healing of periapical lesions after endodontic treatment have shown that subtraction may be a useful tool to evaluate the healing process. Significantly better agreement between observers have been demonstrated when subtraction images are used than when conventional are employed for this type of evaluation (39, 40).

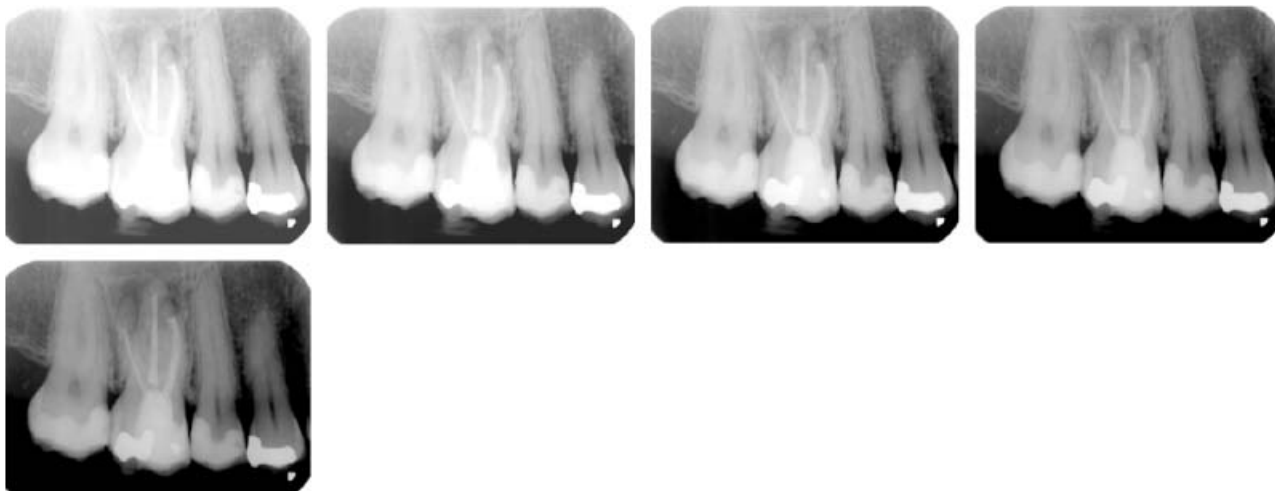


Fig. 17. As this radiograph gradually gets darker, the lesions at the apices of the first molar become more visible.

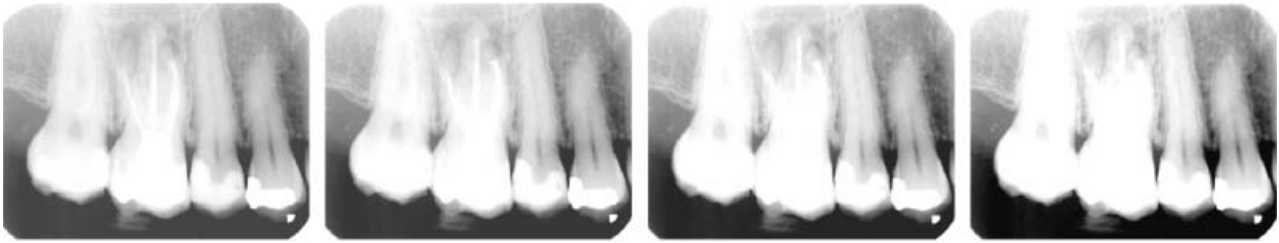

Fig. 18. Increasing contrast only in a radiograph that is too light to start with usually does not improve its diagnostic value.

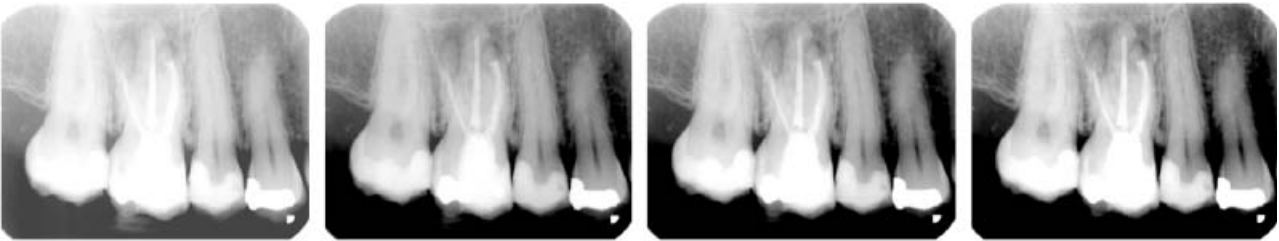


Fig. 19. By first decreasing image brightness slightly and then carefully increasing contrast, an image of better diagnostic value can be achieved.

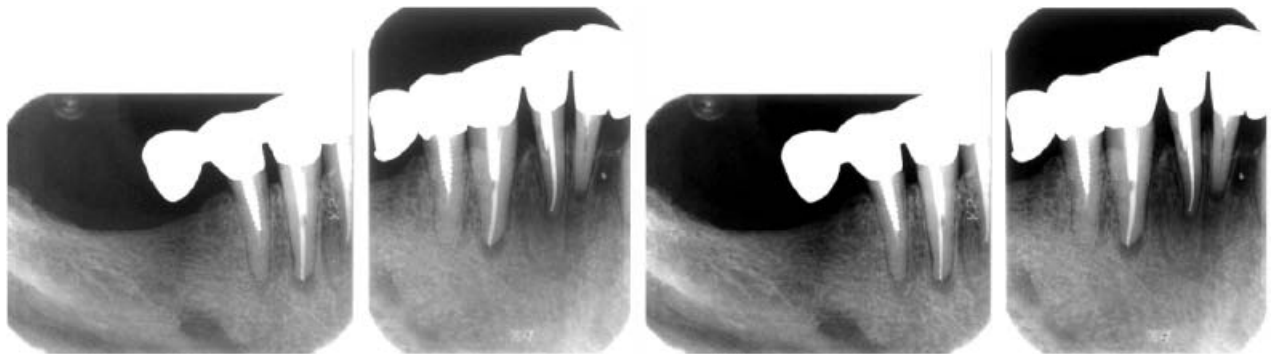


Fig. 20. In the premolar image, a lesion at the apex of the premolar can be seen that is not visible in the image of the cuspid area because of the different irradiation geometry. Lower image brightness and higher contrast (right image pair) does little or nothing to improve lesion visibility when the primary conditions are suboptimal.

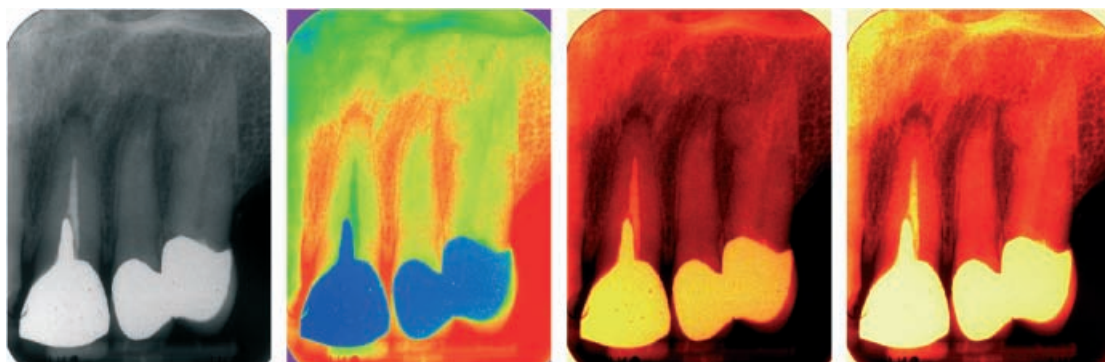


Fig. 21. Color coding of radiographs presents the information in a different way that is not always logical as the gray-scale image is (properly exposed and processed). A color algorithm, sometimes called Fire (the two images to the right) provides colors going from black, through red and yellow to white, as if a piece of iron was heated so that its temperature gradually rose. This is a logic resembling that of the gray-scale image.

In densitometric image analysis, the numeric density values between two images are analyzed to quantify osseous changes in areas of interest. By relating the density of the lesion area to a peripheral, normal bone area a density ratio measure is obtained that may be monitored over time as a marker for development or healing of apical periodontitis (41). In principle, this allows some differences in irradiation geometry and density between the images. Densitometric analysis with digital subtraction has been compared with histological evaluation of healing of apical periodontitis at 6 months after apicoectomy in dogs (42). The average gray value of the surgical area on the subtraction images was significantly correlated with the histological evaluation of healing.

References

1. Gröndahl H-G, Ekstubby A, Gröndahl K. *Cranex Tome & Digora PCT*. Newprint Oy: Soredex Instrumentarium Corp., 2003.
2. Revesz G, Kundel HL, Graper MA. The influence of structured noise on the detection of radiologic abnormalities. *Invest Radiol* 1974; **9**: 479–486.
3. Tenner R, Dietz K. Erste erfahrungen mit einem neuen Stereoröntgenverfahren in der allgemeinen radiologie. *Radiologe* 1985; **25**: 241–246.
4. Bender IB, Seltzer S. Roentgenographic and direct observation of experimental lesions in bone. *J Am Dent Assoc* 1961; **62**: 152–160.
5. Bender IB, Seltzer S. Roentgenographic and direct observation of experimental lesions in bone: II. *J Am Dent Assoc* 1961; **62**: 708–716.
6. Schwartz SF, Foster JK. Roentgenographic interpretation of experimentally produced bone lesions. *Br J Oral Surg* 1971; **32**: 606–612.
7. Tammisalo T, Luostarinen T, Rosberg J, Väh K, Tammisalo EH. A comparison of detailed zonography with periapical radiography for the detection of periapical lesions. *Dentomaxillofac Radiol* 1995; **24**: 114–120.
8. Robinson S, Czerny C, Gahleitner A, Bernhart T, Kainberger FM. Dental CT evaluation of mandibular first premolar root configuration and canal variations. *Oral Surg Oral Med Oral Pathol Oral Radiol Endod* 2002; **93**: 328–332.
9. Cotti E, Vargui P, Dettori C, Mallarini G. Computerized tomography in the management and follow-up of extensive periapical lesion. *Endod Dent Traumatol* 1999; **15**: 186–189.
10. Gröndahl H-G, Jönsson E, Lindahl B. Diagnosis of periapical osteolytic processes with orthopantomography and intraoral full mouth radiography – a comparison. *Sven Tandlak Tidsskr* 1970; **63**: 679–686.
11. Molander B, Ahlqvist M, Gröndahl HG, Hollender L. Comparison of panoramic and intraoral radiography for the diagnosis of caries and periapical pathology. *Dentomaxillofac Radiol* 1993; **22**: 28–32.
12. Velvart P, Hecker H, Tillinger G. Detection of the apical lesion and the mandibular canal in conventional radiography and computed tomography. *Oral Surg Oral Med Oral Pathol Oral Radiol Endod* 2001; **92**: 682–688.
13. Arai Y, Tammisalo E, Iwai K, Hashimoto K, Shinoda K. Development of a compact computed tomographic apparatus for dental use. *Dentomaxillofac Radiol* 1999; **28**: 245–248.
14. Kobayashi K, Shimoda S, Nakagawa Y, Yamamoto A. Accuracy in measurement of distance using limited cone-beam computerized tomography. *Int J Oral Maxillofac Impl* 2004; **19**: 228–231.
15. Sato S, Arai Y, Shinoda K, Ito K. Clinical application of a new cone-beam computerized tomography system to assess multiple two-dimensional images for the pre-operative treatment planning of maxillary implants: case reports. *Quintessence Int* 2004; **35**: 525–528.
16. Ziegler CM, Woertche R, Brief J, Hassfeld S. Clinical indications for digital volume tomography in oral and maxillofacial surgery. *Dentomaxillofac Radiol* 2002; **31**: 126–130.
17. Rigolone M, Pasqualini D, Bianchi L, Berutti W, Bianchi SD. Vestibular surgical access to the palatine root of the superior first molar: ‘low-dose cone beam’ CT analysis of the pathway and its anatomic variations. *J Endod* 2003; **29**: 773–775.
18. Hashimoto K, Arai Y, Iwai K, Araki M, Kawashima S, Terakado M. A comparison of a new limited cone beam computed tomography machine for dental use with a multidetector row helical CT machine. *Oral Surg Oral Med Oral Pathol Oral Radiol Endod* 2003; **95**: 371–377.
19. Ekstubby A. Conventional spiral and low-dose computed mandibular tomography for dental implant planning. *Swed Dent J* 1999; **138**(Suppl): 1–82.
20. Webber RL, Horton RA, Tyndall DA, Ludlow JB. Tuned-aperture computed tomography (TACT). Theory and application for three-dimensional dento-alveolar imaging. *Dentomaxillofac Radiol* 1997; **26**: 53–62.
21. Nair M. Diagnostic accuracy of tuned aperture computed tomography (TACT). *Swed Dent J* 2003; **159**(Suppl): 1–93.
22. Nair MK, Nair UP, Gröndahl H-G, Webber RL, Wallace JA. Detection of artificially induced vertical radicular fractures using Tuned Aperture Computed Tomography. *Eur J Oral Sci* 2001; **109**: 375–379.
23. Borg E, K A, Gröndahl K, Gröndahl H-G. Film and digital radiography for detection of simulated root resorption cavities. *Oral Surg Oral Med Oral Pathol Oral Radiol Endod* 1998; **86**: 110–114.
24. Borg E, Gröndahl H-G. Endodontic measurements in digital radiographs acquired by a photostimulable, storage phosphor system. *Endod Dent Traumatol* 1996; **12**: 20–24.

25. Paurazas SB, Geist JR, Pink FE, Steiman HR. Comparison of diagnostic accuracy of digital imaging by using CCD, CMOS-APS sensors with E-speed film in the detection of periapical bony lesions. *Oral Surg Oral Med Oral Pathol Radiol Endod* 2000; **89**: 356–362.
26. Kullendorff B, Nilsson M, Rohlin M. Diagnostic accuracy of direct digital dental radiography for the detection of periapical bone lesions: overall comparison between conventional and direct digital radiography. *Oral Surg Oral Med Oral Pathol Radiol Endod* 1996; **82**: 344–350.
27. Wallace J, Nair M, Colaco M, Kapa S. A comparative evaluation of the diagnostic efficacy of film and digital sensors for detection of simulated periapical lesions. *Oral Surg Oral Med Oral Pathol Radiol Endod* 2001; **92**: 93–97.
28. Attaelmanan AG, Borg E, Gröndahl HG. Signal-to-noise ratios of 6 intraoral digital sensors. *Oral Surg Oral Med Oral Pathol Radiol Endod* 2001; **91**: 611–615.
29. Brettle DS, Workman A, Ellwood RP, Launders JH, Horner K, Davies RM. The imaging performance of a storage phosphor system for dental radiography. *Br J Radiol* 199; **69**: 256–261.
30. Lehmann TM, Troeltsch E, Spitzer K. Image processing and enhancement provided by commercial dental software programs. *Dentomaxillofac Radiol* 2002; **31**: 264–272.
31. Analoui M. Radiographic image enhancement. Part I: spatial domain techniques. *Dentomaxillofac Radiol* 2001; **30**: 1–9 (Review).
32. Analoui M. Radiographic digital image enhancement. Part II: transform domain techniques. *Dentomaxillofac Radiol* 2001; **30**: 65–77 (Review).
33. Shi XQ, Eklund I, Tronje G, Welander U, Stamatakis HC, Engström PE, Engström GN. Comparison of observer reliability in assessing alveolar bone changes from color-coded with subtraction radiographs. *Dentomaxillofac Radiol* 1999; **28**: 31–36.
34. Scarfe WC, Czerniejewski VJ, Farman AG, Avant SL, Molteni R. *In vivo* accuracy and reliability of color-coded image enhancements for the assessment of periradicular lesion dimensions. *Oral Surg Oral Med Oral Pathol Radiol Endod* 1999; **88**: 603–611.
35. Ettinger GJ, Gordon GG, Goodson JM, Socransky SS, Williams R. Development of automated registration algorithms for subtraction radiography. *J Clin Periodontol* 1994; **21**: 540–543.
36. Yoon DC. A new method for automated alignment of dental radiographs for digital subtraction radiography. *Dentomaxillofac Radiol* 2000; **29**: 11–19.
37. Zacharaki EI, Matsopoulos GK, Asvestas PA, Nikita KS, Gröndahl K, Gröndahl H-G. A digital subtraction radiography scheme based on automatic multiresolution registration. *Dentomaxillofac Radiol* 2004; **33**: 1–14.
38. Ruttimann UE, Webber RL, Schmidt E. A robust digital method of film contrast correction in subtraction radiography. *J Periodontol Res* 1986; **21**: 486–495.
39. Yoshioka T, Kobayashi C, Suda H, Sasaki T. An observation of the healing process of periapical lesions by digital subtraction radiography. *J Endod* 2002; **28**: 589–591.
40. Nicopoulou-Karayianni K, Brägger U, Patrikiou A, Stassinakis A, Lang NP. Image processing for enhanced observer agreement in the evaluation of periapical bone changes. *Int Endod J* 2002; **35**: 615–622.
41. Ørstavik D, Farrants G, Wahl T, Kerekes K. Image analysis of endodontic radiographs: digital subtraction and quantitative densitometry. *Endod Dent Traumatol* 1990; **6**: 6–11.
42. Delano EO, Tyndall D, Ludlow JB, Trope M, Lost C. Quantitative radiographic follow-up of apical surgery: a radiometric and histologic correlation. *J Endod* 1998; **24**: 420–426.