

The Warning Signs of Pulpal Insult

A New Diagnostic Perspective on Pulpal Insults and Early Warning Signs of Pathology

As patients gain a better understanding of rejuvenative and reconstructive dentistry, our diagnostic skill set will need to expand to anticipate unexpected problems.

Conceptually, there is little difference between appreciating that a poor diet and lack of exercise causes atherosclerotic problems and the fact that restorative insult and resultant degenerative pulpal pathosis can exist in the absence of symptoms. The description “stressed pulp” carries with it a biologic understanding of the daily insults and iatrogenic vectors visited upon our dentition throughout a lifetime.

We examine our adolescent patients, find tooth decay, drill it out, scrape the dentine to remove all carious tooth structure, place a base, acid etch the enamel, the dentine, expose the dentinal tubuli, place a primer, thoroughly air dry the preparation, place an unfilled resin adhesive, condense the final material into the preparation, then heat it up adjusting the occlusion and contouring it, then again polishing it to luster. The patient then goes through 600,000 chewing cycles, pounding away all night, bruxing and clenching, then we do it all again, eight to ten years later.

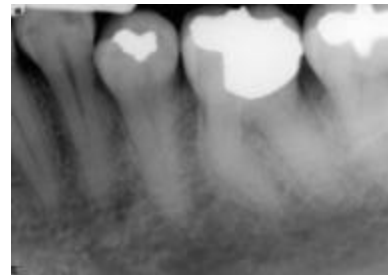
At age 35, we drill out the old filling material, for the second time, heat up the pulp once again, scrape the decay, place another restoration, shave all the enamel off with a rough diamond bur spinning at 500,000 rpm, create a significant amount of heat within the pulp, place an acrylic transitional, allow it to get hot, take it on and off the tooth 8 or 10 times, then exert significant pressures seating the restoration and finally insulting the pulp with an irritating luting material. It’s not altogether a pretty picture.

It was Abou-Rass who defined the stressed pulp as one that over the years has been compromised by caries and periodontitis, trauma – impact, occlusal and iatral, and he

euphemistically stated that, “after the 20 insults of crown preparation, there has to be an element of suspicion about the viability of the pulp. We must comb bite wings for signs of pathology, not just decay, recurrent or virgin and then pursue an evaluation of pulpal health”.

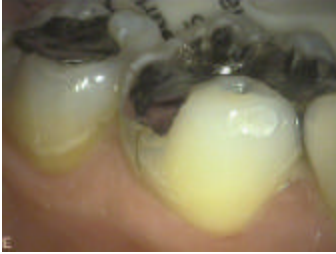The following warning signs of pulpal insult offer a new diagnostic paradigm:

Deep restorations: The placement of gold, alloy, porcelain and resin restorations near the pulp precipitate irreversible inflammatory changes. It is relatively simple to unknowingly nick a pulp horn in a deep preparation and unless there is hemorrhage, it may never be realized. It is the bitewing radiography that reveals this potential pathologic vector most dramatically.



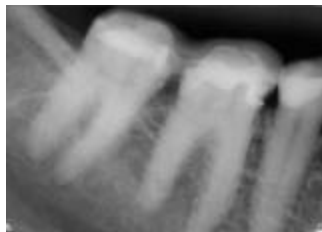Pulp test, not crown prep; historical impact on pulp must be factored into the equation

Large/Multiple Restorations: The larger the restoration, the greater the ratio of filling material to tooth, the greater the number of dentinal tubuli cut and the greater the number of odontoblastic processes exposed and available for contamination. An adult pulp or one induced to age by large/multiple restorations lacks the resistance of “younger” tissue. As the reparative potential of pulp in a previously filled tooth is dramatically reduced, care must be exercised in crown preparation.

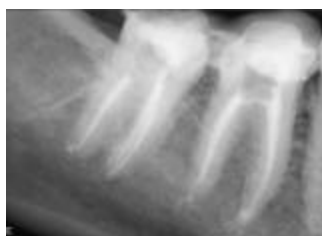

Over-restored tooth
- pulpal viability?
Fractures are
occlusally induced

Crowns, Inlays and Onlays: The first question to be asked in regard to assessing pulpal status is why are you crowning the tooth in the first place. Usually, the tooth has a failing restoration greater in size than two-thirds the intercusp distance or perhaps a fractured cusp. The tooth probably has a deep base and has been restored once or twice in the past. It is not an infrequent occurrence to prepare a tooth, have the patient indicate thermal sensitivity for a period of 7 to 10 days only to have it disappear. Sadly, this does not reflect health. Endodontic involvement increases in proportion to the degree of dental destruction and the complexity of the restoration.



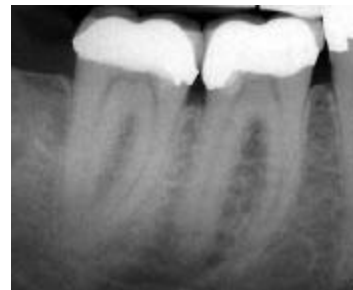50% of crowns
within 7 to 12
years will have
necrotic pulps



Teeth treated with a buildup and full veneer become necrotic roughly 3 x more frequently than those treated with a partial coverage crown. Cohen and Burns in Pathways of the Pulp indicate that research has shown that a higher incidence of pulpal necrosis is associated with full crown preparation (13.3%) as compared to partial veneer restorations (5.1%). The placement of foundations for full crown restorations

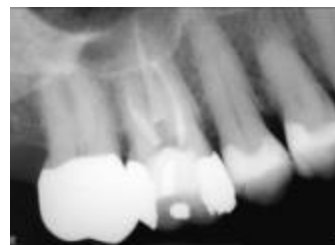showed a 17.7% incidence of pulpal morbidity. They further reported that pulpal insult can continue undetected for many years. Among restored teeth that became endodontically involved for no know reason only 12% deteriorated in the first three years after restorative treatment. That necrosis rate increased to 38% in years 3 to 7 and 50% by years 7 to 12.

Deep Bases: Bases rather than protecting the pulp are irritants designed to stimulate secondary reparative dentine formation. They cause atrophy, pulpitis and premature aging of the pulp. The combined insult of chasing deep decay toward the pulp, the iatrogenic trauma of scraping the dentinal walls with decay and the irritative properties of the base itself as well as the pulpal inflammation that ensues that causes irreversible pulpal changes and inflammatory reactions leading to pulpal necrosis.



Pulp cap
Direct or indirect
Deep Base
Rx for trouble

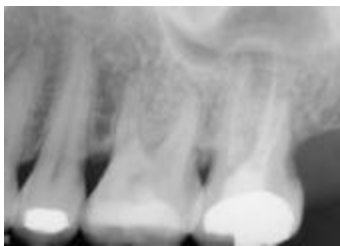Canal Constriction: This reflects increased fibrosis in the root canal space and loss of pulpal volume. The pulp is being strangled as secondary reparative dentine deposits and infarction ensues.



Atrophied canals found in 1.6, exist in 1.7. As canals calcify coronal apically, access and magnification are key.

Chamber Constriction: Irritation from trauma, bruxism, deep bases and restorations induce inflammatory responses resulting in chamber constriction. The odontoid layer of the pulp deposits secondary reparative dentine precipitating the shrinkage of

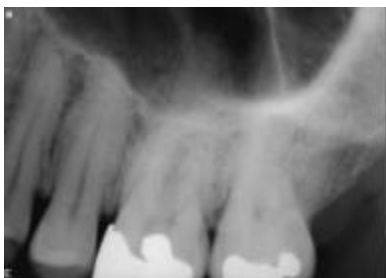the chamber space, increasing fibrosis, cellular density and inducing pulpal strangulation and infarction.



Deep restorations -
pulpal response -
pulpal atrophy

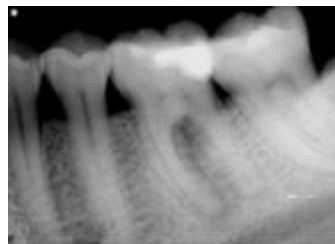
Often, these take the form of adhesions and pulp stones. Pulpal atrophy is a normal component of aging as there is a relative increase in the amount of collagen as well as a decrease in collagen solubility and chemical reactivity. Chronologic age and physiologic age are mutually exclusive. Aged pulps characterized by dense collagenous fibrous bundles, mineralization and cellular dystrophy or disappearance may occur in young individuals with a history of poor hygiene and multiple replacement of restorations in the same tooth.

Pulp Stones: Dystrophic calcification as a result direct, idiopathic or iatrogenic insult manifests within the stroma of the pulp chamber as the pulp calcifies foci of necrotic cells. **Occlusal** disharmony is yet another primary cause of this problem. The existence of occluding stones should create a “danger sign” in regard to the vitality of that particular tooth prior to initiating further restorative procedures.



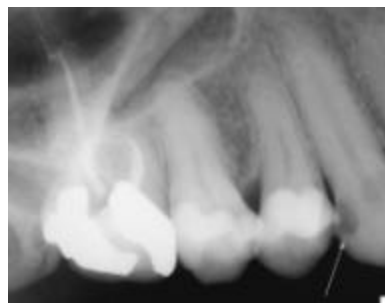Focal Sclerosis/Condensing Osteitis: Condensing osteitis is the manner in which the body protects itself from chronic injury, recurring low-grade infection and long standing periapical infection. Often **asymptomatic**, it is nonetheless a

pathognomonic indicator of chronic inflammation.



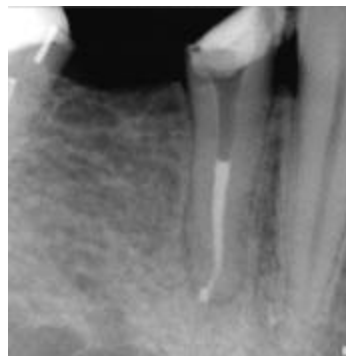
Simultaneous blastic and clastic activity at separate apices of same tooth

Widened Pulp Spaces: In many cases, trauma can cause widened pulp spaces rather than dystrophic canal obliteration. They may remain dormant for a considerable period of time until one day they manifest as an excruciating abscess with associated periapical inflammation and swelling.



Compare coronal canal space in decayed 1.3 to comparable level in 1.4 and 1.5

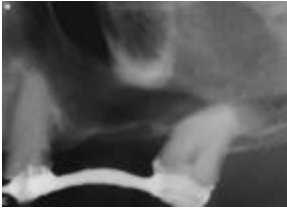
PDL Widening: Widening of the PDL results from incipient pulpal death and expression of the exudates from the canal space into the surrounding tissues. Long-term degeneration leads to pain, swelling and diffuse infection. Anticipation of this occurrence through the use of bitewings to predict the impact of large restorations, deep bases and restorations, crowns, inlays, onlays, chamber or canal constriction obviates the patient's potential for distress.



Loss of lamina dura reflects end stage pulpal degeneration with extension through portals of exit

Loss of Lamina Dura: When the apical or periradicular lamina dura begins to disappear radiographically, pulpal degeneration is occurring and the exudates are starting to infiltrate the surrounding structures. Both the PDL and the lamina dura are being compromised.

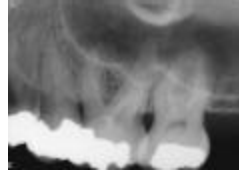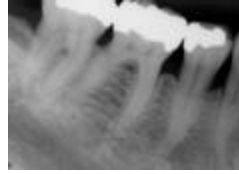
Pins: The advent of adhesion systems to a greater degree has obviated the use of pins in restorations; however, there was an entire generation of teeth whose structural integrity was compromised by the placement of dentinal pins for retention. The trauma of preparation of the pin hole and the insult of placement affected an already stressed pulp and in the case where they were



Pins either cause a significant number of pulp exposures or weaken strategic parts of the coronal tooth structure.

inadvertently inserted directly into the pulp, the irritation vector was maximized. Ingle, Bakland et al (1994) evaluating extracted teeth with pins in a study showed that even the smallest pins caused pulp exposure 40% of the time. If one extrapolates the finding of a Chapel Hill study where one regular pin placed produced cracks that extended into the pulp 73% of the time to two pins, the incidence of pulp exposure increases to 95% of the time and with three pins 98% of the time. Thanks goodness for the adhesion era.

Periodontal Disease: The pulpal consequences of periodontal diseases are often overlooked. The damage to the pulp in terms of atrophy is often catastrophic. Once periodontal disease and gingival recession have exposed the cemental root surface of the tooth, many portals of entry, lateral canals and tubuli are opened making the tooth vulnerable to the toxins accompanying periodontal disease.



Periodontal disease, more deleterious to pulp than both caries and restorations combined. The extravascular communication with the intravascular web is a physiologic continuum that predicates success and failure.

It's intriguing that many of the warning signs are easily identified on a cursory recall exam bitewing film. The nutritional complex that serves the pulp is located in the pulp chamber and not specifically at the apical extent of the tooth and as such it is the control mechanism of health and disease. Pulpal strangulation is a coronal not an apical phenomenon. It is this change in treatment and diagnostic philosophy that will alter the paradigm of rejuvenative and reconstructive dentistry and provide more predictable treatment vistas in the years to come.



www.endosolns.com

Vol 1(1); 2006

Endodontic Solutions

