

Effect of Pretreatment Prednisolone on Postendodontic Pain: A Double-blind Parallel-randomized Clinical Trial

Seyed Mohsen Jalalzadeh, DDS, PhD,* Ahmad Mamavi, DDS, PhD,* Shabriar Shabriari, DDS,* Fábio André Santos, DDS, PhD,[†] and Márcia Thaís Pochapski, DDS[‡]

Abstract

Introduction: Effective management of endodontic pain represents a continuing challenge. This study evaluates the use of a preoperative, single oral dose of prednisolone for the prevention and control of postendodontic pain. **Methods:** Forty patients were randomly assigned to 2 groups, placebo and prednisolone (30 mg). The medications were administered 30 minutes before the start of standard endodontic treatment. Postoperative pain was assessed after 6, 12, and 24 hours by using a visual analogue scale. **Results:** The outcome showed that prednisolone resulted in a statistically significant reduction in postendodontic pain at 6, 12, and 24 hours ($P < .0001$). No side effects were reported for any of the medications used. **Conclusions:** This study suggests that a preoperative, single oral dose of prednisolone substantially reduced postendodontic pain. Further studies are needed to evaluate the applicability of these findings to other clinical conditions, single- versus multiple-visit endodontic treatment, and drug regimens. (*J Endod* 2010;36:978–981)

Key Words

Double-blind study, oral administration, postoperative pain, prednisolone, pulpectomy, root canal therapy

From the *Department of Endodontics, University of Medical Sciences, Hamadan, Iran; [†]Department of Dentistry, Ponta Grossa State University, Parana, PR, Brazil; and [‡]Pharmacology, Anesthesiology and Therapeutics, Piracicaba Dental School, State University of Campinas, Campinas, SP, Brazil.

Address requests for reprints to Dr Márcia Thaís Pochapski, Piracicaba Dental School, University of Campinas, FOP/UNI-CAMP, Av. Limeira, 901, CEP 13414-903, Piracicaba, SP, Brazil. E-mail address: mpochapski@gmail.com. 0099-2399/\$0 - see front matter

Copyright © 2010 American Association of Endodontists. doi:10.1016/j.joen.2010.03.015

Post-treatment endodontic pain has been reported in 25%–40% of all endodontic patients (1–3). Patients with severe preoperative pain tend to have more severe postendodontic pain than patients with mild or no preoperative pain. The possible causes for endodontic interappointment pain are related to endodontic instrumentation, irritating irrigants, intracanal medications, periapical contamination, and temporary restorations in hyperocclusion (1, 2, 4–7). Irritation of periradicular tissues caused by local trauma, caustic irrigating solution, or contamination during root canal therapy causes an acute inflammatory reaction, potentially leading to pain and/or swelling (8). Many chemical mediators (prostaglandins, leukotrienes, bradykinin, etc) have been associated with this inflammatory process. Prostaglandins increase vascular permeability, elevate chemotactic activity, induce fever, and increase sensitivity of pain receptors to other active inflammatory mediators (8–12).

A variety of approaches have been recommended for the management of interappointment pain. These include occlusal reduction, prescription of analgesics, and the use of steroidal and nonsteroidal anti-inflammatory agents (4, 13–15). In this context, drugs that modulate the inflammatory response should be considered for the prevention and control of postendodontic pain. Therefore, systemic drugs (analgesic and anti-inflammatory) have been used to reduce the severity of post-treatment pain. However, a definitive anti-inflammatory protocol to prevent and control the occurrence of postendodontic pain has not yet been established (4, 12, 15–17).

In comparison to repeated doses during the postoperative period, a preoperative, single oral dose of anti-inflammatory drugs can modulate release of inflammatory mediators and reduce the occurrence of side effects. The maximum benefit of the anti-inflammatory is obtained when therapeutic levels are reached before tissue manipulation (1, 4, 10, 11, 16, 18–20).

Prednisolone is a steroidal anti-inflammatory drug (SAID) that inhibits phospholipase A₂ and consequently reduces prostaglandin and leukotriene synthesis, decreasing polymorphonuclear leukocyte chemotaxis. It also suppresses the production of free oxygen radicals and nitric oxide by endothelial cells. Furthermore, SAIDs are also able to down-regulate many proinflammatory cytokines and increase interleukin (IL)-10, which inhibits nuclear factor kappa B activity and affects many immune cells involved in the inflammatory process (11, 21–23).

Nevertheless, few studies have evaluated the effect of SAIDs with regard to prevention and control of postendodontic pain after root canal instrumentation (1, 24–26). The optimal oral prednisolone dosage for the prevention and control of interappointment endodontic pain is yet to be determined. The purpose of the present study was to evaluate the effect of prednisolone (30 mg) administered as a single, preoperative oral dose for the prevention and control of postendodontic pain.

Materials and Methods

This study was approved by the Joint Research and Ethics Committee of the University of Medical Sciences, Hamadan, Iran, and each patient provided informed consent to participate in the study. Sixty-three patients between the ages of 18 and 59 years were selected at the Department of Endodontics, Hamadan Dental School to take part in this double-blind parallel-randomized clinical trial.

Clinical examinations were conducted by 3 operators (senior postgraduate students). The examination included a thermal (cold) test, percussion and palpation evaluation, periodontal probing, mobility assessment, and a periapical radiograph.

All past and present symptoms were noted. A diagnosis was determined on the basis of the history as well as clinical and radiographic features.

The inclusion criteria for the study were requirement for nonsurgical endodontic therapy in single or multirroot teeth (premolar and molar); vital and nonvital pulp and asymptomatic and symptomatic teeth were included. Exclusion criteria were analgesic and inflammatory drugs taken within the last 6 hours, acute endodontic or periodontal abscess, periodontal diseases, requirement for prophylactic antibiotics, pregnancy or lactation, mental disabilities, systemic diseases that contraindicated the endodontic therapy, and any known sensitivity or other adverse reactions to prednisolone.

The volunteers were randomly divided into 2 experimental groups: group 1, placebo (dextrose gelatin capsule), and group 2, prednisolone (30 mg). Both medications were administered 30 minutes before conventional root canal therapy. To maintain the double-blind design, a second investigator (S.M.J.) provided the 2 agents, and each tablet was disguised so that the patient was not aware of the medication he/she was taking.

Treatment in all cases (vital and nonvital teeth) was completed by 3 postgraduate endodontic students in a single visit. Each patient (according to individual needs) was anesthetized with a solution of 2% lidocaine with 1:100,000 epinephrine (Daroupakhsh, Tehran, Iran), followed by rubber dam isolation, access, cleaning and shaping of the canals. The root canal treatment procedure was conducted by using the passive step-back technique. The canals were enlarged to a minimum size of #30 file or larger (depending on the size of the canal), which were 0.5–1.0 mm short of the radiographic apex. Copious irrigation with a saline solution (0.9% of NaCl) or 2.5% sodium hypochlorite was used between each file, and the irrigant remained in the canal throughout the entire procedure.

When instrumentation was completed, the canals were dried with paper points. The canals were filled with gutta-percha (AriaDent, Tehran, Iran) and AH26 sealer (Dentsply DeTrey GmbH, Konstanz, Germany) by using the lateral compaction technique. After placing a cotton pellet in the pulp chamber, the access cavity was closed with Coltosol (Coltene AG, Altstätten, Switzerland). The occlusion was evaluated and reduced if necessary.

Patients were instructed to complete a pain diary 6, 12, and 24 hours after root canal instrumentation. The method used to measure clinical pain intensity was the visual analogue scale (VAS), which consists of a 10-cm line anchored by 2 extremes, "no pain" and "pain as bad as it could be" (26). Patients were asked to make a mark on the line that represented their level of perceived pain. Thus, pain intensity was assigned into 4 categorical scores: 1, none (0); 2, mild (1–3); 3, moderate (4–6); and 4, severe (7–10).

The volunteers received rescue medication (ibuprofen or acetaminophen) and were instructed to take this medication as needed; however, in this case, patients were removed from the study.

Baseline comparisons of the study were performed by using Fisher exact test (age, gender, teeth, diagnosis, and rescue medications). The results of pain intensity (VAS) were computed as the means and standard error (SE). Statistically significant differences among groups (placebo and prednisolone) were evaluated by the unpaired Student *t* test, which was used to determine the differences between groups at each time point. To fit the requirements for this method (normal distribution), the raw data were transformed by using the square root extraction. The normal distribution of the data was tested by the D'Agostino and Pearson omnibus normality test. All calculations were made through the programs SPSS (Statistical Package for the Social Science) version 17.0 for Windows (SPSS Inc, Chicago, IL) and GraphPad Prism, version 5.00 for Windows (GraphPad Software, San Diego, CA). The significance levels were set at $\alpha = 5\%$ ($P \leq .05$).

Results

A total of 40 subjects (12 men and 28 women) completed the study. Fourteen and 9 patients were excluded from the placebo and prednisolone groups, respectively, as a result of rescue medication consumption.

The sample was distributed in a similar way in regards to age, gender, teeth, and endodontic diagnosis, with no significant differences between the groups. However, the percentage of subjects with preoperative pain between placebo (100%) and prednisolone (75%) had significant difference ($P = .0472$) (Table 1).

Postendodontic pain showed a statistically significant difference between groups at 6, 12, and 24 hours ($P < .05$). Prednisolone treatment was associated with the lowest levels of endodontic pain (Fig. 1).

When comparing differences in pain intensity between vital and nonvital teeth, both groups (placebo and prednisolone) had a higher intensity of pain 24 hours after endodontic treatment in nonvital teeth (Fig. 2).

The percentage of subjects reporting no or mild pain after a 6-hour period was 30% for the placebo group and 75% for the prednisolone group. After a 12-hour period, 25% of patients in the placebo group and 80% of patients in the prednisolone group reported no or mild pain. After a 24-hour period, no pain was observed in 15% of the patients in the placebo group and 85% of patients in the prednisolone group (Fig. 3).

No side effects were reported for any of the medications used.

Discussion

Traditionally, impacted third molar extractions and periodontal surgery have served as excellent models for testing analgesic and anti-inflammatory drugs (19, 20, 22). The dental literature presents few studies evaluating oral administration of glucocorticoids for the prevention and control of postendodontic pain (1, 14, 24–26) and no evaluations with oral prednisolone.

TABLE 1. Demographic and Clinical Features

Variables	Group 1 (placebo) (n = 20)	Group 2 (prednisolone) (n = 20)	P value
Age (%)			
18–39 y	95	85	.6050 ns
40–59 y	5	15	
Gender (%)			
Male	70	70	1.000 ns
Female	30	30	
Teeth (%)			
Upper	40	45	1.000 ns
Lower	60	55	
Single root	10	15	1.000 ns
Multirroot	90	85	
Diagnosis (%)			
Vital	60	65	1.000 ns
Nonvital	40	35	
Preoperative conditions (%)			
Asymptomatic	0	25	.0471 s
Symptomatic	100	75	
Rescue medications (%)			
Yes	41*	31*	.4424 ns
No	59	69	

Fisher exact test: s, significant; ns, not significant.

*Patients excluded (rescue medication consumption).

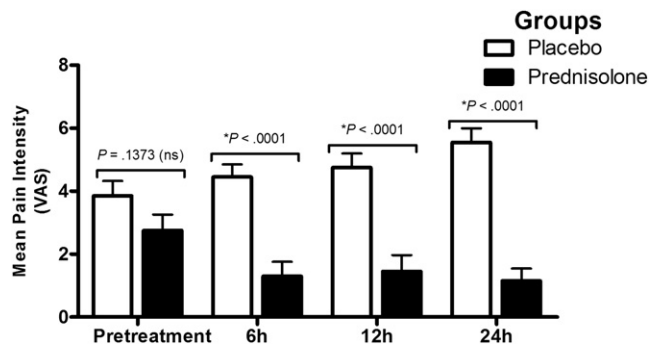


Figure 1. Mean and SE of pain intensity values (VAS) for each group (placebo and prednisolone) at each time point. Single-dose pretreatment with prednisolone was shown to significantly reduce postoperative pain at 6, 12 and 24 hours. *, significant; ns, not significant.

Protocols for assessing endodontic pain differ from oral surgery models in several respects. Patients in need of endodontic treatment might have different systemic conditions and might vary in age or the degree of pulpal pathology; these factors could introduce bias into a study (1, 2, 4–6, 16, 24). Periapical anatomy is another important factor that can lead to different inflammatory responses after root canal therapy (5, 26). Thus, the evaluation of analgesic and anti-inflammatory drugs in oral surgical procedures cannot be directly extrapolated for determining the appropriate approach to treating endodontic pain.

Placebo groups are commonly used in drug efficacy studies. For ethical reasons, all patients were informed about the possibility of receiving a sham treatment. Both groups received rescue medication (ibuprofen or acetaminophen) to be used if they experienced pain during the study; however, in this case, the patients were removed from the study. A combination of placebo and biopulpectomy has been shown to lead to pain relief in 71% of individuals (18). Studies in patients with preexisting pain have shown a significant reduction in pain in patients by using placebo after biopulpectomy (4, 16). In the present study, the placebo did not result in significant pain reduction at the 24-hour time point. These results were different considering other published studies (1, 4, 15, 24). In comparison with placebo at the 6-, 12-, and 24-hour time points, prednisolone was able to significantly reduce pain intensity. The percentage of patients who experienced no pain with the use of prednisolone was 75%, 80%, and 85% at 6, 12, and 24 hours, respectively; for placebo, these values were 30%, 25%, and 15%, respectively. Thus,

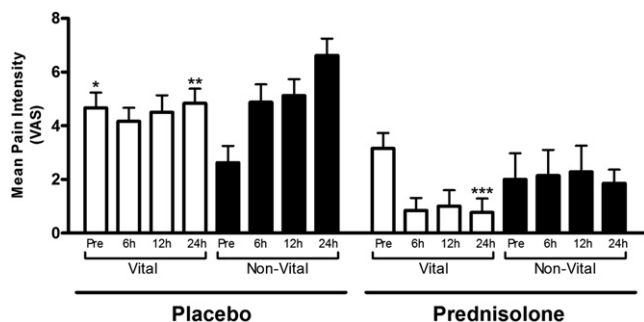


Figure 2. Mean and SE of pain intensity values (VAS) for each group (placebo and prednisolone) with regards to vital and nonvital teeth at each time point. Placebo: $*P = .0266$, pretreatment nonvital teeth; $**P = .0432$, 24 hours nonvital teeth. Prednisolone: $***P = .0280$, 24 hours nonvital teeth.

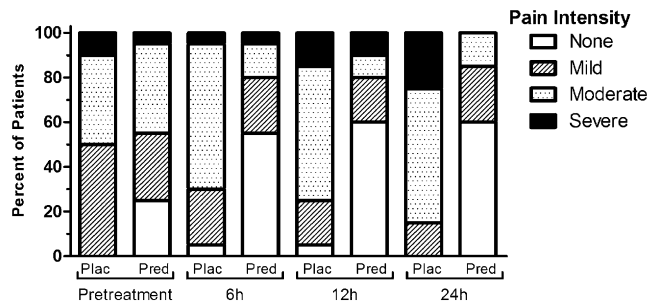


Figure 3. Percentage of subjects in placebo (Plac) and prednisolone (Pred) groups who reported no, mild, moderate, and severe postoperative pain at each time point.

one reason for this difference could be related to the single-visit nonvital endodontic treatment, especially in cases of acute apical periodontitis, in which the inflammatory response is more intense, and debris could be pushed beyond the apex, increasing this inflammatory process and consequently the pain intensity. It is possible that if this study had a longer follow-up (48 or 72 hours), a reduction in pain intensity could have been observed in the placebo group (16).

A VAS was used to evaluate pain intensity; this scale has been used in most of the previous studies that analyzed pain after endodontic treatment (3–5, 8, 10, 15, 18). The VAS is more sensitive to small changes than simple descriptive ordinal scales. One of the limitations of the VAS is that it must be administered on paper or electronically. Caution is required when photocopying the scale because this can lead to significant changes in its length. The failure of VAS is between 4% and 11%, but this can be reduced if the tool is carefully explained to the patient (27). In the present study, the VAS scale was explained in detail to the volunteers, and changes of photocopies were considered.

This is the first study to use a preoperative, single oral dose of prednisolone for the control and prevention of postendodontic pain. Oral administration was preferred because this technique is clinically effective and convenient; the use of intramuscular or intravenous injection might lead to discomfort and fear and is not well-accepted by some patients (1, 14, 19, 24). Most patients and dentists would prefer to provide an anti-inflammatory agent immediately before or self-administered as needed by the patient after anesthesia has worn off. However, in the present research, prednisolone was administered 30 minutes before conventional root canal therapy. Glucocorticoids inhibit the production of cytokines and other factors involved in the inflammatory response in multiple cells. This inhibition results from the effect of corticosteroids on gene transcription, which causes a decrease in release of vasoactive and chemoattractive factors, secretion of lipolytic and proteolytic enzymes, extravasation of leukocytes to areas of tissue injury, and ultimately decreased fibrosis. Glucocorticoids also produce profound effects on the immune response by inhibition of cytokine production, specifically interferon- γ , granulocyte/macrophage colony-stimulating factor (GM-CSF), IL-1, IL-2, IL-3, IL-6, and tumor necrosis factor- α (11, 21). Therefore, corticosteroids must be administered before the infliction of tissue damage, not during or after endodontic treatment. Oral forms must be given at least 2–4 hours in advance of the procedure to ensure adequate tissue levels (8, 22). A single oral dose of prednisolone 30 minutes before endodontic procedures might be appropriate; when the endodontic instruments and irrigating solutions reach the periapical region, the drug will have achieved therapeutic levels in the tissues.

A single oral dose of prednisolone (30 mg), administered 30 minutes before the endodontic procedure, was previously shown to be as effective as treating with comparable dosages for longer periods

of time (1, 24, 26). However, there are few clinical trials involving endodontic and oral surgery procedures that have evaluated the optimal moment for oral corticosteroid administration. Certain studies reported preoperative prescriptions ranging in duration from 1–12 hours (1, 10, 19). In this study, we observed no side effects after prednisolone treatment. However, patients treated with long-term corticosteroids might be expected to have some complications during the endodontic treatment such as a rapid periapical bone destruction caused by the combined effect of a subclinical infection, suppressed immune response, reduced bone mineral content, and negative balance of the bone remodeling process in the jaws (23). But single oral doses are safe over the short term, without side effects or contraindications (1, 11, 22).

This double-blind randomized study minimized bias and allowed sufficient comparison between groups. The sample was similarly distributed with regard to age, gender, teeth, and endodontic diagnosis. However, the percentage of subjects with preoperative pain was higher for placebo (100%) than prednisolone (75%). Nonetheless, mean pain intensity (VAS) was similar in the pretreatment for both groups. Some studies have shown a relationship between preoperative and postoperative pain (2, 14–16). These results, therefore, need to be interpreted with caution. Future clinical trials are required, although control of the variables will be needed to limit bias and provide reliable results (3, 4, 8, 10, 15, 18).

Despite the limitations of this study, postendodontic pain was substantially reduced by preoperative administration of a single oral dose of prednisolone compared with placebo. It is possible that these favorable results might help to prevent postendodontic pain, especially in patients with a low pain threshold. Further clinical studies examining different clinical conditions, single- versus multiple-visit endodontic treatment, and other regimens for prednisolone treatment should be carried out to elucidate the potential of these drugs in the context of endodontic treatment.

References

- Pochapski MT, Santos FA, de Andrade ED, Sydney GB. Effect of pretreatment dexamethasone on postendodontic pain. *Oral Surg Oral Med Oral Pathol Oral Radiol Endod* 2009;108:790–5.
- Ince B, Ercan E, Dalli M, Dulgergil CT, Zorba YO, Colak H. Incidence of postoperative pain after single- and multi-visit endodontic treatment in teeth with vital and non-vital pulp. *Eur J Dent* 2009;3:273–9.
- Nekoofar MH, Sadeghipanah M, Dehpour AR. Evaluation of meloxicam (A cox-2 inhibitor) for management of postoperative endodontic pain: a double-blind placebo-controlled study. *J Endod* 2003;29:634–7.
- Attar S, Bowles WR, Baisden MK, Hodges JS, McClanahan SB. Evaluation of pretreatment analgesia and endodontic treatment for postoperative endodontic pain. *J Endod* 2008;34:652–5.
- Torabinejad M, Cymerman JJ, Frankson M, Lemon RR, Maggio JD, Schilder H. Effectiveness of various medications on postoperative pain following complete instrumentation. *J Endod* 1994;20:345–54.
- Yesilsoy C, Koren LZ, Morse DR, Rankow H, Bolanos OR, Furst ML. Post-endodontic obturation pain: a comparative evaluation. *Quintessence Int* 1988;19:431–8.
- Genet JM, Hart AA, Wesselink PR, Thoden van Velzen SK. Preoperative and operative factors associated with pain after the first endodontic visit. *Int Endod J* 1987;20:53–64.
- Mehrvazfar P, Shababi B, Sayyad R, Fallahdoost A, Kheradpir K. Effect of supraperiosteal injection of dexamethasone on postoperative pain. *Aust Endod J* 2008;34:25–9.
- Hargreaves KM, Keiser K. New advances in the management of endodontic pain emergencies. *J Calif Dent Assoc* 2004;32:469–73.
- Lin S, Levin L, Emodi O, Abu El-Naaj I, Peled M. Etodolac versus dexamethasone effect in reduction of postoperative symptoms following surgical endodontic treatment: a double-blind study. *Oral Surg Oral Med Oral Pathol Oral Radiol Endod* 2006;101:814–7.
- Marshall JG. Consideration of steroids for endodontic pain. *Endo Topics* 2002;3:41–51.
- Negm MM. Management of endodontic pain with nonsteroidal anti-inflammatory agents: a double-blind, placebo-controlled study. *Oral Surg Oral Med Oral Pathol* 1989;67:88–95.
- Rosenberg PA, Babick PJ, Schertzer L, Leung A. The effect of occlusal reduction on pain after endodontic instrumentation. *J Endod* 1998;24:492–6.
- Marshall JG, Liesinger AW. Factors associated with endodontic posttreatment pain. *J Endod* 1993;19:573–5.
- Ryan JL, Jureidini B, Hodges JS, Baisden M, Swift JQ, Bowles WR. Gender differences in analgesia for endodontic pain. *J Endod* 2008;34:552–6.
- Gopikrishna V, Parameswaran A. Effectiveness of prophylactic use of rofecoxib in comparison with ibuprofen on postendodontic pain. *J Endod* 2003;29:62–4.
- Mickel AK, Wright AP, Chogle S, Jones JJ, Kantorovich I, Curd F. An analysis of current analgesic preferences for endodontic pain management. *J Endod* 2006;32:1146–54.
- Menhinick KA, Gutmann JL, Regan JD, Taylor SE, Buschang PH. The efficacy of pain control following nonsurgical root canal treatment using ibuprofen or a combination of ibuprofen and acetaminophen in a randomized, double-blind, placebo-controlled study. *Int Endod J* 2004;37:531–41.
- Pilatti GL, Santos FA, Bianchi A, Cavassim R, Tozetto CW. The use of celecoxib and dexamethasone for the prevention and control of postoperative pain after periodontal surgery. *J Periodontol* 2006;77:1809–14.
- Leone M, Richard O, Antonini F, et al. Comparison of methylprednisolone and ketoprofen after multiple third molar extraction: a randomized controlled study. *Oral Surg Oral Med Oral Pathol Oral Radiol Endod* 2007;103:e7–9.
- Czock D, Keller F, Rasche FM, Haussler U. Pharmacokinetics and pharmacodynamics of systemically administered glucocorticoids. *Clin Pharmacokinet* 2005;44:61–98.
- Alexander RE, Thronson RR. A review of perioperative corticosteroid use in dentoalveolar surgery. *Oral Surg Oral Med Oral Pathol Oral Radiol Endod* 2000;90:406–15.
- Oh WM, Hwang IN, Son HH, Hwang YC. Rapid periapical bone destruction during endodontic treatment of a patient with rheumatoid arthritis. *J Endod* 2008;34:1261–3.
- Glassman G, Krasner P, Morse DR, Rankow H, Lang J, Furst ML. A prospective randomized double-blind trial on efficacy of dexamethasone for endodontic interappointment pain in teeth with asymptomatic inflamed pulps. *Oral Surg Oral Med Oral Pathol* 1989;67:96–100.
- Liesinger A, Marshall EJ, Marshall JG. Effect of variable doses of dexamethasone on posttreatment endodontic pain. *J Endod* 1993;19:35–9.
- Krasner P, Jackson E. Management of posttreatment endodontic pain with oral dexamethasone: a double-blind study. *Oral Surg Oral Med Oral Pathol* 1986;62:187–90.
- Williamson A, Hoggart B. Pain: a review of three commonly used pain rating scales. *J Clin Nurs* 2005;14:798–804.