

Management of the Implant Periapical Lesion: A Case Report

Tae-Ju Oh, DDS, MS,* Joongkyo Yoon, DDS, PhD,** Hom-Lay Wang, DDS, MSD***

Endosseous dental implants have been utilized as a successful treatment modality for the restoration of missing dentition over three decades. A high implant success rate has been reported.¹⁻³ Nevertheless, a significant number of implant failures have also been reported.⁴⁻⁶ The etiology and mechanism of implant failure are multifactorial, and the implant periapical lesion (IPL) has been suggested as a possible cause for some implant failures.⁷⁻⁹

IPL is a periapical lesion of a dental implant often associated with implants that may have been inserted traumatically by bone overheating or excessive tightening the implant during implant surgery, or implants that are located adjacent to a tooth with endodontic/periodontal lesions.^{5,7,8,10} Suggested causes of IPL may include the presence of pre-existing microbial pathology,¹⁰⁻¹² surgical trauma,⁸ contaminated implants,¹² and fenestrated vestibular bone.⁸ The incidence of IPL appears to be somewhat low, as shown in a study where 10 periapically infected implants were found among 3,800 implants examined.⁷ However, the increased use of dental implants has resulted in a considerable number of implant periapical lesions, as demonstrated by recent case reports.^{6,8,13-16}

IPL can be classified into the inactive (non-infected) and infected

The implant periapical lesion (IPL), a possible cause for implant failure, may occur from the presence of pre-existing microbial pathology such as endodontic/periodontal lesions. This case report presents a case history related to IPL, which was caused by a pre-existing endodontic lesion. In addition, other possible causes such as surgical trauma and the management strategies of IPL are suggested. For the treatment of the infected form of IPL, a sequential surgical therapy

can be utilized. This includes surgical removal of the implant or implant apical region, thorough debridement of the infected lesion, systemic antibiotics, and/or guided bone regeneration. The implant therapy should be directed to minimize the occurrence or consequences of IPL by careful diagnosis, systematic treatment planning, and appropriate treatment procedures. (Implant Dent 2003;12: 41-46)

Key Words: *implant periapical lesion, implant failure*

forms.⁷ There is no treatment that is required for the inactive form, but periodic monitoring of the lesion is recommended. For the treatment of the infected form of IPL, surgical approaches have been advocated, including implant removal, resection of infected implant apices, and guided bone regeneration.^{5,7,10,17-18} This case report presents, in a chronological manner, a case history of an implant periapical lesion, which was caused by a pre-existing endodontic lesion. In addition, possible causes and management strategies of IPL will be suggested.

CASE REPORT

A healthy, 47-year-old Caucasian woman presented to the Dental Faculty Associates (DFA) Clinic at the University of Michigan School of Dentistry in October 1994, with a dental caries-associated fracture at the distal root of the mandibular first molar (tooth no. 30), which had been endodontically treated and restored with a full porcelain-fused-to-metal (PFM) crown (Fig. 1). The fracture extended

to the furcation area where radiographic furcation involvement was suggested. Therefore, the proposed treatment plans were distal root resection and the placement of two endosseous dental implants distal to the mesial root of the molar (tooth no. 30). Root resection surgery was performed without complication. Three months were allowed for the healing of the extraction socket. During this period, the remaining mesial root was restored with a post and core-supported PFM crown. Two root-form submerged endosseous implants (3.75 mm × 13 mm in the mesial site and 3.75 mm × 10 mm in the distal site; Brånemark, Nobel Biocare, Yorba Linda, CA) were inserted in the areas of tooth no. 30 distal and tooth no. 31 (mandibular right second molar) under local anesthesia. After surgery, the patient was asked to rinse with an antimicrobial mouthrinse (chlorhexidine 0.12%) for plaque control, and a nonsteroidal anti-inflammatory drug (ibuprofen) was prescribed. No systemic antibiotics were given. The initial healing of both implant sites was uneventful as

*Clinical Assistant Professor, Department of Periodontics/Prevention/Geriatrics, University of Michigan School of Dentistry, Ann Arbor, MI.

**Adjunct Assistant Professor, Department of Oral Medicine, Yonsei University School of Dentistry, Seoul, South Korea; Private Practice, Seoul, South Korea.

***Professor and Director of Graduate Periodontics, Department of Periodontics/Prevention/Geriatrics, University of Michigan School of Dentistry, Ann Arbor, MI.

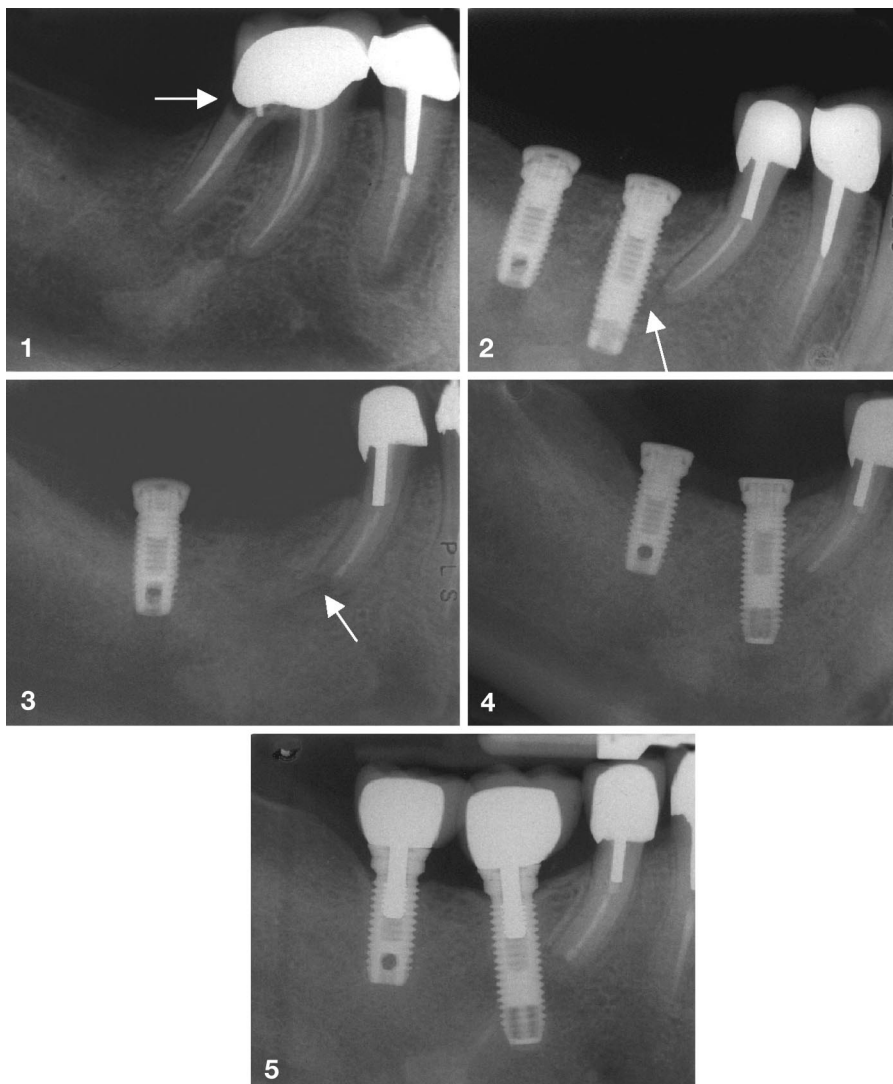


Fig. 1. Radiolucency is noted on the cervical area of the distal root of the mandibular first molar (arrow). Furcation involvement is also suggested by radiolucency in the furcation. Clinically, a tooth fracture in association with dental caries was detected, which extended to the furcation area.

Fig. 2. Following hemisection of the distal root, two implants were placed distal to the mesial root of the first molar. However, the implant adjacent to the remaining root was not osseointegrated as demonstrated by radiolucency (arrow), fistula formation, and implant mobility, possibly because of microbial contamination from pre-existing pathosis.

Fig. 3. The failed implant was removed, and apicoectomy (arrow) was performed on the remaining root that had a periapical pathosis.

Fig. 4. A new submerged endosseous implant (13 mm long and 3.75 mm in diameter) was inserted in the previously failed implant site after healing of the apicoectomy site.

Fig. 5. Both implants, including the newly placed implant, have been in function for 7 years without any signs or symptoms of periimplant infection or IPL.

observed at 2 weeks postimplantation. However, at the time of implant uncover surgery (3 months after implant surgery), a fistula with inflammatory exudate was found on the buccal aspect of the tooth no. 30 implant site. Moreover, there was a radiolucency found in the tooth no. 30 area, extending from the periapical region of the remaining root to the im-

plant mesial surface (Fig. 2). It appeared that endodontic retreatment should have been performed on the remaining root before implant placement to prevent this co-infection. Upon careful clinical examination, a failure of the no. 30 implant was diagnosed as being caused by extensive involvement of active inflammation along with implant mobility. The

failed implant was surgically removed followed by thorough debridement of the socket. In addition, apicoectomy procedures were carried out on the remaining root (no. 30 mesial root, Fig. 3). Clinical examination of the other implant (no. 31) revealed a successful integration. Both implant sites were then covered with flaps to ensure proper healing of the no. 30 area.

Three months later (April 1995), the previously failed implant site was revisited and examined. Because the bone density on the area appeared to be sufficient for implant primary stability, the same size of a root-form endosseous implant (3.75 mm × 13 mm; Brånemark, Nobel Biocare) was again placed in the area of the previously failed implant site (Fig. 4). The implant was submerged under the flaps, together with the no. 31 implant. At this time, antibiotics (amoxicillin 500 mg, three times a day, for 10 days) were prescribed to prevent postsurgical infection. Stage II implant uncover surgery was performed 3 months after the implant placement (July 1995), revealing successful osseointegration of the newly inserted implant. The two implants were then restored with full PFM crowns and have remained in function since then (Fig. 5). No recurrence of periimplant infection or IPL has been noted over the years.

DISCUSSION

Several etiologic factors for IPL have been proposed, including the presence of pre-existing microbial pathology,¹⁰⁻¹² contamination of the implant,¹² bone overheating during implant surgery,⁸ excessive tightening of the implant with compression of bone chips,⁸ premature loading and/or overloading of the implant,¹⁹⁻²⁰ fenestration of vestibular bone,⁸ and inadequate space between implants.¹² Yoon et al (2002) proposed that among those factors, microbial involvement of pre-existing pathosis and surgical trauma, such as bone overheating during implantation, could be considered the most likely causes of IPL.⁹ This is in agreement with the findings observed in the present case, where pre-existing microbial pathology in the host tissues might have been attributed to the initiation of IPL.

It was suggested that dental implants do not possess the ability to withstand any bacterial challenge during the first stage of osseointegration, and that an endodontic lesion can travel through marrow spaces and contaminate an adjacent implant fixture.¹¹ This may lead to the loss of the implant (Fig. 2) or a potential osteomyelitis.^{11,13}

Distinguishing an infected form of a periapical lesion (or IPL) from an inactive form cannot be readily diagnosed unless clinical symptoms such as suppuration or fistula formation develop. A radiographic resolution of a periapical lesion may not signify the eradication of a bacterial reservoir clinically⁶ or histologically.²¹⁻²² Seltzer (1999) reported that histologic evidence of periapical chronic inflammatory lesions was found in at least one-half of the specimens obtained from 14 teeth that were endodontically treated 6 to 30 months before the sampling.²²

This case report demonstrates a successful management of an IPL-associated implant failure by means of the removal of the failed implant, thorough debridement of the socket, apicoectomy, and replacement with a new implant. McAllister et al (1992) described that even with vigorous debridement, bacteria remaining in the socket can initiate infection.¹⁰ On the other hand, Novaes and Novaes (1995) stated that the placement of an implant into a socket with a chronic lesion does not necessarily result in failure if certain precautions, including pre- and postoperative care, as well as meticulous debridement of the alveolus, are taken.²³ It can be speculated that complete removal of etiologic factors with thorough debridement of the socket, in addition to the use of antibiotics, can reduce or eliminate infection that has resulted from bacterial contamination. In the case reported here, the infected area was treated by a combination of implant removal, apicoectomy, and thorough debridement of the previously infected lesion, including antibiotic therapy.

The treatment strategy for implants with periapical lesions is dependent upon the etiology individualized. For example, if the source of IPL is considered to be from a periapical le-

sion of an adjacent tooth, the periapical lesion should be treated together with the treatment of IPL. Although stable asymptomatic inactive forms would not require any specific treatment, periodic monitoring of the lesion, especially with radiographic assessment, should be followed. On the other hand, infected lesions may need to be treated aggressively with a combination of antibiotics and surgical therapy such as guided bone regeneration, resective therapy, or complete removal of the implant.

Surgical approaches for the treatment of IPL have been advocated by several authors. Sussman (1998) stated that an infected implant should be immediately removed to prevent an osteomyelitis because retention of an implant with an osteitis can lead to irreversible bone loss.¹⁸ Reiser and Nevins (1995) recommended that a mobile implant must be removed immediately.⁷ However, they further mentioned that it is unnecessary to prophylactically remove or resect an implant if the periapical area is small and inactive. Because the implant with IPL in this case showed mobility with an active inflammatory lesion, the treatment decision was removal of the implant and replacement with a new implant. It would be possible to treat the implant periapical infection and salvage the implant if:¹ the implant is stable (osseointegrated);² the infection remains apically compartmentalized; and³ the implant is of a sufficient length to allow for removal of its apical portion without jeopardizing stability. The apex of implant can be sectioned if it prevents thorough and complete debridement.^{7,16}

In cases of stable implants with suppurative periimplant infection, the use of systemic antibiotics, such as amoxicillin, metronidazole, or a combination of both, is often recommended.²⁴⁻²⁶ However, antibiotic administration alone is unlikely to be successful because of the difficulties in eradicating bacterial colonies from IPL.²⁷ Therefore, meticulous debridement or removal of infection sources, including contaminated implants and endodontic/periodontal lesions, is essential.

CONCLUSION

Little is known about the etio-pathogenesis of IPL. It is apparent that IPL has a multifactorial background, mainly caused by the presence of pre-existing microbial pathology or surgical trauma during implant surgery. IPL reported in this case report was associated with a pre-existing endodontic lesion. Appropriate endodontic therapy and/or removal of potential infection sources adjacent to implant sites should be performed before implant placement to prevent the occurrence of IPL. If healing of an endodontic lesion could not be achieved by conventional endodontic therapy, apical surgery (apicoectomy) or extraction should be considered. In addition, meticulous removal of potential infection sources such as granulation tissue, root fragments, foreign bodies, and periodontal or periapical infection in the proposed implant site is critical for implant success. For the treatment of the infected form of IPL, a sequential surgical therapy can be utilized, consisting of surgical removal of the implant or implant apical region, thorough debridement of the infected lesion, systemic antibiotics, and/or guided bone regeneration. The optimal implant therapy would be minimizing the occurrence or consequences of implant periapical lesions by careful diagnosis, systematic treatment planning, and appropriate treatment procedures.

Disclosure

The authors claim to have no financial interest in any company or any of the products mentioned in this article.

REFERENCES

1. Adell R, Lekholm U, Rockler B, et al. A 15-year study of osseointegrated implants in the treatment of the edentulous jaw. *Int J Oral Surg*. 1981;10:387-416.
2. Albrektsson T. A multicenter report on osseointegrated oral implants. *J Prosthet Dent*. 1988;60:75-84.
3. Buser D, Mericske-Stern R, Dula K, et al. Clinical experience with one-stage, non-submerged dental implants. *Adv Dent Res*. 1999;13:153-161.
4. Jaffin RA, Berman CL. The excessive loss of Brånemark fixtures in type IV bone: A 5-year analysis. *J Periodontol*. 1991;62:2-4.

5. Esposito M, Hirsch J, Lekholm U, et al. Differential diagnosis and treatment strategies for biologic complication and failing oral implants: A review of the literature. *Int J Oral Maxillofac Implants*. 1999;14:473-490.
6. Brisman DL, Brisman AS, Moses MS. Implant failures associated with asymptomatic endodontically treated teeth. *J Am Dent Assoc*. 2001;132:191-195.
7. Reiser GM, Nevins M. The implant periapical lesion: Etiology, prevention, and treatment. *Compend Contin Educ Dent*. 1995;16:768-777.
8. Piattelli A, Scarano A, Piattelli M, et al. Implant periapical lesion. Clinical, histological and histochemical aspects. A case report. *Int J Periodont Restorative Dent*. 1998;18:181-187.
9. Yoon J, Oh T-J, Wang H-L. Implant periapical lesion: Potential etiology and treatment. *J Korean Dent Assoc*. 2002;40:388-397.
10. McAllister BS, Masters D, Meffert RM. Treatment of implants demonstrating periapical radiolucencies. *Pract Periodontics Aesthet Dent*. 1992;4:37-41.
11. Sussman HI, Moss SS. Localized osteomyelitis secondary to endodontic-implant pathosis. A case report. *J Periodontol*. 1993;64:306-310.
12. el Askary AS, Meffert RM, Griffin T. Why do dental implants fail? Part I. *Implant Dent*. 1999;8:173-185.
13. Sussman HI. Endodontic pathology leading to implant failure; A case report. *J Oral Implantol*. 1997;23:112-115.
14. Ayangco L, Sheridan PJ. Development and treatment of retrograde periimplantitis involving a site with a history of failed endodontic and apicoectomy procedures: A series of reports. *Int J Oral Maxillofac Implants*. 2001;16:412-417.
15. Chaffee NR, Lowden K, Tiffée JC, et al. Periapical abscess formation and resolution adjacent to dental implants: A clinical report. *J Prosthet Dent*. 2001;85:109-112.
16. Jalbout ZN, Tarnow DP. The implant periapical lesion: four case reports and review of the literature. *Pract Proced Aesthet Dent*. 2001;13:107-112.
17. Balshi TJ, Pappas CE, Wolfinger GJ, et al. Management of an abscess around the apex of a mandibular root-form implant: Clinical report. *Implant Dent*. 1994;3:81-85.
18. Sussman HI. Periapical implant pathology. *J Oral Implantol*. 1998;24:133-138.
19. Misch CE. Effect on treatment plans, surgical approach, healing and progressive loading. *Int J Oral Implantol*. 1990;6:23-31.
20. Esposito M, Hirsch J, Lekholm U, et al. Biological factors contributing to failures of osseointegrated oral implants (II): Etiopathogenesis. *Eur J Oral Sci*. 1998;106:721-764.
21. Green TL, Walton RE, Taylor JK, et al. Radiographic and histologic periapical findings of root canal treated teeth in cadaver. *Oral Surg Oral Med Oral Pathol Oral Radiol Endod*. 1997;83:707-711.
22. Seltzer S. Long-term radiographic and histologic observations of endodontically treated teeth. *J Endod*. 1999;25:818-822.
23. Novaes AB Jr, Novaes AB. Immediate implants placed into infected sites: A clinical report. *Int J Oral Maxillofac Implants*. 1995;10:609-613.
24. Mombelli A, Lang NP. Antimicrobial treatment of periimplant infection. *Clin Oral Implants Res*. 1992;3:162-168.
25. Jovanovic SA. The management of peri-implant breakdown around functioning osseointegrated dental implants. *J Periodontol*. 1993;64:1176-1183.
26. Kao RT, Curtis DA, Murray PA. Diagnosis and management of peri-implant disease. *J Calif Dent Assoc*. 1997;25:872-880.
27. Shaffer MD, Juruz DA, Haggerty PC. The effect of periradicular endodontic pathosis on the apical region of adjacent implants. *Oral Surg Oral Med Oral Pathol Oral Radiol Endod*. 1998;86:578-581.

Reprint requests and correspondence to:
 Hom-Lay Wang, DDS, MSD
 Department of Periodontics/Prevention/Geriatrics
 University of Michigan School of Dentistry
 1011 North University Avenue
 Ann Arbor, Michigan 48109-1078
 Phone: (734) 763-3383
 Fax: (734) 936-0374
 E-mail: homlay@umich.edu



Abstract Translations [German, Spanish, Portuguese, Japanese]

AUTOR(EN): Tae-Ju Oh, DDS, MS*, Joongkyo Yoon, DDS, PhD**, und Hom-Lay Wang, DDS, MSD***. *Stellvertretender medizinischer Professor, Abteilung für Orthodontie/ Prophylaxe/ Geriatrie, zahnheilkundliche Fakultät - Universität von Michigan, MI, USA. **Stellvertretender Professor Adjunctus, Abteilung für Oralmedizin, zahnheilkundliche Fakultät der Yonsei Universität, Seoul, Südkorea; privat praktizierender Arzt, Seoul, Südkorea. ***Professor und Leiter des Graduiertenkollegs für Orthodontie, Abteilung für Orthodontie/ Prophylaxe/ Geriatrie, zahnheilkundliche Fakultät - Universität von Michigan, MI, USA. Schriftverkehr: Hom-Lay Wang, DDS, MSD, Abteilung für Orthodontie/ Prophylaxe/ Geriatrie (Dept of Periodontics/ Prevention/ Geriatrics), zahnheilkundliche Fakultät - Universität von Michigan (University of Michigan School of Dentistry), 1011 North University Avenue, Ann Arbor, Michigan 48109 - 1078, USA. Telefon: (734) 763 - 3383, Fax: (734) 936 - 0374; eMail: homlay@umich.edu

ZUSSAMENFASSUNG: Aufgrund von zuvor aufgetretenen, durch Mikroben hervorgerufenen pathologischen Befunden wie endodontischen oder peridentalischen Läsionen kann es zu periapikalen Schädigungen des Implantats kommen, was möglicherweise in einem letztendlichen Fehlschlagen der Implantationsbehandlung resultiert. Der geschilderte Krankenbericht nimmt den Fall eines Patienten mit durch eine zuvor bestehende endodontische Läsion entstandener periapikaler Schädigung am Implantat auf. Es wurde auch in Betracht gezogen, dass andere Ursachen für das Entstehen der Schädigung, wie beispielsweise das Auftreten eines operativen Traumas, verantwortlich sein können. Im vorliegenden Bericht werden daraufhin Methoden zur Behandlung der Schädigung aufgezeigt. Um die infektiöse Form der periapikalen Implantatschädigung sinnvoll zu behandeln, kann eine sequentiell vorgenommene operative Therapie angezeigt sein; dies umfasst die operative Entfernung von Implantat oder Apikalregion, eine gründliche Wundreinigung der infizierten Läsion, die Gabe von Breitbandantibiotika und / oder einen gezielten Knochenaufbau. Eine Implantationsbehandlung sollte von vornherein darauf ausgelegt werden, das Auftreten von periapikalen Implantatschädigungen entweder vollständig zu vermeiden oder aber die Folgen möglichst einzudämmen. Hierzu sollte der Therapieansatz eine gründliche Diagnoseerstellung, eine systematische Behandlungsplanung und entsprechende Behandlungsschritte vorsehen.

SCHLÜSSELWÖRTER: Zahnimplantat, periapikale Implantatschädigung, Fehlschlagen der Implantationsbehandlung

AUTOR(ES): Tae-Ju Oh, DDS, MS*, Joongkyo Yoon, DDS, PhD** y Hom-Lay Wang, DDS, MSD***. **Profesor Clínico Asistente, Departamento de Periodontica/Prevenición/Geriatria, Facultad de Odontología de la Universidad de Michigan, MI, EE.UU.* ***Profesor Asistente Adjunto, Departamento de Medicina Oral, Facultad de Odontología de Yonsei University, Seoul, Corea del Sur; Práctica privada, Seoul, Corea del Sur.* ****Profesor y Director de Periodontica para Graduados, Departamento de Periodontica/Prevenición/Geriatria, Facultad de Odontología de la Universidad de Michigan, MI, EE.UU.. Correspondencia a: Hom-Lay Wang, DDS, MSD., Dept. of Periodontics/Prevention/Geriatrics, University of Michigan School of Dentistry, 1011 North University Avenue, Ann Arbor, MI 48109-1078, EE.UU.. Teléfono: (734) 763-3383, Fax: (734) 936-0374; Dirección electrónica: homlay@umich.edu*

AUTOR(ES): Tae-Ju Oh, DDS, MS*, Joongkyo Yoon, DDS, PhD** e Hom-Lay Wang, DDS, MSD***. **Professor Clínico Adjunto, Departamento de Periodontia/Prevenção/Geriatria, Faculdade de Odontologia da Universidade de Michigan, MI, EUA.* ***Professor Assistente Adjunto, Departamento de Medicina Oral, Faculdade de Odontologia da Universidade de Yonsei, Seoul, Coréia do Sul; Clínica Particular, Seoul, Coréia do Sul.* ****Professor e Diretor com Graduação em Periodontia, Departamento de Periodontia/Prevenção/Geriatria, Faculdade de Odontologia da Universidade de Michigan, MI, EUA. Correspondências devem ser enviadas a: Hom-Lay Wang, DDS, MSD., Dept of Periodontics/Prevention/Geriatrics, University of Michigan School of Dentistry, 1011 North University Avenue, Ann Arbor, Michigan 48109-1078, EUA. Telefone.: (734) 763-3383, Fax: (734) 936-0374; E-mail: homlay@umich.edu*

ABSTRACTO: La lesión periápica del implante (IPL), una causa posible de la falla del implante, podría ocurrir ante la presencia de una patología microbiana preexistente tal como lesiones endodónticas/periodónticas. Este informe de un caso presenta la historia de un caso relacionado con la IPL que fue causada por una lesión endodóntica preexistente. Además, se sugieren otras causas posibles tales como trauma quirúrgico y las estrategias de atención de la IPL. Para el tratamiento de la forma infectada de la IPL, se puede utilizar una terapia quirúrgica secuencial. Esto incluye la eliminación quirúrgica del implante o la región apical del implante, a través del desbridamiento de la lesión infectada, antibióticos sistémicos y/o regeneración guiada del hueso. La terapia del implante deberá orientarse a reducir la ocurrencia o consecuencia de la IPL a través del diagnóstico cuidadoso, planificación de un tratamiento sistemáticos y procedimientos apropiados de tratamiento.

PALABRAS CLAVES: implantes dentales, lesión periapical del implante, falla del implante.

SINOPSE: a lesão periapical de implante (IPL, ou *implant periapical lesion*), uma possível causa para o insucesso do implante, pode ocorrer a partir da presença de patologia microbiana preexistente, como lesões endodônticas/periodontais. Este relatório de caso apresenta um histórico relacionado ao IPL, o que foi causado devido a uma lesão endodôntica preexistente. Além disto, são sugeridas outras possíveis causas, como trauma cirúrgico e as estratégias de controle de IPL. Para o tratamento da forma infecciosa de IPL, pode-se utilizar uma terapia cirúrgica sequencial. Isto inclui a remoção cirúrgica do implante ou da região apical do implante, o desbridamento completo da lesão infectada, antibióticos sistêmicos e/ou a regeneração óssea orientada. A terapia de implante deverá ser direcionada a fim de minimizar a ocorrência ou as consequências de IPL por diagnósticos cuidadosos, planejamento sistemático do tratamento e procedimentos apropriados de tratamento.

PALAVRAS-CHAVES: implante odontológico, lesão periapical de implante, insucesso do implante

インプラント根尖部の病変管理：症例報告

著者：タエ-ジュー、オー、DDS、MS*、ジューンギョー・ユーン、DDS、PhD**、ホーム-ライ・ウォン、DDS、MSD***

概要：インプラントの根尖部病変（IPL）はインプラント機能不全の原因となりうるものであるが、それは歯内病、歯周病の病変部など既存の細菌感染の存在によって起こることがある。本症例報告は、既存の歯内病の病変部を原因として起こったIPLに関するものである。この報告はさらに、術後の損傷などを含む他の原因とIPLの正しい治療管理の方向についても論じる。感染を伴うIPLの治療については、数回に分けた逐次的手術が勧められる。このような治療法には、インプラントまたはインプラントの歯根部分の除去、感染部分の完全なdebridement、全身性抗生物質の投与、誘導骨再生などが含まれる。インプラントによる治療は、IPLの発生またはその結果として起こる問題を、慎重な診断、全体的治療計画、適当な治療法の選択などによって最小に抑えることを目標として行われるべきである。

キーワード：デンタルインプラント、インプラントの根尖部病変、インプラントの機能不全

*ミシガン大学歯科スクール歯周病・予防医学・老人病学部臨床助教授（米国ミシガン州）

**ヨンセイ大学歯科スクール口腔医学部副助教授（韓国、ソウル）、韓国、ソウルにて開業

***ミシガン大学歯科スクール歯周病・予防医学・老人病学部歯周病学士過程主任・教授（米国ミシガン州）

問い合わせ先：Hom-Lay Wang, DDS, MSD, Dept. of Periodontics/Prevention/Geriatrics, University of Michigan School of Dentistry, 1011 North University Avenue, Ann Arbor, Michigan 48109-1078, U.S.A.

電話：734-763-3383 ファックス：734-936-0374 Eメール：homlay@umich.edu