

Immediate implant placement: treatment planning and surgical steps for successful outcome

WILLIAM BECKER & MOSHE GOLDSTEIN

Placement of endosseous implants has made it possible to perform restorations in patients who are fully or partially edentulous (1, 2, 20, 21). Original protocols required the placement of implants into healed edentulous ridges. In 1989, Lazzara (44) placed implants at the time of tooth extraction. Immediate implants were augmented with barrier membranes to preserve ridge width and height and to decrease treatment time. Becker et al. (6, 9, 12) reported a 93.3% 5-year implant survival rate with clinically insignificant crestal alveolar bone loss for immediate implants that were augmented with barrier membranes. Over the past 16 years numerous studies have confirmed the reliability of implants placed at the time of tooth extraction (34, 67, 75, 76, 87, 88). Small osseous defects, which are frequently found adjacent to implants placed at the time of tooth extraction, can be grafted with autogenous bone obtained from edentulous ridges or other intraoral sites (6, 83). Clinicians have also used other materials and methods to augment edentulous ridges and small bony defects adjacent to dental implants, including demineralized freeze-dried bone and barrier membranes (33, 35, 49, 50, 60–62).

The stability of implants can be determined using a resonance frequency analysis (51–53, 68, 69, 72, 79). This method requires the placement of an electronic transducer on the implant head or prosthetic abutment with a retaining screw, and the passing of a low-voltage current, which is undetectable to the patient, through the transducer.

Resistance to the vibration of the transducer in the surrounding bone is digitally registered. The original resonance frequency measurements were recorded in hertz, but were later converted to implant stability quotient (ISQ) units. A recent study of immediate implants found a 2- to 3-year cumulative survival rate of 97.8%, and a mean stability of all implants at the time of tooth extraction of 62.0 ± 9.8 ISQ and at 1 year of 64.0 ± 9.8 ISQ (13). Implants with ISQ values > 50 are considered clinically stable. The initial stability was lower in the maxilla than in the mandible, while the 1-year stability measurements did not differ significantly between the jaws. However, sites that receive implants at the time of tooth extraction or within a short time after extraction may demonstrate a slight decrease in crestal bone width (10, 67).

This paper will review the concept of placement of implants at the time of tooth extraction and describe the indications, limitations, and anatomic, prosthetic, and esthetic requirements for immediate implant placement. The notion of ‘socket preservation’ for sites that might receive dental implants will be discussed. The idea of minimally invasive surgery and guided implant placement for implants placed at the time of extraction will also be introduced.

Diagnosis and treatment planning

Diagnosis and treatment planning are key factors in achieving a successful outcome after placing and restoring implants immediately after tooth extraction. Some or all of the following suggestions, depending on individual circumstances, should be

Portions of this paper were published in the *California Dental Journal*, 2005: 33: No. 4. Permission has been granted by the California Dental Association to use excerpts and photos from this article.

considered when evaluating a patient for dental implants: thorough medical and dental histories, clinical photographs, study casts, periapical and panoramic radiographs as well as linear tomography or computerized tomography of the proposed implant sites.

The most important step in treatment planning is determining the prognosis for the dentition, and in particular the prognosis of the tooth in question. Reasons for tooth extraction may include, but are not limited to, insufficient crown to root ratio, remaining root length, periodontal attachment level, furcation involvement, periodontal health status of teeth adjacent to the proposed implant site, nonrestorable caries lesions, root fractures with large endodontic posts, root resorption and questionable teeth in need of endodontic retreatment (7). Teeth requiring root amputation, hemisection, or advanced periodontal procedures may have a questionable prognosis and patients should be given reasonable options before implementing such treatments. Similarly, implants to replace teeth with nonvital pulp, fractured at the gingival margin with roots shorter than 13 mm, is often considered the treatment of choice (46). If employing traditional methods of treatment, such teeth will require crown-lengthening procedures, endodontic treatment, and posts and crowns. Removing 3 mm or more of the periodontal attachment during crown lengthening may result in a root length with a less than optimal attachment level. The factors above are especially critical when questionable teeth are being considered for abutments for fixed partial dentures. The cost-benefit ratio of various treatment options must also be considered.

In the esthetic zone, the scallop of the periodontium, level of crestal and interproximal bone, smile line, and morphology of the gingival tissues must be considered before initiating treatment (11, 38, 39, 65, 80). Proposed inter-implant distance, as well as existing contact relationships and interproximal bone, must be analyzed before implant placement (81, 82). Patients with a thin or moderately thin periodontium will often show soft tissue recession at implanted sites. In these situations it is advisable to use orthodontic forced eruption procedures before tooth removal and implantation. This allows bone and soft tissues to move coronally, thereby assuring adequate mucosal tissue adjacent to the implant. In the case of soft tissue deficiency or a slight soft tissue recession after tooth extraction, subepithelial connective tissue grafting can further augment tissue height and thickness, thereby enhancing the esthetic outcome (41, 42).

Radiographic examination should evaluate the availability of native bone and bone shape, quality, quantity, bone width, and bone height. A minimum of 4–5 mm of bone width at the alveolar crest, and at least 10 mm bone length from the alveolar crest to a safe distance above the mandibular canal are recommended (89). Sufficient distance must also be available to the maxillary sinus and the floor of the nose. A satisfactory esthetic result in the esthetic zone requires the interproximal bone height to be 5 mm or less, when measured from the contact point of the adjacent tooth. As the distance from the contact point to the interproximal bone increases, the likelihood of retention of the interproximal papillae after implant placement diminishes. Patients must be made aware of potential esthetic shortcomings if implants are placed in compromised esthetic zones.

Once a patient is considered a candidate for immediate implant, a surgical guide should be used to assure proper implant placement. A provisional appliance with an ovate pontic should be available for insertion after implant placement (26, 37, 90).

Tooth extraction and implant placement procedures

Various surgical flap procedures can be used to gain access for tooth extraction (4). Figure 1(A–L) represents the authors' routine surgical sequence for placement of a single immediate implant in the esthetic zone using a minimally invasive surgical method. Infection may be present, as evidenced by the suppuration exuding from the palatal aspects. Many clinicians postpone treatment of sites exhibiting infection. Novaes et al. (63) and Villa & Rangert (86) recently reported on a case series of patients where implants were installed immediately after extraction, and where the extracted teeth exhibited signs of periodontal or endodontic infections. At 2 years post-treatment, the cumulative survival rate was 100%. This study indicated no adverse consequences for an implanted site after extracting an infected tooth. Teeth to be removed and implants placed immediately after extraction can be accessed using either open flap surgery or a minimally invasive surgical technique. With experience the surgeon can displace the marginal tissues buccal-lingually to gain access to the surgical site. A Molt C2 curette (HiFriedy, Chicago, IL) is useful to luxate the root mesial-distally. To avoid damaging the buccal plate, care must be exercised not to luxate buccal-lingually.

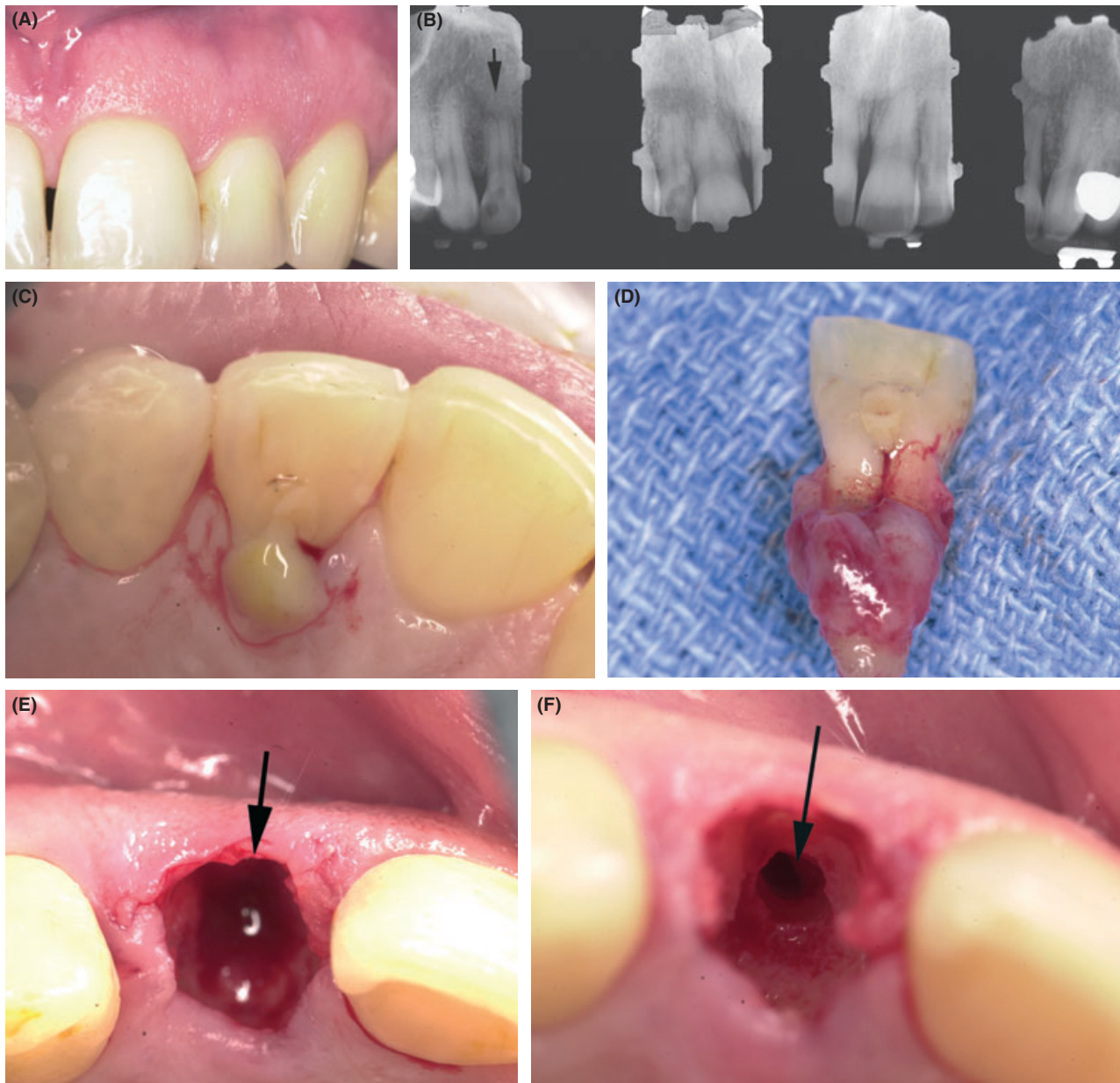


Fig. 1. (A) The maxillary left lateral incisor has a blunted short root with a severe palatal infection related to a nonvital tooth. (B) Left maxillary lateral incisor (arrow) has a blunted apex, possible coronal fracture, and a draining abscess. (C) Suppuration expressed from palatal aspect of maxillary left lateral incisor. (D) Extensive palatal granulation tissue. (E) Tooth has been extracted; arrow points to socket. (F) Osteotomy has been prepared in palatal aspect of extraction socket. (G) Guide pin within palatal aspect of surgical guide. (H) Implant has been

inserted into osteotomy and a 4-mm healing abutment has been placed on the implant. Arrow points to gap between mucosal tissue and healing abutment. (I) Bovine bone has been layered into gap between mucosal tissue and abutment (arrow). (J) Tissues sutured with no attempt to advance flap over bovine bone particles. (K) Two-year follow-up photograph. Note how interdental papillae fill entire embrasure spaces. There is slight soft tissue inflammation between lateral and canine. (L) Two-year follow-up radiograph. Note stable interproximal bone.

After tooth removal, a curette is used to confirm that the location of the buccal plate is intact. The surgical guide is placed over the surgical site and a sharp precision drill (Nobel Biocare, Yorba Linda, CA) (Fig. 2) is used to penetrate the palatal wall of the extraction socket. This drill guides the initial

preparation of an osteotomy. In the maxillary anterior region it is important to avoid placing the implant directly into the extraction socket. Otherwise, the implant will invariably perforate the buccal plate and jeopardize implant survival. The axis of the implant must correspond to the incisal edges of the

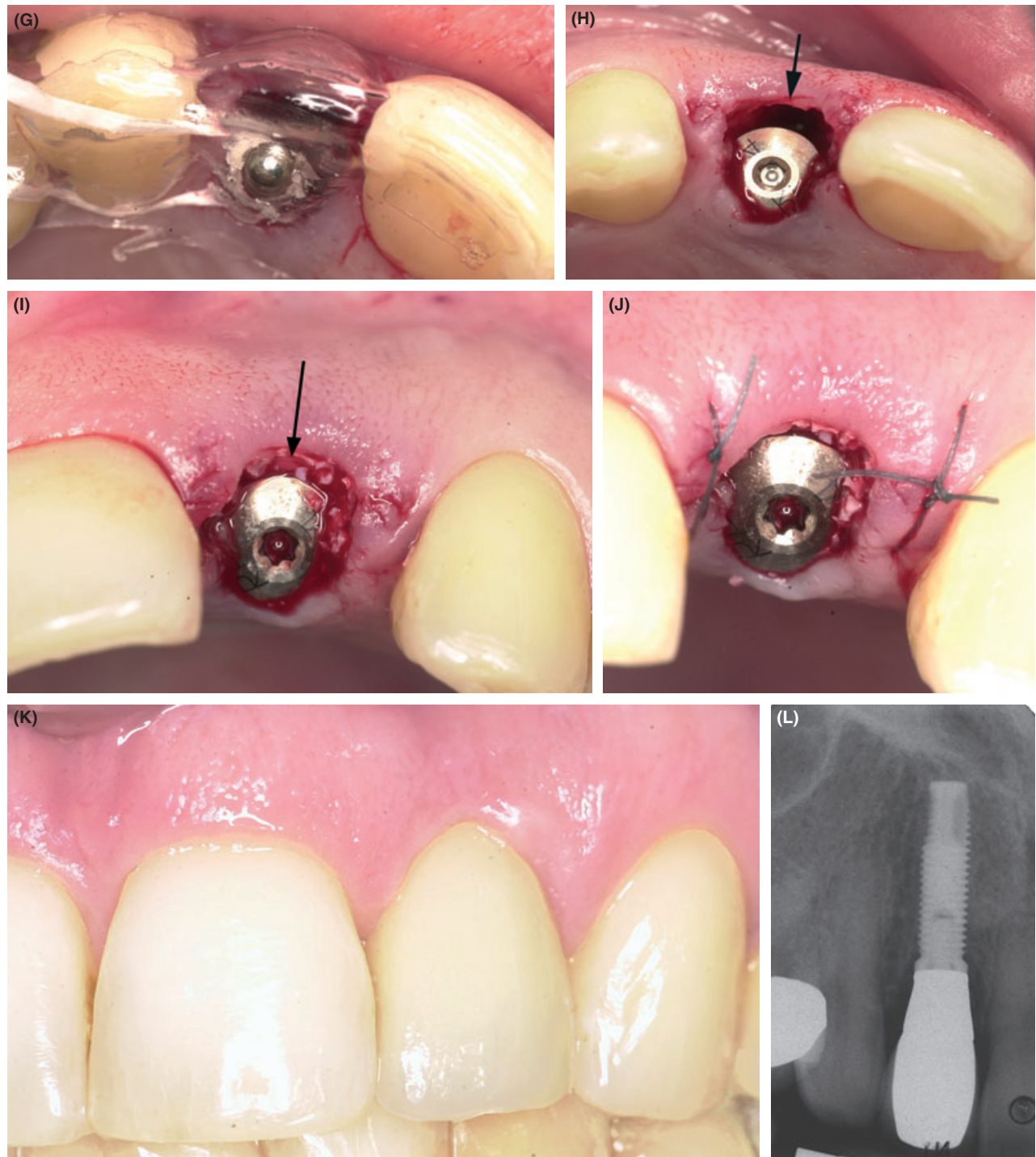

Fig. 1. Continued.

adjacent teeth or be slightly palatal to this landmark. A direction indicator should be used to verify the correct angulation and trajectory of the proposed implant (Fig. 1G). Standard drilling procedures are performed according to the manufacturer's instructions. In the esthetic zone, the implant head should be a minimum of 3 mm apical to an imaginary line connecting the cemento–enamel junctions of the

adjacent teeth and apical to the interproximal and crestal bone (43). This will assure a proper implant emergence profile and facilitate proper implant restoration. The stability of the implant can be verified using resonance frequency analysis (13). The torque registered on the drilling consul can also be a good indicator of initial implant stability. Torque resistance of 40 Newton centimeters is indicative of

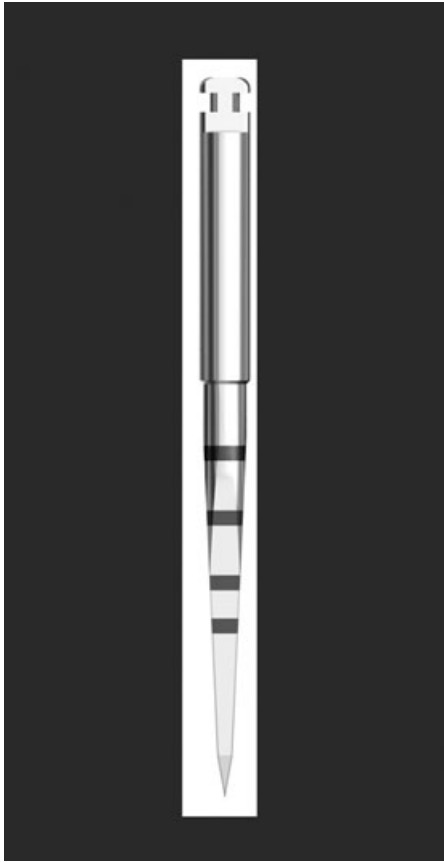


Fig. 2. Precision drill with markings at 8, 10, 13, and 16 mm.

initial implant stability. Excessive torque should not be applied to the implant because this may strip the implant threads or exert excessive compression on the adjacent bone, potentially leading to bone necrosis and implant loss. Fixture level impressions are frequently made immediately after implant placement. This facilitates the fabrication of prosthetic abutments and provisional restorations. Abutments and provisional restorations can be inserted onto implants once osseointegration has been verified after a proper healing interval. A healing abutment can be inserted on the top of the implant (Fig. 1H). The healing abutment should be even with, or slightly apical to, the adjacent marginal tissues. Interproximal papillae adjacent to the implant can be adapted with interrupted sutures under minimal tension (Fig. 1J). The provisional restoration is then inserted, making certain the pontic is clear of the healing abutment. The provisional restoration should have an ovate pontic to support the adjacent tissues and help preserve the soft tissue anatomy adjacent to the implant. The patient is instructed in proper post-surgical care and sutures are removed in 7–10 days. Restoration of the implant can take place once

osseointegration has been confirmed (maxillary anterior region 4–6 months) (Fig. 1K,L). In the event that an immediately placed implant encroaches upon the maxillary sinus, it might be prudent to postpone implant placement, augment the sinus, allow for bone healing, and then place the implant.

The bony gap

On occasion, the marginal tissues do not adapt to the healing abutment. With a wide gap, experimental studies have shown that connective tissue will form between the coronal implant aspect and the surrounding bone (3, 24). With small gaps, on the other hand, animal and human studies have demonstrated bone fill between the implant and the bone, with or without the use of grafting material or barrier membranes (14–19, 77, 78). Botticelli et al. (18) produced 1.0–2.5 mm wide circumferential bony defects in dogs. Over a 4-month healing period the circumferential defects healed with bone fill-in. At a few sites, the labial bone adjacent to the extraction socket was reduced in height. In implant sites with reduced labial bone, proper bone healing occurred at the mesial, distal, and lingual defect aspects. In another study by the same authors, bony gaps were left between implants and surrounding bone. Some test sites were augmented with bovine bone, alone or with a resorbable barrier, while other sites were left to heal spontaneously. At 4 months, all the defects filled with newly formed bone and the biomaterial placed in the marginal defect in conjunction with implant installation became incorporated into the newly formed bone tissue. A high degree of contact was established between the bovine bone particles and the newly formed bone. In the model used, bovine bone *did not* enhance the process of bone formation or defect closure. Recently, a prospective trial reported on the efficacy of combinations of membranes and autogenous bone grafts at immediate implant sites (25). Sixty-two consecutively treated patients each received an immediate implant for a single tooth replacement at a maxillary anterior or premolar site. Dimensions of the peri-implant defect at the implant collar were measured as vertical defect height, horizontal defect depth, and horizontal defect width. Each implant randomly received one of five augmentation treatments and was submerged with connective tissue grafts: Group 1 – expanded polytetrafluoroethylene membrane only, Group 2 – resorbable polylactide/polyglycolide copolymer membrane only, Group 3 – resorbable membrane

and autogenous bone graft, Group 4 – autogenous bone graft only, and Group 5 – no membrane and no bone graft (control). At re-entry, all groups showed significant reduction in vertical defect height, horizontal defect depth, and horizontal defect width. Comparisons between groups showed no significant differences in reduction of vertical defect height (mean 75%) (92) and horizontal defect depth (mean 77%). Significant differences were observed between groups for horizontal defect width reduction (range, 34.1–67.3%), and the membrane-treated Groups 1, 2, and 3 showed the greatest reduction. In the presence of dehiscence defects of the labial plate, a horizontal defect width reduction of 66.6% occurred with the use of membranes compared to 37.7% without membranes. More than 50% higher labial bone plate resorption occurred in the presence of a dehiscence defect irrespective of the augmentation treatment used. The results indicate that vertical defect height and horizontal defect depth reduction at defects adjacent to immediate implants may be achieved without the use of membranes and/or bone grafts.

In practice, when a bony gap is present, no effort is made to surgically advance the flap (Fig. 1H). A small amount of allograft or alloplast is *layered* between the bony margin and the implant abutment (Fig. 1I). This material is left exposed. Within a few weeks some of the material will exfoliate and gingival mucosa will migrate over the exposed materials and provide an uneventful healing.

Results from studies using bovine bone to augment small gaps adjacent to immediately placed implants demonstrate that the bovine bone does not affect the survival of implants (84, 91). It is important to recognize that placement of bovine bone, allografts, or other substances with or without barrier membranes may support or improve soft tissue contours; however, these materials cannot be relied upon to enhance osseointegration.

Socket preservation

Socket preservation is a relatively new term in implant dentistry, which implies the placement of various implantable materials within extraction sockets to maintain the socket anatomy. To date, there is inconclusive evidence that this procedure maintains the original socket dimensions. In contrast, evidence exists that placement of foreign materials into extraction sockets may interfere with normal bone formation (6, 8). Iasella et al. (36) compared normal socket healing with those grafted with demineralized

freeze-dried bone and covered with a collagen barrier membrane. Unaugmented sockets decreased in width by an average of 1.7 mm, while grafted sites decreased by 1.2 mm (a difference of 0.5 mm). The quantity of bone observed on histological analysis was slightly greater in preservation sites, although these sites included both vital and nonvital bone. Other researchers have compared alveolar ridge dimensions and histological characteristics of ridges preserved with two different graft materials (83). Twenty-four subjects, each requiring a nonmolar extraction and delayed implant placement, were randomly selected to receive ridge preservation treatment with either an allograft in an experimental putty carrier plus a calcium sulfate barrier, or a bovine-derived xenograft plus a collagen membrane. Horizontal and vertical ridge dimensions were determined using a digital caliper and a template. At 4 months post-extraction, a trephine core of bone was obtained for histological analysis. Allograft mixed with an experimental putty carrier produced significantly more vital bone fill than did the use of a xenograft with no carrier material. Ridge width and height dimensions were similarly preserved with both graft materials.

There is evidence that resorbable barriers, without concomitant grafting, reduce alveolar ridge resorption after tooth extraction (45, 85). Following elevation of buccal and lingual full-thickness flaps and extraction of teeth, experimental sites were covered with bio-absorbable membranes; control sites received no barrier membrane. Titanium pins served as fixed reference points for measurements. Flaps were advanced to achieve primary closure of the surgical wound, and no membrane exposure occurred during the course of healing. Re-entry surgery performed after 6 months showed that experimental sites presented with significantly less loss of alveolar bone height, more internal socket bone fill, and less horizontal resorption of the alveolar bone ridge. This study suggests that treatment of extraction sockets with membranes made of glycolide and lactide polymers is of value in preserving alveolar bone in extraction sockets and preventing alveolar ridge defects. Use of barrier membranes may be indicated to minimize crestal alveolar bone resorption in cases where dental implants are not part of the treatment plan. However, placement of implants into membrane-treated sites may cause limited osseointegration as the result of formation of sub-optimal bone. Until there is sufficient evidence that barrier membranes can maintain socket anatomy without interfering with osseointegration, caution should be exercised when using such treatment in implant dentistry.

Soft tissue management for immediate implants

Primary flap closure over immediately placed implants was considered important for many years (4, 22, 31). The discrepancy of size and form between the extraction socket and an immediate implant ensures that a space usually exists around the coronal portion of the implant. Frequently, pre-existing bony defects can also be found in the extraction area. Depending

on size, the bony defects may be treated with regenerative techniques (5, 49). Soft tissue coverage of the implant area was considered necessary to achieve bone fill adjacent to the implant. The presence of interdental bone, soft tissue anatomy, smile line, occlusion, and interdental space are all important factors in the placement of immediate implants in the esthetic zone (30, 39, 47, 66, 74).

Various surgical techniques have been proposed to achieve primary soft tissue closure with immediate implants (4, 70, 71, 73). Use of a rotated buccal flap

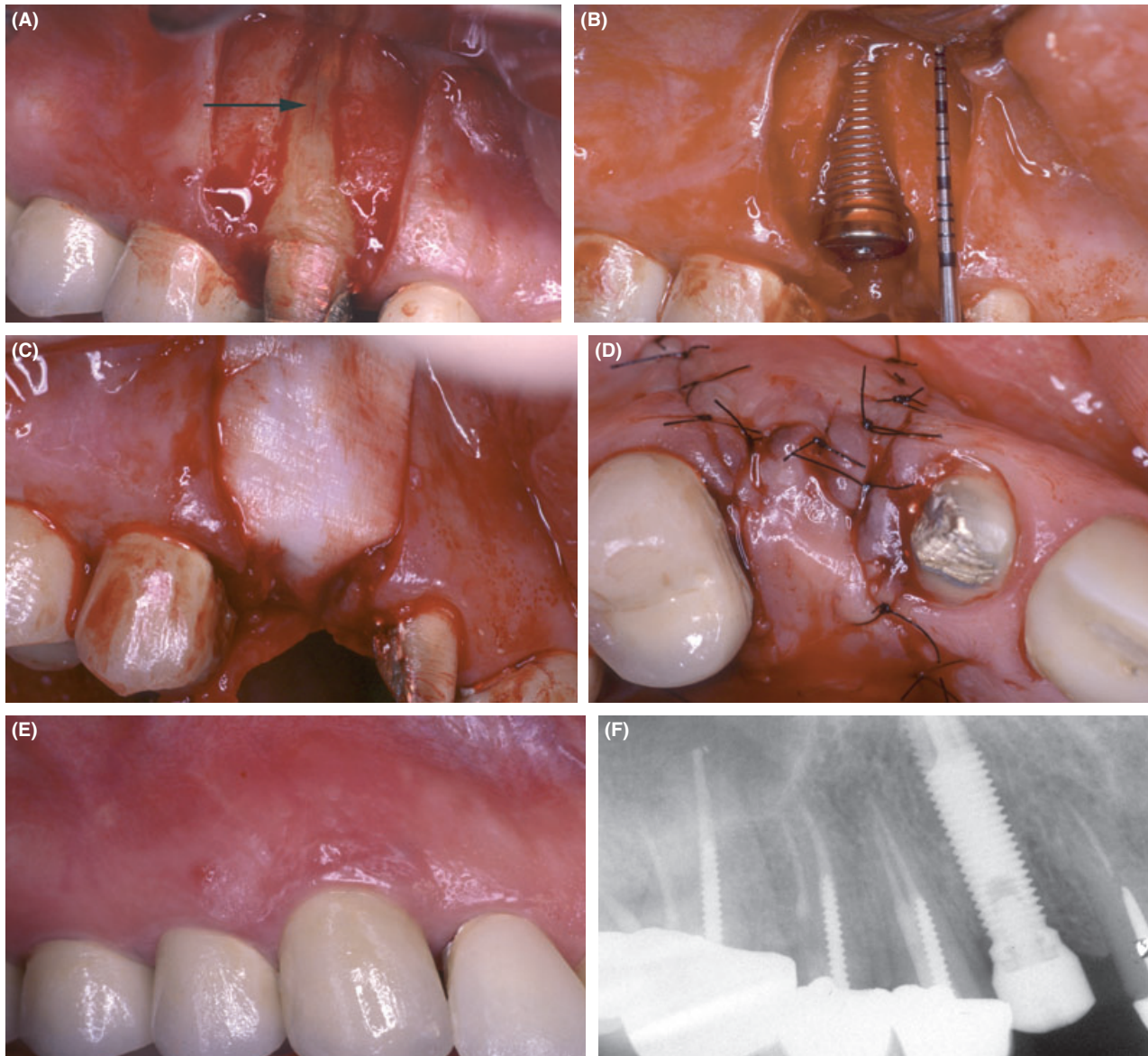


Fig. 3. (A) Maxillary second bicuspid with a vertical fracture (arrow) and buccal dehiscence. (B) A machined-surface implant has been installed in the osteotomy. There were 13 threads exposed and the implant was stable. (C) A collagen membrane has been adapted over the allograft and implant site. (D) A pedicle flap has been

rotated from the palate and sutured over the implant and grafted site. (E) At 6 months the implant was uncovered and the final restoration was placed. There is slight marginal inflammation. (F) Radiograph taken after 6 months of healing and before final restoration.

from an adjacent tooth can be used to achieve closure over implants placed at the time of extraction. This procedure can be applied for single or multiple implant sites and can be employed in conjunction with membrane barriers or various grafting materials. The main disadvantage of this technique is the requirement for an adequate width of keratinized mucosa and vestibule depth. Edel (27) was the first to publish on the use of a connective tissue graft for coverage of immediately placed implants. A potential problem is the limitation of donor tissue size. In periodontal plastic surgery, an acellular dermal matrix allograft is sometimes employed as an alternative to autologous connective tissue. Acellular dermal matrix has also been used alone or with various grafting materials to cover immediately placed implant sites (28, 29, 64). Gingival grafts have been used as well to augment sites that have received immediately placed implants. Esthetic outcomes from this technique are good, but the procedure requires a second surgery for graft procurement (40). The palatal advanced flap or pediculated flap is another useful surgical technique for maxillary immediate implant cases (Fig. 3A–F) (32, 48, 54–59). The technique provides adequate tissue mobility and bulk, facilitating a complete, precise, and highly predictable coverage of the extraction site in large defect areas, and in cases of multiple implants. The main disadvantage of this technique is the prolonged and uncomfortable secondary palatal tissue healing.

Conclusions

This paper has reviewed the history, predictability, rationale, treatment planning steps, and treatment for implant placement immediately after tooth extraction. Multicenter studies have validated the predictability of placing implants at the time of extraction provided these procedures are appropriately planned. To date, evidence for placement of bone substitutes adjacent to small bone defects related to immediately placed implants indicates that this technique appear safe, although these materials do not appear predictably to promote osseointegration. There is insufficient evidence that 'socket preservation' procedures predictably maintain socket anatomy without crestal resorption. Bone substitutes implanted into extraction sockets may interfere with normal bone healing and ultimately osseointegration. A minimally invasive surgical technique in the placement of immediate implants offers several

advantages and should be employed wherever possible.

References

1. Adell R, Eriksson B, Lekholm U, Branemark PI, Jemt T. Long-term follow-up study of osseointegrated implants in the treatment of totally edentulous jaws. *Int J Oral Maxillofac Implants* 1990; **5**: 347–359.
2. Adell R, Lekholm U, Branemark PI. A 15-year study of osseointegrated implants in the treatment of the edentulous jaw. *Int J Oral Surg* 1985; **10**: 387–418.
3. Akimoto K, Becker W, Donath K, Becker BE, Sanchez R. Formation of bone around titanium implants placed into zero wall defects: pilot project using reinforced e-PTFE membrane and autogenous bone grafts. *Clin Implant Dent Relat Res* 1999; **1**: 98–104.
4. Becker W, Becker BE. Flap designs for minimization of recession adjacent to maxillary anterior implant sites: a clinical study. *Int J Oral Maxillofac Implants* 1996; **11**: 46–54.
5. Becker W, Becker BE, Handelsman M. Guided tissue regeneration for implants placed into extraction sockets and for implant dehiscences: surgical techniques and case report. *Int J Periodontics Restorative Dent* 1990; **10**: 376–391.
6. Becker W, Becker BE, Polizzi G, Bergstrom C. Autogenous bone grafting of bone defects adjacent to implants placed into immediate extraction sockets in patient: a prospective study. *Int J Oral Maxillofac Implants* 1994; **9**: 389–396.
7. Becker W, Becker BE, Ricci A, Bahat O, Rosenberg E, Rose LF, Handelsman M, Israelson H. A prospective multicenter clinical trial comparing one- and two-stage titanium screw-shaped fixtures with one-stage plasma-sprayed solid-screw fixtures. *Clin Implant Dent Relat Res* 2000; **2**: 159–165.
8. Becker BE, Becker W, Ricci A, Geurs N. A prospective clinical trial of endosseous screw-shaped implants placed at the time of tooth extraction without augmentation. *J Periodontol* 1998; **69**: 920–926.
9. Becker W, Dahlin C, Becker BE, Lekholm U, van Steenberghe D, Higuchi K, Kultje C. The use of e-PTFE barrier membranes for bone promotion around titanium implants placed into extraction sockets: a prospective multicenter study. *Int J Oral Maxillofac Implants* 1994; **9**: 31–40.
10. Becker W, Huijoe P, Becker BE. Effect of barrier membranes and autogenous bone afts on ridge width preservation around implants. *Clin Implant Dent Relat Res* 2002; **4**: 143–149.
11. Becker W, Ochsenein C, Tibbetts L, Becker BE. Alveolar bone anatomic profiles as measured from dry skulls. Clinical ramifications. *J Clin Periodontol* 1997; **24**: 727–731.
12. Becker W, Sennerby L. A new era. *Clin Implant Dent Relat Res* 1999; **1**: 1.
13. Becker W, Sennerby L, Bedrossian E, Becker BE, Lucchini JP. Implant stability measurements for implants placed at the time of extraction: a cohort, prospective clinical trial. *J Periodontol* 2005; **76**: 391–397.
14. Berman F. The creation of an ovate pontic at the time of extraction. *Dent Today* 2003; **22**: 48–49.
15. Botticelli D, Berglundh T, Buser D, Lindhe J. Appositional bone formation in marginal defects at implants. *Clin Oral Implants Res* 2003; **14**: 1–9.

16. Botticelli D, Berglundh T, Buser D, Lindhe J. The jumping distance revisited: an experimental study in the dog. *Clin Oral Implants Res* 2003; **14**: 35–42.
17. Botticelli D, Berglundh T, Lindhe J. Hard-tissue alterations following immediate implant placement in extraction sites. *J Clin Periodontol* 2004; **31**: 820–828.
18. Botticelli D, Berglundh T, Lindhe J. The influence of a biomaterial on the closure of a marginal hard tissue defect adjacent to implants. An experimental study in the dog. *Clin Oral Implants Res* 2004; **15**: 285–292.
19. Botticelli D, Berglundh T, Lindhe J. Resolution of bone defects of varying dimension and configuration in the marginal portion of the peri-implant bone. An experimental study in the dog. *J Clin Periodontol* 2004; **31**: 309–317.
20. Botticelli D, Berglundh T, Persson LG, Lindhe J. Bone regeneration at implants with turned or rough surfaces in self-contained defects. An experimental study in the dog. *J Clin Periodontol* 2005; **32**: 448–455.
21. Brånemark PI, Hansson BO, Adell R, Breine U, Lindström J, Hallén O, Ohman A. Osseointegrated implants in the treatment of the edentulous jaw. Experience from a 10-year period. *Scand J Plast Reconstr Surg Suppl.* 1977; **16**: 1–132.
22. Branemark PI, Svensson B, van Steenberghe D. Ten-year survival rates of fixed prostheses on four or six implants ad modum Branemark in full edentulism. *Clin Oral Implants Res* 1995; **6**: 227–231.
23. Buser D, Dula K, Belser U, Hirt HP, Berthold H. Localized ridge augmentation using guided bone regeneration. 1. Surgical procedure in the maxilla. *Int J Periodontics Restorative Dent* 1993; **13**: 29–45.
24. Carlsson L, Rostlund T, Albrektsson B, Albrektsson T. Implant fixation improved by close fit. Cylindrical implant–bone interface studied in rabbits. *Acta Orthop Scand* 1988; **59**: 272–275.
25. Chen ST, Darby IB, Adams GG, Reynolds EC. A prospective clinical study of bone augmentation techniques at immediate implants. *Clin Oral Implants Res* 2005; **16**: 176–184.
26. Dylina TJ. Contour determination for ovate pontics. *J Prosthet Dent* 1999; **82**: 136–142.
27. Edel A. The use of a connective tissue graft for closure over an immediate implant covered with occlusive membrane. *Clin Oral Implants Res* 1995; **6**: 60–65.
28. Fowler EB, Breault LG, Rebitski G. Ridge preservation utilizing an acellular dermal allograft and demineralized freeze-dried bone allograft: Part I. A report of 2 cases. *J Periodontol* 2000; **71**: 1353–1359.
29. Fowler EB, Breault LG, Rebitski G. Ridge preservation utilizing an acellular dermal allograft and demineralized freeze-dried bone allograft: Part II. Immediate endosseous implant placement. *J Periodontol* 2000; **71**: 1360–1364.
30. Garber DA. The esthetic dental implant: letting restoration be the guide. *J Oral Implantol* 1996; **22**: 45–50.
31. Gher ME, Quintero G, Sandifer JB, Tabacco M, Richardson AC. Combined dental implant and guided tissue regeneration therapy in humans. *Int J Periodontics Restorative Dent* 1994; **14**: 332–347.
32. Goldstein M, Boyan BD, Schwartz Z. The palatal advanced flap: a pedicle flap for primary coverage of immediately placed implants. *Clin Oral Implants Res* 2002; **13**: 644–650.
33. Gotfredsen K, Nimb L, Buser D, Hjorting Hansen E. Evaluation of guided bone generation around implants placed into fresh extraction sockets: an experimental study in dogs. *J Oral Maxillofac Surg* 1993; **51**: 879–884.
34. Grunder U, Polizzi G, Goené R, Hatano N, Henry P, Jackson WJ, Kawamura K, Köhler S, Renouard F, Rosenberg R, Triplett G, Werbit M, Lithner B. A 3-year prospective multicenter follow-up report on the immediate and delayed-immediate placement of implants. *Int J Oral Maxillofac Implants* 1999; **14**: 210–216.
35. Hermann JS, Buser D. Guided bone regeneration for dental implants. *Curr Opin Periodontol* 1996; **3**: 168–177.
36. Iasella JM, Greenwell H, Miller RL, Hill M, Drisko C, Bohra AA, Scheetz JP. Ridge preservation with freeze-dried bone allograft and a collagen membrane compared to extraction alone for implant site development: a clinical and histologic study in humans. *J Periodontol* 2003; **74**: 990–999.
37. Johnson GK, Leary JM. Pontic design and localized ridge augmentation in fixed partial denture design. *Dent Clin North Am* 1992; **36**: 591–605.
38. Kan JY, Rungcharassaeng K, Umezu K, Kois JC. Dimensions of peri-implant mucosa: an evaluation of maxillary anterior single implants in humans. *J Periodontol* 2003; **74**: 557–562.
39. Kois JC. Predictable single tooth peri-implant esthetics: five diagnostic keys. *Compend Contin Educ Dent* 2004; **25**: 895–905; quiz 905.
40. Landsberg CJ. Socket seal surgery combined with immediate implant placement: a novel approach for single-tooth replacement. *Int J Periodontics Restorative Dent* 1997; **17**: 140–149.
41. Langer B. The esthetic management of dental implants. *Dent Econ* 1995; **85**: 86–87.
42. Langer B, Langer L. Overlapped flap: a surgical modification for implant fixture installation. *Int J Periodontics Restorative Dent* 1990; **10**: 208–215.
43. Langer B, Sullivan DY. Osseointegration: its impact on the interrelationship of periodontics and restorative dentistry. Part 3. Periodontal prosthesis redefined. *Int J Periodontics Restorative Dent* 1989; **9**: 240–261.
44. Lazzara RJ. Immediate implant placement into extraction sites: surgical and restorative advantages. *Int J Periodontics Restorative Dent* 1989; **9**: 332–343.
45. Lekovic V, Camargo PM, Klokkevold PR, Weinlaender M, Kenney EB, Dimitrijevic B, Nedic M. Preservation of alveolar bone in extraction sockets using bioabsorbable membranes. *J Periodontol* 1998; **69**: 1044–1049.
46. Lovdahl P. Endodontic retreatment. *Dent Clin North Am* 1992; **36**: 473–490.
47. Magne P, Magne M, Belser U. The diagnostic template: a key element to the comprehensive esthetic treatment concept. *Int J Periodontics Restorative Dent* 1996; **16**: 560–569.
48. Mathews DP. The pediculated connective tissue graft: a technique for improving unaesthetic implant restorations. *Pract Proced Aesthet Dent* 2002; **14**: 719–724 quiz 726.
49. Mellonig JT, Nevins M. Guided bone regeneration of bone defects associated with implants: an evidence-based outcome assessment. *Int J Periodontics Restorative Dent* 1995; **15**: 168–185.
50. Mellonig JT, Triplett RG. Guided tissue regeneration and endosseous dental implants. *Int J Periodontics Restorative Dent* 1993; **13**: 108–119.
51. Meredith N, Alleyne D, Cawley P. Quantitative determination of the stability of the implant–tissue interface using

- resonance frequency analysis. *Clin Oral Implants Res* 1996; **7**: 261–267.
52. Meredith N, Book K, Friberg B, Jemt T, Sennerby L. Resonance frequency measurements of implant stability *in vivo*. A cross-sectional and longitudinal study of resonance frequency measurements on implants in the edentulous and partially dentate maxilla. *Clin Oral Implants Res* 1997; **8**: 226–233.
 53. Meredith N, Shagaldi F, Alleyne D, Sennerby L, Cawley P. The application of resonance frequency measurements to study the stability of titanium implants during healing in the rabbit tibia. *Clin Oral Implants Res* 1997; **8**: 234–243.
 54. Nelson SW. The subpedicle connective tissue graft. A bilaminar reconstructive procedure for the coverage of denuded root surfaces. *J Periodontol* 1987; **58**: 95–102.
 55. Nemcovsky CE, Artzi Z. Split palatal flap. II. A surgical approach for maxillary implant uncovering in cases with reduced keratinized tissue: technique and clinical results. *Int J Periodontics Restorative Dent* 1999; **19**: 385–393.
 56. Nemcovsky CE, Artzi Z, Moses O. Rotated split palatal flap for soft tissue primary coverage over extraction sites with immediate implant placement. Description of the surgical procedure and clinical results. *J Periodontol* 1999; **70**: 926–934.
 57. Nemcovsky CE, Artzi Z, Moses O. Rotated palatal flap in immediate implant procedures. Clinical evaluation of 26 consecutive cases. *Clin Oral Implants Res* 2000; **11**: 83–90.
 58. Nemcovsky CE, Artzi Z, Moses O, Gelernter I. Healing of dehiscence defects at delayed-immediate implant sites primarily closed by a rotated palatal flap following extraction. *Int J Oral Maxillofac Implants* 2000; **15**: 550–558.
 59. Nemcovsky CE, Moses O. Rotated palatal flap. A surgical approach to increase keratinized tissue width in maxillary implant uncovering: technique and clinical evaluation. *Int J Periodontics Restorative Dent* 2002; **22**: 607–612.
 60. Nevins M, Jovanovic SA. Localized bone reconstruction as an adjunct to dental implant placement. *Curr Opin Periodontol* 1997; **4**: 109–118.
 61. Nevins M, Mellonig JT. Enhancement of the damaged edentulous ridge to receive dental implants: a combination of allograft and the GORE-TEX membrane. *Int J Periodontics Restorative Dent* 1992; **12**: 96–111.
 62. Nevins M, Mellonig JT. The advantages of localized ridge augmentation prior to implant placement: a staged event. *Int J Periodontics Restorative Dent* 1994; **14**: 96–111.
 63. Novaes Junior AB, Novaes AB. Immediate implants placed into infected sites: a clinical report. *Int J Oral Maxillofac Implants* 1995; **10**: 609–613.
 64. Novaes Junior AB, Papalexiou V, Luczyszyn SM, Muglia VA, Souza SL, Taba Junior M. Immediate implant in extraction socket with acellular dermal matrix graft and bioactive glass: a case report. *Implant Dent* 2002; **11**: 343–348.
 65. Ochsenein C, Ross S. A reevaluation of osseous surgery. *Dent Clin North Am* 1969; **13**: 87–102.
 66. Phillips K, Kois JC. Aesthetic peri-implant site development. The restorative connection. *Dent Clin North Am* 1998; **42**: 57–70.
 67. Polizzi G, Rangert B, Lekholm U, Gualini F, Lindstrom H. Branemark System Wide Platform implants for single molar replacement: clinical evaluation of prospective and retrospective materials. *Clin Implant Dent Relat Res* 2000; **2**: 61–69.
 68. Rasmusson L, Meredith N, Kahnberg KE, Sennerby L. Stability assessments and histology of titanium implants placed simultaneously with autogenous onlay bone in the rabbit tibia. *Int J Oral Maxillofac Surg* 1998; **27**: 229–235.
 69. Rasmusson L, Meredith N, Kahnberg KE, Sennerby L. Effects of barrier membranes on bone resorption and implant stability in onlay bone grafts. An experimental study. *Clin Oral Implants Res* 1999; **10**: 267–277.
 70. Rasmusson L, Meredith N, Sennerby L. Measurements of stability changes of titanium implants with exposed threads subjected to barrier membrane induced bone augmentation. An experimental study in the rabbit tibia. *Clin Oral Implants Res* 1997; **8**: 316–322.
 71. Rosenquist B. A comparison of various methods of soft tissue management following the immediate placement of implants into extraction sockets. *Int J Oral Maxillofac Implants* 1997; **12**: 43–51.
 72. Rosenquist B, Ahmed M. The immediate replacement of teeth by dental implants using homologous bone membranes to seal the sockets: clinical and radiographic findings. *Clin Oral Implants Res* 2000; **11**: 572–582.
 73. Rosenquist B, Grenthe B. Immediate placement of implants into extraction sockets: implant survival. *Int J Oral Maxillofac Implants* 1996; **11**: 205–209.
 74. Salama H, Salama M, Garber D, Adar P. Developing optimal peri-implant papillae within the esthetic zone: guided soft tissue augmentation. *J Esthet Dent* 1995; **7**: 125–129.
 75. Schwartz-Arad D, Chaushu G. Placement of implants into fresh extraction sites: 4 to 7 years retrospective evaluation of 95 immediate implants. *J Periodontol* 1997; **68**: 1110–1116.
 76. Schwartz-Arad D, Chaushu G. The ways and wherefores of immediate placement of implants into fresh extraction sites: a literature review. *J Periodontol* 1997; **68**: 915–923.
 77. Scipioni A, Bruschi GB, Calesini G. The edentulous ridge expansion technique: a five-year study. *Int J Periodontics Restorative Dent* 1994; **14**: 451–459.
 78. Scipioni A, Bruschi GB, Giargia M, Berglundh T, Lindhe J. Healing at implants with and without primary bone contact. An experimental study in dogs. *Clin Oral Implants Res* 1997; **8**: 39–47.
 79. Sennerby L, Meredith N. Resonance frequency analysis: measuring implant stability and osseointegration. *Compend Contin Educ Dent* 1998; **19**: 493–498, 500, 502: quiz 504.
 80. Spear FM, Mathews DM, Kokich VG. Interdisciplinary management of single-tooth implants. *Semin Orthod* 1997; **3**: 45–72.
 81. Tarnow D, Elian N, Fletcher P, Froum S, Magner A, Cho SC, Salama M, Salama H, Garber DA. Vertical distance from the crest of bone to the height of the interproximal papilla between adjacent implants. *J Periodontol* 2003; **74**: 1785–1788.
 82. Tarnow DP, Magner AW, Fletcher P. The effect of the distance from the contact point to the crest of bone on the presence or absence of the interproximal dental papilla. *J Periodontol* 1992; **63**: 995–996.
 83. ten Bruggenkate CM, Kraaijenhagen HA, van der Swast WA, Krekeler G, Oosterbeek HA. Autogenous maxillary bone grafts in conjunction with placement of ITI endosseous implants. A preliminary report. *Int J Oral Maxillofac Surg* 1996; **21**: 81–84.

84. van Steenberghe D, Callens A, Geers L, Jacobs R. The clinical use of deproteinized bovine bone mineral on bone regeneration in conjunction with immediate implant installation. *Clin Oral Implants Res* 2000; **11**: 210–216.
85. Vance GS, Greenwell H, Miller RL, Hill M, Johnston H, Scheetz JP. Comparison of an allograft in an experimental putty carrier and a bovine-derived xenograft used in ridge preservation: a clinical and histologic study in humans. *Int J Oral Maxillofac Implants* 2004; **19**: 491–497.
86. Villa R, Rangert B. Early loading of interforaminal implants immediately installed after extraction of teeth presenting endodontic and periodontal lesions. *Clin Implant Dent Relat Res* 2005; **7** (Suppl. 1): S28–S35.
87. Wagenberg B, Froum SJ. A retrospective study of 1925 consecutively placed immediate implants from 1988 to 2004. *Int J Oral Maxillofac Implants* 2006; **21**: 71–80.
88. Wagenberg BD, Ginsburg TR. Immediate implant placement on removal of the natural tooth: retrospective analysis of 1,081 implants. *Compend Contin Educ Dent* 2001; **22**: 399–404, 406, 408 passim; quiz 412.
89. Worthington P. Injury to the inferior alveolar nerve during implant placement: a formula for protection of the patient and clinician. *Int J Oral Maxillofac Implants* 2004; **19**: 731–734.
90. Zitzmann NU, Marinello CP, Berglundh T. The ovate pontic design: a histologic observation in humans. *J Prosthet Dent* 2002; **88**: 375–380.
91. Zitzmann NU, Naef R, Scharer P. Resorbable versus non-resorbable membranes in combination with Bio-Oss for guided bone regeneration [published erratum appears in *Int J Oral Maxillofac Implants* 1998;13:576]. *Int J Oral Maxillofac Implants* 1997; **12**: 844–852.
92. Zitzmann NU, Scharer P, Marinello CP. Long-term results of implants treated with guided bone regeneration: a 5-year prospective study. *Int J Oral Maxillofac Implants* 2001; **16**: 355–366.