

University of Pennsylvania Libraries

NOTICE WARNING CONCERNING COPYRIGHT RESTRICTIONS

The copyright law of the United States (title 17, United States Code) governs the making of photocopies or other reproductions of copyrighted material.

Under certain conditions specified in the law, libraries and archives are authorized to furnish a photocopy or other reproduction. One of these specific conditions is that the photocopy or reproduction is not to be "used for any purpose other than private study, scholarship, or research." If a user makes a request for, or later uses, a photocopy or reproduction for purposes in excess of "fair use," that user may be liable for copyright infringement.

This institution reserves the right to refuse to accept a copying order if, in its judgment, fulfillment of the order would involve violation of copyright law.

This notice is posted in compliance with Title 37 C.F.R., Chapter II, Part 201.14

# ILLiad Request Printout

---

Transaction Number: 165523  
Username: barnettf Name: Frederic Barnett Status: Faculty  
ISSN/ISBN: 0022-3492  
NotWantedAfter: 12/31/2010  
Accept Non English: Yes  
Accept Alternate Edition: No  
Request Type: Article - Article

## Loan Information

---

LoanAuthor:  
LoanTitle:  
LoanPublisher:  
LoanPlace:  
LoanDate:  
LoanEdition:  
NotWantedAfter: 12/31/2010

## Article Information

---

PhotoJournalTitle: Journal of periodontology  
PhotoJournalVolume: 43  
PhotoJournalIssue: 4  
Month: 04  
Year: 1972  
Pages: 202-8  
Article Author: Simon, J H JH  
Article Title: The relationship of endodontic-periodontic lesions.

## Citation Information

---

Cited In: Entrez:PubMed (Via SFX)  
Cited Title:  
Cited Date:  
Cited Volume:  
Cited Pages:

## OCLC Information

---

ILL Number:  
OCLC Number: 4505605  
Lending String:  
Original Loan Author:  
Original Loan Title:  
Old Journal Title:  
Call Number:  
Location:

## Notes

---

# The Relationship of Endodontic-Periodontic Lesions

by

JAMES H. S. SIMON,\* A.B., D.D.S.

DUDLEY H. GLICK,\*\* B.S., D.D.S.

ALFRED L. FRANK,\*\*\* D.D.S.

THE CORRELATION OF ENDODONTIC and periodontic radicular lesions has aroused controversy and confusion inasmuch as dentists have become increasingly more aware of the relationship between the attachment apparatus and the pulp. This article will offer a classification of these lesions based on their possible etiology, diagnosis and prognosis of treatment. Only by careful diagnosis and proper classification can the most effective treatment plan be selected.

Although others<sup>2, 3, 4, 5</sup> have classified these lesions in varying degrees, we can theoretically delineate five types of lesion formation that are interrelated (Figure 1). These will be discussed individually.

## Primary Endodontic Lesions

Clinically, these lesions may appear concurrently with drainage from the gingival sulcus area and/or swelling in the buccal attached gingiva. Although the patient may be aware of minimal discomfort, pain is not usually present. An initial clinical impression is that these are of periodontic origin. However, they are periodontic only in that they pass through the periodontal ligament area. In reality, they are fistulas resulting from pulpal disease.

Radiographically, different levels of bone loss may be apparent depending on the avenue of fistulation. The necrotic pulp may cause a fistulous tract from the apex through the periodontium along the mesial or distal root surface, to exit at the cervical line. This appears as a radiolucency along the entire root length (Figure 2a, Figure 3, Figure 4). This is not a totally dark radiolucent area, instead a greyish, bony matrix may

\*Chief, Endodontic Section, V.A. Hospital, Long Beach, California and Clinical Assistant Professor of Endodontics, University of Southern California.

\*\*Clinical Professor of Endodontics, University of Southern California.

\*\*\*Clinical Professor of Endodontics, University of Southern California.

Reprint requests are to be sent to: James H. Simon, D.D.S. (600/160), Veterans Administration Hospital, 5901 E. 7th Street, Long Beach, California 90801.

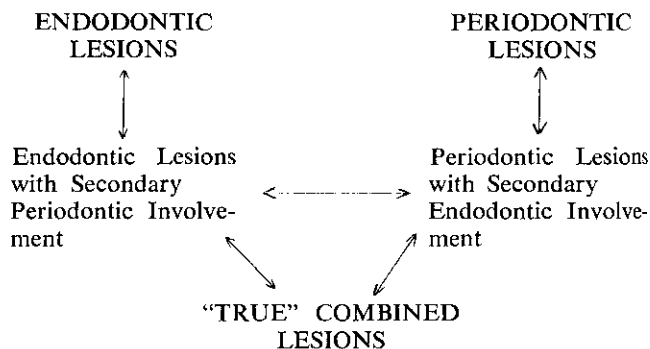


FIGURE 1. The clinical interrelationship of these five types of lesions is readily apparent.

be visible. These lesions may occur on any maxillary or mandibular tooth.

Fistulation can also occur from the apex into the bifurcation area which, radiographically, creates the appearance of periodontal involvement. A similar radiographic appearance may result from continual pulpal irritation through an accessory canal<sup>6, 7</sup> which opens into the bifurcation area (Figure 2b & Figure 5). Diagnostically, one should be suspicious of a pulpally induced lesion when the crestal bone level on the mesial and distal appears relatively normal and only the bifurcation area is radiolucent.

Another possibility results from fistulation through an accessory canal some distance from the apex on the mesial or distal which resembles an infra-bony pocket. (Figure 2a and Figure 6).

It must be pointed out that if fistulation occurs on the buccal or lingual aspect and is superimposed over the tooth root, a radiolucency may not appear on the radiograph. This also could be true of upper molars where the palatal root screens the view of the trifurcation area. Thus it is imperative that a gutta percha or silver cone be inserted into the fistulous tract and x-rayed to determine the origin of the lesion. However, when the pulp does not respond to an electric vitalometer or thermal tests; it is evident a necrotic pulp may be the offender. In addition, when probing, a minimal amount of calculus or plaque formation is encountered. In reality, these are not periodontic lesions but rather fistulas of endodontic origin. They will heal with endodontic therapy alone.

## Primary Endodontic Lesions With Secondary Periodontic Involvement

After a period of time if this primary endodontic problem remains untreated, it may then become secondarily involved with periodontal breakdown. Plaque may begin to form at the gingival margin which could result in a periodontitis (Figure 2c & Figure 7). The

treatment  
a problem  
This to  
dentic  
dental  
are ade  
of the  
seconda  
ing of  
ticipate

## Primary

These  
Periodo  
root sur  
2d & Fi  
superim  
the usual  
reveals  
surface

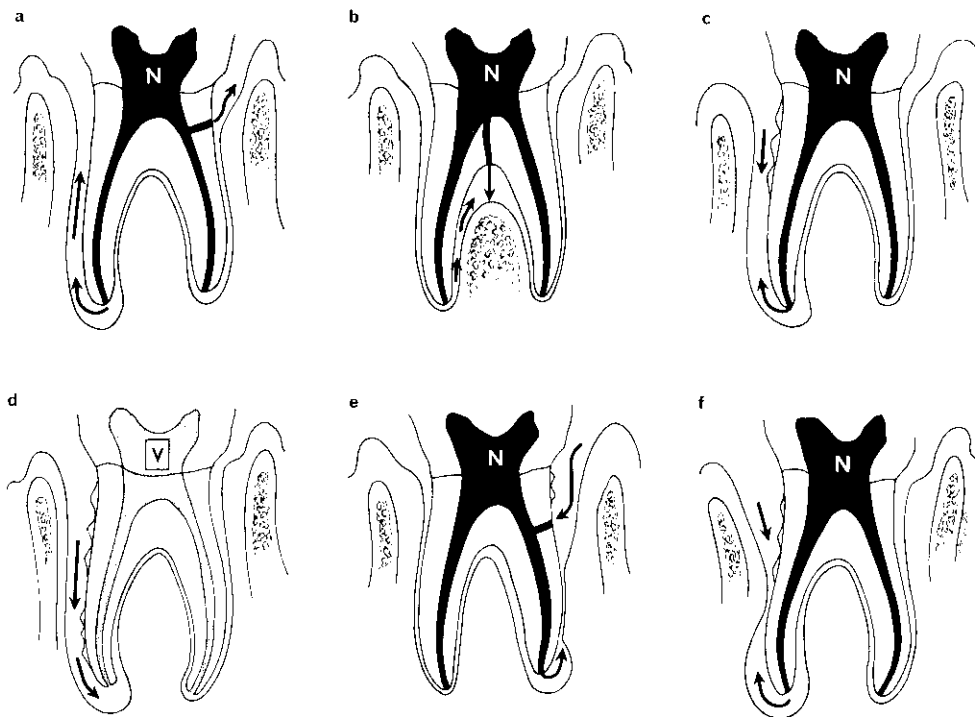


FIGURE 2. (a) Endodontic Lesions. The pathway of fistulation is evident through the periodontal ligament from the apex or a lateral canal. (b) Fistulation through the apex or a lateral canal may cause bifurcation involvement. (c) Primary Endodontic Lesion with Secondary Periodontic Involvement. The existing pathway as in 2a is shown but with the passage of time periodontitis with calculus formation begins at the cervical area. (d) Periodontic Lesions. This is the progression of periodontitis to apical involvement. Note the vital pulp. (e) Primary Periodontic Lesion with Secondary Endodontic Involvement. The primary periodontic involvement at the cervical margin and the resultant pulp necrosis once the lateral canal is exposed to the oral environment result in this picture. (f) "True" Combined Lesions. The two separate lesions are heading to a coalescence which forms the "true" combined lesion.

treatment and prognosis of the tooth are altered when a probe or explorer encounters plaque or calculus. This tooth now requires both endodontic and periodontic therapy. The prognosis depends on the periodontal therapy, assuming the endodontic procedures are adequate. With endodontic therapy alone, only part of the lesion may heal which indicates the presence of secondary periodontic involvement. In general, healing of the endodontically induced areas may be anticipated.

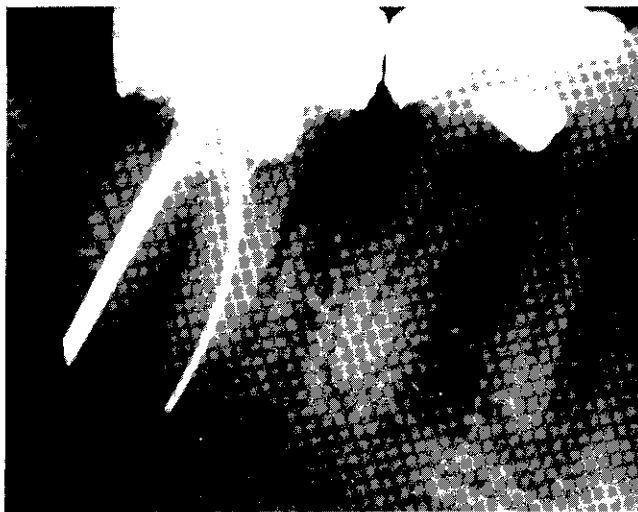
#### Primary Periodontic Lesions

These lesions are caused by periodontal disease. Periodontitis gradually progresses unchecked along the root surface until the apical region is reached (Figure 2d & Figure 8). Occlusal trauma may or may not be superimposed in these lesions. Diagnosis is based on the usual periodontic test procedures. Probing usually reveals calculus for varying lengths along the root surface and the pulp responds vitally to endodontic

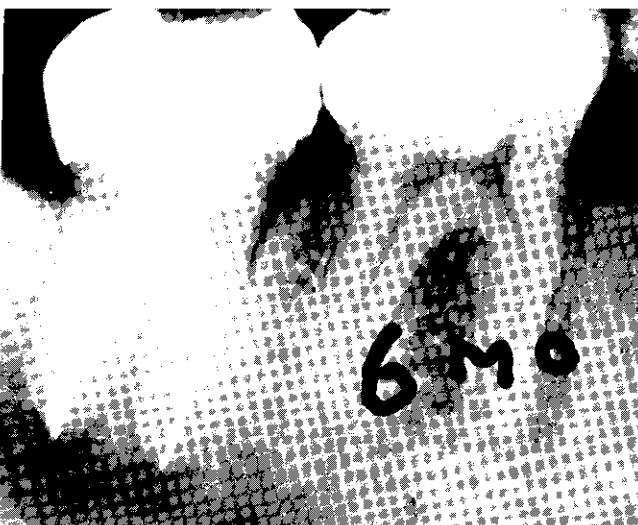testing procedures. The diagnostician must also be aware of the radiographic appearance of periodontal disease associated with developmental radicular anomalies.<sup>8</sup> Sugarman and Sugarman<sup>9</sup> have raised the question of diagnosis on teeth with full coverage. In this instance the test cavity is extremely useful. A small hole is drilled through the crown and into the dentin with a highspeed #1/2 or #2 round burr, without the use of local anesthesia. The positive reaction to cutting dentin without coolants often will confirm a vital pulp. This is indicative of a periodontal lesion. The prognosis in this situation depends wholly upon the efficacy of periodontal therapy.

#### Primary Periodontic Lesions With Secondary Endodontic Involvement

As periodontal lesions progress toward the apex, lateral or accessory canals may be exposed to the oral environment which can lead to necrosis of the pulp<sup>10</sup> (Figure 2e). In addition, pulp necrosis can result



3A



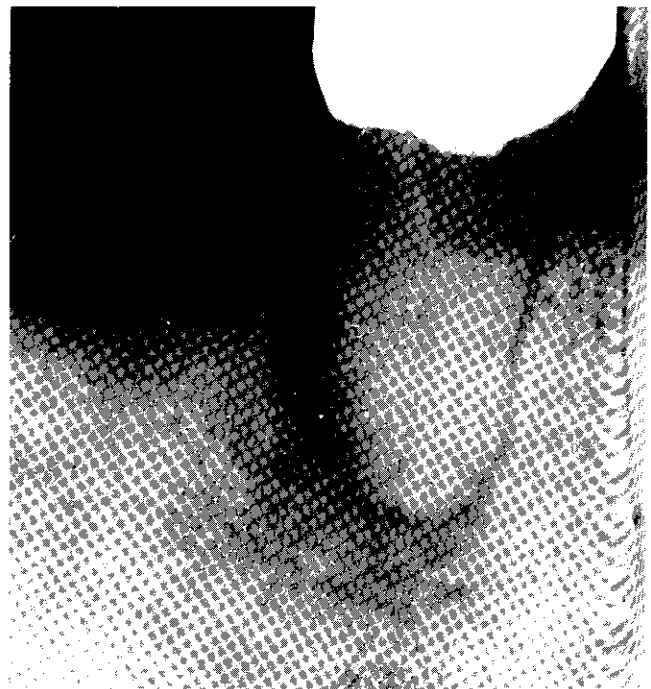
3B

FIGURE 3. The rather typical radiographic appearance on the distal is evident. Six month recall shows the radiolucency almost healed. Note the bony stroma visible on the distal.

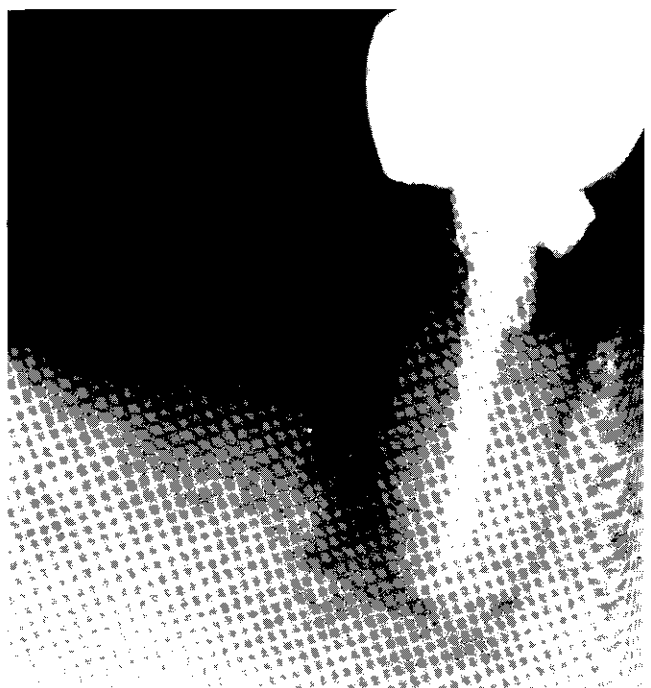from periodontal procedures where the blood supply, through an accessory canal or the apex is severed by a curette.

These primary periodontal lesions with secondary endodontic involvement may be radiographically indistinguishable from primary endodontic lesions with secondary periodontic involvement. Teeth undergoing periodontal therapy that do not respond as anticipated, should be pulp tested. It may be that the previously vital tooth is now necrotic. Again the prognosis depends on the periodontal therapy once the endodontic therapy has been solved. Periodontal treatment alone will suffice in the presence of a pulpally involved tooth.

Recently, there has been research to determine the




4A



4B

FIGURE 4. Demonstrates the same radiographic appearance as on the distal of the molar. However, only endodontic therapy is required to accomplish healing.

relationship between periodontal and pulpal disease. Mazur and Massler, 1964,<sup>11</sup> found no correlation between the severity of periodontal disease and the status of the pulp. However, recent studies by others<sup>12, 13, 14</sup> suggests that an interrelationship does exist once the



4C

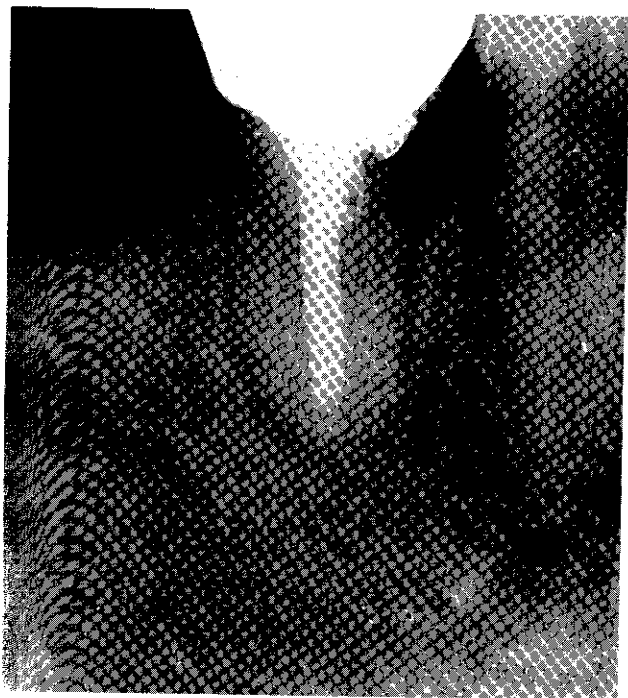
integrity  
research i

"True" C

These l  
periapical  
tally invo  
created w  
where alc  
Ultimately  
distinguish  
secondari  
ticipated  
periodont  
periodont  
involveme

It is in  
appearanc  
If a fistu  
flap to he  
that has p  
also can

We hav  
dodontic  
understan  
their diag



4C

Integrity of the dentinal tubules is violated. Further research in this area is definitely indicated.


*"True" Combined Lesions*

These lesions occur where an endodontically induced periapical lesion exists on a tooth that is also periodontally involved. The radiographic infra-bony defect is created when these two entities meet and merge somewhere along the root surface. (Figure 2f & Figure 9). Ultimately, the clinical and radiographic picture is indistinguishable from the other two lesions that are secondarily involved. Periapical healing may be anticipated following successful endodontic therapy. The periodontic aspects then may or may not respond to periodontal treatment, depending on the severity of involvement.

It is interesting to note that a similar radiographic appearance may result from a vertically fractured tooth. If a fistula is present, it may be necessary to lay a flap to help determine the exact etiology. A fracture that has penetrated to the pulp with resultant necrosis, also can be labelled a "true" combined lesion.

SUMMARY

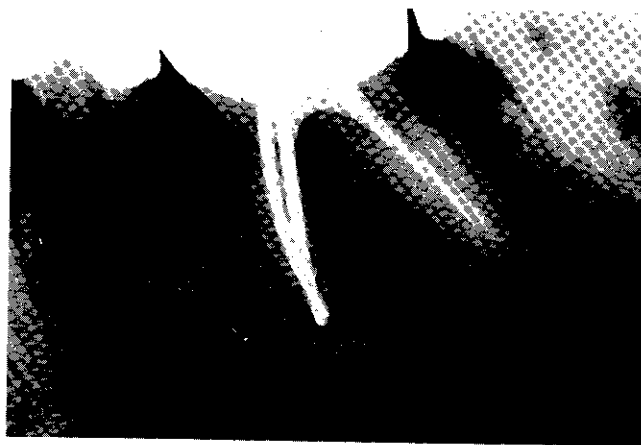
We have presented an etiologic classification of endodontic and periodontic lesions. To better recognize, understand and treat these problems, we have discussed their diagnosis and prognosis from a clinical standpoint



5A

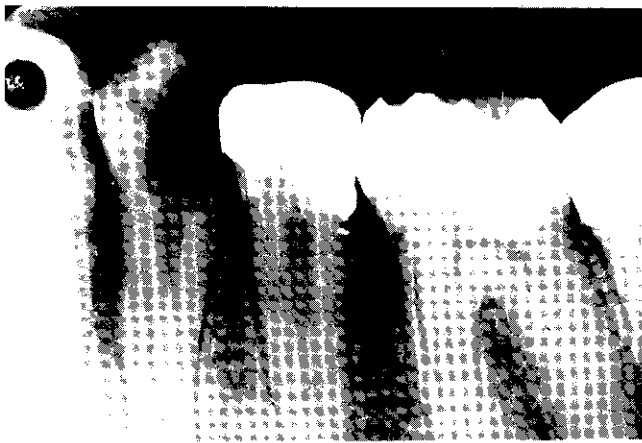

5B




5C


FIGURE 5. Radiographic bifurcation involvement is readily visible. Since the pulp was necrotic only endodontic therapy was performed. Complete radiographic healing is apparent nine months later. Note lateral canal opening into the bifurcation.



6A

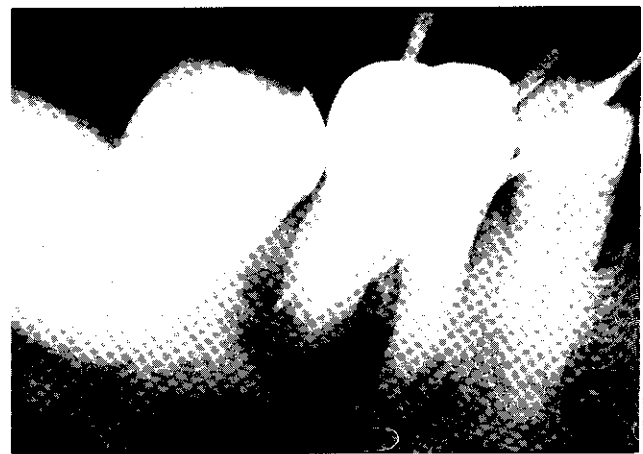


6B

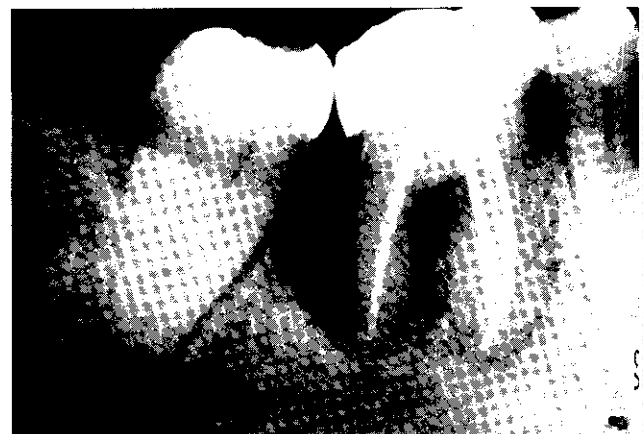

6C

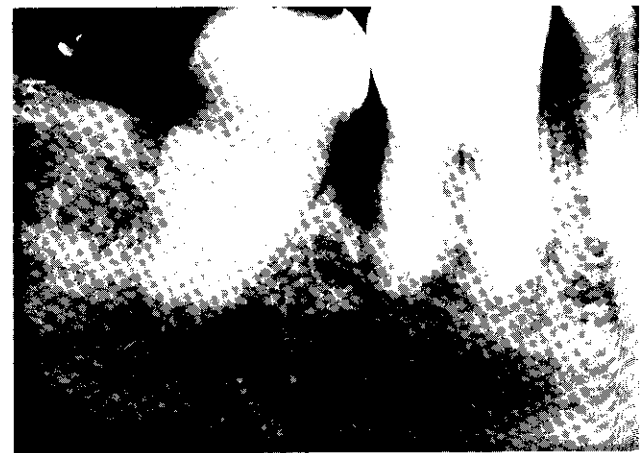
FIGURE 6. The mesial radiolucency on the first bicuspid resembles an infrabony pocket. Since the pulp was non-vital, endodontic therapy was completed. The lateral canal that showed on the post-operative x-ray was not anticipated. However, in spite of a poorly condensed filling, healing of both the mesial and periapical areas occurred.



7A




7B




7C

FIGURE 7. This was initially diagnosed as a primary endodontic lesion. However, on 3 year follow-up examination only partial healing is seen radiographically. On probing the distal aspect calculus was encountered and the diagnosis of secondary periodontitis was made.



8A

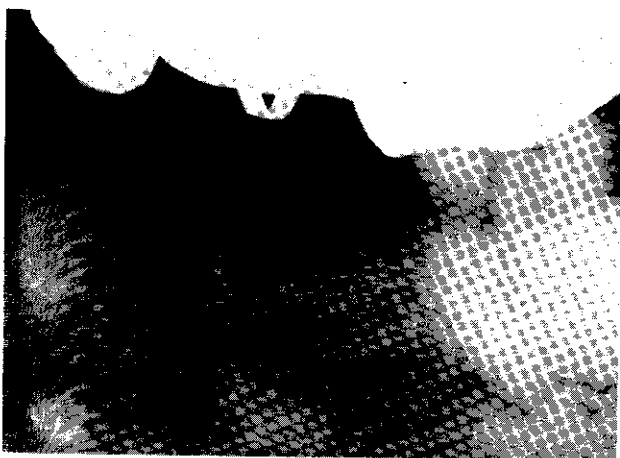


8B

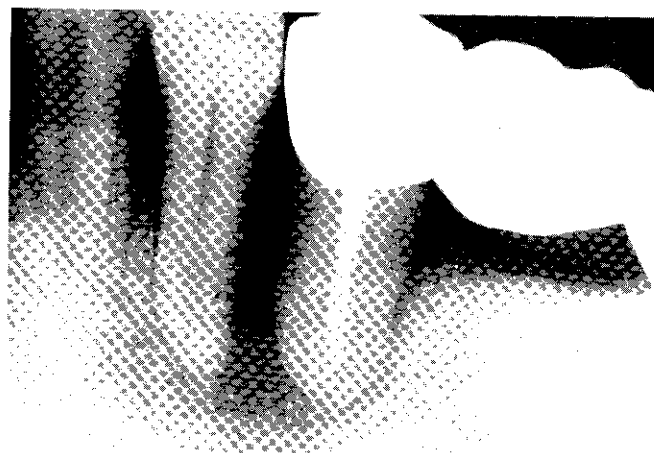
FIGURE 8. The opposite ultimate face of the tooth showed this a periodontal lesion.

in order to  
treatment.



1. Schile, "Endodontics: A Reference on the University of Pennsylvania,"
2. American Journal of Orthodontics and Facial Orthodontics, "An Important Periodontal Problem,"
3. "Beginning Periodontal Therapy," February, 1968, July, 1968.
4. Olieck, "The Role of the Endodontic Treatment in the Management of Periodontitis,"



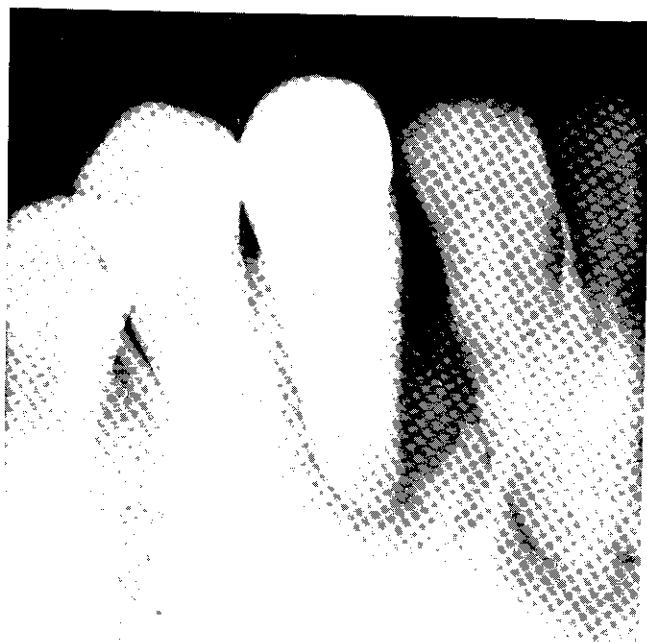
8A



8C



8B



9A

FIGURE 8. This is the reverse situation as in Figure 4. It is the opposite side of the same patient. This case went on to ultimate failure because of misdiagnosis. As the records showed this to have a vital healthy pulp, this was purely a periodontal problem.

FIGURE 9. The lesion involving the cuspid was diagnosed as a "true" combined lesion. The tooth was both super-erupted and lingually tipped. The cuspid had endodontic therapy including attempts at an autogenous bone marrow transplant. In spite of everything healing in the endodontic area occurred.

In order to explain the success or failure that follows treatment.

#### REFERENCES

1. Schilder, H., "The Relationship of Periodontics to Endodontics," *Transactions of the Third International Conference on Endodontics* (Louis I. Grossman, editor), University of Pennsylvania, Philadelphia, 1963.
2. Amen, C. R., "When is the Condition of the Pulp an Important Consideration in Periodontal Disease?", *Periodontal Abstract*, 15:7-8, March, 1967.
3. Begin, J. F., "Perio-Endo Considerations: Combined Therapy," *Royal Canadian Dent. Corps Quarterly*, 9:1-5, July, 1968.
4. Oliet, S. and Pollock, S., "Classification and Treat-

- ment of Endo-Perio Involved Teeth," *Phila. Co. Dent. Soc. Bulletin*, 34:12-16, Nov., 1968.
5. Simon, P. and Jacobs, P., "The So-Called Combined Periodontal Pulpal Problem," *Dent. Clinics of N.A.*, 13:45-53, W. B. Saunders Co., 1969.
6. Seltzer, S., Bender, I. B., and Zonti, M., "The Interrelationship of Pulp and Periodontal Disease," *O.S., O.M., and O.P.*, 16:1474-1490, Dec., 1963.
7. Winter, G. B. and Kramer, I. R. H., "Changes in

ary en-  
camina-  
n prob-  
the di-





9B



9C

Periodontal Membrane and Bone Following Experimental Pulpal Injury in Deciduous Molar Teeth in Kittens," Arch. Oral. Biol., 10:279-289, 1965.

8. Simon, J. H., Glick, D. H., and Frank, A. L., "Predictable Endodontic and Periodontic Failures as a Result of Radicular Anomalies," O.S., O.M., and O.P. 31:823-826, June 1971.

9. Sugarman, M. M., and Sargarman, E. F., "The Differential Diagnosis of Periodontic - Endodontic Problems," J. Alabama Dent. Assoc., 53:16-24, July 1969.

10. Rubach, W. C., and Mitchell, D. F., "Periodontal Disease, Accessory Canals, and Pulp Pathosis," J. Periodont., 36:34-38. Jan.-Feb., 1965.

11. Mazur, B., and Massler, M., "Influence of Periodontal Disease on the Dental Pulp," O.S., O.M., and O.P. 17:592-603, May, 1964.

12. Stahl, S. S., "Pathogenesis, of Inflammatory Lesions in Pulp and Periodontal Tissues," Periodontics, 4:190-196, July-August, 1966.

13. Seltzer, S., Bender, I. B., Nazimov, H., et al., "Pulpitis-Induced Interradicular Periodontal Changes in Experimental Animals," J. Periodont., 38:124-129, Mar.-April, 1967.

14. Stallard, R. E., "Periodontal Disease and Its Relationship to Pulpal Pathology," Am. Inst. of Oral Biology Annual Meeting, pages 197-203, 1967.

## Relati Endoc

by

HERMAN

ALL DEN  
tain the t  
health and  
are vitally  
structures  
in many f  
of root ca  
dontics, s  
tial in or  
forces of

Periodo  
ratus (ce  
bone), at  
to these s  
lar bone,  
developm  
of period  
and mobi  
volved too  
loss. Apic  
ment app  
of pulpal  
to crestal  
regenerati  
after endo

Because  
ervation t  
important  
inter-relat  
of the pul  
A brief r  
the period  
tationship.

Pulpal  
caused by  
cases of p  
which bac  
Chemical

\*Instruct  
Dentistry;  
40506.