

# Periodontal parameters and cervical root resorption during orthodontic tooth movement

Catherine Giannopoulou<sup>1</sup>, Alexander Dudic<sup>2</sup>, Xavier Montet<sup>3</sup>, Stavros Kiliaridis<sup>2</sup> and Andrea Mombelli<sup>1</sup>

<sup>1</sup>Department of Periodontology;

<sup>2</sup>Department of Orthodontics and

<sup>3</sup>Department of Cell Physiology and

Metabolism, University of Geneva, Geneva Switzerland

Giannopoulou C, Dudic A, Montet X, Kiliaridis S, Mombelli A. Periodontal parameters and cervical root resorption during orthodontic tooth movement. *J Clin Periodontol* 2008; doi: 10.1111/j.1600-051X.2008.01211.x.

## Abstract

**Objectives:** To assess the relationship between periodontal parameters and cervical root resorption in orthodontically moved teeth.

**Material and Methods:** In a standardized experimental tooth movement in 16 periodontally healthy subjects, 29 pre-molars were tipped buccally for 8 weeks. Eighteen contralateral pre-molars not subjected to orthodontic movement served as controls. Plaque Index (PI), Gingival Index (GI), probing depth and bleeding on probing were assessed three times before and six times during the experimental phase. Teeth were extracted and scanned in a micro-computed tomography scanner. The presence or absence, and the severity of cervical root resorption were evaluated on the three-dimensional reconstruction of the scans by two calibrated examiners.

**Results:** Overall, periodontal parameters were not different between the test and the control teeth. Clear signs of buccal cervical resorption were detected on 27 of 29 orthodontically moved teeth and on one control tooth. Ten subjects had perfect oral hygiene and no gingivitis, whereas six subjects showed a moderate level of plaque and gingivitis (>20% occurrences of PI or GI with >0). No relationship could be demonstrated between resorption and periodontal parameters.

**Conclusions:** Nearly all orthodontically moved teeth showed signs of cervical resorption. Periodontal parameters were unrelated to this important side effect of orthodontic treatment.

Key words: cervical root resorption; orthodontic movement; periodontal parameters

Accepted for publication 13 January 2008

It has been shown that orthodontic forces represent a physical agent capable of inducing an inflammatory reaction in the periodontium. This reaction is necessary for orthodontic tooth movement. The different phases of tooth movement involving the recruitment of different cells such as osteoclast and osteoblast progenitors as well as inflammatory cells have been

extensively investigated (for a review, see Krishnan & Davidovitch 2006). However, the effect of orthodontic movement on the gingiva has been studied to a lesser extent. Unlike bone and periodontal ligament, gingival tissue is not resorbed after orthodontic treatment but is compressed and consequently retracted. The fact that orthodontic force does not induce gingival resorption prevents the formation of periodontal pockets and the detachment of the tooth from the gingiva. However, orthodontic treatment produces a local change in the oral ecosystem, with changes in the composition of bacterial plaque and consequently the development of gingivitis (Huser et al. 1990, Alexander 1991, Paolantonio et al. 1999).

Root resorption is an undesirable side effect of orthodontic treatment. When a tooth is tipped buccally, pressure is created on the cervical part of the buccal side of the tooth and on the apical part of the palatin/lingual side. These pressure areas are the ones where root resorption is mostly expected (Hollender et al. 1980, Linge & Linge 1991, Davidovitch 1996, Kuroi et al. 1996). While apical root resorptions can be seen in radiographs (McFadden et al. 1989, Mirabella & Artun 1995a,b), to diagnose root resorption on the buccal and palatal surfaces of the root, the radiograph is an inadequate tool (Andreasen et al. 1987, Chapnick 1989). Therefore, the inflammatory changes underlying the

## Conflict of interest and source of funding statement

The authors declare that they have no conflict of interests.

The present study was supported by the Swiss National Science Foundation (Grant No. 3200-112296).

remodelling processes necessary for tooth movement have to be investigated in a wider context.

This study explores one aspect of this phenomenon by assessing the potential relationship between clinical periodontal parameters obtained during orthodontically induced tooth movement and cervical root resorption observed after treatment.

## Material and Methods

### Subjects

Sixteen patients (12 females and four males) were selected among patients attending the Orthodontic Department in Geneva for orthodontic treatment. The mean age of the patients was 17.7 years with a range of 11.3–43.0 years. The patients had to meet the following criteria: (i) good general health, (ii) healthy periodontium, i.e., probing depth  $\leq 3$  mm and no radiographic evidence of bone loss, (iii) no radiographic evidence of idiopathic root resorption, (iv) no previous orthodontic treatment, (v) no history of previous dental trauma, (vi) severe crowding in both jaws and (vii) scheduled to begin orthodontic treatment comprising extractions of at least the two or four first or second pre-molars. Informed consent in written form was obtained from the patients (and the parents) before the beginning of the study. The protocol was approved by the Medical Ethics Committee of the University of Geneva.

### Clinical examination

Before the beginning of the study, subjects received oral hygiene instructions and all tooth surfaces were cleaned and polished. Motivation for good plaque control was given to all patients. The following clinical parameters were

assessed at the first (day 0) and all following visits at the buccal, mesial, distal and palatal sites of all pre-molars scheduled for extraction: Plaque Index (PI) (Silness & Loe 1964), Gingival Index (GI) (Løe 1967), periodontal probing depth (PPD) and presence or absence of bleeding on probing (BOP).

### Standardized orthodontic tooth movement

The study was divided into three phases: baseline (day 0, day 7, day 21), the early experimental period (day 28, day 35, day 49) and late experimental period (day 56, day 63, day 77). The outline of the study is shown in Fig. 1.

Each patient contributed with at least one experimental and one control pre-molar. During the baseline period, only periodontal examinations were performed. In the beginning of the early experimental period (day 21), 29 pre-molars randomly assigned to the experimental group were tipped buccally. For this movement, a sectional archwire (0.019  $\times$  0.025 TMA, Ormco, Glendora, CA, USA) was activated buccally and attached with a ligature to the bracket of the experimental tooth in order to exert a 1N force. At day 49 (beginning of the late experimental period), the amount of force was controlled and adjusted. A transpalatal and lingual arch were placed as anchorage. Eighteen contralateral pre-molars bonded with brackets but not subjected to orthodontic tooth movement served as controls. At the end of the whole experimental period (day 77), all pre-molars were carefully extracted, placed in 4% formaldehyde solution and scanned in a micro-computed tomography (CT) scanner.

### Micro-CT acquisition and reconstruction

All images were acquired on a Skyscan-1076 micro-CT (Skyscan, Aartselaar,

Belgium). This system is based on a cone-beam X-ray source and a charge-coupled device camera, and allows acquiring images with resolutions ranging from 35 to 9  $\mu$ m. All scans were acquired at a 9  $\mu$ m resolution using the following parameters: 65 kV anode voltage, 100  $\mu$ A, 0.45° rotation step and 589 ms exposure time per view. For each mode, a 0.5 mm aluminium filter was installed in the beam path to cut off the softest X-rays in order to increase the accuracy of the beam-hardening correction (BHC). These settings allowed to scan a tooth in 90 min.

Cross-sectional images were reconstructed using a classical Feldkamp cone-beam algorithm (Feldkamp et al. 1984). The corrected image data were calibrated in the conventional linear scale of CT number, known as Hounsfield units (HU), defined so that water and air have values of 0 and –1000 HU, respectively.

The three-dimensional (3D) reconstructions of the micro-CT scans were analysed by two calibrated examiners (A. D. and C. G.). The amount of root resorption on the cervical part of the buccal side was assessed semi-quantitatively on randomly sequenced movies and categorized into three groups: (i) those without any resorption, including not more than one barely visible shallow resorption up to an 80  $\mu$ m depth, (ii) those with moderate resorption, including a few small and shallow craters of 80–120  $\mu$ m depth and (iii) those with severe resorption, including several large and deep craters of >120  $\mu$ m depth (Fig. 2).

### Statistics

The following subject-based parameters were generated separately for the experimental teeth and control teeth for the three baseline examinations, the

	Baseline			Early experimental period			Late experimental period		
	Day 0	Day 7	Day 21	Day 28	Day 35	Day 49	Day 56	Day 63	Day 77
			Start of activation	1 week after activation	2 weeks after activation	Reactivation	1 week after reactivation	2 weeks after reactivation	4 weeks after reactivation
Oral hygiene instructions	x	x	x	x	x	x	x	x	
Periodontal examination	x	x	x	x	x	x	x	x	x
Extractions									x

Fig. 1. Outline of the study.

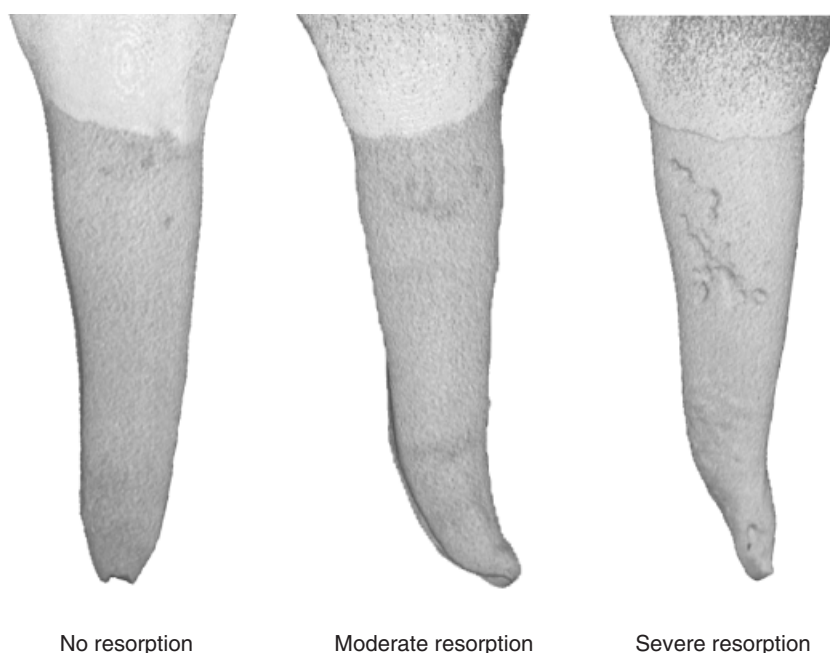


Fig. 2. Presence or absence and severity of cervical root resorption evaluated by two calibrated examiners in one experimental and two control pre-molars of one patient: the first control pre-molar shows no resorption; the second control pre-molar shows moderate resorption; and the third experimental pre-molar shows severe resorption.

Table 1. Observed (in bold) and expected frequencies of buccal cervical root resorption assessment on three-dimensional micro-computed tomography (CT) images

First observer	Second observer			total
	no resorption	moderate resorption	severe resorption	
No resorption				
Observed	<b>11</b>	1	1	13
Expected	3.3		7.7	
Moderate resorption				
Observed	1	<b>5</b>	2	8
Expected		1.2		
Severe resorption				
Observed	0	1	<b>25</b>	26
Expected			15.5	
Total	12	7	28	47

three examinations in the early experimental period and the three examinations of the late experimental period: the percentage of sites per subject with a PI > 0, the percentage of sites per subject with a GI > 0 and the percentage of sites per subject with BOP > 0. In addition, the mean PPD ( $\pm$  standard deviation) was calculated for each subject in each experimental phase by summing the scores and dividing by the number of sites graded. The same parameters were assessed separately for the buccal sites.

The differences between test and control teeth were determined for each

experimental period using the Fisher exact test for PI, GI and BOP and the *t*-test for PPD. The  $\chi^2$  test was used to study the relationship between the patient's hygiene level and the degree of cervical root resorption. *p* values < 0.05 were accepted for statistical significance.

The relationship between resorption and clinical parameters was further tested using logistic regression, with the presence or absence of resorption as the dependent variable and treatment or no treatment and the clinical parameters in the three experimental phases as independent variables.

The statistical analysis was performed using SPSS for Windows (Release 13.0.0., standard version, SPSS Inc., Chicago, IL, USA).

#### Interrater agreement

The interrater agreement on the micro-CT scans was assessed using Cohen's  $\kappa$ . The frequencies for the presence or absence of root resorption on the cervical part of the buccal side of the root assessed by both observers are shown in Table 1. The bold figures along the diagonal show the observed frequencies of agreement when evaluating root resorption on the 3D micro-CT scan images; the corresponding expected frequencies are shown just below. The calculated Cohen's  $\kappa$  is 0.77. There appears to be a substantial agreement between the two observers in the coding of cervical root resorption on the 3D micro-CT scans.

#### Results

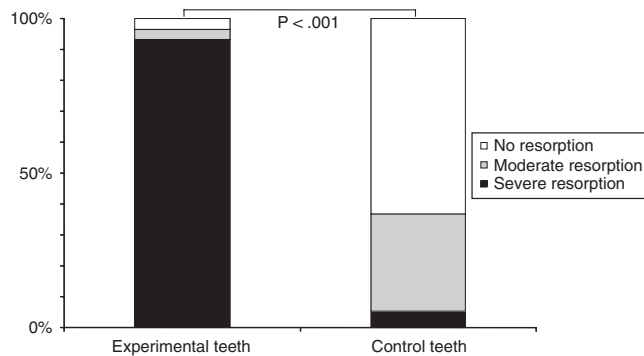
Table 2 shows the mean values of probing depth, the percentage of buccal sites with PI and GI scores > 0 and the percentage of buccal sites that bled upon probing for the experimental and control teeth at baseline (day 0, day 7 and day 21), the early experimental period (day 28, day 35 and day 49) and during the late experimental period (day 56, day 65 and day 77). No significant differences were observed for any of the clinical parameters between experimental and control teeth throughout the study; both showed relatively good periodontal status with a mean PPD below 3 mm, a percentage of scores of PI and GI > 0 not exceeding 26.6% and 19.8%, respectively, and no more than 10% sites with a positive BOP. During the late experimental period, an increase in the number of buccal sites with plaque and/or gingival inflammation was observed for both experimental and control teeth. However, the differences from the baseline and/or the early experimental period were not significant.

Figure 3 shows the presence or absence and the severity of cervical root resorption in the experimental and control teeth evaluated in the 3-D reconstructions of the micro-CT scans. The presence or absence and the severity of apical root resorption are reported in a companion paper. As explained under

**Table 2.** Percentage of buccal sites with PI and GI > 0, BOP positive and PPD (mean ± SD) in experimental (*n* = 29) and control teeth (*n* = 18)

	Baseline			Early experimental period			Late experimental period		
	experimental	control		experimental	control		experimental	control	
PI (> 0)	17.7%	17.5%	NS	21.5%	20.0%	NS	24.7%	26.6%	NS
GI (> 0)	8.0%	9.1%	NS	11.8%	6.6%	NS	19.8%	17.5%	NS
BOP (positive)	3.2%	10.0%	NS	3.7%	4.1%	NS	6.5%	9.1%	NS
PPD (mm)	2.20 ± 0.31	2.05 ± 0.27	NS	2.35 ± 0.38	2.30 ± 0.38	NS	2.36 ± 0.44	2.39 ± 0.38	NS

NS, not significant (*p* > 0.05); PI, Plaque Index; GI, Gingival Index; BOP, bleeding on probing; PPD, pocket probing depth; SD, standard deviation.

**Fig. 3.** Severity of cervical root resorption on the reconstructed micro-computed tomography images.**Table 3.** Relationship between degree of cervical resorption and patients' hygiene level

Hygiene level	Buccal cervical resorption on reconstructed micro-computed tomography (CT) images	
	severe resorption	moderate or no resorption
Moderate ( <i>n</i> = 6)	11 (39%)	11 (58%)
Good ( <i>n</i> = 10)	17 (61%)	8 (42%)

‘‘Material and Methods’’, the amount of root resorption was categorized into three groups: no resorption, moderate resorption and severe resorption. Clear signs of buccal cervical resorption were detected in 27 out of 29 (93%) of the experimental teeth and one out of 18 (5%) of the control teeth. Moderate resorption was observed in one pre-molar of the experimental group (3.4%) and in six pre-molars (33%) of the control group.

Finally, we assessed whether the degree of cervical root resorption is correlated to the patient's level of oral hygiene. Ten subjects had perfect oral hygiene and no signs of gingivitis, whereas six subjects showed a moderate level of plaque and gingivitis (>20% occurrences of PI and GI). However, no

relationship could be demonstrated between resorption and periodontal parameters (Table 3). Logistic regression analysis confirmed these findings as treatment or no treatment was the only significant predictor for the presence or absence of resorption; the clinical parameter had no further significant effect.

## Discussion

The present study was designed to evaluate the relationship between periodontal parameters and cervical root resorption in orthodontically moved teeth. Signs of buccal cervical resorption were obvious on almost all orthodontically moved teeth, as evaluated in the reconstructed images of the micro-CT scanner. However, as no significant differences were observed for any of the periodontal parameters between experimental and control teeth, it was concluded that periodontal parameters are unrelated to cervical root resorption.

Cellular and tissue reactions start immediately after force application: the early phase of orthodontic tooth movement involves an acute inflammatory response characterized by periodontal vasodilation and migration of leucocytes out of the capillaries. Inflammation is essential to tooth movement, resulting,

however, in several undesirable side effects. These effects include mainly the development of gingivitis, root resorption, gingival recession, caries, marginal bone loss and pulpal reactions.

For many years, the extent and depth of a resorbed area on the root surface of an orthodontically moved and then extracted tooth was evaluated by histology (Owman-Moll et al. 1995, Kuroi & Owman-Moll 1998). However, root resorption is a 3D phenomenon and its extent needs to be quantified with precision. The micro-CT scanner is a rapid and accurate method with high resolution, providing enhanced visual and perspective assessment of root surfaces, thus offering a 3D analysis of the cracks. Thus, this method may serve as a gold standard. Hence, due to the high precision we may obtain, histology would not offer any further information.

Concerning the gingival response to tooth movement, wide variations in the clinical appearance have been described, depending on the type of tooth movement (rotation, labial movement), the force, the patient's hygiene level, etc. (for a review, see Redlich et al. 1999). Gingivitis has been described as the most common side effect of orthodontic movement due to plaque accumulation. Several studies have shown that fixed orthodontic therapy is almost always related to inflammation of gingival tissues (Zachrisson & Zachrisson 1972, Kloehn & Pfeifer 1974, Huser et al. 1990, Alexander 1991). This situation is mostly related to hampered oral hygiene and consequently to the accumulation of bacterial plaque. Furthermore, the composition of bacterial plaque following placement of orthodontic appliances changes to a more pathogenic flora (Diamanti-Kipioti et al. 1987, Paolantonio et al. 1996). An orthodontic appliance modifies locally the supragingival environment, thus affecting the colonization and occurrence of specific microorganisms. For example, Paolantonio et al. (1996)

reported a remarkable frequency of detection of *Actinobacillus actinomyces-comitans* (*A.a*) in young individuals wearing orthodontic appliances. The presence of *A.a* was related to the gingival bleeding index but not to the plaque levels. Other pathogenic bacteria such as *Porphyromonas gingivalis*, *Prevotella intermedia*, *Tannerella forsythia* and *Fusobacterium* have been detected after bracket placement, resulting in more gingival inflammation and bleeding (Naranjo et al. 2006). However, these pathogens could be significantly reduced when the orthodontic appliance was removed and professional prophylaxis was given to the patient (Sallum et al. 2004).

The subjects in our study showed almost similar gingival conditions for the experimental and control teeth. This is mainly due to the oral hygiene instructions given to each patient before and during the whole experimental treatment. Several studies have shown that it is possible to achieve and maintain a high standard of gingival health during orthodontic treatment (Lundstrom & Hamp 1980a, Lundstrom et al. 1980b). The slight deterioration of the gingival status observed after 3 months in orthodontically treated children was mainly due to the sub-gingivally located orthodontic bands. In fact, banded teeth may give higher PI and bleeding scores as compared with control teeth (Huser et al. 1990), especially in patients with established gingivitis (Sallum et al. 2004).

Cervical resorption has been described as an aggressively destructive form of external root resorption, classified in the group of inflammatory resorptions and starting sub-gingivally at the cervical root surface of the tooth. Although the aetiology remains uncertain, several predisposing factors have been assessed, such as trauma, intra-oral bleaching, surgery, periodontal root scaling, bruxism and orthodontics. Heithersay (1999a) identified that of all potential predisposing factors, orthodontics was the most common sole factor: when a group of 222 patients displaying varying degrees of invasive cervical resorption was analysed, orthodontics constituted 21.2% of the patients and 24% of the teeth examined. Brezniak & Wasserstein (2002a, b) proposed that the term *orthodontically induced inflammatory root resorption* is more accurate to describe this pathologic consequence of orthodontic tooth

movement, which should be distinct from the other type of root resorption.

Often, there are no obvious clinical signs and the condition is only detected radiographically. However, where the lesion is visible, the clinical features may vary from a small defect at the gingival margin to a pink discoloration of the tooth crown (Heithersay 1999b). Furthermore, this condition is associated with inflammation of the periodontal tissues and does not involve the pulp of the tooth. In our study, even if patients were highly motivated, cervical root resorption was present. We cannot, however, rule out the possibility that resorption would have been more severe if patients showed a poor hygiene level.

Because no differences in the periodontal parameters were found between experimental and control teeth, we may assume that plaque, BOP and PPD have no prognostic effect on cervical root resorption as a consequence of orthodontic tooth movement. Although teeth were selected to exclude any external or predisposition to resorption and were carefully extracted using forceps, resorption craters were evident in seven pre-molars of the control group (six pre-molars with moderate resorption and one pre-molar with severe resorption). This demonstrates that resorption could be a naturally occurring physiologic phenomenon. Other studies involving the identification of molecules associated with and/or responsible for root resorption during orthodontic tooth movement may be necessary.

In conclusion, cervical root resorption is a common sequela of orthodontic treatment. All the orthodontically moved teeth showed moderate and/or severe resorption on the cervical part of the buccal side. Periodontal parameters did not seem to be associated with root resorption, as no changes were observed clinically during the experimental trial.

## References

- Alexander, S. A. (1991) Effects of orthodontic attachments on the gingival health of permanent second molars. *American Journal of Orthodontics and Dentofacial Orthopedics* **100**, 337–340.
- Andreasen, F. M., Sewerin, I., Mandel, U. & Andreasen, J. O. (1987) Radiographic assessment of simulated root resorption cavities. *Endodontics and Dental Traumatology* **3**, 21–27.

- Brezniak, N. & Wasserstein, A. (2002a) Orthodontically induced inflammatory root resorption. Part I: the basic science aspects. *The Angle Orthodontist* **72**, 175–179.
- Brezniak, N. & Wasserstein, A. (2002b) Orthodontically induced inflammatory root resorption. Part II: the clinical aspects. *The Angle Orthodontist* **72**, 180–184.
- Chapnick, L. (1989) External root resorption: an experimental radiographic evaluation. *Oral Surgery, Oral Medicine and Oral Pathology* **67**, 578–582.
- Davidovitch, Z. (1996) Etiologic factors in force-induced root resorption. In: Davidovitch, Z. & Norton, L. A. (eds). *Biological Mechanisms of Tooth Movement and Craniofacial Adaptation*, pp. 349–355. Boston: Harvard Society for the Advancement of Orthodontics.
- Diamanti-Kipioti, A., Gusberti, F. A. & Lang, N. P. (1987) Clinical and microbiological effects of fixed orthodontic appliances. *Journal of Clinical Periodontology* **14**, 326–333.
- Feldkamp, L. A., Davis, L. C. & Kress, J. W. (1984) Practical cone-beam algorithm. *Journal of the Optical Society of America A* **1**, 612–619.
- Heithersay, G. S. (1999a) Invasive cervical resorption: an analysis of potential predisposing factors. *Quintessence International* **30**, 83–95.
- Heithersay, G. S. (1999b) Clinical, radiologic and histopathologic features of invasive cervical resorption. *Quintessence International* **30**, 27–37.
- Hollender, L., Ronnerman, A. & Thilander, B. (1980) Root resorption, marginal bone support and clinical crown length in orthodontically treated patients. *European Journal of Orthodontics* **2**, 197–205.
- Huser, M. C., Baehni, P. C. & Lang, R. (1990) Effects of orthodontic bands on microbiologic and clinical parameters. *American Journal of Orthodontics and Dentofacial Orthopedics* **97**, 213–218.
- Kloehn, J. S. & Pfeifer, J. S. (1974) The effect of orthodontic treatment on the periodontium. *The Angle Orthodontist* **44**, 127–134.
- Krishnan, V. & Davidovitch, Z. (2006) Cellular, molecular, and tissue-level reactions to orthodontic force. *American Journal of Orthodontics and Dentofacial Orthopedics* **129**, 469e1–469e32.
- Kurol, L. & Owman-Moll, P. (1998) Hyalinization and root resorption during early orthodontic tooth movement in adolescents. *The Angle Orthodontist* **68**, 161–166.
- Kurol, J., Owman-Moll, P. & Lundgren, D. (1996) Time-related root resorptions after application of a controlled continuous orthodontic force. *American Journal of Orthodontics and Dentofacial Orthopedics* **110**, 303–310.
- Linge, L. & Linge, B. O. (1991) Patient characteristics and treatment variables associated with apical root resorption during orthodontic treatment. *American Journal of Orthodontics and Dentofacial Orthopedics* **82**, 35–43.

- Löe, H. (1967) The gingival index, the plaque index and the retention index systems. *Journal of Periodontology* **38**, 610–616.
- Lundstrom, F. & Hamp, S. E. (1980a) Effect of oral hygiene education on children with and without subsequent orthodontic treatment. *Scandinavian Journal of Dental Research* **88**, 53–59.
- Lundstrom, F., Hamp, S.E & Nyman, S. (1980b) Systematic plaque control in children undergoing long-term orthodontic treatment. *European Journal of Orthodontics* **2**, 27–39.
- McFadden, W. M., Engstrom, C., Engstrom, H. & Anholm, J. M. (1989) A study of the relationship between incisor intrusion and root shortening. *American Journal of Orthodontics and Dentofacial Orthopedics* **96**, 390–396.
- Mirabella, A. D. & Artun, J. (1995a) Risk factors for apical root resorption of maxillary anterior teeth in adult orthodontic patient. *American Journal of Orthodontics and Dentofacial Orthopedics* **108**, 48–55.
- Mirabella, A. D. & Artun, J. (1995b) Prevalence and severity of apical root resorption of maxillary anterior teeth in adult orthodontic patients. *European Journal of Orthodontics* **17**, 93–99.
- Naranjo, A. A., Trivino, M. L., Jaramillo, A., Betancourth, M. & Botero, J. E. (2006) Changes in the subgingival microbiota and periodontal parameters before and 3 months after bracket placement. *American Journal of Orthodontics and Dentofacial Orthopedics* **130**, 275.e17–275.e22.
- Owman-Moll, P., Kurol, J. & Lundgren, D. (1995) Continuous versus interrupted continuous orthodontic force related to early tooth movement and root resorption. *The Angle Orthodontist* **65**, 395–402.
- Paolantonio, M., diGirolamo, G., Pedrazzoli, V., di Murro, C., Picciani, C., Catamo, G., Cattabriga, M. & Piccolomini, R. (1996) Occurrence of *Actinobacillus actinomycetemcomitans* in patients wearing orthodontic appliances. A cross-sectional study. *Journal of Clinical Periodontology* **23**, 112–118.
- Paolantonio, M., Festa, F., diPlacido, G., D'Attilio, M., Catamo, G. & Piccolomini, R. (1999) Site specific subgingival colonisation by *Actinobacillus actinomycetemcomitans* in orthodontic patients. *American Journal of Orthodontics and Dentofacial Orthopedics* **115**, 423–428.
- Redlich, M., Shoshan, S. & Palmon, A. (1999) Gingival response to orthodontic force. *American Journal of Orthodontics and Dentofacial Orthopedics* **116**, 152–158.
- Sallum, E. J., Nouer, D. F., Klein, M. I., Gonçalves, R. B., Machion, L., Sallum, W. A. & Sallum, E. A. (2004) Clinical and microbiologic changes after removal of orthodontic appliances. *American Journal of Orthodontics and Dentofacial Orthopedics* **126**, 363–366.
- Silness, L. & Loe, H. (1964) Periodontal disease in pregnancy. II Correlation between oral hygiene and periodontal condition. *Acta Odontologica Scandinavica* **22**, 121–135.
- Zachrisson, S. & Zachrisson, B. U. (1972) Gingival condition associated with orthodontic treatment. *The Angle Orthodontist* **42**, 26–34.

Address:  
 Catherine Giannopoulou  
 Department of Periodontology  
 Dental School  
 University of Geneva  
 Rue Barthelemy-Menn 19  
 1205 Geneva  
 Switzerland  
 E-mail: Ekaterini.Giannopoulou@medecine.unige

#### Clinical Relevance

*Scientific rationale for the study:* Cervical root resorption is a common sequela of orthodontic treatment associated with inflammation of the periodontal tissues. Nevertheless,

prediction and prevention are still impossible.

*Principal findings:* All orthodontically moved teeth showed signs of cervical resorption. However, no relationship could be demonstrated

between resorption and periodontal parameters.

*Practical implications:* Routine periodontal parameters are unrelated to cervical root resorption resulting from orthodontic tooth movement.