
Use of Anatomic Post and Core for Reconstructing an Endodontically Treated Tooth: A Case Report

Simone Grandini^a/Serena Sapio^a/Marco Simonetti^a

Summary: A clinical case is presented in which a new type of fiber post was used in combination with the proprietary dual-curing resin cement to bond in a wide, nonrounded root canal. The anatomic post was inserted and the relining resin photopolymerized. The anatomic post was then removed and a luting procedure was performed, as for any other translucent post. The clinical procedure was simple, and a superior fit to the root canal walls was achieved, thus reducing the amount of cement needed. The luting procedure described can be proposed as a clinical technique for routine use when the prepared root canal is too wide or not perfectly round.

J Adhes Dent 2003; 5: 243–247.

Submitted for publication: 08.07.02; accepted for publication: 19.11.02.

The introduction of fiber posts has had a great impact on the clinical procedures for restoring endodontically treated teeth. Since their debut at the beginning of the 90s,⁵ there has been continuous research on these products to modify the type of fibers (from carbon to quartz to glass) as well as the shape of the posts. The technological evolution has enabled manufacturers today to provide fiber posts that – besides offering superior esthetic and mechanical properties (which were the first qualities to be appreciated in comparison with metal or cast posts) – are also radiopaque and available in a great variety of shapes.^{1,4,11} The growing popularity of fiber posts bears witness to their clinical success, and the results of longitudinal studies^{7,11,13,16} confirm their reliability.

Particularly regarding the shape of the posts, the evolution has gone from the double cylinder of the carbon posts, thus designed for retention purposes,

to the cylindrical or conic profile of the Endoposts and DT posts, respectively. These latter designs are meant for a better adaptation of the post to the canal anatomy, thus minimizing the amount of residual root structure that has to be sacrificed in order to obtain proper post fit. Obviously, this trend toward more and more conservative root preparations for post adaptation has been possible only thanks to the contemporary progress in the field of materials and techniques for bonding, which has made adhesion to root canal walls safer and more predictable.^{8-10,14,15}

It is likely that a further significant improvement in fiber post adaptation and retention will be achieved with the so-called anatomic post. This is a translucent fiber post covered by a layer of light-curing resin (Anatomic Post'n Core, RTD, St Egrève, France), which allows for an individual, anatomical shaping of the post through its insertion into the canal, with the aim of achieving a better fit than is possible with any prefabricated post.^{6,12} As a result of its precise adaptation to the root canal space, the individualized post is surrounded by a thin and uniform layer of resin cement, which creates ideal conditions for post retention.²

The procedure of "individualizing" the post through the resin layer, although advisable in all cases, appears to be particularly effective for the

^a Clinical Professor, Department of Dental Materials and Restorative Dentistry, University of Siena, Italy.

Reprint requests: Dr. Simone Grandini, Via Poliziano 3, Firenze, 50127, Italy; Tel: +39-055-472895, Fax: +39-055-474520. e-mail: simogr@tiscalinet.it

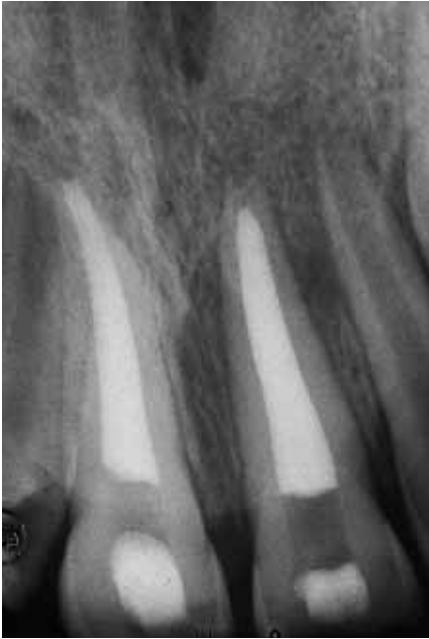


Fig 1 Radiographic examination after having completed the endodontic treatment.

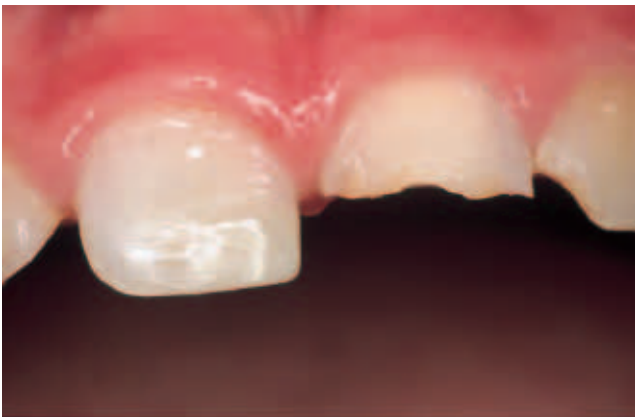

Fig 2 Endodontic treatment was performed on teeth 11 and 21. A direct composite restoration was placed on tooth 11.

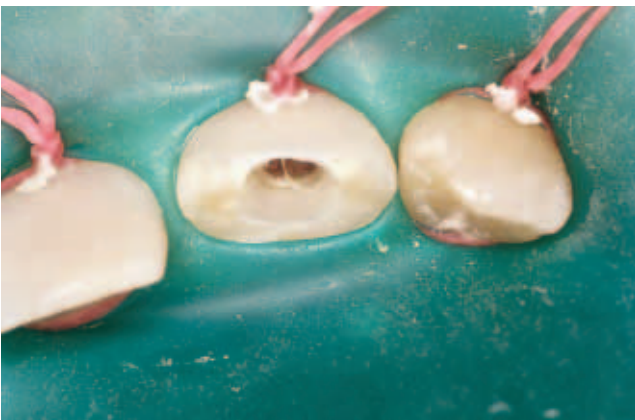

Fig 3 After rubber-dam placement, the wide and not perfectly round residual root canal anatomy is visible in tooth 21.

purpose of improving post retention when dealing with canals of elliptic shape, or exhibiting a reduced amount of residual root structure after endodontic treatment; this latter situation obviously contraindicates a further removal of dentin to make the canal shape match the post shape. The creation of an “anatomic post”, ie, shaping the post to the root anatomy instead of vice versa, is the procedure of choice in these clinical situations, of which the described case is an example.

CASE REPORT

A nine-year-old patient came to the office two days after having hit his front teeth as a result of falling down while playing in the school gym. The trauma caused a complicated crown fracture with extensive pulp exposure on teeth 11 and 21, and an enamel-dentinal fracture without pulp exposure on tooth 22. After clinical and radiographic examination, the decision was made to endodontically treat teeth 11 and 21, and to restore all the teeth with resin composites until prosthetic treatment could be performed. The root canal treatments were conducted, and tooth 11 was restored with a direct resin composite restoration (Figs 1 and 2).

On tooth 21, the root canal anatomy after endodontic treatment was such that no prefabricated post could satisfactorily adapt to it (Fig 3), and the amount of residual dentin on the canal walls was such as to contraindicate the further removal of tissue to make the canal shape adapt to that of the post. The decision was made to use an anatomic post for tooth 21. First, a rotating instrument was used to remove any undercut still possibly present on the canal walls, which were then lubricated with glycerine. At this point, the Anatomic Post'n Core was inserted (Fig 4) and light cured for 20 s (Fig 5). Then the anatomic post was gently pulled out of the canal, and an additional 20 s of light curing was performed in order to completely polymerize the relining resin (Fig 6). The anatomic post was tried in again, in order to ensure that it inserted easily, without any interference.

At this point, a luting procedure was performed similar to that recommended for a conventional translucent post. The root canal walls were etched with 32% phosphoric acid (Bisco, Schaumburg, IL, USA) for 15 s, washed with a water syringe, and gently air dried. Excess water was removed from the post space using paper points (Mynol, Block Profes-

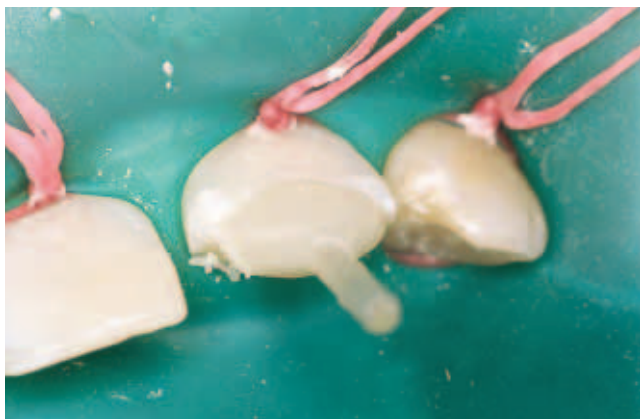

Fig 4 The post coated with light-curing resin is inserted into the root canal with the aim of adapting it to the canal shape (anatomic post).

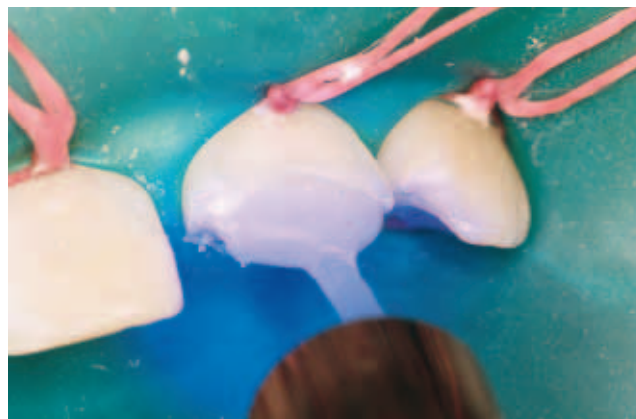

Fig 5 Light curing through the post (20 s) to polymerize the surrounding resin.

sional Dental Products, Jersey City, NJ, USA). Four to five coats of the one-step bonding system (Bisco) were applied into the root canals with a microbrush provided by the manufacturer. The excess primer-adhesive solution was removed with a paper point (Mynol), the cavity was gently air dried, and then the adhesive was light cured for 20 s.

Dual Link (Bisco), a new dual-cure resin cement was used for luting. The catalyst and base components of the material were mixed and applied following manufacturer's instructions. The resin cement was carried into the root canal space with a lentulo drill, the post was seated, and the excess material removed before light curing for 40 s through the post (Fig 7). Due to the young age of the patient, the decision was made to postpone preparation for a prosthetic crown. The anatomic post was therefore simply used as a base for a direct composite restoration (Fig 8). The prepared tooth was etched with 32% phosphoric acid (Bisco) (Fig 9), then the one-step adhesive system (Bisco) was applied as recommended by the manufacturer (Fig 10). The restoration was completed with a microhybrid resin composite material (Micronew, Bisco) (Figs 11 to 13).

DISCUSSION

It is not uncommon to observe a residual root canal shape after endodontic treatment which is not perfectly round.^{3,17} This case is a suitable situation for using the anatomic post. In fact, in the attempt to place a conventional fiber post in such a canal, one would either be forced to round out the canal walls

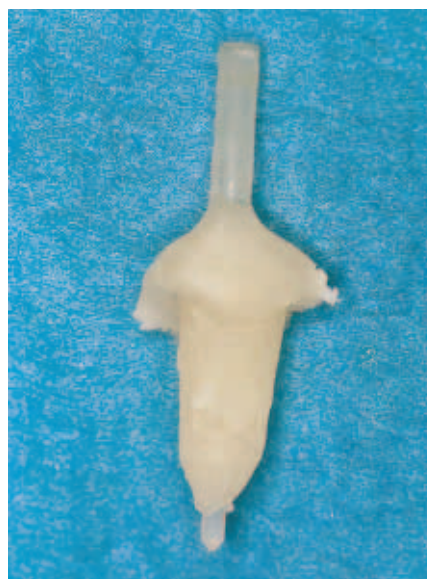

Fig 6 The individualized post as it appears after having been light cured outside of the patient's mouth.

with burs – thus sacrificing a considerable amount of the residual tissue – or to apply a thick layer of cement to fill up the spaces between the loosely fitting post and the canal walls. The latter situation predisposes to adhesive failure and debonding of the post.⁷ On the other hand, a post individualized to closely match the shape of the canal will be surrounded by a thin and uniform film of cement, which represents ideal conditions for retention.

In addition, the technique of the anatomic post makes it possible to perform a direct restoration on

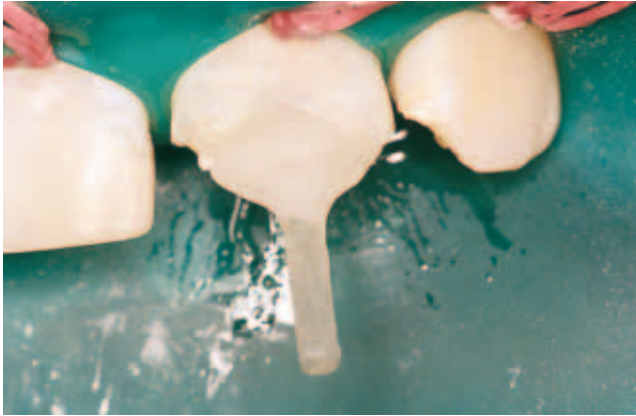

Fig 7 The post after the luting procedures.

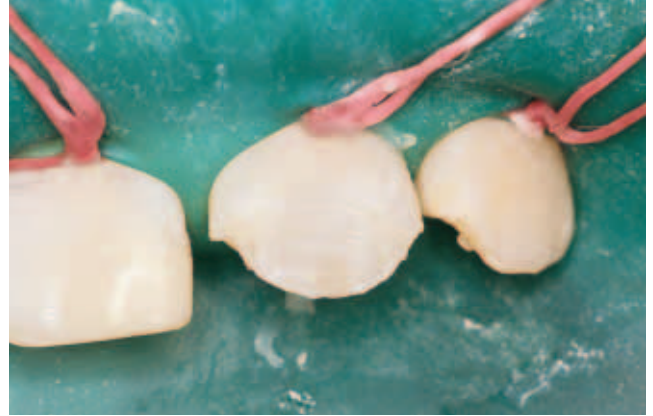

Fig 8 View of tooth 21 after preparation for a direct restoration. The anatomic post is used as a “base” for the resin composite restoration.

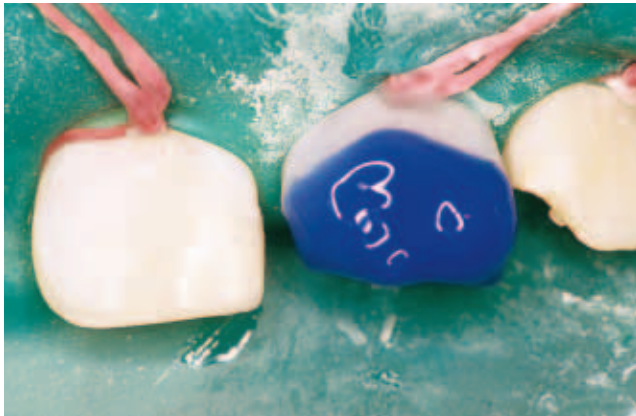

Fig 9 Etching procedure with phosphoric acid.

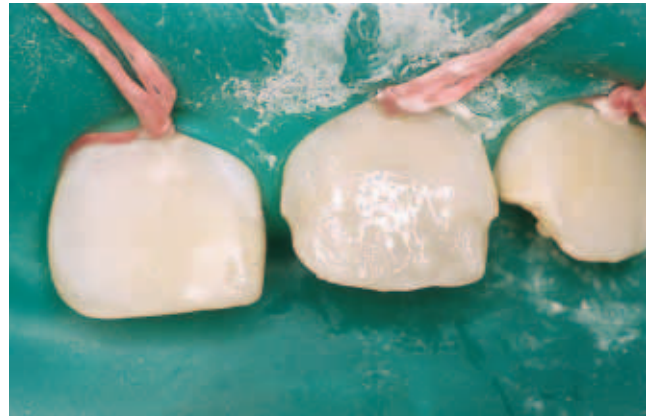

Fig 10 Opaque resin composite is used to build up the core of the tooth and to obtain the proper effect of opacity or to reproduce the natural opacity of the tooth.

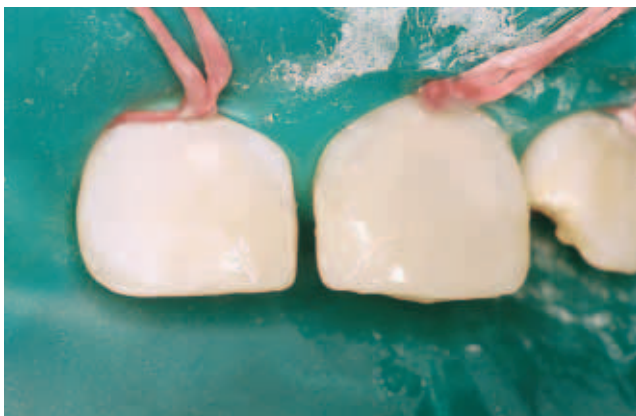

Fig 11 The restoration is completed with a translucent resin composite, used as “enamel” material.

an individualized post in only one visit, without laboratory involvement. In contrast, the classic post and core system, direct or indirect, requires at least two visits and a laboratory phase. This new technique is particularly advantageous in a case like the one described, where the young age of the patient called for treatment to be completed in few visits, with each one as quick and easy as possible. Additionally, if a prosthetic restoration is planned for the endodontically treated tooth, it is possible to immediately build up and prepare a resin composite core on the anatomic post.

From a clinical point of view, it appears that the step of creating an individualized post by allowing the resin layer to adapt it to the canal shape can greatly improve post fit and retention while adding only five minutes of chair time to the standard pro-

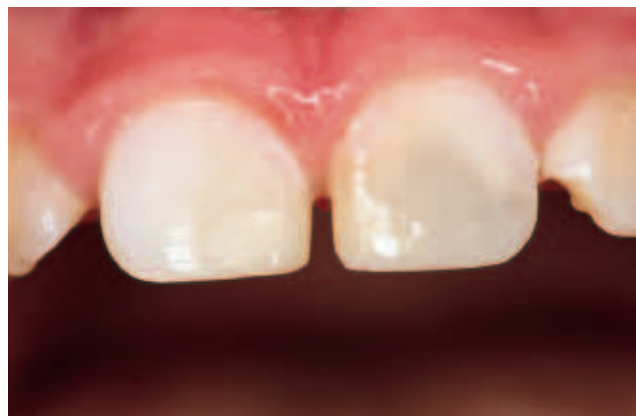
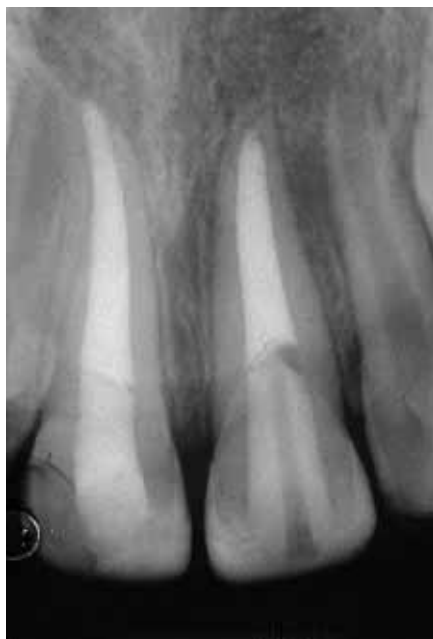
Fig 13 Facial view immediately after the removal of the rubber-dam.

Fig 12 (left) Postoperative radiographic examination. The anatomic post has been luted into the root canal, and the restoration completed.

cedure for luting a translucent post. A study involving both an in vivo trial and an SEM evaluation of the quality of adhesion is ongoing (Grandini et al), in order to substantiate the positive clinical impression.

CONCLUSION

The clinical procedure of the anatomic post can be used for reconstructing an endodontically treated tooth when the anatomy of the root canal walls after preparation is not perfectly round, and when there is an important loss of substance at the coronal level. In this manner, it is possible to obtain a fit of the individual anatomic post which is superior to any other prefabricated fiber post.

REFERENCES

1. Asmussen E, Peutzfeldt A, Heitmann T. Stiffness, elastic limit, and strength of newer types of endodontics posts. *J Dent* 1999;27:275-278.
2. Boudrias P, Sakkal S, Petrova Y. Anatomical post design applied to quartz fiber/epoxy technology: a conservative approach. *Oral Health* 2001;11:9-16.
3. Davis SR, Brayton SM, Goldman M. The morphology of the prepared root canal: a study utilizing injectable silicone. *Oral Surg* 1972;34:642-648.
4. Drummond JL, Toepke RS, King TJ. Thermal and cycling loading of endodontic posts. *Eur J Oral Sci* 1999;107:220-224.
5. Duret B, Reynaud M, Duret F. Un nouveau concept de reconstitution corono-radicaire: le composiposte (1). *Chirurg Dent France* 1990;540:131-141.
6. Ferrari M, Scotti R. Fiber posts: clinical and research aspects. Milano: Masson Ed, 2002.
7. Ferrari M, Vichi A, Mannocci F, et al. Retrospective study of clinical behavior of several types of fiber posts. *Am J Dent* 2000;13:B15-B18.
8. Ferrari M, Vichi A, Grandini S, Goracci C. Efficacy of a Self-Curing Adhesive/Resin Cement System on Luting Glass-Fiber Posts into Root Canals: An SEM Investigation. *Int J Prosthodont* 2001;14:543-549.
9. Ferrari M, Vichi A, Grandini S, Davidson C. An SEM evaluation of several adhesive systems used for bonding fiber posts under clinical conditions. *Dent Mater* 2002;18:495-502.
10. Ferrari M, Vichi A, Grandini S. Influence of adhesive application technique on efficacy of bonding to root canal walls: An SEM investigation. *Dent Mater* 2001;17:422-429.
11. Fredriksson M, Astback J, Pamenius M, Arvidson K. A retrospective study on 236 patients with teeth restored by carbon fiber-reinforced epoxy resin posts. *J Prosthet Dent* 1998;80:151-157.
12. Grandini S, Ferrari M. Una tecnica per rendere anatomici i perni in fibra. *Il Dentista Moderno*. Anno XVIII, n° 5, May 2000.
13. Malferrari S, Baldissara P, Arcidiacono A. Translucent quartz fiber posts: a 20 months in vivo study [abstract 2656]. *J Dent Res* 2002;81(special issue A):A-333.
14. Mason PN. Bonding to root canal dentin. *Transactions of Academy of Dental Materials Meeting*. Siena, 2001:65-69.
15. Mjor IA, Nordhal I. The density and branching of dentinal tubules in human teeth. *Archs Oral Biol* 1996;41:401-412.
16. Scotti S, Malferrari S, Monaco C. Clinical evaluation of quartz fiber posts: a 30 months results [abstract 2657]. *J Dent Res* 2002;81(special issue A):A-333.
17. Walton R, Torabinejad M. Principles and practice of endodontics. 2nd ed. Philadelphia: W.B. Saunders, 1996:212-214.