

Neurological Complications of Local Anaesthetics in Dentistry

ST-JOHN CREAN AND ALISON POWIS

Abstract: Neurological complications following the administration of a local anaesthetic can be alarming. By reading reports of such incidents, dentists who find themselves in similar situations will be able to reassure their patients and act accordingly. The authors have reviewed the literature for those neurological complications that have been reported and offer an explanation of their aetiology. Examples of complications covered are facial nerve palsy, transient amaurosis, post-injection paraesthesia, Horner's syndrome, transient paralysis of combined cranial nerves III, IV and VI, sudden unilateral deafness and abducens nerve palsy. A thorough knowledge of the relevant anatomy pertinent to the various injections used in dental surgery is essential and is highlighted in the text.

Dent Update 1999; 26: 344-349

Clinical Relevance: Neurological complications can be very alarming and this paper will go some way to familiarizing practitioners with the reported complications and their outcome.

A number of significant events led to the introduction of local anaesthetics in dentistry. Following the introduction by Alexander Wood¹, of the hypodermic syringe, Carl Koller², in 1884, discovered that cocaine possessed analgesic properties, and William Halsted³, an American surgeon, used a syringe to inject cocaine to anaesthetize the branches of the mandibular nerve for the relief of pain. First reported complications related to these early anaesthetic agents, until safer alternatives were introduced. Alfred Einhorn⁴ manufactured procaine in 1905 and lignocaine was subsequently introduced by Nils Lofgren⁵ in 1943.

There are numerous routes to achieving local anaesthesia in dentistry.

- In the maxilla, infiltrations (e.g. buccal and palatal) are commonly employed, as well as nerve blockade of the posterior superior alveolar

and the infraorbital nerves.

- In the mandible there are lingual and buccal nerve infiltrations as well as the inferior alveolar, lingual and mental nerve blocks.

Many millions of local anaesthetic cartridges are administered in dentistry each year, yet the neurologically related complications appear to be rarely reported in the literature: over the past 5 years, of 500 reports of complications related to dental anaesthetic, only 40 address neurological side-effects directly. When such complications do occur, early recognition goes some way to allaying the patient's (as well as the surgeon's) concerns.

This short article will outline the neurological complications related to local anaesthetics in dentistry that have been reported in the literature and, where possible, explain their aetiology.

Neurological complications can be divided into:

- those that arise as a direct result of the procedure itself (inferior alveolar nerve block and posterior superior alveolar nerve block); and

- those due to the toxicity of the agents used.

COMPLICATIONS ARISING FROM INFERIOR ALVEOLAR NERVE BLOCK

Facial Nerve Palsy

The most common neurological complication following an inferior alveolar nerve block is a facial nerve palsy (Figure 1).⁶⁻¹¹

The facial nerve is the seventh cranial nerve and exits the skull via the stylomastoid foramen. Before this, the chorda tympani branch arises, which supplies preganglionic secretomotor fibres to the submandibular and sublingual gland and carries efferent taste fibres from the anterior two-thirds of the tongue, except the vallate papillae. After leaving the skull the facial nerve divides into two main branches—temporal and cervical—before entering the substance of the parotid gland, where it divides into temporal, zygomatic, buccal, mandibular and cervical branches, which, eventually, supply the muscles of facial expression.

Patients with a peripheral facial nerve palsy exhibit the following signs:

- generalized weakness of the ipsilateral side of the face;
- inability to close the eyelids;
- obliteration of the nasolabial fold;
- drooping of the corner of the mouth; and
- deviation of the mouth to the unaffected side (Figure 1).

They may also complain of pain in the retroauricular area and a decreased taste sensation.

St-John Crean, FDS RCS, FRCS (Eng.), Lecturer, Department of Maxillofacial Surgery, and **Alison Powis**, BDS, FDS RCS, Senior House Officer, Department of Maxillofacial Surgery, Eastman Dental Hospital and Institute, London.

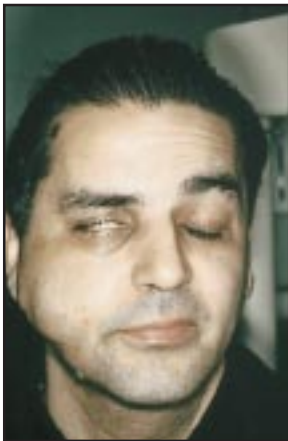

Figure 1. Lower motor neurone facial nerve palsy following the administration of an inferior alveolar nerve block on the right-hand side. Note the smooth right forehead, inability to close the right eye and the relative immobility of the right angle of the mouth. Also note that on attempting to close his right eye the patient's right globe rolls upward, exposing not the iris but the white sclera. This is known as Bell's sign.

Facial nerve palsies may be peripheral or central in origin. The distinction is made in the case of a unilateral paralysis by appreciating that an *upper motor neurone lesion* spares the muscles of the forehead as this area receives innervation from both cerebral hemispheres, due to crossover of fibres in the corticonuclear tracts. The peripheral nerve palsy, in contrast, is a *lower motor neurone lesion* and therefore affects all the muscles of the face.

Facial nerve palsy following inferior alveolar nerve block may appear immediately or be delayed.

Immediate Palsy

The immediate (transient) palsy generally recovers within 3 hours of administration of the local anaesthetic. It is probably due to anaesthesia of the facial nerve trunk as a result of an abnormal nerve anatomy such as passage of the nerve along the deep surface of the parotid gland. Alternatively, it may be caused by a congenital abnormality such as the gland failing to envelop the nerve and its divisions, thus increasing its chances of direct exposure to local anaesthetic solution. It has also been proposed that the capsule of the parotid gland will prevent any escape of local anaesthetic solution inadvertently deposited within

the gland substance, thus maintaining a high concentration of solution in contact with passing branches of the facial nerve.⁶

These explanations however, fail to explain the involvement of the chorda tympani and the associated taste disturbance, the occurrence of facial nerve palsy following a posterior alveolar nerve block and the delayed onset of palsy hours after the anaesthetic has worn off.

Delayed Palsy

Delayed-onset facial palsy occurs after several hours (and in some cases many days) after the administration of the anaesthetic. Three hypotheses have been put forward to explain this.

1. The anaesthetic solution or its breakdown products stimulate the sympathetic plexus associated with the external carotid artery (Figure 2).
2. From the external carotid artery,

fibres of this plexus continue in association with the stylomastoid artery (which in 66% of cases is a branch of the occipital artery and in the remainder a branch of the auricular artery) as it passes into the parotid gland. The stimulation of the stylomastoid sympathetic plexus causes a delayed reflex spasm of the vasa nervorum of the facial nerve, leading to ischaemic neuritis and secondary oedema. The origin of these sympathetic fibres is in the superior cervical ganglion which gives rise to lateral, medial and anterior branches. Of these, it is the anterior branches that pass onto the common and external carotid arteries to form plexuses that accompany the blood vessels.⁸

2. The mechanical action of the needle itself may lead to stimulation of the sympathetic plexus associated with the external carotid artery.⁶

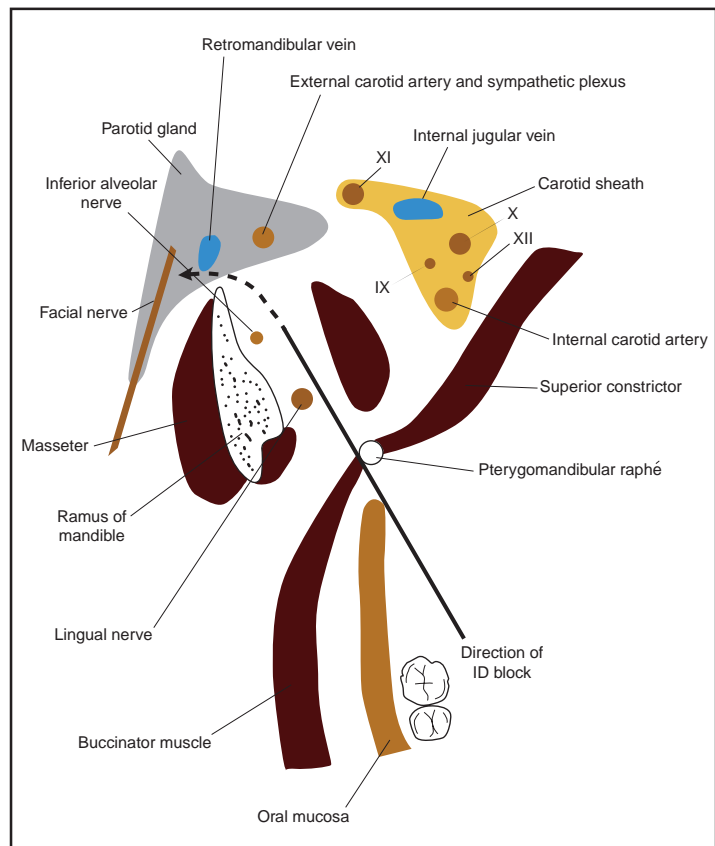


Figure 2. Transverse section through the retromandibular region to demonstrate the path of direction of the needle during an inferior dental nerve block. The potential direction that deposited local anaesthetic solution may take to enter the substance of the parotid gland, and consequently the facial nerve, is marked with a dotted line. The proximity to the external carotid artery and associated sympathetic plexus should be noted.

3. Reactivation of a latent viral infection due to the trauma of the procedure may be responsible for neural sheath inflammation and subsequent disturbance in function.¹¹

Transient Amaurosis

Another, more terrifying complication, transient amaurosis (blindness), has been reported following an inferior dental block.^{12,13}

Total Body Hemiparesis

Inadvertent intravascular injection of local anaesthetic with subsequent retrograde internal movement in branches of the internal carotid artery has been suggested as a mechanism for a reported case of total body hemiparesis 15 minutes following inferior dental nerve block. This comprised ptosis, occipital and neck stiffness, anaesthesia of the right side of the face with dysphasia, and led to complete aphasia and a right hemiparesis. The effects lasted for approximately 45 minutes and were attributed to excess

pressure created during the administration of the injection leading to a retrograde flow into the internal carotid artery.¹⁴

Post-injection Paraesthesia

Although not unique to inferior dental blocks, post-injection paraesthesia has also been recorded in the literature.¹⁵ This has been attributed to barbing of the needle, which, on withdrawal from the tissues, may damage any nearby tissues—for example the inferior dental nerve (Figure 3).

Other causes of persistent paraesthesia include direct nerve damage following injection of local anaesthetics contaminated with sterilizing agents or the development of haemorrhage or haematoma around the nerve sheath leading to necrosis of the neural tissue. Direct inferior nerve trauma feels like an electric shock, sometimes causing the patient to suddenly jerk their head. The practitioner should cease the injection immediately if this occurs.¹⁶

Horner's Syndrome

A rare complication following an inferior dental nerve block, reported by Campbell *et al.*,¹⁷ is the development of Horner's syndrome. This arose due to penetration of the local anaesthetic through the lateral pharyngeal and prevertebral spaces, causing blockade of the stellate ganglion. The features of the syndrome include:

- flushing of the face on the same side;
- ptosis of the eyelid;
- vasodilatation of the conjunctiva;
- pupillary constriction; and
- (occasionally) a rash over the neck, face, shoulder and arm of the ipsilateral side.

The case described by Campbell also reported a hoarse voice and difficulty in breathing due to involvement of the recurrent laryngeal nerve. All of these effects were transient.¹⁷

Transient Paralysis of Combinations of Cranial Nerves

Use of techniques such as Gow-Gates may result in local anaesthetic, which is deposited in a superior position, gaining access to the cavernous sinus following inadvertent intravenous injection.

Consequently, reports have been made of transient paralysis of combined cranial nerves III, IV and VI, leading to immobility of the ipsilateral eyeball, diplopia, ptosis of the eyelid and—in contrast to Horner's syndrome—a dilated pupil.

Careful aspiration and direction of the needle to an area with fewer large-bore blood vessels such as the lateral aspect of the condyle are recommended to avoid this complication.¹⁸

Sudden Unilateral Deafness

There has also been a report of sudden unilateral deafness following dental procedures involving inferior dental nerve blocks. The suggested explanation implies that the venous systems within the mandibular region provide access for the anaesthetic to the middle ear and that this, due to the added vasoconstrictor, results in localized vasospasm of the cochlear division of the internal auditory artery, leading to dysfunction of the cochlear nerve.¹⁹

COMPLICATIONS ARISING FROM POSTERIOR SUPERIOR ALVEOLAR NERVE BLOCK

Peripheral Facial Nerve Palsy

Peripheral facial nerve palsies have been reported following a posterior superior alveolar nerve block (Figure 4).¹⁰ It has been suggested that retrograde injection of local anaesthetic into the posterior superior alveolar artery is transported via the middle meningeal artery and subsequent petrosal artery branches to the facial nerve.

Abducens Nerve Palsy

Uniquely associated with this nerve block is the development of an abducens nerve

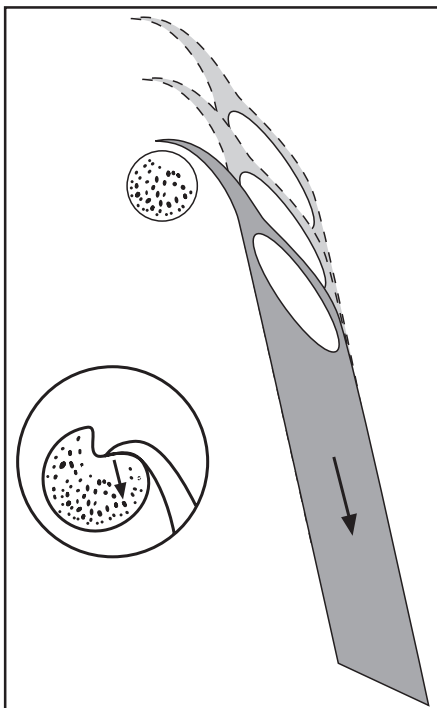


Figure 3. Schematic representation of damage to a nerve bundle on withdrawal of a needle that has been barbed against a solid object, e.g. the mandibular ramus during an inferior alveolar dental nerve block.

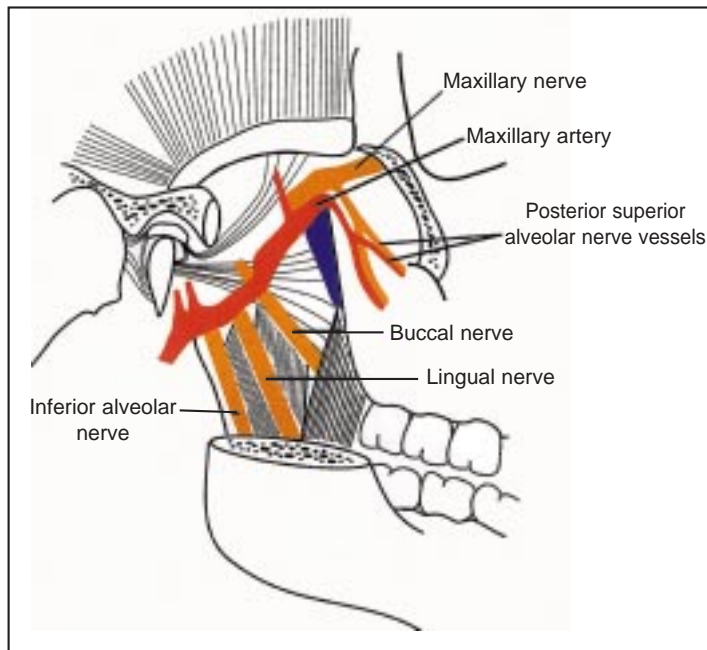


Figure 4. The relevant anatomy involved in a posterior superior alveolar nerve block.

palsy²⁰ (Figure 5). The patient may complain of double vision and may exhibit limitation of abduction of the ipsilateral eye as well as paraesthesia of the lateral side of the upper and lower eyelids. The following explanations have been put forward:

1. Inadvertent deposition of local anaesthetic solution passes through the inferior orbital fissure to cause direct anaesthesia of the abducens nerve. However, this seems unlikely as the abducens nerve lies within the common tendinous ring, medial to the lateral rectus muscle and at some distance from the potential needle entry point. It has also been noticed that the palsy of the lateral rectus recovers well before the effects of the analgesia have subsided.
2. Local anaesthetic solution reaches the inferior ophthalmic vein via the pterygoid plexus or its communicating branches. This vein contains no valves and connects directly with the extrinsic muscles of the eye via the inferior orbital foramen. An intraluminal injection may easily reverse the flow within the vessel, so predisposing the muscles to the effects of the anaesthetic solution. However, if this was the route of deposition of the solution then more

widespread intraorbital effects would be expected.

3. Deposition of anaesthetic solution within the posterior superior alveolar artery, which causes a back flow into the connecting maxillary artery and subsequently into the middle meningeal artery. There exists a constant anastomosis between the orbital branch of the middle meningeal and the recurrent meningeal division of the lacrimal branch of the ophthalmic artery. This lacrimal artery supplies the lateral rectus muscle, the lacrimal gland and the outer half of the eyelids, which, due to these anatomical considerations, may explain all the symptoms.
4. Local anaesthetic reaches the abducens nerve within the cavernous sinus, arriving via the infratemporal fossa and the pterygoid plexus and its connecting emissary veins passing through the foramen ovale and lacerum.

Temporary Blindness

Temporary blindness has been reported following posterior alveolar nerve block due to a large quantity of local anaesthetic under great pressure diffusing through the inferior orbital fissure and coming into

contact with the optic nerve.²¹

COMPLICATIONS ARISING FROM OTHER NERVE BLOCKS

There are many other routes for administration of local anaesthetics during dental procedures, including mental and infraorbital nerve blocks and palatal and buccal infiltrations. Despite the enormous number of injections given, it is reassuring to note that no other procedure-related neurological complications have been reported.

COMPLICATIONS DUE TO THE LOCAL ANAESTHETIC SOLUTION

Toxic complications as a result of an overdose of local anaesthetic solution, resulting in dangerously high concentrations in the brain, are usually produced only by rapid injection directly into a blood vessel.¹³ It should be remembered that for fit adults the recommended maximum safe dose of 2% lignocaine in 1:80 000 adrenaline is four-and-a-half 2 or 2.2 ml cartridges (180 to 198 mg lignocaine); for 3% prilocaine, and felypressin 0.03 i.u./ml, the maximum safe dose is 400 mg (six 2 ml cartridges).²² Some studies have shown that intravascular injection may occur in

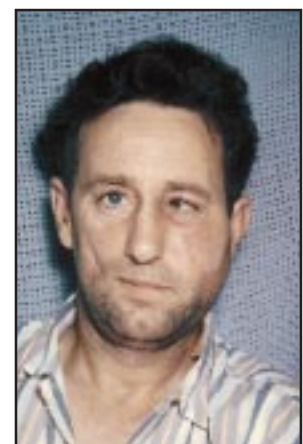

Figure 5. The effects of an abducens nerve palsy on the left-hand side. The subject, due to a palsy of the lateral rectus muscle, has unopposed action of the medial rectus, with a resultant medial deviation of the eye at rest.

between 3 and 12% of cases.²³ To avoid accidents with potentially hazardous results, routine aspiration is essential.

As the anaesthetic solutions of the amide type (e.g. lignocaine and prilocaine) rely on the liver for hydrolysis and metabolism before elimination, any patient with seriously impaired liver function is in danger of inadequate elimination of the solution: a normal volume of anaesthetic will become potentially toxic in such people. The final route for elimination of the metabolized anaesthetic solution is excretion in the urine and so any patient with impaired renal function will also be unable to eliminate these products and be predisposed to toxic accumulation.

The effects of the build up of the local anaesthetic or its breakdown products may occur in two distinct phases: an initial central nervous system stimulation followed by a marked cerebral depression. Stimulation is noted by symptoms ranging from increased anxiety, restlessness, hallucinations to increased depth and rate of respiration, gagging, vomiting and even the risk of severe cortical stimulation resulting in tremors and convulsions. However, with the onset of medullary depression these symptoms will fade as there will be a lapse into unconsciousness, a drop in the blood pressure and a marked reduction in the respiratory rate. Death would result from respiratory failure.

Treatment is an awareness that, although restlessness and confusion may not in themselves be dangerous, they may lead to more sinister symptoms. The role of the dental practitioner is to maintain an airway, ensure the patient is breathing and monitor cardiac activity. Whilst performing these primary measures the practitioner should summon help and contact the nearest casualty department. Placing the patient supine and administering oxygen will allow monitoring of vital signs (pulse, respiration and blood pressure). Convulsions, which occur in some cases, may need to be treated with a slow (over 2 minutes) intravenous infusion of 10 mg diazepam. The rectal route is an alternative when intravenous access is difficult. Clinicians should closely

monitor the patient for signs of respiratory depression. Flumazenil, a specific benzodiazepine antagonist, should always be available. Cerebral depression is managed by elevation of the foot of the dental chair, administration of oxygen and respiratory and circulatory support until the effects have worn off. If supportive measures are not successful and the blood pressure fails to respond, further hospital-based treatment may include methoxamine hydrochloride, which has been administered with some success.

Although psychomotor reactions have in the past been blamed on the intravascular injection of anaesthetic, it is usually fear of the injection that is responsible. This fear leads to a reflex dilation of the splanchnic blood vessels with a concomitant cerebral anaemia and hypoxia. Pallor, skin coldness and perspiration are accompanied by a low blood pressure and a rapid but weak pulse. Convulsive movements may accompany these symptoms. On recognition of these signs the patient should be placed in the supine position and oxygen administered. Tight clothing should be loosened. If recovery is not soon forthcoming then a more serious medical problem should be considered.

CONCLUSION

Every day in dentistry thousands of local anaesthetic injections are administered to patients, but the literature reports only a few neurological complications which require recognition to enable the practitioner to reassure the patient. Those complications due to the local anaesthetic solution itself demand a knowledge of the pharmacology of the drugs used and an awareness that it is important to obtain an accurate medical history—especially with reference to the renal and hepatic systems.

ACKNOWLEDGEMENT

The authors would like to thank Alison Elmes, for her help in the preparation of this manuscript, and the Medical Illustration Department at University College London.

REFERENCES

- Rix KJ. Alexander Wood (1725-1807): Deacon of the Incorporation of Surgeons, Surgeon-in-ordinary, Edinburgh Royal Infirmary, and 'Doctor of Mirth'. *Scott Med J* 1988; **33**(5): 346-348.
- Leonard M. Carl Koller: Mankind's greatest benefactor? The story of local anaesthesia. *J Dent Res* 1998; **77**(4): 535-538.
- Ingle JJ. William Halstead, surgeon, pioneer in oral nerve block injection and victim of drug experimentation. *J Am Dent Assoc* 1971; **82**(1): 46-47.
- Dunsky JL. Alfred Einhorn: the discoverer of procaine. *J Mass Dent Soc* 1997 Fall; **46**(3): 25-26.
- Holmdahl MH. Xylocain (lidocaine, lignocaine), its discovery and Gordh's contribution to its clinical use. *Acta Anaesthesiol Scand Suppl* 1998; **113**: 8-12.
- Tiwari IB, Keane T. Hemifacial palsy after inferior dental block for dental treatment. *BMJ* 1970; **1**: 798.
- Gray RLM. Peripheral facial nerve paralysis of dental origin. *Br J Oral Surg* 1978-79; **16**: 143-150.
- Ling KC. Peripheral facial nerve paralysis after local dental anaesthesia. *Oral Surg Oral Med Oral Pathol* 1985; **60**: 23-24.
- Miles EG. Facial palsy in the dental surgery. Case report and a review. *Aust Dent J* 1992; **37**: 262-265.
- Bernsen BLJA. Peripheral facial nerve palsy after local upper dental anaesthesia. *Eur Neurol* 1993; **33**: 90-91.
- Shaib A, Lee MA. Recurrent peripheral facial nerve palsy after dental procedures. *Oral Surg Oral Med Oral Pathol* 1990; **70**: 738-740.
- Leopard PJ. Diplopia following injection of a local anesthetic. *Dent Pract* 1971; **22**: 92-94.
- Aldrete JA, Narang R, Sada T et al. Reverse carotid flow: a possible explanation for some reactions to local anaesthetics. *J Am Dent Assoc* 1977; **94**: 1142.
- Weinberg A et al. Transient hemiparesis following mandibular nerve anaesthesia. *J Dent Res* 1984; **63**: 549 (Abstract 32).
- Stacy GC, Hajjar G. Barbed needle and inexplicable paraesthesias and trismus after dental regional anaesthesia. *Oral Surg Oral Med Oral Pathol* 1994; **77**: 585-588.
- Malamed SF. *Handbook of Local Anaesthesia*, 3rd ed. St. Louis: Mosby-Year Book, 1990; pp.160-218, 245-257.
- Campbell RL, Mercuri LG, Van Sickels J. Cervical sympathetic block following intraoral local anaesthesia. *Oral Surg Oral Med Oral Pathol* 1979; **47**: 223-226.
- Fish LR, McIntire DN, Johnson L. Temporary paralysis of cranial nerves III, IV and VI after a Gow-Gates injection. *J Am Dent Assoc* 1989; **119**: 127-130.
- Farrell RW, Pemberton MN, Parker AJ, Buffin JT. Sudden deafness after dental surgery. *BMJ* 1991; **303**: 1034.
- Marinho ROM. Abducent nerve palsy following dental local analgesia. *Br Dent J* 1995; **179**: 69-70.
- Cooley RL and Cottingham AJ Jr. Ocular complications from local anaesthetic injections. *Gen Dent* 1979; **27**: 40.
- Meehan J. How to avoid local anaesthetic toxicity. *Br Dent J* 1998; **184**: 334-335.
- Schiano AM, Strambi RC. Frequency of accidental intravascular injections in dental practice. *Oral Surg* 1964; **17**: 178.