

Efficacy of Revascularization to Induce Apexification/Apexogenesis in Infected, Nonvital, Immature Teeth: A Pilot Clinical Study

Naseem Shah, MDS, Ajay Logani, MDS, Uday Bhaskar, MDS, and Vivek Aggarwal, MDS

Abstract

Endodontic treatment options for immature, nonvital teeth conventionally include surgical endodontics, apexification with calcium hydroxide, or single visit mineral trioxide aggregate plug. A new treatment option of revascularization has recently been introduced. It involves disinfecting the root canal system, providing a matrix of blood clot into which cells could grow, and sealing of the coronal access. The present pilot clinical study was undertaken to evaluate the efficacy of revascularization in 14 cases of infected, immature teeth. Endodontic treatment was initiated, and after infection control, revascularization was performed. The access cavity was sealed with glass ionomer cement. The cases were followed up at regular intervals of 3 months; the range in follow-up was 0.5–3.5 years. The outcomes were as follows. Radiographic resolution of periradicular radiolucencies was judged to be good to excellent in 93% (13 of 14) of the cases. In the majority of cases, a narrowing of the wide apical opening was evident. In 3 cases, thickening of apical dentinal walls and increased root length were observed. The striking finding was complete resolution of clinical signs and symptoms and appreciable healing of periapical lesions in 78% (11 of 14) of cases. Thickening of lateral dentinal walls was evident in 57% (8/14) of cases, and increased root length was observed in 71% (10/14) of cases. None of the cases presented with pain, reinfection, or radiographic enlargement of preexisting apical pathology. This pilot study documented a favorable outcome of revascularization procedures conducted in immature nonvital, infected permanent teeth. (*J Endod* 2008;34:919–925)

Key Words

Apexification, apexogenesis, immature teeth, open apices, regenerative endodontics, revascularization

From the Department of Conservative Dentistry and Endodontics, Center for Dental Education & Research, All India Institute of Medical Sciences, New Delhi, India.

Address requests for reprints to Dr Naseem Shah, Professor & Head, Department of Conservative Dentistry & Endodontics and Chief, Center for Dental Education & Research, All India Institute of Medical Sciences, Ansari Nagar, New Delhi 110029, India. E-mail address: naseemys@gmail.com. 0099-2399/\$0 - see front matter

Copyright © 2008 American Association of Endodontists. doi:10.1016/j.joen.2008.05.001

Trauma to the anterior teeth, commonly found among young children, accounts for one third of all traumatic injuries in boys and one fourth of all injuries in girls (1). Tooth fracture constitutes 4%–5% and luxation injuries 30%–44% of all dental trauma injuries (2, 3). Because of their position, the anterior teeth tend to bear the brunt of many impact injuries. The injuries vary from avulsion to intrusion, lateral displacement, fracture, or just a concussion. In many cases, the injury causes cessation of tooth development. Because the root development takes place for almost 2 years after the tooth has erupted into the oral cavity, an incompletely formed apex is one of the most common features seen in traumatized teeth. The patient commonly reports after many years when necrosis of the pulp has caused apical periodontitis or discoloration, causing either pain or compromised esthetics. Inadvertently, radiographs reveal an open apex or blunderbuss apex.

Treatment of the immature nonvital anterior tooth with apical pathosis presents several treatment challenges. The mechanical cleaning and shaping of a tooth with blunderbuss canal are difficult, if not impossible. The thin, fragile lateral dentinal walls can fracture during mechanical filing, and the large volume of necrotic debris contained in a wide root canal is difficult to completely disinfect. Obturation of wide canal systems requires precise fabrication of a customized gutta-percha cone, and there is danger of splitting of the root during lateral condensation. Many blunderbuss canals with flaring walls cannot be obturated and sealed by orthograde methods and might require apical surgery and retrograde sealing of the canal.

Endodontic management of such teeth includes surgery and retrograde sealing, calcium hydroxide–induced apical closure (apexification), and, more recently, placement of an apical plug of mineral trioxide aggregate (MTA) and gutta-percha obturation. A novel concept of revascularization of immature nonvital, infected teeth was recently introduced. The concept of revascularization, per se, is not new. It was introduced by Ostby (4) in 1961, and in 1966, Rule and Winter (5) documented root development and apical barrier formation in cases of pulpal necrosis in children. Occasional cases of regeneration of apical tissues after traumatic avulsion and replantation led to the search for the possibility of regeneration of the whole pulp tissue in a necrotic, infected tooth. In 1972, Ham et al (6) demonstrated apical closure of immature pulpless teeth in monkeys. The development of normal, sterile granulation tissue within the root canal is thought to aid in revascularization and stimulation of cementoblasts or the undifferentiated mesenchymal cells at the periapex, leading to the deposition of a calcific material at the apex as well as on the lateral dentinal walls. In 2001 Iwaya et al (7) and in 2004 Banchs and Trope (8) demonstrated the advantages of this treatment modality, which resulted in a radiographically apparent normal maturation of the entire root versus an outcome of only a calcific barrier formation at the apex after conventional calcium hydroxide–induced apexification. So far, only isolated case reports and small case series have been reported in the literature. We therefore planned a prospective pilot clinical study to evaluate the efficacy of revascularization procedures for the management of traumatized immature, nonvital, infected permanent teeth, including regular follow-up appointments to assess the treatment response in terms of clinical and radiographic healing, root development, and thickening of lateral dentinal walls.

Material and Methods

Fourteen cases of immature, nonvital maxillary anterior teeth presenting with or without signs and/or symptoms of periapical pathology were included in the study. The cases presented with either fractured or discolored anterior teeth and were associated with symptoms of acute or chronic apical infection, ie, diffuse facial swelling or intraoral sinuses. Intraoral periapical radiographs revealed immature apices, either blunderbuss canals or wide canals with parallel walls and a slight flaring in the apical end, and in a few cases, moderately developed root but with open apex. The age of the patients ranged between 9 and 18 years, with average age of 11.6 years. Patients and their parents were informed of the treatment alternatives and risks and consented to the revascularization treatment.

After rubber dam isolation and gaining access to the root canal system, the root canal systems were irrigated with 3% hydrogen peroxide and 2.5% sodium hypochlorite solution, with minimal filing to prevent further weakening of root canal walls. A light cotton pellet with formocresol as an interappointment dressing (squeezed dried) was placed in the pulp chamber, and the coronal access was sealed with intermediate restorative material. In cases with frank purulent discharge, the tooth was left open for drainage for 24–48 hours with a light cotton pellet in the pulp chamber and then closed at the next visit. At the next visit, chemical disinfection with copious irrigation was done, with very minimal filing. Revascularization was done if the tooth was symptom-free and the canal was found to be dry. In cases in which infection persisted and drainage from the canal was present, one more dressing was applied, and revascularization was performed at a subsequent appointment.

The revascularization process was completed as follows. Teeth were anesthetized with a local anesthetic. A sterile 23-gauge needle was taken, and a rubber stopper was placed at 2 mm beyond the working length. With sharp strokes, the needle was pushed past the confines of the canal into the periapical tissue to intentionally induce bleeding into the canal. When frank bleeding was evident at the cervical portion of the root canal system, a tight dry cotton pellet was inserted at a depth of 3–4 mm into the canal and the pulp chamber and held there for 7–10 minutes to allow formation of clot in the apical two thirds of the canal. The access opening was sealed with glass ionomer cement extending 4 mm into the coronal portion of the root canal system. An intraoral radiograph was taken for a baseline record to be compared with follow-up radiographs to be taken at intervals of every 6 months. Both clinical and radiographic evaluation was done at each follow-up visit.

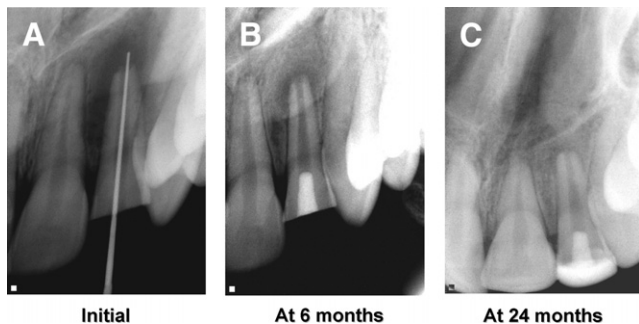


Figure 1. (A) An immature, fractured maxillary lateral incisor with open apex and large periradicular radiolucency in a 16-year-old girl. (B) Six months after revascularization, apical pathology is reduced significantly. (C) At 2-year follow-up, normal bony architecture around the entire root is seen. Note the narrowing of the apical third of root canal lumen.

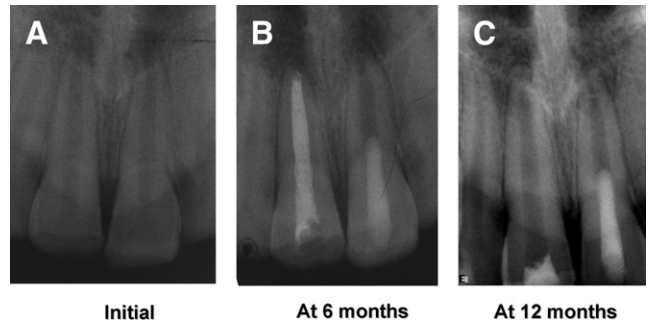


Figure 2. (A) A 14-year-old boy presented with draining intraoral sinus in relation to tooth #21. Intraoral radiograph revealed open apices of both central incisors and a 1 × 1.5 mm lesion associated with #21. On vitality testing, both #11 and 21 were nonvital. It was decided to treat #11 by conventional apexification procedure and #21 by revascularization. (B) At 6-month follow-up, #21 treated by revascularization showed complete healing of periapical lesion and normal maturation of apical end. Tooth #11 with calcium hydroxide also shows satisfactory healing. (C) At 1 year, further narrowing of canal space in apical 1/3 and thickening of the lateral walls is quite evident.

Results

The individual details of these cases and their radiographic presentations are illustrated in Figs. 1–14 and summarized in Table 1. The follow-up of the cases ranged between 6 months to 3½ years. One case could be followed up for 3½ years, 3 for 2 years, 2 for 18 months, 5 for 12 months, and 3 for 6 months. The striking finding was complete resolution of clinical signs and symptoms and appreciable healing of periapical lesions in 11 cases. Thickening of lateral dentinal walls could be appreciated in 8 of the 14 cases, and increased root length was observed in 10 of the 14 cases. None of the cases presented with pain, reinfection, or radiographic enlargement of preexisting apical pathology. Overall, the response to revascularization procedure could be rated as very satisfactory.

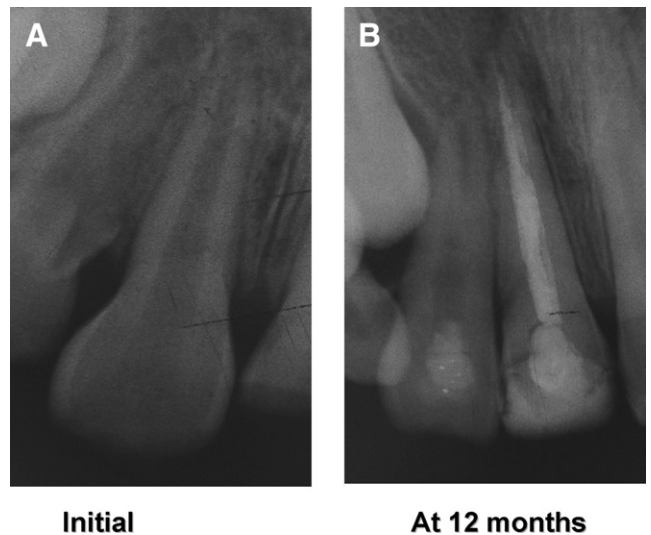


Figure 3. (A) An intraoral periapical radiograph of maxillary right central and lateral incisors in a 9-year-old boy showing poorly formed lateral root walls of tooth #12. Tooth #11 was obliquely fractured and was negative to electric pulp test. It was planned to perform apexification in #11 and revascularization in #12. (B) At 1-year follow-up, complete development of root of #12 is evident, although the canal seems to be obliterated in the middle third. Tooth #11 shows calcium hydroxide dressing in the canal and composite build-up of the incisal edge.

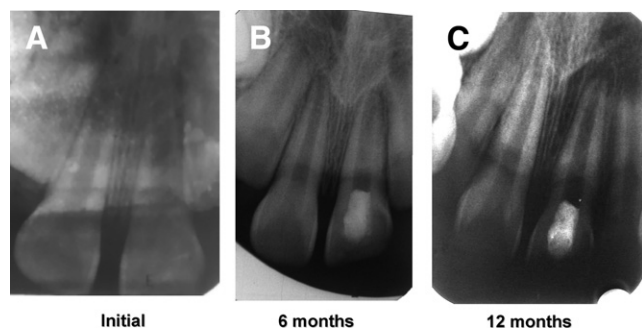


Figure 4. (A) Intraoral radiograph of upper central incisors showing wide root canals and open apices after trauma in a 14-year-old boy. On vitality testing, tooth #11 was vital, and #21 was nonvital. Revascularization was done in #21. (B) At 6-month follow-up, maturation of root comparable to normal physiologic root development in adjacent vital central incisor is evident. (C) At 1 year, further maturation and root lengthening can be appreciated.

Discussion

Apexogenesis is a natural physiologic process of root development. However, the term is used more commonly to describe the endodontic procedure of preservation of pulp vitality in a traumatized tooth with pulp involvement, so that the affected tooth could develop its full growth potential. Recently, it has been suggested that maturogenesis is a more appropriate term than apexification, because not only the apex but the entire root is allowed to mature as in a nontraumatized tooth (9).

Regeneration of tissues rather than replacement with artificial substitutes is an emerging and exciting field in the health sciences. Revascularization of infected, nonvital, immature teeth has been documented to stimulate regeneration of apical tissues and to induce apexogenesis and is emerging as a new treatment modality for such teeth. It was earlier unthinkable that the tissue in the periapical region of a nonvital infected tooth could regenerate. Therefore, a classic treatment option for such teeth was to perform surgical endodontic procedure to seal the wide-open, often blunderbuss apical opening. Although success can

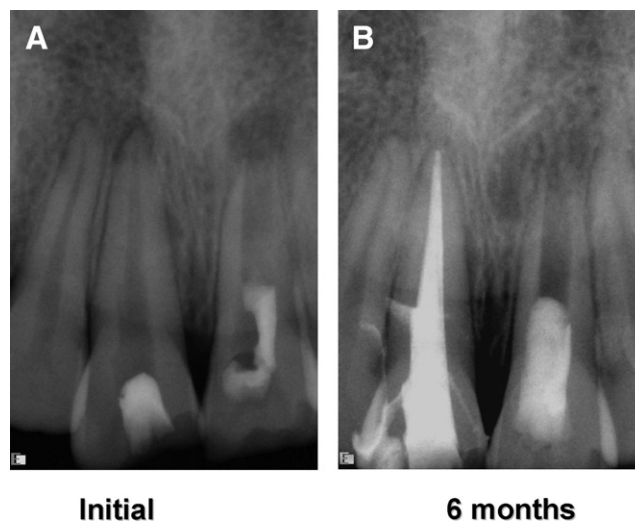


Figure 6. (A) An 11-year-old girl presented with fractured and discolored upper central incisors. The overlying mucosa was slightly inflamed, and there was an intraoral sinus in relation to tooth #21. She gave the history of root canal opening from a private practitioner 1 week earlier. Intraoral x-ray showed periapical lesions in relation to both the incisors. Tooth #21 had an immature apex with very thin dentinal walls. Tooth #11 was treated with Metapex (Meta Dental Corp, LTD, Elmhurst, NY) followed by gutta-percha obturation, and tooth #21 was treated by revascularization. (B) Follow-up radiograph at 6 months shows complete healing of the periapical lesions in both teeth and narrowing of the apex as well as thickening of the lateral dentinal walls.

occur by using a surgical approach with retrograde seal, there are disadvantages. It is an invasive procedure with its accompanying shortcomings, including possibility of surgical complications as well as increased cost of treatment and possible psychological distress, especially in children. Surgical treatment might also lead to a compromised crown:root ratio in a tooth already weakened as a result of immature root development.

When the osteogenic potential of calcium hydroxide was documented by Mitchell and Shankwalkar (10) in 1958 by implantation of

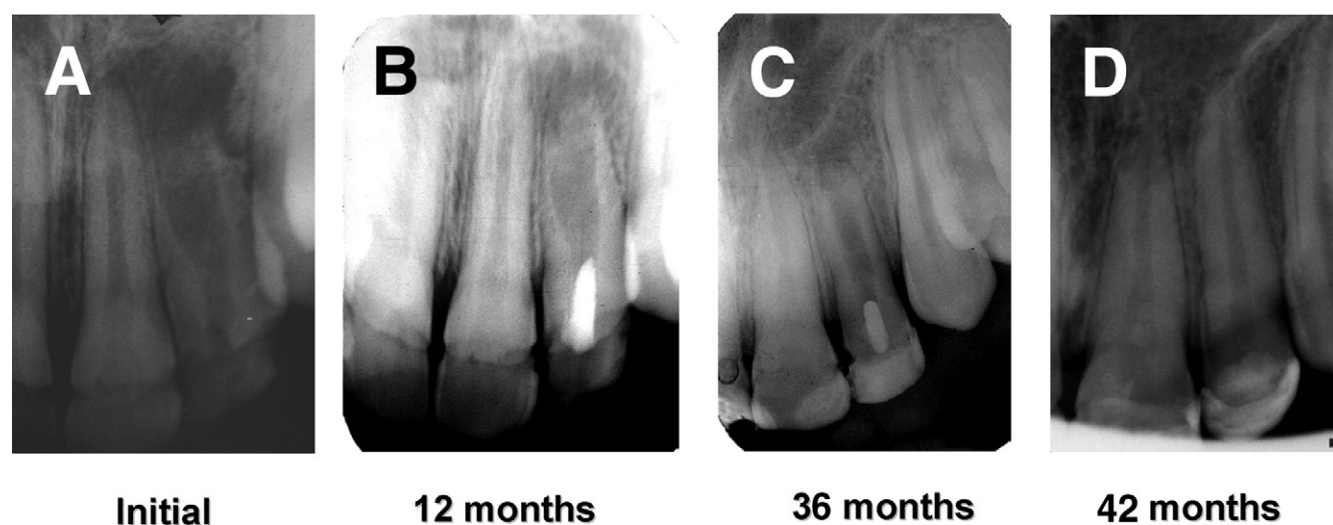


Figure 5. (A) A 12-year-old girl presented with bony hard swelling over maxillary left central and lateral incisors. Intraoral periapical x-ray showed immature lateral incisor with blunderbuss canal, thin dentinal root walls associated with large periapical pathology measuring 3×2 cm. After complete disinfection of the canal in 2 sittings, revascularization was performed. (B) At 1-year follow-up, healing of periapical lesion and elongation of root are evident. (C) At 36-month follow-up, normal maturation of root with thickening of lateral dentinal walls and root lengthening is well-documented. (D) At 42 months, remarkable healing and attainment of normal root length is seen.

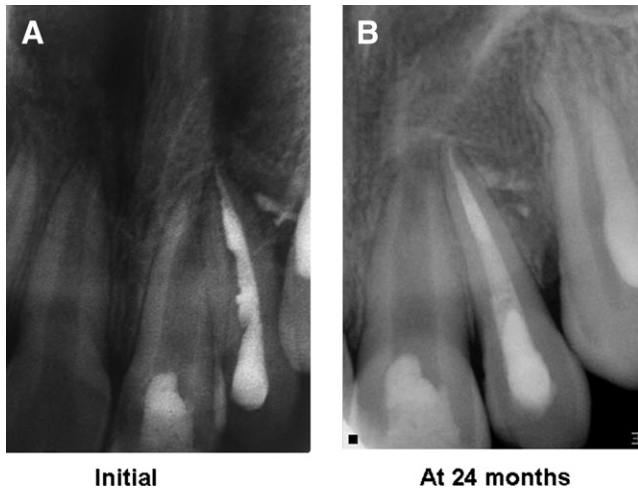


Figure 7. (A) An 8-year-old boy reported with pain and intraoral sinus in relation to teeth #21 and #22. Intraoral periapical x-ray showed wide-open apex of #21 but normal periradicular tissues. In #21, revascularization was induced, and in #22 after cleaning and shaping, Metapex dressing was given. The patient was lost to follow-up for 2 years. When he reported for treatment, endodontic treatment in #22 was completed by laterally condensed gutta-percha obturation. (B) The follow-up radiograph at 24 months shows closure of wide-open apex and normal periradicular architecture.

calcium hydroxide in rat's connective tissue, calcified material was seen to be deposited, even in an area where no preexisting hard tissue was present. Taking advantage of this property of calcium hydroxide apexification in a nonvital incisor was documented by Kaiser (11) in 1962 and later popularized by Frank (12). Since then, apexification has become the standard treatment protocol for treatment of nonvital immature teeth. Many other materials have been used for apexification including tricalcium phosphate (TCP) (13), collagen calcium phosphate (14), bone growth factors (15), osteogenic protein (16), but none has truly replaced calcium hydroxide. However, calcium hydroxide-induced apexification has several limitations (17). It might require 6–24 months for barrier formation. The barrier formed is often porous and not continuous or compact and therefore requires obturation of the

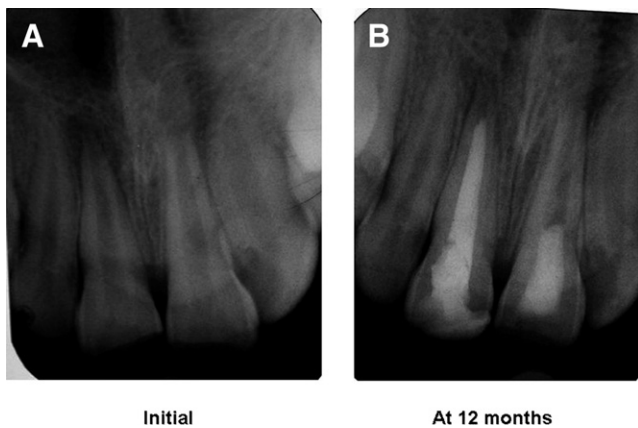


Figure 8. (A) A 12-year-old boy reported with fractured and discolored teeth #11 and #12 with diffuse apical swelling. Intraoral periapical radiograph showed a well-defined radiolucency in relation to #11 and #12 and fully mature apex. Tooth #21 showed wide-open apex. The case was treated with calcium hydroxide in #11 and by inducing revascularization in #21. (B) Follow-up at 12 months showed elongation of root and closure of apex with thickening of lateral dental walls in #21.

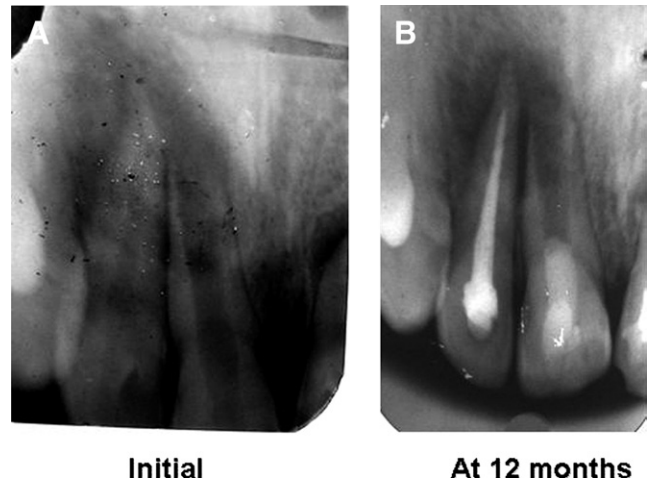


Figure 9. (A) A 17-year-old boy presented with diffuse swelling and frank pus discharge through labial sinus in relation to teeth #11 and #12. On examination, the teeth exhibited grade II mobility. Intraoral periapical radiograph showed wide-open apex of #11 with very thin lateral dental walls and a diffuse apical radiolucency with hazy margins. After 2 dressings at 1-week interval, calcium hydroxide was given in #12, and revascularization was induced in #11. Patient was followed up at regular intervals. (B) At 12-month follow-up, he was completely symptom-free. The teeth were stabilized, and x-ray showed reduction in size of periapical radiolucency and calcific barrier formation at the apex. The case is under follow-up.

canal after barrier formation, with all its inherent problems of achieving a fluid-tight seal without splitting the tooth. Even if successful, apexification can only induce a hard tissue barrier at the apex. Further development of the root does not take place. Intracanal calcium hydroxide dressing can also make the tooth brittle because of its hygroscopic (18) and proteolytic properties (19, 20). Cvek reported 4 years after calcium hydroxide apexification, fractures ranged from 77% of the most immature teeth to 28% of the most fully developed teeth (21). Calcium hy-

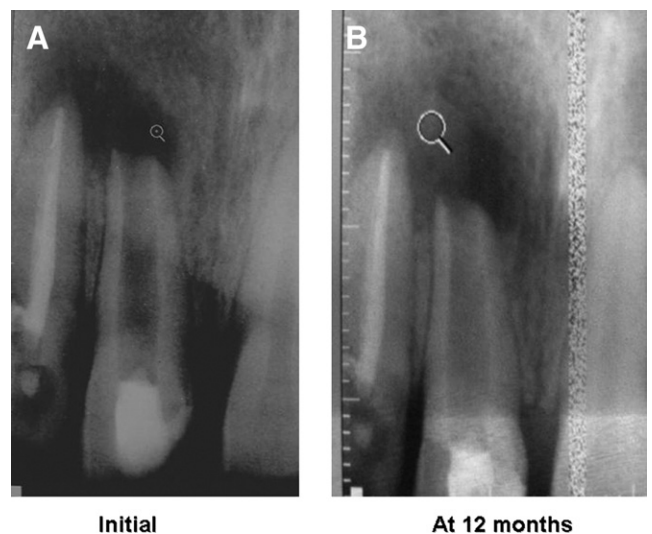


Figure 10. (A) A 14-year-old boy presented with fractured and discolored teeth. Intraoral periapical radiograph of teeth #11 and #12 showed very well-defined radiolucency involving the apices of #11 and #12 and wide-open apex of #11. The case was treated by revascularization in #11 and conventional endodontic treatment in #12. (B) At 1-year-follow-up, evidence of healing of periapical lesion and narrowing of apical opening could be appreciated.

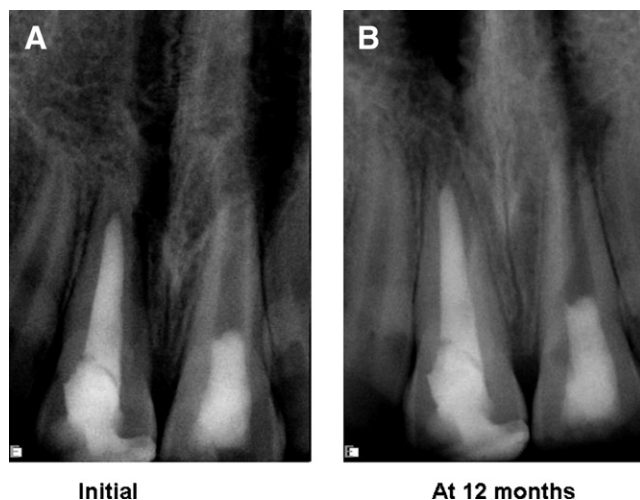


Figure 11. (A) A 10-year-old boy presented with diffuse facial swelling and proclined and discolored upper central incisors. Periapical radiograph showed a large radiolucency involving tooth #21 and extending up to the medial aspect of #11. Revascularization was induced in #21, and conventional endodontics with calcium hydroxide was performed in #21. (B) Follow-up x-ray at 12 months showed a small residual periapical lesion. Elongation of the root and thickening of lateral dental walls could be seen.

droxide with its high pH is known to be toxic to vital cells (22) and hence might damage the cells in its contact at the apex, which have regenerative capacity to heal periapical tissues. By filling the canal with calcium hydroxide, a physical barrier is created that prevents migration of multipotent undifferentiated mesenchymal cells into the canal (23) and regeneration of tissues at the lateral dental walls.

The placement of an apical plug of MTA and gutta-percha filling has several advantages over calcium hydroxide–induced apexification (24–26). MTA is a biocompatible material, has osteoinductive properties, and sets in the presence of moisture, and the treatment can be

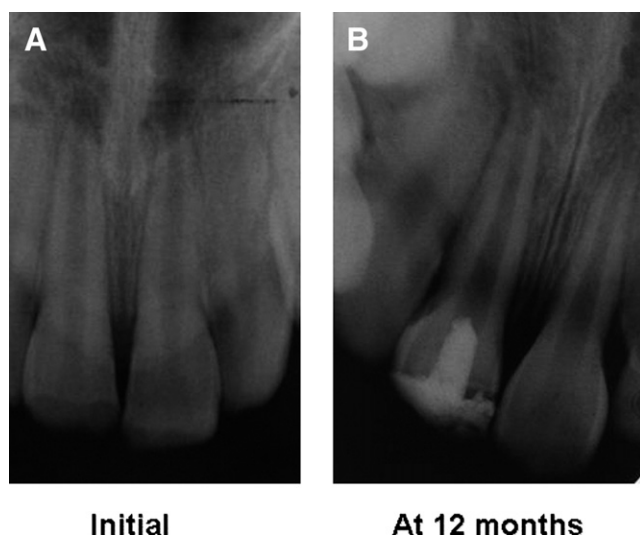


Figure 12. (A) A 12-year-old boy reported for treatment of fractured and discolored tooth #11. He had no symptoms. However, intraoral periapical radiograph showed diffuse periapical lesion. On vitality testing, #21 was vital, and #11 was nonvital. After 1 initial dressing, revascularization was induced. (B) Follow-up radiograph at 12 months showed elongation of root and narrowing of the canal space along with thickening of the lateral dental walls.

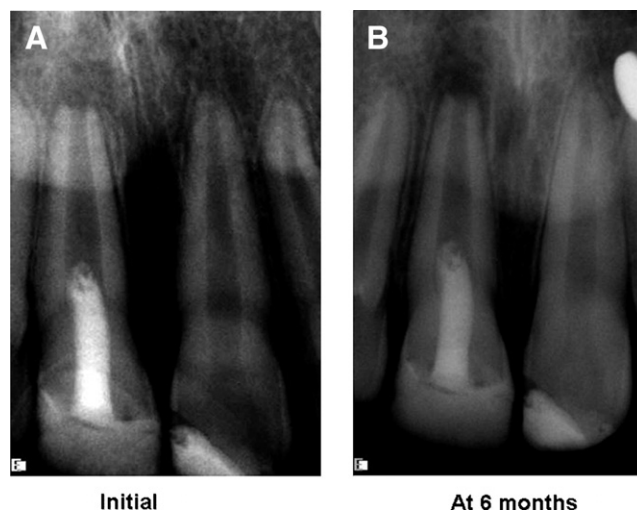


Figure 13. (A) A 12-year-old girl presented with draining intraoral sinus in relation to tooth #11. After 2 dressings when her symptoms subsided, revascularization was performed. (B) At 6-month follow-up, patient was completely asymptomatic, and the x-ray showed narrowing of the apical foramen and thickening of the lateral root walls.

completed in a single sitting. However, it does not strengthen the remaining tooth structure.

Revascularization is the procedure to reestablish the vitality in a nonvital tooth to allow repair and regeneration of tissues. The rationale of revascularization is that if a sterile tissue matrix is provided in which new cells can grow, pulp vitality can be reestablished. Revascularization protocols are derived from the observations of reimplanted and auto-transplanted teeth in experimental animals in which necrotic pulp, if free of infection, provided a matrix into which the cells from the periapical tissues could grow and reestablish pulp vascularity, slowly replacing the necrotic tissue (27, 28). In immature, infected, nonvital teeth, infection control is achieved with minimal instrumentation, depending more on aggressive, copious irrigation with sodium hy-

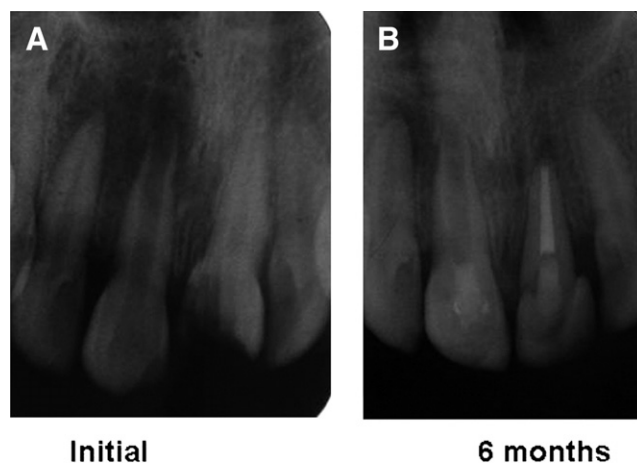


Figure 14. (A) A 9-year-old girl presented with diffuse facial swelling and fractured tooth #21. Intraoral periapical radiograph showed a large diffuse periapical lesion involving #11 and #12. Tooth #21 had normal periapical tissues. However, on vitality testing, #12 was found to be vital, and #21 was nonvital. Endodontic treatment was started in both #11 and #21. When her symptoms subsided at the third visit, revascularization was induced in #11. (B) Follow-up radiograph at 6 months shows complete resolution of the periapical lesion, closure of the apex, and thickening of the lateral dental walls.

TABLE 1. Summary of the 14 Revascularization Cases

Case No.	Age (y)/sex	Tooth #	Follow-up Period	Radiographic Findings at Follow-up		
				Periapical Healing	Dentinal Wall Thickness	Increase in Root Length
1.	16/F	21	2 y	+++	+++	+++
2.	14/M	11	1 ½ y	+++	+++	+++
3.	9/M	12	2 y	++	+++	+++
4.	14/M	11	1 ½ y	+++	+++	+++
5.	11/F	11	6 mo	+++	+++	+++
6.	16/F	22	3 ½ y	+++	+++	+++
7.	8/M	21	2 y	+++	+++	+++
8.	12/M	11	1 y	++	++	+++
9.	17/M	11	1 y	+	+	+
10.	14/M	21	1 y	++	+	+
11.	10/M	11	1 y	++	++	+
12.	12/M	21	1 y	++	++	+++
13.	12/F	21	6 mo	++	++	+
14.	9/F	21	6 mo	+++	+++	+++

+, Satisfactory; ++, good; +++, excellent.

pochlorite, chlorhexidine, or povidone-iodine. Some authors have suggested the use of ciprofloxacin and metronidazole paste (7, 8) or Ca(OH)₂ paste (29) to control the infection.

Mechanism of Revascularization

It is possible that a few vital pulp cells remain at the apical end of the root canal (8, 30). These cells might proliferate into the newly formed matrix and differentiate into odontoblasts under the organizing influence of cells of Hertwig’s epithelial root sheath, which are quite resistant to destruction, even in the presence of inflammation (31). The newly formed odontoblasts can lay down atubular dentin at the apical end, causing apexogenesis (elongation of root), as well as on lateral aspects of dentinal walls of the root canal, reinforcing and strengthening the root.

Another possible mechanism of continued root development could be due to multipotent dental pulp stem cells, which are present in permanent teeth (32) and might be present in abundance in immature teeth. These cells from the apical end might be seeded onto the existing dentinal walls and might differentiate into odontoblasts and deposit tertiary or atubular dentin.

The third possible mechanism could be attributed to the presence of stem cells in the periodontal ligament (33, 34), which can proliferate, grow into the apical end and within the root canal, and deposit hard tissue both at the apical end and on the lateral root walls. The evidence in support of this hypothesis is presented by documentation of cementum and Sharpey’s fibers in the newly formed tissues.

The fourth possible mechanism of root development could be attributed to stem cells from the apical papilla or the bone marrow. Instrumentation beyond the confines of the root canal to induce bleeding can also transplant mesenchymal stem cells from the bone into the canal lumen. These cells have extensive proliferating capacity. Transplantation studies have shown that human stem cells from bone marrow can form bone or dentin *in vivo* (35, 36).

Another possible mechanism could be that the blood clot itself, being a rich source of growth factors, could play an important role in regeneration. These include platelet-derived growth factor, vascular endothelial growth factor (VEGF), platelet-derived epithelial growth factor, and tissue growth factor and could stimulate differentiation, growth, and maturation of fibroblasts, odontoblasts, cementoblasts, etc from the immature, undifferentiated mesenchymal cells in the newly formed tissue matrix. Expression of VEGF in immature and mature permanent teeth has been documented (37).

There are several advantages of revascularization as observed from this study as well as from the past studies. It requires a shorter

treatment time; after control of infection, it can be completed in a single visit. It is also very cost-effective, because the number of visits is reduced, and no additional material (such as TCP, MTA) is required. Obturation of the canal is not required unlike in calcium hydroxide-induced apexification, with its inherent danger of splitting the root during lateral condensation. However, the biggest advantage is that of achieving continued root development (root lengthening) and strengthening of the root as a result of reinforcement of lateral dentinal walls with deposition of new dentin/hard tissue.

There are only a few limitations of revascularization. Long-term clinical results are as yet not available. It is possible that the entire canal might be calcified, compromising esthetics and potentially increasing the difficulty in future endodontic procedures if required. In case post and core are the final restorative treatment plan, revascularization is not the right treatment option because the vital tissue in apical two thirds of the canal cannot be violated for post placement.

Conclusion

The present pilot clinical study offers several advantages over other established treatment protocols for the management of immature, infected nonvital teeth. However, longer case series with longer follow-up period is required to establish it as the standard protocol for management of such teeth.

References

- Gassner R, Bösch R, Tuli T, Emshott R. Prevalence of dental trauma in 6000 patients with the facial injuries. *Oral Surg* 1999;87:27.
- Bader JD, Martin JA, Shugars DA. Preliminary estimates of the incidence with the consequences of tooth fractures. *J Am Dent Assoc* 1995;126:1650.
- Andreasen JO, Andreasen FM. Luxation injuries. In: Andreasen JO, ed. *Textbook and color atlas of traumatic injuries to teeth*. 3rd ed. Copenhagen: Munksgaard, 1993:315–82.
- Ostby BN. The role of the blood clot in endodontic therapy: an experimental histologic study. *Acta Odontol Scand* 1961;19:324–53.
- Rule DC, Winter GB. Root growth and apical repair subsequent to pulpal necrosis in children. *Br Dent J* 1966;120:586–90.
- Ham JW, Patterson SS, Mitchell DF. Induced apical closure of immature pulpless teeth in monkeys. *Oral Surg Oral Med Oral Pathol* 1972;33:438–49.
- Iwaya S, Ikawa M, Kubota M. Revascularization of an immature permanent tooth with apical periodontitis and sinus tract. *Dent Traumatol* 2001;17:185–7.
- Banchs F, Trope M. Revascularization of immature permanent teeth with apical periodontitis: new treatment protocol? *J Endod* 2004;30:196–200.
- Weisleder R, Benitez CR. Maturogenesis: is it a new concept? *J Endod* 2003; 29:776–8.
- Mitchell DF, Shankhwalkar GB. Osteogenic potential of calcium hydroxide and other materials in soft tissue and bone wounds. *J Dent Res* 1958;37:1157–63.

11. Kaiser JH. Management of wide-open canals with calcium hydroxide. Paper presented at the meeting of the American Association of Endodontics, Washington, DC, April 17, 1964. Cited by Steiner JC, Dow PR, Cathey GM. Inducing root end closure of non vital permanent teeth. *J Dent Child* 1968;35:47.
12. Frank AL. Therapy for the divergent pulpless tooth by continued apical formation. *J Am Dent Assoc* 1966;72:87.
13. Roberts SC, Brilliant JD. Tricalcium phosphate as an adjunct to apical closure in pulpless permanent teeth. *J Endod* 1975;1:263.
14. Nevins AJ, Wrobel W, Valachovic R, Finkelstein F. Induction of hard tissue into pulpless open-apex teeth using collagen-calcium phosphate gel. *J Endod* 1978;4:76.
15. Tittle KW, Farley J, Linkhardt T, et al. Apical closure induction using bone growth factors and mineral trioxide aggregate (abstract). *J Endod* 1996;22:198.
16. Shabahang S, Torabinejad M, Boyne PP, Abedi H, McMillan P. A comparative study of root-end induction using osteogenic protein-1, calcium hydroxide and mineral trioxide aggregate in dogs. *J Endod* 1999;25:1–5.
17. Kleier DJ, Barr ES. A study of endodontically apexified teeth. *Endod Dent Traumatol* 1991;7:112.
18. Andreasen JO, Farik B, Munksgaard EC. Long-term calcium hydroxide as a root canal dressing may increase the risk of root fracture. *Dent Traumatol* 2002;18:134–7.
19. Spanberg L. Instruments, materials and devices. In: Cohen S, Burns RC, eds. *Pathways of the pulp*. 8th ed. St Louis, MO: Mosby, 2002:548.
20. Andreasen M, Lund A, Andreasen JO, Andreasen FM. In vitro solubility of human pulp tissue in calcium hydroxide and sodium hypochlorite. *Endo Dent Traumatol* 1992;8:104–8.
21. Cvek M. Prognosis of luxated non-vital maxillary incisors treated with calcium hydroxide and filled with gutta-percha. *Endod Dent Traumatol* 1992;8:45–55.
22. Spangberg L. Biological effects of root canal filling materials: effect in vitro of solubilised root canal filling materials on HeLa cells. *Odontol Revy* 1969;20:289–99.
23. Cvek M. Prognosis of luxated non-vital maxillary incisors treated with calcium hydroxide and filled with gutta percha. *Endod Dent Traumatol* 1992;8:45–55.
24. Arcangelo C, Amario M. Use of MTA for orthograde obturation of non vital teeth with open apices: report of two cases. *Oral Surg Oral Med Oral Pathol Oral Radiol Endod* 2007;104:98–101.
25. Simon S, Rilliard F, Berdal A, Machtou P. The use of mineral trioxide aggregate in one-visit apexification treatment: a prospective study. *Int Endod J* 2007;40:186–97.
26. Giuliani V, Baccetti T, Pace R, Pagavino G. The use of MTA in teeth with necrotic pulps and open apices. *Dent Traumatol* 2002;18:217–21.
27. Cvek M, Cleaton-Jones P, Austin J, Lownie J, Kling M, Fatti P. Pulp revascularization in reimplanted immature monkey incisors: predictability and the effect of antibiotic systemic prophylaxis. *Endod Dent Traumatol* 1990;6:157–69.
28. Skoglund A, Tronstad L, Wallenius K. A microangiographic study of vascular changes in replanted and autotransplanted teeth of young dogs. *Oral Surg Oral Med Oral Pathol* 1978;45:17–28.
29. Chueh LH, Huang GTJ. Immature teeth with periradicular periodontitis or abscess undergoing apexogenesis: a paradigm shift. *J Endod* 2006;32:1205–13.
30. Heithersay GS. Stimulation of root formation in incompletely developed pulpless teeth. *Oral Surg Oral Med Oral Pathol* 1970;29:620–30.
31. Yousef Saad A. Calcium hydroxide and apexogenesis. *Oral Surg Oral Med Oral Pathol* 1988;66:499–501.
32. Gronthos S, Brahimi J, Li W, et al. Stem cell properties of human dental pulp stem cells. *J Dent Res* 2002;81:531–5.
33. Lieberman J, Trowbridge H. Apical closure of non vital permanent incisor teeth where no treatment was performed: case report. *J Endod* 1983;9:257–60.
34. Nevin A, Wrobel W, Valachovic R, Finkelstein F. Hard tissue induction into pulpless open-apex teeth using collagen-calcium phosphate gel. *J Endod* 1977;3:431–3.
35. Krebsbach P, Kuznetsov SA, Satomura K, Emmons RV, Rowe DW, Robey PG. Bone formation in vivo: comparison of osteogenesis by transplanted mouse and human marrow stromal fibroblasts. *Transplantation* 1997;63:1059–69.
36. Gronthos S, Mankani M, Brahimi J, Robey PG, Shi S. Postnatal human dental pulp stem cells (DPSCs) in vitro and in vivo. *Proc Natl Acad Sci U S A* 2000; 97:13625–30.
37. Wang Q, Lin XJ, Lin ZY, Liu GX, Shan XL. Expression of vascular endothelial growth factor in dental pulp of immature and mature permanent teeth in human. *Shanghai Kou Qiang Yi Zue* 2007;16:285–9.