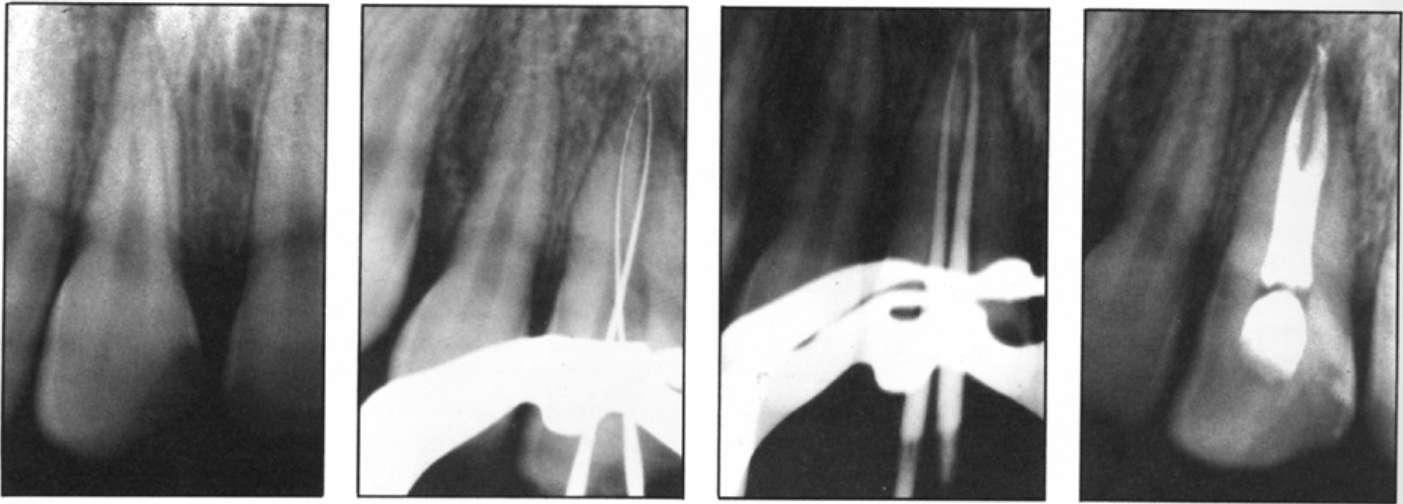


ENDODONTIC THERAPY: EXPECT THE UNEXPECTED

By Terrell F. Pannkuk, D.D.S., M.Sc.D.
Santa Barbara, California



Perhaps the most important point to remember when delivering endodontic therapy is to consider the entire range of possibilities, no matter how unlikely. If you happen to be treating the one-in-one-hundred case, you'll have no chance at success if you don't consider that possibility. And when it comes to root canal systems, complexity is the norm.

A patient recently presented to me for treatment with a history of trauma to the anterior maxilla occurring two years prior to the consultation visit. The right and left maxillary central incisors demonstrated coronal fractures that had been repaired with composite restorations. The right maxillary central incisor had become discolored and sensitive to biting.

Clinical examination revealed moderate percussion sensitivity, Class 2 mobility, and normal sulcular probing depths and soft tissue findings. Vitality testing revealed no response to ice nor the electric vitalometer. The pre-operative radiograph shows a small periapical radiolucency as well as two periodontal ligament spaces appearing as radiolucent lines along the mesial aspect of the root. A diagnosis of pulpal necrosis with periapical extension was made.

Endodontic textbooks state that maxillary central incisors have one canal one hundred percent of the time, and during initial cleaning and shaping in this case there were no indications of a possible second canal. Yet, as the canal was flared during instrumentation, an abnormal sensation was felt tactilely. During the routine introduction of precurved files, a second canal system was discovered branching off a common orifice at mid-root.

The key clue to successful treatment of this case was the two periodontal ligament spaces appearing along the mesial aspect of the root as radiolucent lines on the pre-operative radiograph. Two spaces generally indicate either multiple roots or unusual anatomy, and they were accurate indicators in this case. But in order to have a chance at successful treatment, the practitioner must consider all anatomical possibilities. ■