

Healing Process of Dog Dental Pulp after Pulpotomy and Pulp Covering with Mineral Trioxide Aggregate or Portland Cement

Roberto HOLLAND¹
Valdir de SOUZA¹
Suely Satomi MURATA²
Mauro Juvenal NERY¹
Pedro Felício Estrada BERNABÉ¹
José Arlindo OTOBONI FILHO¹
Eloí DEZAN JUNIOR¹

¹Discipline of Endodontics, Department of Restorative Dentistry,

²Department of Pediatric and Social Dentistry
Faculty of Dentistry of Araçatuba, UNESP,
Araçatuba, SP, Brazil

Considering several reports about the similarity between the chemical compositions of the mineral trioxide aggregate (MTA) and Portland cement (PC), the subject of this investigation was to analyze the behavior of dog dental pulp after pulpotomy and direct pulp protection with these materials. After pulpotomy, the pulp stumps of 26 roots of dog teeth were protected with MTA or PC. Sixty days after treatment, the animal was sacrificed and the specimens removed and prepared for histomorphological analysis. There was a complete tubular hard tissue bridge in almost all specimens. In conclusion, MTA and PC show similar comparative results when used in direct pulp protection after pulpotomy.

Key Words: mineral trioxide aggregate, Portland cement, pulpotomy.

INTRODUCTION

In 1929, Hess (1) reported a technique of pulpotomy with calcium hydroxide. Until now this material has been used for the protection of exposed dental pulps. The healing process of dental pulp after pulpotomy and treatment with calcium hydroxide is fundamentally characterized by the formation of a hard tissue bridge and maintenance of vital subjacent pulp tissue free of inflammatory cells (2,3). Other materials have been proposed for direct pulp protection, but the results are questionable (4,5). More recently a mineral trioxide aggregate (MTA) was recommended for direct pulp protection (6-8). In cases of pulpotomy in dog teeth, Soares (7) reported results with MTA similar to those obtained with calcium hydroxide.

Wucherpfening and Green (9) reported that MTA and Portland cement (PC) seem almost identical macroscopically, microscopically and by X-ray diffraction analysis. They also reported apposition of reparative dentin when the material was used for direct pulp capping in rat teeth. Estrela et al. (10) reported that PC contains the same principal chemical elements as MTA, except that MTA also contains bismuth. Holland et al. (11) studied the rat subcutaneous connective tissue response to implanted dentin tubes filled with MTA, PC and calcium hydroxide and found very similar mechanisms of action.

Considering these results and that Wucherpfening and Green (9) did not publish a full report of their results, the subject of this paper is to study the behavior of dog dental pulp after pulpotomy and subsequent

protection of the remaining tissue with MTA or PC.

MATERIALS AND METHODS

Eighteen teeth of a young mongrel dog, with a total of 26 roots, were used in this experiment. Under general anesthesia, with sodium pentobarbital, and with a rubber dam in place, the pulp chamber was reached and the coronal portion of the pulp was removed with a bur and a spoon-shaped excavator. Bleeding was controlled by thoroughly washing the pulp chamber with sterile saline solution and by applying pressure to the pulp stump with sterile cotton pellets. The pulp stumps were then protected with MTA (Loma Linda University, Loma Linda, CA) or PC (Portland cement, Itaú Type II-F32, Itaú de Minas, MG, Brazil). Each material

was prepared in distilled water and used to protect 13 dental pulps. All coronal openings were sealed with zinc oxide-eugenol and amalgam. Sixty days after treatment, the animal was sacrificed and the pieces were removed and fixed in 10% neutral buffered formalin solution. After decalcification in formic acid-sodium citrate solution the pieces were embedded in paraffin. Serial sections (6- μ m thick) were stained with hematoxylin and eosin, and Brown and Brenn techniques.

During the analysis of the results of this study, details were considered regarding the hard tissue bridge (continuity, morphological aspects, thickness), inflammatory reaction (chronic or acute, number of cells and extension of the reaction), presence of giant cells, particles of the capping material and microorganisms. These histomorphological findings were evaluated by scores of 1 to 4, with 1 being the best result and 4 the worst result (8). The data were submitted to statistical analysis (Kruskal-Wallis test, $p < 0.05$).

RESULTS

Mineral Trioxide Aggregate (MTA)

Hard tissue bridges and vital dental pulps without any inflammatory reaction were seen in 10 cases (Figure 1). The hard tissue bridges varied in thickness and showed a slight irregular calcified area in the more coronal portion of the bridge. All bridges were tubular and in continuity with the lateral dentin formed after treatment. The bridges were complete and some of them had tunnel defects (Figure 1), but these defects

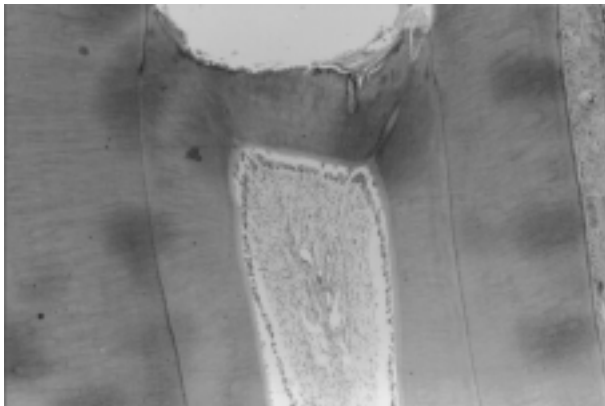


Figure 1. MTA 60 days. Note complete tubular hard tissue bridge and dental pulp without inflammatory reaction (H&E, 40X).

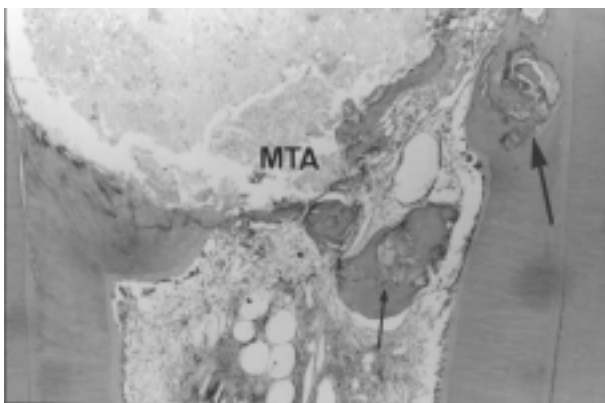


Figure 2. MTA 60 days. Observe a partial, thin dentin bridge in direct contact with the capping material (MTA). There are dentin chips (arrows) surrounded by hard tissue and dental pulp with mild chronic inflammatory reaction (H&E, 40X).

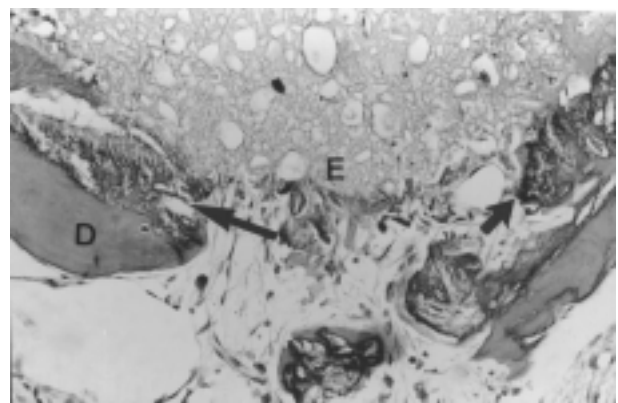


Figure 3. MTA 60 days. Note dentin (D) and dental pulp in contact with an eosinophilic structure (E) and dentin chips (arrows). There is a mild chronic inflammatory reaction (H&E, 200X).

were closed at their more coronal portion. Only 2 specimens exhibited a slight necrotic tissue layer between the bridges and the capping material. In the majority of cases, the new odontoblastic layer had a variable number of cells, 3 of them the same number as observed laterally.

The other 3 cases had problems with the filling of the coronal openings. The Brown and Brenn technique showed Gram-positive and -negative microorganisms in dental tubules and between the filling material and dentin walls. Two of these cases exhibited partial and thin bridges with some dentin chips (Figure 2). The dental pulps showed a mild chronic inflammatory reaction and some neutrophils were observed adjacent to the bridges. One of these specimens with partial bridge and dentin chips had tissue with many irregular spherical forms with apparent empty spaces, resem-

bling the MTA morphology, but with an eosinophilic color close to the dentin bridge. The dental pulp of this case exhibited a mild chronic inflammatory reaction (Figure 3).

Portland Cement (PC)

Complete hard tissue bridges developed in 11 cases protecting the remnants of vital pulp without any inflammatory reaction (Figure 4). Similar to the MTA group, these hard tissue bridges with variable thicknesses exhibited an irregular area at their more coronal portion. Only 3 specimens showed a thin necrotic tissue between the bridge and the capping material. The bridges were tubular and in continuity with the lateral dentin deposited after the treatment. The newly formed odontoblastic layer exhibited a variable number of cells, in 2

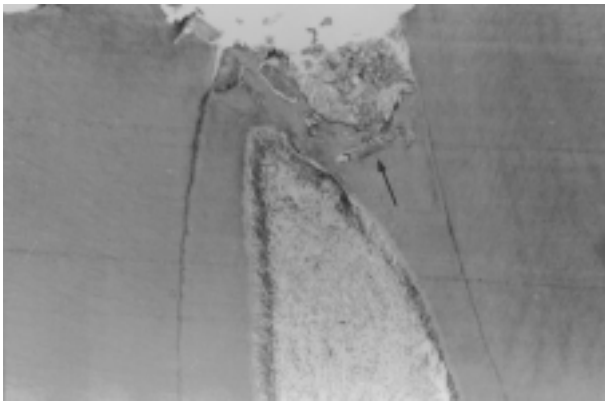


Figure 4. PC 60 days. Example of complete hard tissue bridge with inclusion of dentin chips (arrow). Observe noninflamed dental pulp (H&E, 40X).

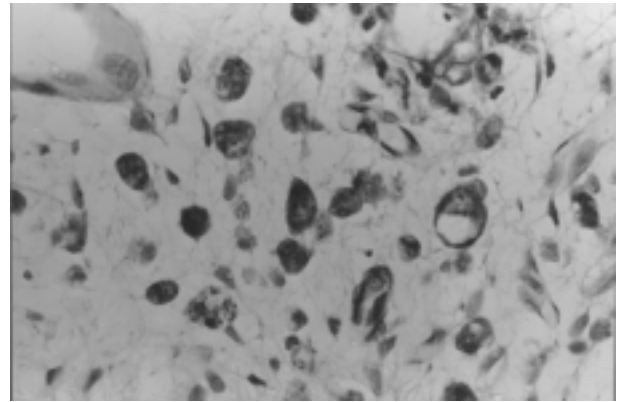


Figure 6. PC 60 days. Note macrophages with particles of capping material in their cytoplasm (H&E, 400X).

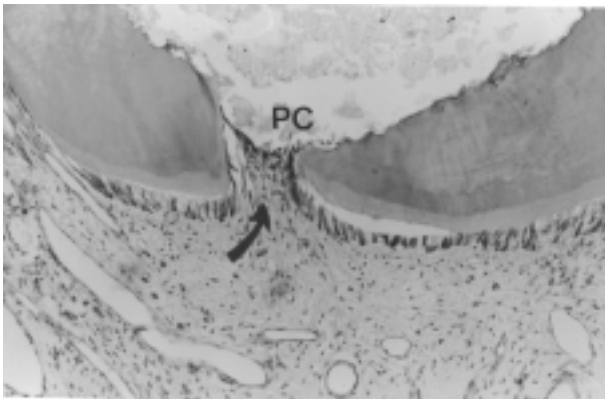


Figure 5. PC 60 days. Note partial dentin bridge. The bridge and pulp tissue (arrow) are in direct contact with the capping material (PC). There is a chronic inflammatory reaction (H&E, 100X).

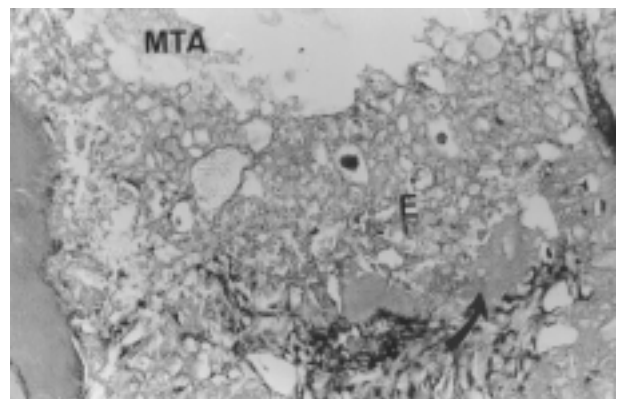


Figure 7. PC 60 days. Observe the capping material (MTA), an eosinophilic structure (E) and hard tissue (arrow) deposit (H&E, 200X).

cases similar to the ones observed laterally next to the dentin walls (Figure 4).

Two cases with problems in the filling of coronal openings exhibited Gram-positive and -negative microorganisms in dentin wall tubules next to the remains of dental pulp. One of these cases showed a partial tubular bridge and dental pulp with chronic inflammatory reaction and scattered neutrophilic cells (Figure 5). Some macrophages exhibited little particles of the materials in their cytoplasm (Figure 6). The other case showed an irregular and eosinophilic structure similar to that described in the MTA experimental group. There was some hard tissue deposit adjacent to that structure (Figure 7). The dental pulp of this case exhibited a mild chronic inflammatory reaction.

Analysis of the numerical data showed no significant differences between MTA and PC (Kruskal-Wallis test, $p > 0.05$).

DISCUSSION

The results observed with MTA are similar to those reported by others on pulp capping (6,8) and pulpotomy (7). The irregular eosinophilic structure reported in one specimen treated with MTA was also described by Faraco Júnior (8) and we do not know exactly what it is; however, it looks a structural alteration in the deeper layer of the capping material in direct contact with pulp tissue. Soares (7) reported 89.28% of cases with complete tubular dentin bridges and Faraco Júnior (8) and Pitt Ford et al. (6) 100%. We observed partial bridges only in specimens with problems in the coronal opening filling with leakage of microorganisms indicating that problems in the healing process were observed only for technical reasons.

The PC experimental group had results very similar to those described for MTA. Complete tubular bridges were observed in 84.6% of the treated cases. Partial bridges were also related to problems in the coronal opening filling in the same way as those reported for MTA.

The results observed with PC and MTA are supported by Holland et al. (11) who reported that the mechanisms of action of MTA and PC are similar. Both materials have calcium oxide that forms calcium hydroxide when mixed with water. According to Holland (12) and Holland et al. (13), the reaction of the calcium from calcium hydroxide with the carbon dioxide from

the pulp tissue produces calcite crystals. Seux et al. (14) observed a rich extracellular network of fibronectin in close contact with these crystals. The authors concluded that their findings strongly support the role of calcite crystals and fibronectin as an initiating step in the formation of a hard tissue barrier. Our results showed many cases with complete dentin bridges for both studied materials. These data support those reported by Wucherpfenning and Green (9) on capping rat dental pulp as well as the described similarity between PC and MTA (9,10).

Considering that both studied materials have similar chemical formulations except for bismuth oxide in MTA (10), and that the obtained results were the same for MTA and PC, one can assume that the bismuth oxide does not influence the results of pulp tissue treatment.

RESUMO

Holland R, Souza V, Murata SS, Nery MJ, Bernabé PFE, Otoboni Filho JA, Dezan Junior E. Processo de reparo da polpa dentária de dentes de cão após pulpotomia e recobrimento pulpar com agregado de trióxido mineral ou cimento Portland. *Braz Dent J* 2001;12(2):109-113.

Levando-se em consideração alguns relatos sobre a semelhança de composição química entre o agregado de trióxido mineral (MTA) e o cimento Portland (PC), foi objetivo deste experimento analisar o comportamento da polpa dentária de dentes de cão após pulpotomia e proteção direta com esses dois materiais. Assim, após a realização da pulpotomia, os remanescentes pulpares de 26 raízes de dentes de cão foram protegidos com MTA ou PC. Sessenta dias após o tratamento o animal foi sacrificado e os espécimes removidos e preparados para análise histológica. Os resultados obtidos foram semelhantes para os dois materiais estudados, tendo sido observado formação de ponte de dentina tubular em quase todos os casos estudados. Foi concluído que o MTA e o PC possibilitam a obtenção de resultados semelhantes entre si quando empregados diretamente na proteção da polpa dentária, após a realização da pulpotomia.

Unitermos: agregado de trióxido mineral, cimento Portland, pulpotomia.

REFERENCES

1. Hess W. Pulp amputation as a method of treating root canals. *D Items Int* 1929;51:596.
2. Souza V, Holland R. Treatment of the inflamed dental pulp. *Aust Dent J* 1974;19:191-196.
3. Holland R, Souza V, Nery MJ, Bernabé PFE, Mello W, Otoboni Filho JA. Healing process after pulpotomy and covering with calcium hydroxide, Dycal or MPC. *Histological study in dogs*

- teeth. *Rev Fac Odont Araçatuba* 1978;7:185-191.
4. Stanley HR, Pameijer CH. Dentistry's friend: calcium hydroxide. *Operat Dent* 1997;22:1-3.
 5. Holland R, Mello W, Souza V, Nery MJ, Bernabé PFE, Otoboni Filho JA. O endogel no tratamento conservador da polpa dental. *Rev Bras Odont* 1986;43:14-18.
 6. Pitt Ford TR, Torabinejad M, Abedi HR, Bakland LK, Kariyawasam SP. Using mineral trioxide aggregate as a pulp-capping material. *J Am Dent Assoc* 1996;127:1491-1494.
 7. Soares IML. Resposta pulpar ao MTA - agregado de trióxido mineral - comparado ao hidróxido de cálcio em pulpotomias: histológico em dentes de cães. [PhD Thesis]. Florianópolis, SC: Faculdade de Odontologia, UFSC; 1996.
 8. Faraco Júnior IM. Avaliação histomorfológica da resposta da polpa de dentes de cães submetida ao capeamento com sistema adesivo, cimento de hidróxido de cálcio e dois tipos de agregado de trióxido mineral. [PhD Thesis]. Araçatuba, SP: Faculdade de Odontologia de Araçatuba, UNESP; 1999.
 9. Wucherpfennig AL, Green DB. Mineral trioxide vs Portland cement: two biocompatible filling materials. *J Endodon* 1999;25:308 (Abstract).
 10. Estrela C, Bammann LL, Estrela CRA, Silva RS, Pécora JD. Antimicrobial and chemical study of MTA, Portland cement, calcium hydroxide paste, Sealapex and Dycal. *Braz Dent J* 2000;11:19-27.
 11. Holland R, Souza V, Nery MJ, Faraco Júnior IM, Bernabé PFE, Otoboni Filho JA, Dezan Junior E. Reaction of rat connective tissue to implanted dentin tube filled with mineral trioxide aggregate, Portland cement or calcium hydroxide. *Braz Dent J* 2001;12:3-8.
 12. Holland R. Histochemical response of amputated pulps to calcium hydroxide. *Rev Bras Pesq Med Biol* 1971;4:83-95.
 13. Holland R, Pinheiro CE, Mello W, Nery MJ, Souza V. Histochemical analysis of the dogs dental pulp after pulp capping with calcium, barium, and strontium hydroxides. *J Endodon* 1982;8:444-447.
 14. Seux D, Couble ML, Hartmann DJ, Gauthier JP, Magloise H. Odontoblast-like cytodifferentiation of human dental pulp cells in vitro in the presence of a calcium hydroxide-containing cement. *Arch Oral Biol* 1991;36:117-128.

Accepted March 27, 2001