



Issue Date: May 2002, Posted On: 8/23/2005

The Cracked Tooth Syndrome
John D. West, DDS, MSD



The Cracked Tooth Syndrome (CTS) is both a transient and progressive condition. Diagnosis of CTS can be difficult, appropriate treatment is necessary to prevent further damage to the tooth, and the failure to diagnose this condition can result in the eventual loss of the affected tooth. This article will present a classification system for CTS and discuss how to accurately diagnose and treat this clinical condition.

BACKGROUND

A MedLine search reveals that more than 150 articles have been published about the CTS during the past 25 years. In 1993 Williams presented a classification of specific diagnostic symptoms of CTS as well as guidelines for predictable treatment.¹ The condition of CTS was originally described by Cameron in 1964, and he revisited the subject in 1976.^{2,3} In 1993 Christensen presented a pragmatic treatment approach that discussed types of cracks, and noted that certain more complex cracks involved the dental pulp or intraradicular portion of the tooth.⁴

Pretreatment diagnosis of the severity of the problem is nearly impossible. Consequently, patients should be clearly advised of all potential outcomes in the treatment plan and accept the plan before treatment begins. Subsequently, the clinician must be able to advise the patient about the specifics of the treatment plan which, of course, is based on clinical findings. Therefore, it becomes essential to have guidelines for treatment.

It is important to note that the CTS is a frequent reason that patients will change dentists. A patient reports pain, and often the dentist relies on a periapical radiograph to determine the origin of the pain. Because the CTS is a vital pulp condition, the periapical radiograph is of limited value as a diagnostic test for CTS. As a result, lack of treatment, or inappropriate treatment, will not resolve the symptoms, often causing the patient to seek help from another clinician.

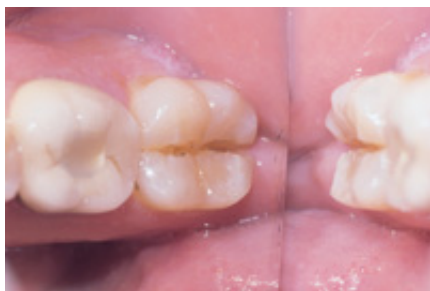

Figure 1. Cracked Tooth Syndrome can affect patients of different ages. A teenager has a class IV mesiodistal fracture from clenching during weight lifting. The tooth was nonrestorable.

Dentists can expect to encounter patients with CTS with increasing frequency, and early diagnosis will be essential to saving these teeth. People are living longer, retaining more teeth during later years of life, but also experiencing more stress. If undiagnosed, the fracture will progress with time, and teeth will fail. With the aging process, more restorations will likely be placed, and teeth will be more susceptible to vertical fracture. Different types of fractures require different approaches for management.^{5,6} CTS can affect patients of all ages (Figure 1).

Gibbs,⁷ who wrote one of the earliest reports on the subject of CTS, listed conditions that promote tooth fracture. Cusps weakened by caries, by the shape and size of cavity preparation, and by improper restorations were generally considered the most important causes. He also described the CTS as odontalgia secondary to cuspal fracture. His characteristic findings were: (1) pain on mastication; (2) difficulty in localizing pain; and (3) lack of other objective or subjective findings.

Cameron's studies found that teeth restored with silver amalgam tended to fracture more frequently than those with gold inlays.^{2,3} Fractures were believed to be caused by amalgam expansion or by the seating of inlays, and most restorations had been in place for many years.

Stanley⁸ suggested that considerations in cavity and crown preparations may reduce the incidence of CTS. The restoration and remaining tooth structure must resist structural failure if the restoration is to be successful. Cusp protection is essential.

DIFFERENTIAL DIAGNOSIS

As part of the diagnostic process for CTS, the clinician must thoroughly evaluate the nature of pain when biting. If the patient favors

one side when chewing, some of the more common causes include: endodontic abscess, periodontal abscess, pericoronitis, sinusitis, discomfort associated with orthodontic movement, hypersensitivity, poorly placed composite restoration, restoration impinging on the attachment apparatus, loose temporary restoration or crown, open contact, a tooth about to exfoliate, bruxism and clenching, and a parafunctional occlusal habit. Most of these conditions are easy to diagnose, and if the problem is none of the above, then clinicians must consider a fractured tooth.

The clinician may ask the patient which side of the mouth is the preferred side for chewing. If a favorite side of the mouth is identified, the opposite side should be the focus of the differential diagnosis. Proper diagnosis and early treatment of a fracture can prevent a vertical fracture or pulp involvement.

CLASSES OF CRACKED TOOTH SYNDROME

Based on the work of Williams,¹ a classification system for CTS was developed, including symptoms and guidelines for diagnosis and treatment.

Class I: Incomplete Vertical Fracture

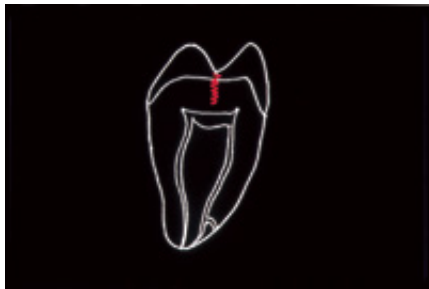


Figure 2a. Schematic of class I fracture: incomplete vertical fracture through enamel into dentin, but not into pulp.

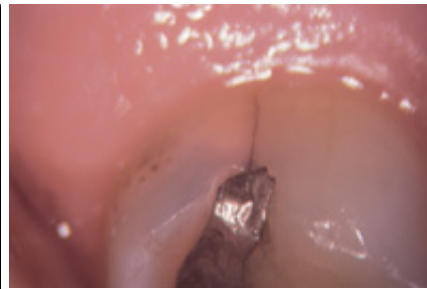


Figure 2b. Example of naturally-stained vertical fracture on the distal of the maxillary second molar (at 15X).

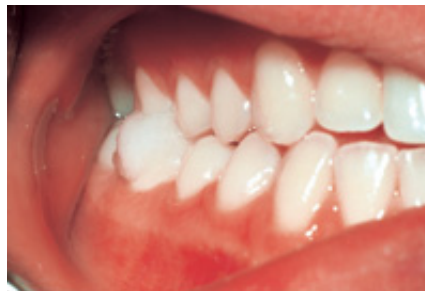

Figure 2c. Cotton wad test.

In this class, there is incomplete vertical fracture through enamel and into dentin, but not into the pulp (Figures 2a and 2b).

Symptoms. This fracture involves the dentinal tubules, and action potentials are produced when there is micromovement of the crack. These fractures can often be seen under the microscope and through the additional use of transillumination or staining procedures. (Note: In the classification system described, classes I through IV represent a progression of the same type of fracture, which is occlusally induced. If the dentist makes an early diagnosis, the problem may not progress beyond a class I fracture. If the diagnosis is missed and no treatment is provided, it may rapidly proceed to a class IV fracture. The majority of fractures seen by general practitioners are class I and class II. Class III and class IV fractures have unpredictable outcomes, and a class V fracture requires extraction. Success depends on an accurate diagnosis, relief of the occlusion, and a proper restoration.)

The cleavage plane of a class I fracture is usually in a mesiodistal direction. The patient with this problem often complains for months or years that they experience a sharp pain when chewing. Again, radiographs are of no diagnostic value here because there are no osseous changes, and the fracture is perpendicular to the radiographic beam. Often, a patient will call one day to report that a portion of a tooth has broken and the sharp pain has subsided.

Diagnosis. The key to diagnosis is to reproduce the symptoms of the patient's chief complaint, which is a sharp pain when biting. A variety of diagnostic aids are available, but perhaps the best is a cotton roll or a cotton wad (Figure 2c). The cotton wad technique is as follows: Place the patient in a sitting position and ask them to identify a substance that causes pain when chewing. If the answer is gum, for example, then wad a piece of cotton in the size of chewing gum and wet it. Have the patient chew on this until he experiences pain. Pain may be experienced within a few seconds, or it may take several minutes for the patient to locate the exact area that elicits pain. The patient is instructed to keep the teeth together when they experience pain and inform the clinician. This often works well if the patient has been complaining of pain on chewing for a number of years. It may be necessary to change the size of the cotton wad, moisten with saliva, and duplicate their own symptom in what is often their own special occlusal position. In this manner, the patient will be able to participate in the diagnosis.

Treatment. For a fracture in one or more of the line angles in a tooth without pulpal symptoms, place a copper band or stainless steel band with permanent cement, or a temporary crown and removal of cuspal contact. (Note: If the tooth has an existing restoration that is deep toward the pulp, upon its removal a base should be placed before the permanent cement is placed; otherwise, the pulp may be irritated from the cement.) If the patient is asymptomatic after 1 week, and has no discomfort with thermal changes, then the tooth can be predictably restored with a cast crown. Note that it is important to see the patient in the dental office for follow-up visits, as

opposed to speaking by telephone. The clinician must be sure that the patient is chewing on the affected tooth (see Flowchart). In an unpublished clinical evaluation by the author, 133 cases of class I CTS became asymptomatic after diagnosis and treatment performed from 1990 to 1993. One hundred patients were recalled in the year 2000, and 5% of the teeth required endodontic treatment, 2% were removed, and 93% were asymptomatic and did not require endodontic therapy.

Class II: Pulpal Involvement

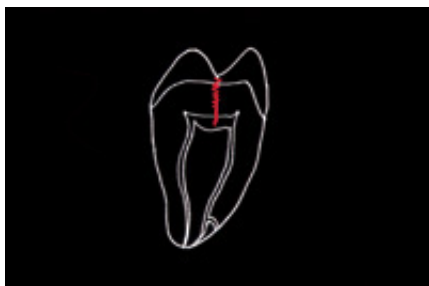

Figure 3a. Schematic of class II fracture: incomplete crown fracture involving the pulp.

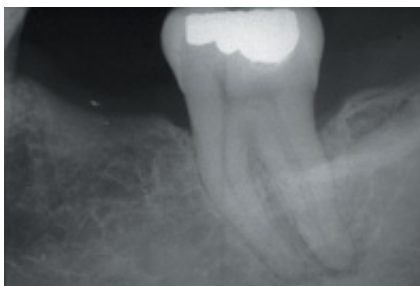


Figure 3b. Periapical radiograph of tooth eliciting symptoms.

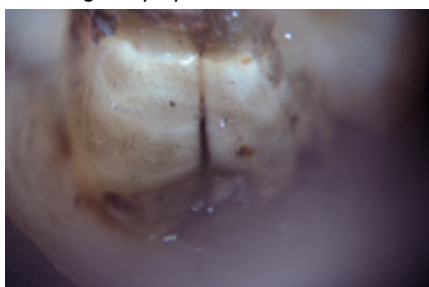


Figure 3c. Vertical fracture down the distal wall of the tooth after preparing for an orthodontic band.

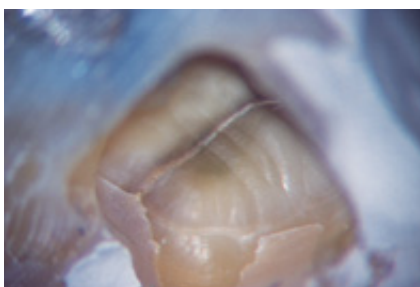

Figure 3d. Vertical fracture down the mesial wall after endodontic access cavity.

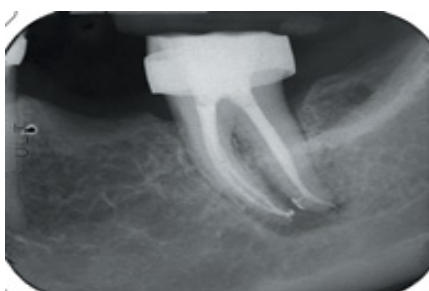

Figure 3e. Radiograph after orthodontic band placed and endodontic therapy completed.

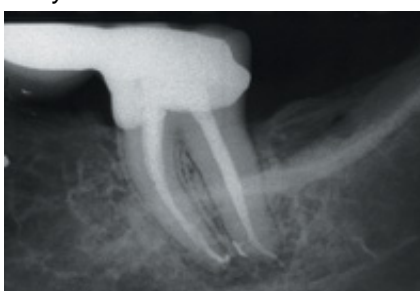

Figure 3f. A 6-month postoperative radiograph demonstrating normal level of alveolar bone.

In this class, crown fracture is associated with irreversible inflammation of the pulp (Figures 3a through 3f). This category can include teeth without symptoms, but pain with thermal change can also be observed.

Symptoms. In addition to sharp biting pain, the patient will often experience discomfort with thermal changes and report a recent history of pain with thermal stimuli. The tooth may have advanced to an acute alveolar abscess, but there will be a recent history of pain to thermal stimuli. The history is key in these cases. If the patient is questioned about when they had pain with biting, ie, was the pain first with biting or to thermal change, the patient will report that the pain occurred first with biting. This should lead to a diagnosis of a vertical fracture in the crown. If the fracture is not diagnosed, and the patient is treated just for pulpitis or acute alveolar abscess, failure will result. The reason for failure is that the tooth was not treated for the combined problem, ie, fracture and pulpal involvement.

Teeth in this category need to be treated with a copper or stainless steel band that is cemented with permanent cement, and root canal therapy. If the tooth is asymptomatic to chewing after the endodontic treatment is completed, then it can be restored with a cast crown. The tooth must be completely asymptomatic to chewing or biting before treating with a crown or the treatment is not predictable. Do not expect the tooth to be less symptomatic with a crown in place than it was with the cemented band.

Diagnosis. Duplicate symptoms with biting, and evidence of pulpitis.

Treatment. Adjust the tooth so it is not in occlusion. Band the crown immediately. Treat the pulpal pain appropriately. Check the mesial and distal surfaces for increased probing depth. If an isolated periodontal defect is observed, the fracture may involve the root surface in an apical direction, and the prognosis is poor. If the tooth remains symptomatic to biting after the band is placed and endodontic treatment is complete, consider extraction. The reason the tooth remains symptomatic is that the fracture line has extended into the periodontal ligament, and the pain the patient experiences is from the periodontal ligament and not the pulp. The symptoms will not improve when a crown is placed. If the tooth is asymptomatic with the band and following endodontic treatment, then continue with a cast crown. Within the next 2 or 3 years, some teeth in this category will be lost, but the vast majority will be as serviceable as any

other endodontically treated tooth. Ultimately, it is difficult to measure the relationship of the depth of the fracture and pulpal involvement, except by a sequence of measured symptoms after band placement. There are three possible outcomes after band placement (see Flowchart).

Class III: Attachment Involvement

The class III fracture is the most difficult to treat because the periodontal defect associated with the fracture is important to the prognosis. This dilemma was described by Hiatt.⁹ He concluded that as the fracture proceeds deeper into structures of the tooth, bacteria invade the pulp or periodontal tissues and may result in pulpal lesions, periodontal lesions, or combined lesions. The attachment apparatus is often involved. These cases can have minimal probing depth, except in the area of the fracture. The depth will depend, of course, on the extent of the fracture.

Here the pulpal tissue is almost always necrotic and often asymptomatic. Generally, the patient's history will reveal that they have experienced symptoms of a class I and class II fracture. The fracture has now advanced to involve the periodontal ligament. The tooth may have an acute alveolar abscess. There may or may not be an endodontic lesion obvious on the radiograph.

Symptoms. If the pulp is necrotic, there are few symptoms.

Diagnosis. History of class I and class II symptoms. Periapical or lateral bone loss radiographically.

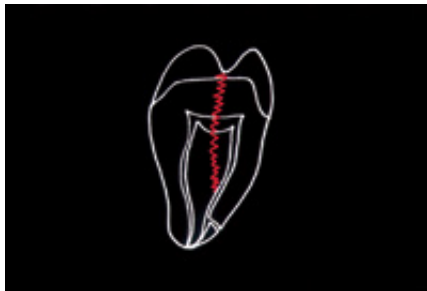


Figure 4a. Schematic of class III fracture: incomplete vertical fracture involving the attachment apparatus.

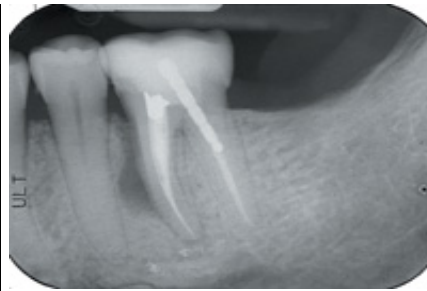

Figure 4b. Pretreatment radiograph of mandibular first molar demonstrating a class III fracture.

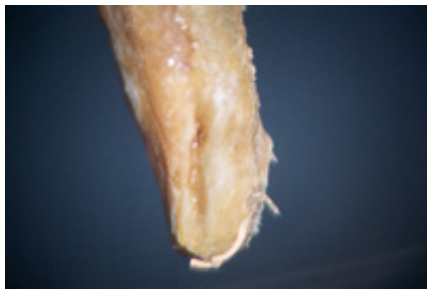

Figure 4c. The mesial root has been amputated and the fracture is observed.

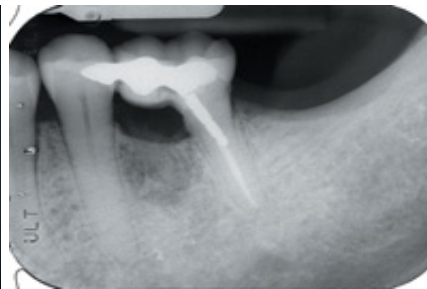

Figure 4d. A 10-year recall of hemisection and restoration.

Treatment. In most cases the best treatment is extraction. However, certain procedures may be attempted if the tooth is particularly important either functionally or aesthetically (Figures 4a through 4d). The clinician can band the tooth, treat any acute symptoms, and observe the results. Cleaning the root canal system will eliminate the endodontic component. If the tooth has shallow probing depth in the area of the fracture line, and if the tooth becomes asymptomatic with biting following banding, then the clinician can consider proceeding with endodontic treatment and a crown. This should not be the treatment plan unless the clinician is certain the patient understands that the prognosis is uncertain.

Class IV: Complete Separation of Tooth Fragments

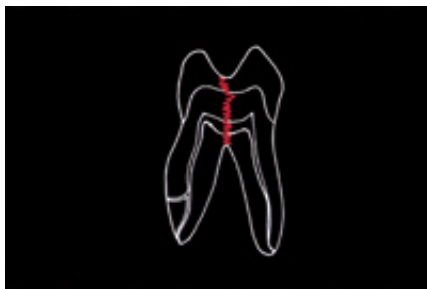


Figure 5a. Schematic of class IV fracture: fracture divides the tooth.

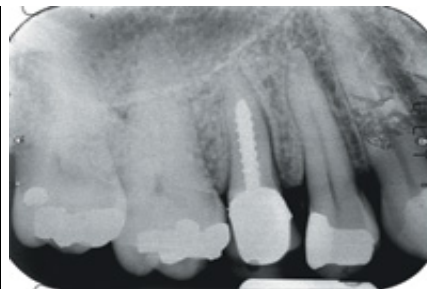

Figure 5b. Pretreatment radiograph of class IV fracture.

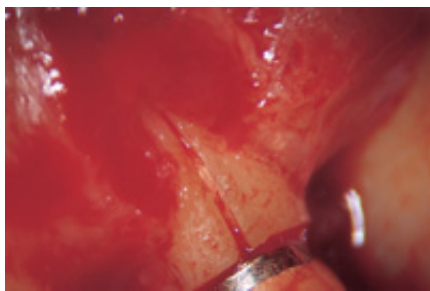


Figure 5c. Demonstration of class IV fracture. This tooth has a hopeless prognosis.

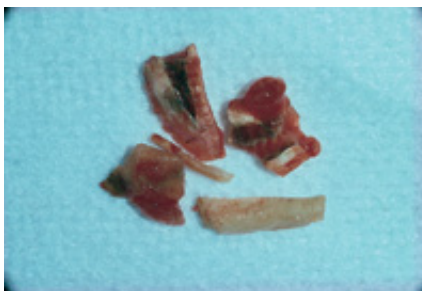


Figure 5d. Fragments of the tooth after removal.

This type of fracture is through the crown, extends subgingivally, and one or more parts of the tooth are mobile (Figure 5a). The mobile portion needs to be removed, and if what is remaining is restorable, the endodontic involvement is treated and the tooth restored. The ability to restore the crown must be considered in the approach to treatment (Figures 5b through 5d).

Symptoms. History of fracture symptoms, bite pain, and gingival swelling or inflammation.

Diagnosis. Deep and narrow periodontal defect.

Treatment. Extraction of all or a portion of the tooth.

Class V: Retrograde Root Fracture

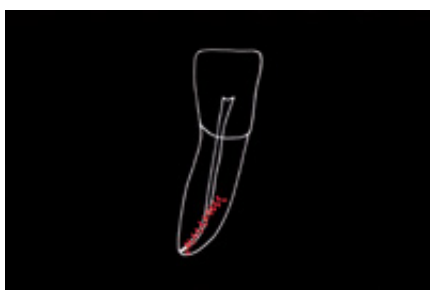

Figure 6a. Schematic of class V fracture: apically induced fracture.

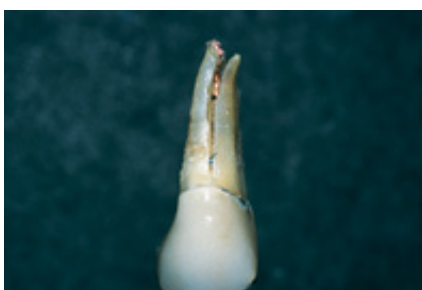


Figure 6b. Clinical example of class V fracture: apical fracture.

These fractures originate at the apex and travel coronally (Figures 6a and 6b). They are iatrogenic in nature, resulting from overzealous preparation of the root canal, the obturation of the apical root canal system, or inappropriate post placement. Root amputation or extraction is the only solution. The challenge is to rule out other causes besides a vertical root fracture. A failing root canal treatment can appear as a vertical fracture on the radiograph. Often, a root with a vertical root fracture will have a lesion of endodontic origin that is parallel to the side of the root. The typical radiographic appearance of a failing endodontic procedure is rounded lucency, with its center point being the portal of exit from the failing root canal system. The typical radiographic appearance of a vertical fracture is round at the apex (similar to the typical lesion of a failing root canal), but the lesion will over time move coronally along the root. The coronal edge of the lesion will form a knife-edge with the periodontal ligament.

When evaluating a lesion that over time progresses coronally along a root, note that a failing root canal with an undersealed accessory canal will also give a similar picture. These complications are rarely seen by the general practitioner because they are observed either after extraction or during endodontic surgery. It is important, however, to understand the associated symptoms. Generally, when dealing with a root fracture, the sensation the patient reports will be fairly continuous. In the case of a failing endodontic procedure, the symptoms will frequently vary over time. Some of the patient's symptoms include discomfort with manipulation of the tooth, pain on chewing, and vague discomfort since completion of endodontic treatment. There may be intermittent swelling.

The class V fracture usually occurs in a bucco-lingual direction. This is opposite to the direction of class I and class II fractures. Class V fractures frequently occur on the mesiobuccal root of maxillary first molars and the mesial roots of mandibular molars, and maxillary premolars and mandibular incisors. These problems can be seen when there are two canals in a root. Many times, the obturation quality looks acceptable. If a patient has had discomfort for several years, and endodontic therapy was performed several years ago, a fracture should be part of the differential diagnosis.

Symptoms. Tooth discomfort, sometimes vague.

Diagnosis. Radiographic, history, and observation during endodontic microsurgery.

Treatment. Extraction or endodontic surgery.

Lastly, note that the CTS occurs most often on mandibular second molars, followed by maxillary first molars, mandibular first molars, and maxillary first premolars.^{1,2}

SUMMARY GUIDELINES

- (1) Identify the tooth using a cotton wad.
- (2) Treat class I fractures with band and restore. Eliminate all centric and working contacts on noncentric holding cusps, ie, lingual cusps of mandibular posterior teeth and buccal cusps of maxillary posterior teeth.
- (3) Treat class II fractures with band plus endodontic therapy and restore unless symptomatic (see Flowchart).
- (4) Treat class III fractures with band and perhaps endodontic therapy, and restore, but extraction likely.
- (5) Treat class IV fractures by removal or root resection.
- (6) Treat class V fractures by removal or endodontic surgery.

CONCLUSION

The CTS presents both a challenge and an opportunity for the dentist. The number of CTS cases is increasing. Occlusally induced fractures can be divided into four classes based on symptoms and diagnostic tests. They may have a favorable prognosis. Apically induced fractures often have an iatrogenic etiology.

Author's Note

There are two noteworthy publications on the CTS. "Cracked Teeth" is a seven-page pamphlet that explains the types of fractures. It is written for patients. For dentists, the Fall/Winter 1997 issue of Endodontics: Colleagues for Excellence addressed the subject of "Cracking the Cracked Tooth Code." This particular publication provides a protocol for diagnosing the CTS and explains types of fractures, diagnostic clues, and treatment. Reprints of both publications can be obtained from the American Association of Endodontists, 211 E. Chicago Ave., Suite 1100, Chicago, IL 60611-2691.

References

1. Williams JJ. Cracked tooth syndrome: a new classification. *Dent Today*. 1993;June/July:34-39.
2. Cameron CE. Cracked tooth syndrome. *J Am Dent Assoc*. 1964;68:405-411.
3. Cameron CE. *J Am Dent Assoc*. 1976;93:971-976.
4. Christensen, G. The cracked tooth syndrome. *J Am Dent Assoc*. 1993;124:107-108.
5. Gutmann JL, Rakusin H. Endodontic and restorative management of incompletely fractured molar teeth. *Inter Endodontic J*. 1994;27:343-348.
6. Chemel D. Internal bonding of the cracked tooth syndrome. *Dent Today*. 1995;January:52-55.
7. Gibbs JW. Cuspal fracture odontalgia. *Dent Digest*. 1954;60:158.
8. Stanley HR. The cracked tooth syndrome. *J Am Academy Gold Foil Operators*. 1967;11:36-37.
9. Hiatt WH. Incomplete crown root fracture in pulpal-periodontal disease. *J Periodontol*. 1973;44:369-376.

Dr. West is founder and director of the Center for Endodontics in Tacoma, Wash. Dr. West is a member of the American Academy of Esthetic Dentistry and the International College of Dentists, and is an editorial advisory board member of *The Journal of Esthetic Dentistry* and scientific editor for Boston University's *Communique*. He is affiliate associate professor at the University of Washington School of Graduate Endodontics and clinical instructor at Boston University Henry M. Goldman School of Dental Medicine, where he was awarded the 1995 Distinguished Alumni Award. He coauthored "Obturation of the Radicular Space" with Dr. John Ingle, in Ingle's 1994 and 2001 editions of *Endodontics*, and was senior author of "Cleaning and Shaping the Root Canal System" in Cohen and Burns' 1994 and 1998 editions of *Pathways of the Pulp*.