

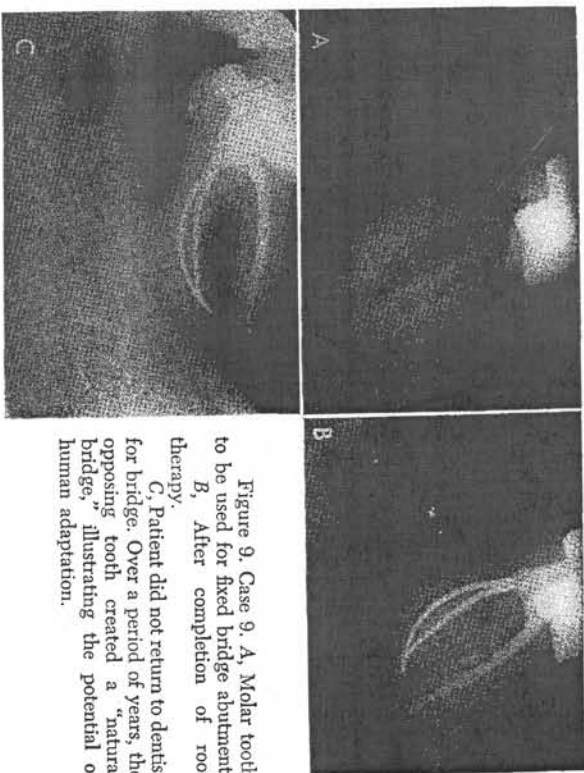Figure 9. Case 9. A, Molar tooth to be used for fixed bridge abutment. B, After completion of root therapy. C, Patient did not return to dentist for bridge. Over a period of years, the opposing tooth created a "natural bridge," illustrating the potential of human adaptation.

REFERENCES

1. Bender, I. B., Selzer, S., and Saltnoff, W.: Endodontic success—a reappraisal of criteria. *Oral Surg., Oral Med., Oral Path.*, 22:780, 1966.
2. Bender, I. B., Selzer, S., and Turkenkopf, S.: To culture or not to culture? *Oral Surg., Oral Med., Oral Path.*, 18:527, 1964.
3. Cameron, C. E.: Cracked tooth syndrome. *J. A. D. A.*, 68:405, 1964.
4. Grossman, I. I.: Roentgenologic and clinical evaluation of endodontically treated teeth. *Oral Surg., Oral Med., Oral Path.*, 17:368, 1964.
5. Nicholls, E.: Assessment of the periapical status of pulpless teeth. *Brit. Dent. J.*, 114:453, 1963.
6. Oilet, S.: Evaluation of methods for sterilizing root canal instruments. *Oral Surg., Oral Med., Oral Path.*, 9:666, 1956.
7. Selzer, S., et al.: Endodontic failures—an analysis based on clinical, roentgenographic, and histologic findings. *Oral Surg., Oral Med., Oral Path.*, 23:500, 1967.
8. Stewart, G.: A comparative study of three root canal sealing agents. *Oral Surg., Oral Med., Oral Path.*, 11:1029, 1958.
9. Williams, N. B., and Stewart, G.: A preliminary report on the efficacy of molten metal for the sterilization of root canal instruments and materials. *Oral Surg., Oral Med., Oral Path.*, 3:256, 1950.

Filling Root Canals in Three Dimensions

HERBERT SCHILDER, D.D.S.*

The final objective of endodontic procedures should be the total obturation of the root canal space. Biologic necessity requires the elimination of the protein degradation products, bacteria, and bacterial toxins which emanate from necrotic and gangrenous root canals. While these irritants may be eliminated by extraction of the tooth, the health of the dentition is secured more soundly if they are eliminated by the cleaning and shaping, sterilization, and total obturation of the root canal system. In the final analysis, it is the sealing off of the complex root canal system from the periodontal ligament and bone which insures the health of the attachment apparatus against breakdown of endodontic origin.

Under unusual circumstances (note paper by Dr. Siskin in this symposium), it may be necessary to seal off the root canal by means of a reverse root end filling, while incarcerating potentially injurious agents inside the tooth. For the most part, however, it is desirable and possible to clean and shape the root canals in their entirety, and to obturate them totally. Two important elements must be considered when judging the value of total obturation of the root canal system: 1. The inability to know with certainty whether the apex has been sealed in a nonsurgical procedure; 2. The existence of numerous accessory canals, many of which contain significant potential for the production of lateral root abscesses (see the paper by Dr. Langeland).

THREE-DIMENSIONAL FILLING

The problem faced by dentists doing root canal therapy procedures is in many ways analogous to the problems faced in filling any dental cavity. A space whose parameters vary infinitely from root to root or from tooth to tooth must be obliterated completely. In the case

of a coronal cavity, the space usually can be visualized easily, whereas in the case of the root canal system, the filling must be most complete in regions beyond the visibility of the dentist, deep at the apical foramen and at major accessory foramina. In operative dentistry, the margins of the cavity must be extended in certain ways to insure the removal of all carious dentin, to provide for the placement of a suitable filling, and to protect against redecah. Likewise, the cavity form developed in cleaning and shaping root canals must provide for the removal of all organic debris, give good access to the foramina, and offer a shape conducive to the placement of a dense permanent root canal filling. Inadequate obturation of the root canal invites failure as surely as does inadequate filling of a coronal cavity.

The objective of root canal filling procedures, therefore, should be the total three-dimensional filling of the root canals and all accessory canals. Too often in the past, the adequacy of a root canal filling procedure was based primarily on its vertical appearance on the dental radiograph. Excessive emphasis was placed on whether the filling reached the radiographic apex of the tooth, whether it overextended beyond the apical foramen, or whether it was short—presumably placed at the cementodentinal junction. In everyday practice, too little emphasis was given to the paramount problem of eliminating the root canal system as an entity, by its total obturation, in spite of significant data which were produced demonstrating astonishing failure in the absence of three-dimensional filling. What is required is a deeper appreciation of the importance of filling canals laterally and in depth as well as vertically, and then the adaptation of clinical technique to make the objective both simple and effective.

REVIEW OF ROOT CANAL FILLING TECHNIQUES

Many root canal filling techniques have been developed in the hope of achieving total root canal obturation. Most of the currently employed techniques use either a solid core and a cementing substance, or a plastic material which can be adapted more or less to the shape of the root canal system.

The two most popular solid cores are gutta percha and silver cones. Silver cones are used always with a suitable cement. Gutta percha cones may be used with a cementing material, or they may be rendered plastic with various solvents and used without root canal cement. A brief review of the more popular methods of using gutta percha and silver cones is helpful in the evolution of a technique which may most closely fulfill the requirements of a permanent three-dimensional root canal filling.

GUTTA PERCHA TECHNIQUES

Solvent Techniques

Gutta percha may be dissolved in various solvents, such as chloroform, oil of eucalyptus, or xylol. When dissolved in chloroform, a paste of chloropercha is formed, the thickness of which is determined by the amount of solvent used and by the amount which evaporates in the course of the filling procedure.

At the beginning of the filling visit, several pieces of gutta percha are cut into a dappen dish and stirred with a small amount of chloroform. The dappen dish should be covered with a glass slab to minimize evaporation of the chloroform as the gutta percha dissolves into it while the dentist is selecting his master gutta percha cone.

Gutta percha cones are available in many widths as well as in the standardized sizes which purport to conform to the standardized sizes of root canal reamers and files. Except insofar as the standardized gutta percha cones provide a greater variety of sizes available for selection, they are clinically of no special value. For example, a #40 gutta percha cone may not reach deeply into a curved root canal which has been prepared with a #40 file or reamer, since the flexibility and softness of the gutta percha may result in its binding and collapsing on its long axis at the first suggestion of lateral resistance, long before the apical end of the root canal has been reached. Good clinical judgment will quickly lead to the selection of a gutta percha cone which fits the canal reasonably well and is 1 or 2 mm. short of the end of the root.

A small amount of chloropercha is streaked onto the walls of the dry root canal with a fine root canal spreader or other suitable instrument. The apical third of the master cone is dipped into the chloropercha paste, and the entire master cone is gently repositioned into the canal. The material in the canal is now forced laterally with root canal spreaders, making room for additional gutta percha cones which are added repeatedly in sufficient number to provide a dense root canal filling. Each piece of gutta percha blends with the gutta percha and chloropercha already in the canal to form a homogeneous mass which conforms quite adequately to the configuration of the root canal system. The lateral pressure on the plastic gutta percha-chloropercha mixture automatically imparts a small vertical component of pressure, owing to the shape of most prepared canals. The entire mass moves apically during lateral condensation with any solvent technique.

Many variations of solvent techniques have been used successfully in addition to the basic chloropercha or eucapercha methods. In the Callahan-Johnson diffusion technique, the root canal system is flooded with 95 per cent ethyl alcohol and then dried with paper points. The alcohol flooding and drying removes some organic and most aqueous

material from the walls of the canals. The canals are flooded again, now with a chlorosin solution. The chlorosin solution spreads extensively into inaccessible eccentricities in the root canal and into accessory canals as well. This solution acts as a solvent both for a previously prepared master cone and for fatty organic material, so that when the master cone and additional cones are added in the condensation procedure, dissolved gutta percha will diffuse effectively into otherwise inaccessible portions of the root canal system. Very good results have been obtained with these methods.

Some criticism has been directed toward the solvent techniques in spite of the excellent results which have been obtained by experienced endodontists. Since all of the solvents which have been used are highly volatile, a measurable amount of shrinkage takes place gradually as the root canal filling hardens. The amount of shrinkage varies directly with the amount of solvent used, and, if shrinkage is excessive, failure may result from the inadequate sealing of the root canal. Likewise, when excess solvent has been employed, it may be difficult to confine the plastic material to the root canals, and gross excess may be forced into the periodontal tissues. While this surplus in no way prejudices the final outcome of the case, the solvents are irritants, and considerable discomfort may occasionally occur until the chloroform has been carried away from the apical periodontium. The excess material is resorbed over a period of years with complete bone regeneration at the root apex.

The Nygaard-Ostby technique is a variation of the Callahan-Johnson method, where finely ground specially prepared gutta percha particles are spatulated with chloroform to produce the necessary paste which will be used in conjunction with the master gutta percha cone. This method is reported to reduce greatly both apical excess and the shrinkage in the final filling.

Lateral Condensation with Nonsolvent Cements

Gutta percha also has been used with nonsolvent cements. Grossman has set forth the properties of a good root canal cement as follows:

1. The cement should be tacky when mixed so as to provide good adhesion, when set, between it and the canal wall.
2. It should make a hermetic seal.
3. It should be radiopaque so that it can be visualized in the roentgenogram.
4. The particles of powder should be very fine so that they can mix easily with the cement liquid.
5. It should not shrink upon setting.
6. It should not stain tooth structure.
7. It should be bacteriostatic, or at least should not encourage bacterial growth.
8. It should set slowly.
9. It should be insoluble in tissue fluids.

10. It should be tissue tolerant, i.e., nonirritating to periapical tissue.
11. It should be soluble in a common solvent if it be necessary to remove the root canal filling.

These properties are incorporated in the Grossman nonstaining root canal cement, which is available as Procosol Nonstaining Sealer or Kerr Tubli-seal. The original Richert formula (Kerr sealer) and the Grossman silver cement containing precipitated silver, zinc oxide, and stabilite resin are equally useful and will not stain tooth structure when adequate access cavities and coronal restorations are employed (see the papers by Dr. Levin and Dr. Baraban).

In lateral condensation with a nonsolvent cement, the original gutta percha cone is selected to coincide as closely as possible to the shape and length of the root canal, and this is confirmed with a radiograph. The master gutta percha cone is then rolled in the cement and placed in position in the dry canal. This cone is now pressed laterally repeatedly with a root canal spreader, and a series of fine gutta percha cones are added until a dense filling has been obtained. The advantage of this method over the solvent techniques is that positive dimensional stability of the root canal filling can be anticipated, and there is less likelihood of carrying filling material beyond the root apex.

One disadvantage is that at no time is a homogeneous mass developed. The final filling consists of a large number of separate gutta percha cones tightly pressed together and joined by frictional grip and the cementing substance only. It is the gradual setting of the root canal cement which gives the digital illusion of homogeneity as the lateral condensation procedure continues. Only at the point where the coronal excess is removed with a hot instrument is true homogeneity established. By the nature of lateral condensation procedures with nonsolvent cements and the shape of most root canals, lateral condensation produces the densest filling in the middle and coronal thirds of the tooth, and the apical seal is little improved as additional cones are added. It should be clear, however, that in spite of criticism directed toward the value of this type of lateral condensation in establishing positive apical seal, the method does insure a thorough, dimensionally stable obturation of the major volume of the root canal. It offers the distinct advantages of greater control and greater patient comfort, and has been successfully employed by large numbers of dentists for many years.

SILVER CONE TECHNIQUES

Silver cones were introduced into endodontics about 40 years ago and have had a rather checkered career as a root canal filling material. They are always used in conjunction with a root canal cement. They are decidedly inert, dimensionally stable, and, except in the rarest in-

stances of manufacturing defect, they cannot be resorted. Their semi-rigidity permits them to be wedged forcibly toward the critical root apex, where they are expected to provide a hermetic seal for the root canal. As in the case of gutta percha, silver cones are available in a variety of widths and in standardized sizes which are intended to conform to the shapes of standardized reamers and files. Ideally, the silver cone should pass loosely through the coronal and middle third of a root canal and bind in the apical portion only. The shape and rigidity of silver cones make this possible in most instances.

Proper Fitting

A silver cone is not properly fitted unless it reaches very close to the root apex and cannot be pushed farther with any amount of pressure. For this reason, silver cones should be manipulated with silver cone pliers specifically designed for this purpose, such as the Anteos silver cone pliers. Hemostats cannot provide the kind of pressure necessary for the forcible seating of silver cones.

Great care must be taken in the proper selection and fitting of silver cones. It is fantasy to expect a canal that has been cleaned and shaped with a certain number reamer or file to be obturated by a silver cone of the same size. Should a dentist complete the shaping of a root canal with a #70 file, for example, the very fact that the #70 file can be placed to the root apex and removed again indicates that the apical portion of the canal must be wider than the apical end of the file. Usually, the difference in the respective diameters of the root canal and the final reamer or file is considerable, and a silver cone of the same size as the last cutting instrument will fit too loosely at the apical end of the canal. Two possibilities exist: namely, that the tip of a silver cone which fits too loosely may be cut off step by step until by trial and error a tight fit at the apex is obtained, or that a silver cone somewhat wider than the last cutting instrument can be selected and its apical end narrowed somewhat until it binds tightly at the root apex.

When using silver cones, I prefer the latter method of gradually shaving down a slightly oversized cone. The apical 3 or 4 mm. of the silver cone are placed within the abrasive surfaces of a folded-over medium grit $\frac{7}{8}$ -inch sandpaper disk. By pressing the folds of the disk tightly over the silver cone with the thumb and index finger of the left hand, and rotating the silver cone back and forth rapidly with the thumb and index finger of the right hand, a gentle taper is imparted to the silver cone. This taper permits the silver cone to be locked into position at the end of the root canal while importantly increasing the surface area over which the cone and root canal walls are in contact. This extra effort is well worthwhile, and will be rewarded by greatly increased success rates where silver cones are used.

The nature of the "locking," "binding," or "fitting" of silver cones

in root canals must be understood if consistent success is to be achieved. While both silver and dentin are slightly compressible, they are both substances of considerable firmness. It is possible, therefore, for a silver cone to bind in an eccentric root canal, although it contacts the walls at only two points. Indeed, this happens not infrequently. Although elliptical root canals tend to become round in their apical thirds, they are never geometrically round, and it is doubtful if the best directed efforts of any endodontist will make them geometrically round. It has been observed that in inexperienced hands root canal instrumentation often results in canals with elliptical or teardrop shaped foramina. Great attention must be paid to maintaining or developing roundness at the apical foramen if success is to be achieved with silver cones. To the extent that the apical portion of the root canal is eccentric, the seal at the apex will depend on root canal cement, or the seal will be deficient when silver cones are used. To the extent that the apical portion of the canal approaches roundness, the compressibility of silver and dentin will provide a permanent apical seal.

A correctly fitted silver cone is one which reaches to the end of the cleaned shaped canal, which cannot be forced farther with strong pressure, and which offers resistance to removal before cementation. A silver cone which cannot be pushed deeper, but which can be withdrawn without frictional resistance is sitting on a ledge in the root or against bone, but it does not seal the foramen. This is a very common error in the buccal roots of upper molars, where many silver cones are fitted against the zygoma without sealing the root canals. This condition can be diagnosed and corrected if small portions of the apical end of the cone are cut off and it is found that the silver cone still appears to stop at the root-end radiographically. Clearly, then, dense bone and not frictional grip has prevented the silver cone from being pushed farther. By repeated reduction at the end of the silver cone, the cone will be made to fit so that it can neither be forced deeper nor be removed from the canal without considerable effort. It is now ready for cementation.

Another point must be borne in mind. Silver cones were sometimes recommended for use especially in extremely narrow and curved canals. Nothing could be more incorrect unless the canals were first shaped and enlarged considerably. The #3 silver cone is the minimum sized one that can possibly seal an apex. A #2 silver cone may be threaded or teased into a narrow, underprepared root canal, but it defies logic to expect such a slender wire introduced at the coronal end of the canal to offer a frictional seal at the apical foramen. It was the improper use of silver cones in this way, as well as the occasional defective cementation of silver cones, which led to objections to the use of silver cones from time to time. Silver cones almost always provide esthetic radiographs, but it is only the dentist who checks the case several years later who can determine the thoroughness of the obturation.

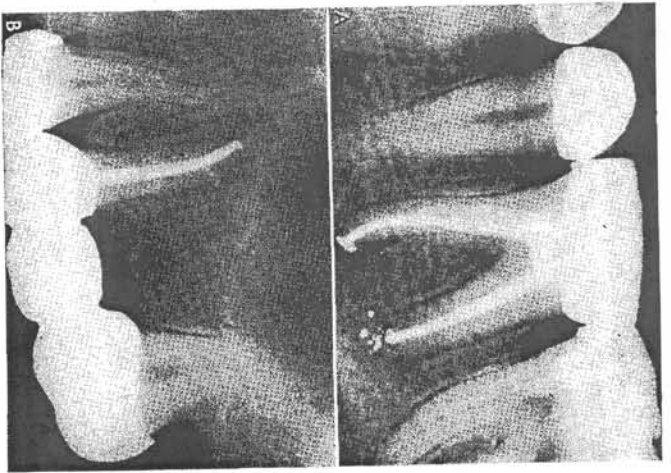


Figure 1. Silver cones are used always in conjunction with a cement and often with lateral gutta percha as well.

A, A lower molar where the mesiolingual and mesiobuccal canals shared a common foramen. Both the distal and mesiolingual canals were obturated with silver cones, while warm gutta percha was plugged into the mesiobuccal canal. The rather typical puff of cement at the apex of the mesial root resulted from the initial cementation of the mesiolingual cone and not from the pressure developed subsequently in the buccal canal. This verified the fit of the mesiolingual silver cone.

B, An upper premolar, where a lateral canal was filled while gutta percha was forcibly plugged alongside a recently cemented silver cone. In this case, too, the apical puff is typical, and is looked for as an indication that the silver cone has been cemented along its entire length. The apical cement was not increased by the vertical pressure which forced cement into the lateral canal. Note the bone resorption that had occurred opposite the unfilled accessory foramen.

Cementation of Silver Cones

Any of the above-mentioned root canal cements may be used with silver cones. A small amount of cement should be introduced into the root canal first, and then the silver cone may be rolled in the cement and gradually replaced into the canal. Gradual seating of the silver cone will prevent excess cement from extruding past the root apex as well as obviate pressure discomfort to the patient caused by air being compressed against the periodontal tissues. The seating of a silver cone should be as certain as the seating of a well-made gold inlay. As it takes its position at the root apex, it may be rotated slightly to increase the wedging

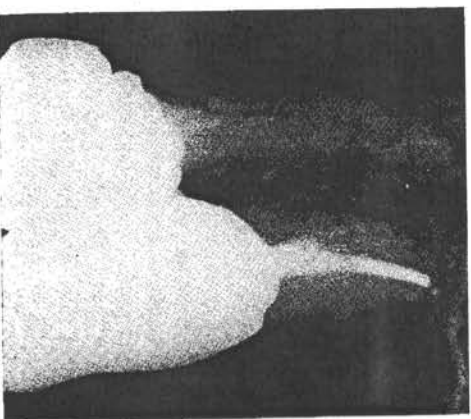
effect near the foramen. Some men, fearful that cement may be deposited outside the canal, only roll the cone in cement and do not introduce cement into the canal prior to the final placement of the cone. If no cement is placed in the root canal ahead of the silver cone, the cement on the cone quite often wipes off halfway up the canal, so that the apical portion of the cone is placed in position without any cement at all. The basic problem of sealing potentially eccentric foramina with relatively round silver cones requires that a film of cement be provided along the entire length of the cone. A properly fitted and cemented silver cone cannot be removed after the cement has set without the use of much solvent (alcohol, chloroform, xylol, etc.) and much mechanical effort. Some can never be removed. Silver cones which can be removed easily were not properly fitted and cemented.

Since silver cones rarely fill the root canals laterally, the remaining space also must be obturated in some manner. In narrow canals, the lateral space sometimes is filled with root canal sealer only. In wider, more tapering canals, gutta percha or additional silver cones may be condensed laterally beside the nail silver cone. In all silver cone cases, I prefer to place warm pellets of gutta percha in the floor of the pulp chamber adjacent to the silver cone or cones, and to press the gutta percha apically around the silver cones with narrow root canal pluggers (Fig. 1). The gutta percha may be rewarmed from time to time with a heated spreader and the softened mass forced repeatedly into the mouth of the root canal. Many lateral canals are filled in this manner.

Split Cone Technique

A variation of the above technique may be employed where a cast post is needed to support a coronal restoration. This variation has been

Figure 2. The split silver cone technique in an upper second premolar. The apical plug of silver, perhaps 4 to 5 mm. long, is seen wedged at the root apex. A cast crown has been built upon a gold post placed in the coronal third of the root canal, and the tooth helps to support a partial denture. The apical puff of cement has been resorbed almost fully from this old silver cone case.



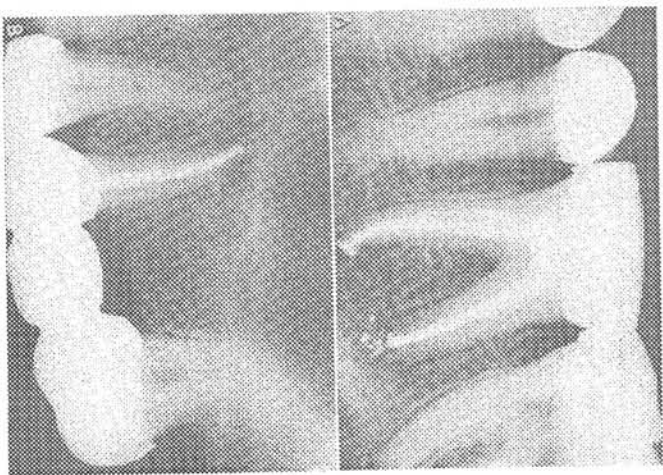


Figure 1. Silver cones are used always in conjunction with a cement and often with lateral gutta percha as well.

A. A lower molar where the mesiobuccal and mesiobuccal canals showed a common foramen. Both the distal and mesiobuccal canals were obturated with silver cones, while warm gutta percha was plugged into the mesiobuccal canal. The rather typical puff of cement at the apex of the mesial root resulted from the initial cementation of the mesiobuccal cone and not from the pressure developed subsequently in the buccal canal. This verified the fit of the mesiobuccal silver cone.

B. An upper premolar where a lateral canal was filled while gutta percha was forcibly plugged alongside a recently cemented silver cone. In this case, too, the apical puff is typical and is looked for as an indication that the silver cone has been cemented along its entire length. The apical cement was not increased by the vertical pressure which forced cement into the lateral canal. Note the bone resorption that had occurred opposite the unfilled accessory foramen.

Cementation of Silver Cones

Any of the above-mentioned root canal cements may be used with silver cones. A small amount of cement should be introduced into the root canal first, and then the silver cone may be rolled in the cement and gradually replaced into the canal. Careful seating of the silver cone will prevent excess cement from extruding past the root apex as well as obviate pressure discomfort to the patient caused by air being compressed against the periodontal tissues. The seating of a silver cone should be as certain as the seating of a well-made gold inlay. As it takes its position at the root apex, it may be rotated slightly to increase the wedging

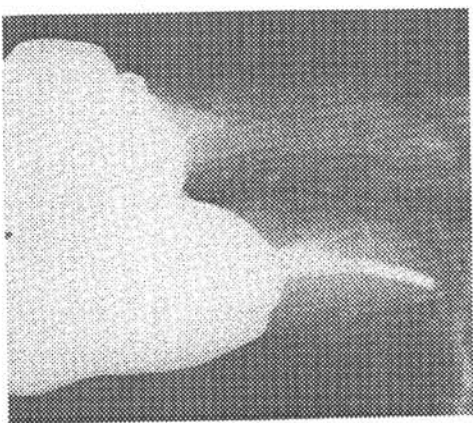
effect near the foramen. Some men, fearful that cement may be deposited outside the canal, only roll the cone in cement and do not introduce cement into the canal prior to the final placement of the cone. If no cement is placed in the root canal ahead of the silver cone, the cement on the cone quite often wipes off halfway up the canal, so that the apical portion of the cone is placed in position without any cement at all. The basic problem of sealing potentially eccentric foramina with relatively round silver cones requires that a film of cement be provided along the entire length of the cone. A properly fitted and cemented silver cone cannot be removed after the cement has set without the use of much solvent (alcohol, chloroform, xylol, etc.) and much mechanical effort. Some can never be removed. Silver cones which can be removed easily were not properly fitted and cemented.

Since silver cones rarely fill the root canals laterally, the remaining space also must be obturated in some manner. In narrow canals, the lateral space sometimes is filled with root canal sealer only. In wider, more tapering canals, gutta percha or additional silver cones may be condensed laterally beside the root silver cone. In all silver cone cases, I prefer to place warm pellets of gutta percha in the floor of the pulp chamber adjacent to the silver cone or cones, and to press the gutta percha apically around the silver cones with narrow root canal pluggers (Fig. 1). The gutta percha may be returned from time to time with a heated spreader and the softened mass forced repeatedly into the mouth of the root canal. Many lateral canals are filled in this manner.

Split Cone Technique

A variation of the above technique may be employed where a cast post is needed to support a coronal restoration. This variation has been

Figure 2. The split silver cone technique in an upper second premolar. The apical plug of silver, perhaps 4 to 5 mm. long, is seen wedged at the root apex. A cast crown has been built upon a gold post placed in the coronal third of the root canal, and the tooth hinges to support a partial denture. The apical plug of cement has been reabsorbed almost fully from this old silver cone case.



presented under many names, but it is usually recognized as the split cone technique. The silver cone is fitted carefully as above. Before cementation, however, the cone is scored deeply with a disk or bur at some distance from its apical end. Cementation proceeds as indicated, but after the cone has been seated well, its coronal end is rotated repeatedly along its long axis. While rotating, firm apical pressure is applied through the pliers to prevent unseating at the root apex. As the rotary motion continues, the cone will be severed at the score line, and all but the apical portion removed. The middle and coronal parts of the canal are now available for impressions for a post, or the deeper portion of the canal may be filled with warm gutta percha condensed vertically against the apical segment of the silver cone and cement (Fig. 2). Interestingly, this condensation provides a severe test for the apical fit of the silver cone. If the apical segment cannot be moved beyond the foramen under the tremendous pressure that is imparted to it through the warm gutta percha, the dentist can be assured that some form of apical wedging has been effected. If, on the other hand, cement or gutta percha can be extruded outside the canal beyond the stationary silver cone, then the apical wedging was to some extent incomplete. Fortunately, most silver cones will remain stationary under this test; but, unfortunately, extrusion can be produced in almost half the cases.

Hundreds of thousands of cases have been treated successfully with well managed silver cones, but extrusion past stationary apical segments makes one wonder if a more effective manner of root canal obturation cannot be employed.

VERTICAL CONDENSATION WITH WARM GUTTA PERCHA

It would seem desirable to fill root canals with a homogeneous, inert, dimensionally stable, physiologically acceptable material which could be manipulated with sufficient plasticity to form a permanent cast of the internal configuration of the root canal system. Borrowing heavily from the experience gained by others in the development and use of the above techniques, and from my own clinical and laboratory experience with them, I now favor warm gutta percha as the filling material of choice for most root canals. The value of gutta percha in endodontics has long been established, and its use in a plastic state, without dependence on solvents, imparts to the filling the dimensional stability which sometimes was lacking in the past. Of equal importance, the use of warm gutta percha with *vertical condensation* permits great density to be created in the apical portion of the filling. Last, no other technique provides for the filling of accessory canals and foramina with such frequency as warm gutta percha used in conjunction with vertical condensation (Fig. 3).

In order to employ the warm gutta percha technique, the root canal must be shaped so that a continuously tapering funnel is created with its narrowest diameter at the periodontal ligament and its widest diameter at the coronal opening or access cavity (see the paper by Dr. Levin). However this funnel may curve, it must be progressively wider coronally. This continuous taper permits the introduction into the canal of a graded series of pluggers with which the gutta percha is wedged apically.

The materials to be employed are gutta percha and an acceptable root canal cement. The only mechanical instruments necessary are a lentulo or paste filler, one root canal spreader or heat carrier, and the graded series of pluggers.

THE MASTER GUTTA PERCHA CONE

The original piece of gutta percha must be carefully selected so that its taper is more gradual than the taper of the root canal. For this reason, it is important to reject gutta percha cones which are too pointed, since they will bind somewhere within the body of the canal and not near the apex. It is preferable to cut off the apical end of a less heavy

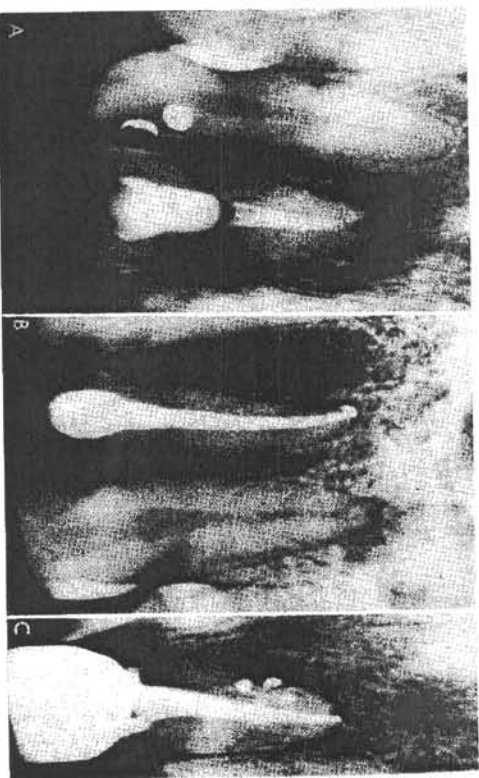


Figure 3. A, This case was specially selected to illustrate the problems that may occur when cold gutta percha is used with inadequate lateral condensation. It is not typical of good lateral condensation cases. Both the apical fit of the gutta percha and its lateral adaptation to the walls of the root canal are defective. A fistular opening has erupted on the labial alveolus.

B, A typical example of a dense homogeneous root canal filling obtained with warm gutta percha. The solidity of the apical obturation is most important.

C, Another fairly routine maxillary anterior tooth filled with vertical condensation of warm gutta percha. Three accessory foramina as well as an additional one through the plane of the film have been filled.

gutta percha cone than to select a heavier gutta percha cone with a fine tip. In any event, the apical end of the master gutta percha cone must be wider than the apical end of the root canal. The task, then, is to insure the seal by forcibly wedging the gutta percha into the narrower portion of the shaped canal.

A small amount of root canal cement is introduced into the root canal by means of a lentulo, which is rotated clockwise between the thumb and index finger. Care should be taken to use as little cement as possible, and only enough to streak the walls in several places is necessary. On the one hand, it is undesirable to have any large portion of the final filling composed of the potentially resorbable cement; on the other hand, a small amount of cement is fully adequate for spreading over all the surfaces of the canals after condensing pressure has been applied to the warm gutta percha.

The apical end of the properly sterilized master cone is dipped in the cement, and the gutta percha is introduced into the dry root canal. Care should be taken to deliver the gutta percha cone gently back to its original position so as not to force cement apically. This should be checked radiographically. With the use of rapid developers, in less than a minute the dentist is prepared to begin the vertical condensation.

VERTICAL CONDENSATION

The Heat Carrier

The coronal end of the gutta percha cone is seared off with a hot spreader, and the warm end which remains in the tooth is folded into the pulp chamber with a broad plugger. It is well to remember that pluggers differ from spreaders in that, regardless of their width, pluggers have blunt ends, whereas the ends of spreaders are pointed. In this technique, the pluggers are always used cold, whereas the spreader is only used hot. The spreader is not used to "spread" gutta percha, as is common in lateral condensation techniques, but only to carry heat which softens the gutta percha sufficiently to allow vertical condensation with the pluggers. The pluggers must never be heated, since heat will make them stick to the gutta percha and will soften the metal, rendering the instrument useless for the application of strong vertical pressure. A change in term from "spreader" to "heat carrier" is suggested, since at no time should this hot instrument be directed laterally in this technique.

The heat carrier is now heated to cherry redness, and it is brought quickly to the root canal, where it pierces the coronal 3 or 4 mm. of the gutta percha. Immediately after the gutta percha is softened, the heat carrier is removed and a suitable plugger is applied to the plastic mass, forcing it apically. It must be understood clearly that gutta percha is an

excellent insulating material, and that only the gutta percha near the heat carrier is softened. Gutta percha several millimeters beyond the cervical region is completely unaffected by any condensation at this point. As the process of reheating and plugging continues, a three-dimensional vertical condensation in the cervical region is achieved first, while the middle and apical thirds of the canal remain relatively unaffected.

After the canal has been filled laterally and in depth in the cervical region, the heat carrier can be used not only to soften the gutta percha but to remove portions of it as it is withdrawn from the main mass of material. By this means, the 3 or 4 mm. plunges of the heated instrument will progressively soften deeper portions of the gutta percha, while removing portions of the gutta percha at the working end of the canal. Sequential strong vertical condensation with the graded series of pluggers will slowly carry a wave of condensed gutta percha down into the middle portion of the root canal, which in its turn will be filled laterally and in depth. This wavelike condensation with warm gutta percha extending to a depth of 3, 4, or 5 mm. at a time will effectively seal lateral canals which are large enough to receive filling material. At this time, the apical portion of the gutta percha cone is still unaffected. A radiograph should be taken when the pluggers are brought to bear approximately halfway into the depth of the root. In this way, the dentist can prepare himself for the movement of the apical plug of gutta percha up to the root surface.

In order to simplify the depth perception which is necessary in delivering the apical plug of gutta percha tightly to the apex, 5-mm. indications have been scored into the pluggers. The dentist can readily compare the length of his last reamer or file with the score lines on the pluggers and judge his progress toward the root apex.

Apical Filling and Lateral Canals

It is only after a series of heatings, condensations, and gutta percha removals that the hot spreader can soften the apical portion of the gutta percha. With experience, the dentist can now deliver this portion of gutta percha progressively into cross-sectional portions of the apical end of the canal, into which it could not fit in its original solid state. The gutta percha fully adapts itself to the infinite anatomic complexities of the root canal, forming a cast of its interior while filling the major apical accessory canals (Fig. 4). The root canal is now essentially empty, except in its apical end. The remaining portion of the canal is filled with warmed segments of gutta percha, 2, 3, or 4 mm. in length which have been previously selected to conform to the diameters of the root canal pluggers and the canal. One by one these plugs of gutta percha are heated and condensed vertically as described above, but with no attempt to remove material with the heat carrier. No cement at all is used in this phase,

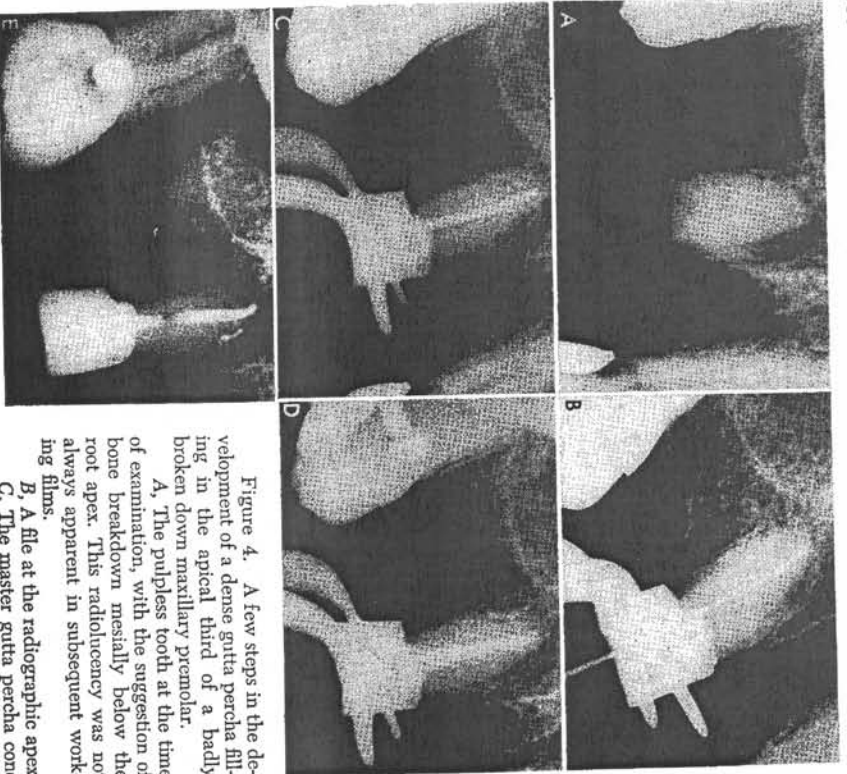


Figure 4. A few steps in the development of a dense gutta percha filling in the apical third of a badly broken down maxillary premolar.

A, The pulpless tooth at the time of examination, with the suggestion of bone breakdown mesially below the root apex. This radiolucency was not always apparent in subsequent working films.

B, A file at the radiographic apex.

C, The master gutta percha cone selected so that the cone binds apically only. Still, the cross-sectional diameter of the gutta percha is too great to fit into the apical end of the canal.

D, The master cone is shown cemented into the root canal. Care has been taken to prevent root canal cement from preceding the master cone. Vertical condensation has been started only in the coronal third of the canal.

E, Here can be seen what has happened after the gutta percha was repeatedly heat softened, vertically condensed, and partially removed. A wave of condensation moved apically, and finally the gutta percha was delivered to the root apex, as a lateral canal leading to the mesial radiolucency area was filled. No reverse wave of condensation took place here, but a pellet of cotton was placed in the canal to prevent temporary cement from blocking the space that will be used for a cast post.

and a new wave of vertically condensed gutta percha passes through the root, reversing the direction of the original movement. In this manner, the root canal is filled three-dimensionally with a solid core of inert gutta percha and a minimum amount of potentially resorbable paste. Should it be deemed desirable to use a cast core in restoring the tooth, the repacking of the canal cervically can be stopped at any

distance and the depth of the post space approximated accurately by the score lines on the pluggers.

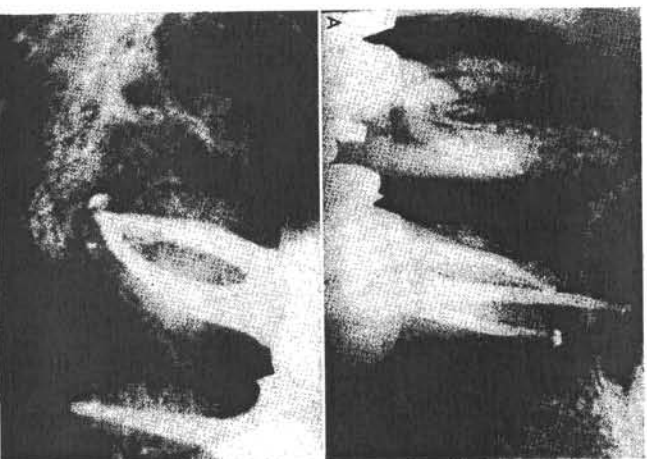
It must be recalled that only a minimum amount of cement is to be used, since the firm vertical condensation of the gutta percha mass will spread the cement uniformly under enormous hydrostatic pressure. Indeed, lateral canals which are too fine to receive the warm gutta percha will be filled by the cement. Although this is less desirable than filling with gutta percha, it is preferable to leaving them unobturated.

Fears that the gutta percha will shrink on cooling are groundless. While molten gutta percha does contract on solidifying, at no time in this technique is the apical gutta percha in contact with the heat carrier. It is softened only by proximity to the heat source, and actually moves only under firm pressure. In no part of the filling is the gutta percha liquefied, and considerable attention must be placed on the prompt delivery of the heat carrier to the gutta percha lest the heat be inadequate to soften the gutta percha at all. It is control of the amount of heat in the spreader which determines whether the gutta percha is to be softened or is to be removed. If the instrument is not heated sufficiently, the gutta percha will harden on it, and excessive portions of the filling will be inadvertently carried away. Also, the repetitions nature of the heating and condensation in this technique is similar to the paint-on

Figure 5. Canals of posterior teeth also may be filled with warm gutta percha and vertical condensation.

A, A maxillary second molar with three canals obturated with warm gutta percha. The apical pulps are somewhat typical and indicate the completion of the filling.

B, A mandibular second molar where all canals share a common foramen. The root canal system has been filled three-dimensionally as well as a fine network of accessory canals near the apex.



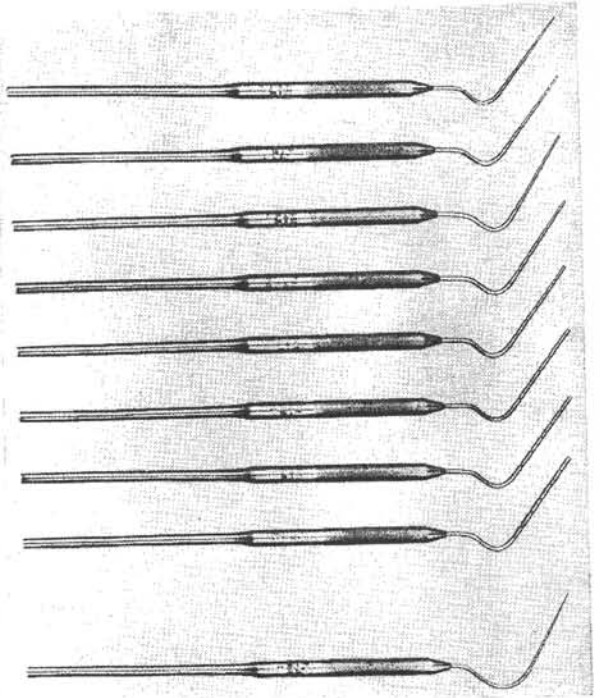


Figure 6. Lines have been scored into the pluggers at 5-mm. intervals to indicate the effective level of condensation at all times. The measurements also permit the intelligent prefitting of the pluggers to be used at each level before the actual filling procedure commences. By the addition of half sizes, a more useful series of pluggers has been developed.

technique with acrylic filling materials. The application and reapplication of pressure on the gutta percha as it cools with the continuous augmentation of material eliminates the significance of dimensional change as the temperature drops (Fig. 5).

This technique incorporates many elements of the sectional method of filling root canals. In the sectional method, segments of gutta percha too wide to fit the apical end of the root canal are forcibly wedged into position piece by piece until a complete root canal filling has been achieved. The pieces may be warmed or pressed in cold, in which case solely the compressibility of the gutta percha is relied upon to insure the seal. The sectional technique lacks the first wave of condensation from the cervical to apical portions of the root, and does not take advantage of the continuous resoftening of the gutta percha to improve its adaptation to the walls of the root canal system.

Vertical Condensation Pluggers

The pluggers for the warm gutta percha technique are not dissimilar to the pluggers used in lateral condensation. As has been mentioned, it was found convenient to place score lines on the pluggers

at 5-mm. intervals. Also, both to simplify and to perfect the filling, a more evenly graded series of pluggers was required, and half sizes have been added to the regular series. A complete series of these instruments is made by the Star Dental Manufacturing Company, and includes numbers 8, 9, 9½, 10, 10½, 11, 11½, 12, although most vertical condensation is found to be done with numbers 8 through 11 (Fig. 6). Where a plugger must be bent in order to conform to a curved canal, it should be left in its new shape and used again only for a similarly curved canal. Rebending the instrument will soften it or lead to breakage, and in either case it will be rendered useless.

Prefitting of Pluggers

Two additional points must be made about the use of the pluggers. One is that a small amount of dry cement powder may be used as a separating medium on the end of the pluggers to keep warm gutta percha from adhering to them. The other is that, to plan the root filling procedure most intelligently, the pluggers should be prefitted into the canal. A plugger which cannot fit to within a few millimeters of the end of a canal will be valueless in obturating the apical end of the canal. Attempting to force a plugger deeper into a canal than its own cross-sectional diameter will permit results in lateral pressure of metal against dentin, instead of vertical pressure of metal against gutta percha. It is decidedly possible to split a longstanding pulpless tooth by needless wedging with an oversized plugger. Prefitting will prevent unnecessary root splitting, will insure that proper instruments are available to reach the apical third of the canal, will help the dentist plan the sequence of pluggers he will use in any given case, and may indicate areas where the shaping of the root canal should be improved.

VERTICAL EXTENT OF ROOT CANAL FILLINGS

It should be clear that the totality of the three-dimensional filling of the root canal is more important than its vertical extent alone. What significance should be given, then, to so-called "underfilled" and "overfilled" root canals?

CEMENTODENTINAL JUNCTION

Many endodontists rely on filling root canals to the cementodentinal junction. The cementodentinal junction is, theoretically, the point which divides the pulp tissue from the tissue of the periodontal ligament. This junction is usually found some small distance within the apical end of the root canal and at a somewhat constricted portion of the

apical opening. Filling to this point, it is assumed, fills the root canal without impingement on the periapical tissues and encourages the eventual physiologic closure of the root canal with cementum. In order to fill to the cementodentinal junction, the endodontist relies either on his sense of feel or he fills all canals .5 to 1 mm. short in the hope of ending the root canal filling properly. Countless successful cases have been obturated in this manner.

Filling to the theoretical cementodentinal junction is not an unmixed blessing. Studies of the anatomy of root canals indicate clearly that the position of this line is highly variable from one tooth to another, and even from one wall to the opposite wall of the same root. The cementum may join the dentin .5 mm. inside the root on one surface, and 3 or 4 mm. inside on the opposite surface; or, owing to a variety of causes, the cementodentinal junction may occur outside the root canal completely. Feeling for the apical constriction, while not an infallible guide in the hands of the experienced endodontist, can be very difficult for less experienced operators. Also, the closure of the root end with cementum, while both possible and desirable, is demonstrable much more readily in animal experimentation than in human patients, and is unnecessary for the health and function of the apical periodontium. The success which has been encountered in filling to this point has resulted more likely from the care with which the root canals were instrumented and by the lateral completeness of the fillings than from apical closure with cementum. A root canal system filled in three dimensions to within .5 or 1 mm. of its radiographic apex is essentially filled to its entirety. The shortness of such a filling should in no way be quated with the massive underfilling produced by a laterally incomplete filling procedure, regardless of the vertical extent of the filling material.

РАДИОГРАФИЧЕСКИЙ АПЕКС

Other endodontists prefer to fill to the radiographic apex or, more precisely, to the point where the root canal appears to join the periodontal ligament as viewed in a roentgenogram. Fillings carried to this point may more closely approach the 100 per cent total filling of the root canal system, but are probably overextended beyond the root canal by a fraction of a millimeter in most cases, owing to the physics of dental radiography. Countless teeth have been treated successfully to this point as well, indicating the high degree of tolerance of the periodontal tissues for most root canal filling materials. It should be observed that some markedly curved canals exit their roots at a point which is invisible radiographically, and that filling of root canals to the radiographic limitation of the root is to be avoided in such cases.

The enormous success which has followed filling root canals to their

radiographic apices or beyond has led some to theorize that healing of large periapical radiolucencies may be stimulated by root canal filling material outside the confines of the canal. While this may be possible, it is more likely that, as in the case of filling to the cementodentinal junction, continued success results from the thoroughness of the three-dimensional filling along the major extent of the root canal and not on fractional overextension or underextension of the filling. The wise old suggestion to slightly underextend root canal fillings in cases of vital extrusion and to fill to the radiographic apex or slightly beyond in cases of pulpal necrosis and gangrene is probably more meaningful in terms of patient comfort than in terms of the ultimate result.

OVERFILLING VERSUS OVEREXTENSION

An important distinction must be made between overfilling and underfilling, and overextension and underextension. Over and underextension refer solely to the vertical dimension of the root canal filling, beyond or short of the root apex. Underfilling refers to a tooth whose root canal system has been inadequately obturated in any dimension, leaving large reservoirs for recontamination and infection. An overfilled tooth is one whose root canal system has been filled in three dimensions, and where a *surplus* of material extrudes beyond the foramina. In spite of a long and conscientious search, I have never encountered a case of endodontic failure due to overfilling, where one means by "overfilling" that the root canal has been obturated in its entirety and surplus material has been intruded into the apical periodontium (Fig. 7). On the other hand, as have other endodontists, I have encountered numerous cases of failure of *vertical overextensions of underfilled root canals*. In the latter cases, gutta percha or silver cones which never did seal the circumference of the apical foramen were carelessly forced into the apical periodontium, where their presence added additional insult to the primary problem, namely the *underfilled* root canal.

The benign nature of most root canal filling materials, if the root canal system is properly sealed, has been demonstrated over decades of clinical practice. One must recall only the extrusions of the diffusion techniques, the classic Callahan button, the chloropercha and eucapercha surplusses of the solvent techniques, and, more recently, the intentional overfillings with metal posts in severe periodontal cases (see the paper by Dr. Frank) to realize that the vertical extent of the acceptable root canal filling within a 1-mm. range cannot be considered of major importance. Excess material beyond the cementodentinal junction probably plays no part in healing and should be avoided solely on the basis of its needlessness and its possible potential for discomforting the patient at the time of the filling procedure.

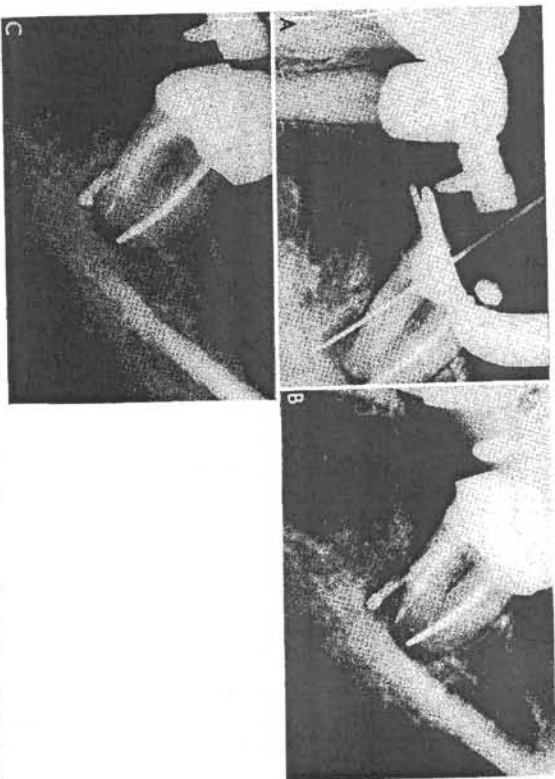


Figure 7. This tooth presented a history of a silver cone having been cemented in the distal canal many years previous to the more recent inadvertent perforation of the mesial root. The mesial root perforation apparently had led to a severe lateral abscess.

A, A large file passed easily through the perforation, giving some indication of its size and the extent of the associated bone destruction.

B, The periapical condition immediately after the sealing of the true foramen and the overfilling of the false canal with surplus gutta percha in the perforicular bone.

C, The case one year later. Very little resorption of the excess gutta percha has taken place as yet, but the alveolar bone has regenerated tightly against the surplus material. The slight void above the apical plug of gutta percha in the mesial root shows evidence of the segmented nature of the technique.

SUMMARY

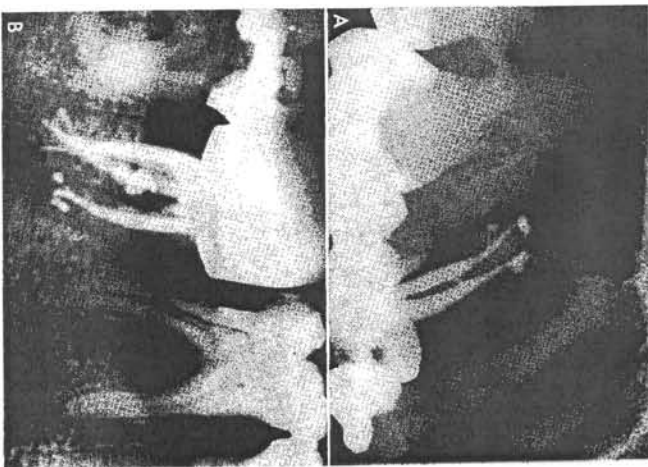
The ultimate objective of endodontic technique is the elimination of the root system as a source of infection and inflammation to the apical periodontium after irreversible pulp pathosis. The most desirable way to render root canals innocuous is to clean and shape them, to eliminate bacteria and tissue debris from within them, and then to obliterate them by means of a dense three-dimensional root canal filling.

Accessory canals are present in practically all teeth. Many accessory canals are very small and calcify spontaneously during chronic pulp irritation, and others contain too little tissue to be clinically significant. Often, however, accessory canals are of considerable size, and, where the tissue within them becomes necrotic or infected, they may contribute to lateral root abscesses unless sealed off from the periodontal ligament.

Figure 8. The filling of complex root canal systems with warm gutta percha and vertical condensation. Studies of root canal systems show them to be often highly complex, with multiple foramina.

A, An upper first premolar with three filled foramina in the buccal and lingual canals.

B, A lower second molar with five filled foramina as well as a lateral canal filled through the plane of the film in the mesial portion of the distal root.



Root canal filling procedures should be directed toward the filling of significant lateral canals as well as the filling of main root canals (Fig. 8).

Many techniques have been used to obturate root canals successfully. Most of these techniques employ either silver cones or gutta percha in some form. When used well, all of these techniques are valuable; when abused, no technique can succeed. The difficulty of adapting a silver cone to a less than geometrical round foramen sets certain potential limitations upon the use of silver cones in all cases. Likewise, small dimensional changes inherent in the use of gutta percha and a solvent, as well as certain problems of apical adaptation of the gutta percha when no solvent is used, encourages the evolution of a technique by means of which gutta percha is rendered plastic without the use of solvents.

Vertical condensation of warm gutta percha produces consistently dense, dimensionally stable, three-dimensional root canal fillings. Lateral canals are filled with extraordinary frequency, often with gutta percha, sometimes with cement.

The final test of a root canal filling is its capacity to seal off the root canal system from the periapical tissues. The tissue compatibility of almost all commonly used root canal filling materials is very high, and for decades bone has been demonstrated to be laid down in close

proximity to all of them. Overfilling, while not necessarily beneficial, will not prejudice the outcome of a case or prevent healing. *Overfilling* must be distinguished from *overextension* of underfilled cases.

REFERENCES

1. Berg, Bernard: Endodontic management of multirrooted teeth. *Oral Surg., Oral Med., Oral Path.*, 6:3, 1953.
2. Coolidge, E. D., and Kessel, R. C.: Endodontology. Philadelphia, Lea & Febiger, 1956.
3. Dow, P., and Ingles, J. I.: Isotope determination of root canal failure. *Oral Surg., Oral Med., Oral Path.*, 8:1100, 1955.
4. Grossman, L. I.: Endodontic Practice. Philadelphia, Lea & Febiger, 1965.
5. Grossman, L. I.: Present status of plastic root canal filling materials. Transactions of the Third International Conference on Endodontics, Univ. of Penna., 1963.
6. Healey, H. J.: Endodontics. Philadelphia, Lea & Febiger, 1965.
7. Ingles, J. I.: Endodontics. Philadelphia, Lea & Febiger, 1965.
8. Schilder, H.: Endodontic therapy. In: *Current Therapy in Dentistry*, H. Goldman et al., ed. St. Louis, The C. V. Mosby Co., 1964.
9. Schilder, H.: The value of culturing in endodontic treatment. *Dent. Clin. North America*, March, 1966, pp. 127-138.
10. Sommer, R. F., Ostrander, F. D., and Crowley, M. C.: *Clinical Endodontics*. Philadelphia, W. B. Saunders Co., 1966.

Surgical Techniques Applicable to Endodontics

MILTON SISKIN, B.A., D.D.S.

Modern dentistry and those who practice the profession are dedicated to the proposition that the vast majority of individuals can maintain a functional natural dentition for the entirety of their life span. Endodontics is one of the areas of retentive dentistry that can provide many of the solutions and help overcome a large number of obstacles that beset the quest of this goal. When surgical procedures are advantageously utilized as an adjunct to conventional endodontics the scope and comprehensiveness of the field is tremendously expanded. Thus the attainment of the ultimate objective of dentistry can be brought nearer fruition.

CONVENTIONAL VERSUS IMMEDIATE SURGICAL ENDODONTICS

The utilization of surgical procedures for the purpose of retaining pulpally involved teeth is as old and as time-honored as the desire and inclination to perform such a feat. In the past there has been an arbitrary attempt to divide the practice of endodontics into two divisions: one, conventional or conservative therapy; the other, surgical or radical therapy. Conventional therapy implies the treating of a pulpally involved tooth without the employment of periapical surgery. When surgical therapy is used, the treatment of every pulpally involved tooth includes immediate periapical surgery. In other words, apical surgery is an integral part of the total therapeutic procedure for every tooth in this concept of treatment. It should be made clear that the vast majority of teeth requiring endodontic therapy can be treated via conventional methods alone, and that the periapical involvement will undergo reso-

* Professor and Head, Division of Endodontics, University of Tennessee, College of Dentistry; Dental Consultant to the Central Office of the Veterans Administration; Diplomate and Member, American Board of Endodontics.
Dental Clinics of North America—NOVEMBER, 1967