

# Morphology of the Physiological Foramen: I. Maxillary and Mandibular Molars

Benjamín Briseño Marroquín, Prof. Dr. med.dent., Mohammed A. A. El-Sayed, Dr. med.dent., and Brita Willershausen-Zönnchen, Prof. Dr. med.dent.

**Information concerning the anatomy of the physiological foramen is limited. The aim of this study was to investigate the distance between the physiological and anatomical apex, accessory foramina frequency, and the shape and diameter of the physiological foramen in maxillary and mandibular molars. The apical anatomy of 523 maxillary and 574 mandibular molars from an Egyptian population was investigated by means of a computer-aided stereomicroscope (40× magnification). The following results were obtained:**

- (a) There was a high percentage of two physiological foramina in mesial (87.06%) and mesiobuccal (71.15%) roots of mandibular and maxillary first molars, respectively.**
- (b) There was a high frequency of accessory foramina in maxillary mesiobuccal (33%) and mandibular mesial (26%) roots.**
- (c) The most common physiological foramen shape was oval (70%).**
- (d) The mean of the narrow and wide physiological foramen diameters was as follows:**
  - 0.20 to 0.26 mm in mandibular molars**
  - 0.18 to 0.25 mm in the maxillary mesiobuccal and distobuccal root**
  - 0.22 to 0.29 mm in the maxillary palatal root**

The purpose of shaping during root canal instrumentation is, besides the elimination of pulpal tissue and/or bacteria, the creation of a root canal configuration suitable for obturation. The physiological foramen or apical constriction is considered the terminus of the root canal preparation (1). Thus, knowledge of the morphological dimensions of this area would be advantageous in determining the final shaping diameter in this area. Numerous investigations using injection of materials into the root canal system, dye perfusion with subsequent demineralization, histological sectioning, and examination of ground sections under a stereomicroscope have shown the anatomic variations in the root canal system (2–5). Further methods such as a three-dimensional imaging technique (6) and a noninvasive high-resolution tomography technique (7) have been used in an effort to obtain more accurate morphological

information about the apical area. Typically, the root canal narrows toward the apex into the apical constriction or physiological foramen and expands to form the physiological foramen (3). Yet, Wu et al. (8) reported that an apical constriction was found in less than half of the teeth they examined. Moreover, the most apical portion of the root canal has been reported to have not only tapered but also parallel walls (9). Other authors have suggested that the apical constriction is often not present, particularly when apical pathosis and root resorption are present (1). Few studies concerning the root anatomical apex and anatomical foramen morphology have been conducted, and they mainly discuss the distance between these two entities (3, 9, 10). Even fewer studies concerning the diameter (2, 11) and shape (12) of the anatomical foramen have been conducted.

The aim of the study was to investigate the distance between the physiological and anatomical apex; accessory foramina frequency; and the number, shape, and diameter of the physiological foramen in the roots of maxillary and mandibular first, second, and third molars.

## MATERIALS AND METHODS

A total of 1097 extracted human permanent molars from an Egyptian population were obtained and stored in 5.25% sodium hypochlorite. The teeth had to show an intact or almost intact crown for clear identification of the tooth type and location (13, 14). Primary teeth and roots evidencing fractures, resorption, or underdevelopment (40× magnification) or that had received any previous endodontic treatment were discarded. The teeth were cleaned of any attached soft tissues or calculus by means of an ultrasonic scaler and placed for 1 hour in an ultrasonic bath with 3% hydrogen peroxide. The teeth were stored in 70% alcohol according to their type and dental arch position. Any tissue residuals in the anatomical foramen area were carefully removed with a No. 10 Micro-Opener (Maillefer/Ballaigues, Switzerland) under 40× magnification to make sure that the area was not modified. The roots were dyed with methylene blue, washed under running water for 10 min, and dried with pressurized air before the examinations.

A computer-aided stereomicroscope (Motic Images 2000 software and Motic Digital Microscope; Micro-Optic Industrial Group Co., France) with 40× magnification was used in this study. Measurement accuracy was assured through calibration

between an image (dot) with a known external diameter (2.5 mm/40× magnification) and the software. An image of each specimen (JPEG) was captured, and the data obtained were recorded for further statistical evaluation. The measuring dialog menu was set in millimeters and adjusted to three digits after the decimal.

The physiological (apical constriction) and anatomical foramina were determined to be the most inner and outer diameters at the apical terminus of the root canal, respectively. The anatomic apex was defined as the most apical root structure (Fig. 1). These three anatomical entities could, theoretically, coincide in one. The root morphology of the apical area was examined at 40× magnification. Each root was directly illuminated and oriented until the physiological foramen was located in the middle of and parallel to the objective lens. The mesial roots of mandibular and maxillary molars and the distal roots of mandibular molars were examined to detect two main physiological foramina. The tooth number and type, root type, physiological foramen location and shape, and accessory foramina

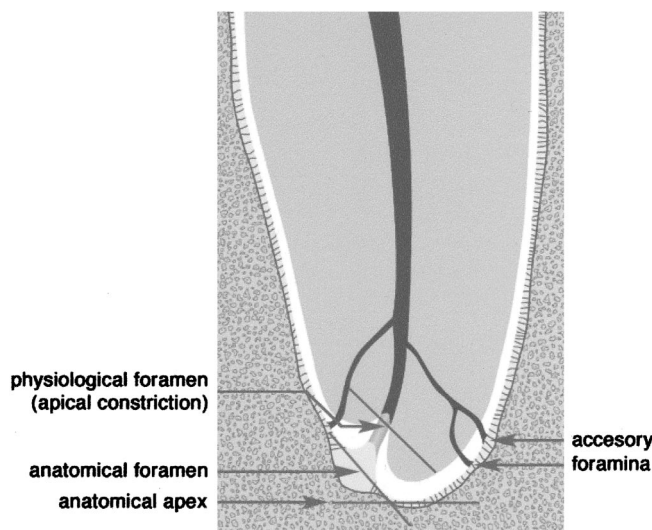


FIG 1. Diagrammatic definitions of the morphological entities investigated in this study.

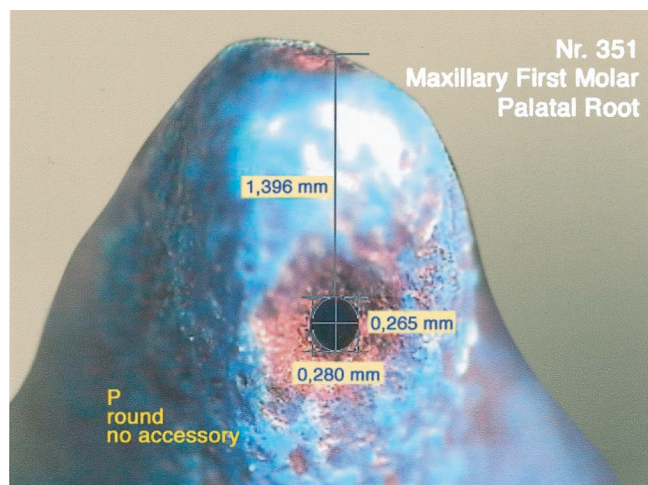


FIG 2. Distance measuring method between the physiological foramen and anatomical apex (40× magnification).

frequency (if found) were recorded. The foramen was considered accessory when its diameter was narrower than 0.10 mm (11). The distance between the physiological foramen and anatomical apex (Fig. 2) and the diameter of the physiological foramen were measured with the software length measuring mode. Two diameter measurements were made at each physiological foramen and were defined as wide and narrow diameters (Figs. 3, 4). A physiological foramen with a difference equal to or greater than 0.02 mm between the wide and narrow diameters was defined to have an oval instead of a round shape. The shape of the physiological foramen was determined by means of the measuring mode option and was accordingly determined to have a round, oval, or irregular (triangular, kidney, or irregular) form. The statistical data were arranged in mean, maximum, minimum, and SD.

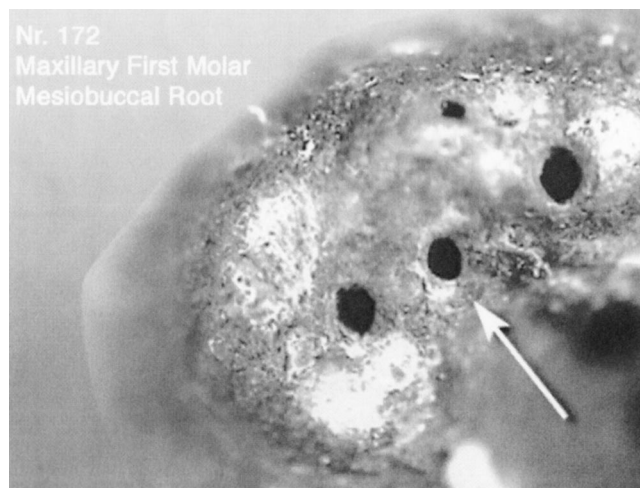


FIG 3. Physiological and accessory foramina of the mesiobuccal root of a first maxillary molar. The extreme foramina were determined in this case, according to their location and size, as physiological (main) foramina. The study design (noninvasive) did not allow precise determination of whether the foramen located in the middle (arrow) was an accessory or a physiological foramen originating from a third root canal (40× magnification).

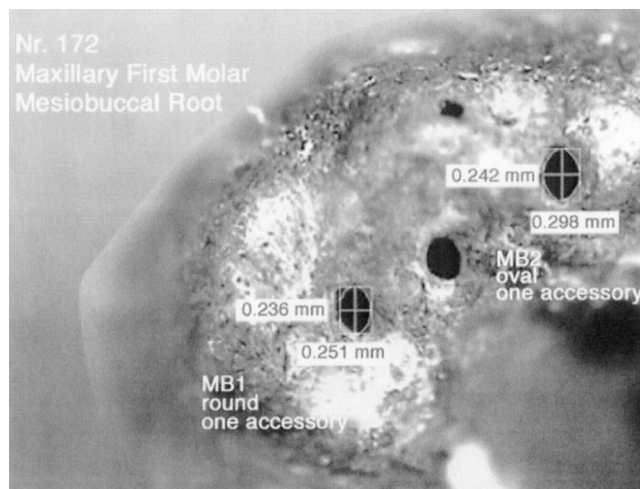


FIG 4. Measurement of the narrow and wide diameters of the mesiobuccal physiological foramina of a first maxillary molar (40× magnification).

TABLE 1. Sample distribution

	Maxillary	Mandibular	<i>n</i>
First molar	260	286	546
Second molar	187	224	411
Third molar	76	64	140
Total	523	574	1097

## RESULTS

A total of 2639 physiological foramina were investigated: 780 and 556 in the first, 560 and 431 in the second, and 205 and 107 in the third maxillary and mandibular molars ( $n = 1057$ ), respectively (Table 1). The distance between the physiological foramen and anatomical apex; frequency of accessory foramina; number of physiological foramina in each root; and shape and diameter of the physiological foramen of mandibular and maxillary first, second, and third molars are shown in Tables 2 to 11.

## DISCUSSION

The large number of teeth originally collected allowed discarding teeth in which any identification uncertainty aroused or any morphological changes were suspected without being afraid of compromising a solid statistical evaluation of the sample. Previous morphological investigation methods such as radiography or stereomicroscope are not reliable, because the radiograph does not give information concerning the buccal and lingual aspects of the root, and the measurement method under the microscope is cumbersome because of variables such as observer calibration and the objective micrometer quality. Other investigation methods such as scanning electron microscopy (11), a three-dimensional imaging technique (6), and a high-resolution tomography technique (7) have been used in an effort to reduce uncontrollable variables in research and to increase measurement accuracy. However, these research methods are difficult to perform on a large number of teeth. In the present study, a digital stereomicroscope with integrated software was

TABLE 2. Distance between the mesial and distal physiological foramina and anatomical root apex of mandibular molars (mm)

	First			Second			Third		
	M	MB	ML	M	MB	ML	M	MB	ML
Mean	0.77	0.75	0.86	0.91	0.65	0.87	0.64	0.85	1.10
SD	0.28	0.27	0.42	0.30	0.21	0.36	0.15	0.28	0.57
Maximum	1.32	1.59	2.66	1.74	1.19	1.81	0.93	1.18	2.21
Minimum	0.33	0.24	0.12	0.48	0.37	0.36	0.36	0.53	0.60
	D	DB	DL	D	DB	DL	D	DB	DL
Mean	1.00	0.84	0.97	0.85	0.88	0.95	0.89	0.70	1.03
SD	0.38	0.34	0.45	0.26	0.32	0.42	0.33	0.35	0.43
Maximum	2.44	2.04	2.55	1.62	1.60	2.09	1.55	1.31	1.51
Minimum	0.08	0.34	0.30	0.32	0.58	0.44	0.41	0.43	0.47

D = single distal; DB = distobuccal; DL = distolingual; M = single mesial; MB = mesiobuccal; ML = mesiolingual.

TABLE 3. Distance between the mesiobuccal, distobuccal, and palatal physiological foramina and anatomical root apex of maxillary molars (mm)

	First			Second			Third		
	MB	MB1	MB2	MB	MB1	MB2	MB	MB1	MB2
Mean	0.91	0.78	1.53	0.83	0.82	1.42	0.90	0.87	1.75
SD	0.35	0.27	0.77	0.45	0.50	0.63	0.35	0.46	0.79
Maximum	1.61	1.63	3.74	3.00	2.13	3.00	1.59	1.88	3.35
Minimum	0.33	0.22	0.21	0.33	0.18	0.40	0.35	0.43	0.66
	DB			DB			DB		
Mean	0.75			0.64			0.74		
SD	0.26			0.22			0.41		
Maximum	1.65			1.12			2.35		
Minimum	0.25			0.24			0.28		
	P	P1	P2	P	P1	P2	P	P1	P2
Mean	0.91	1.23	1.28	0.82	1.04	0.99	0.71	1.23	0.99
SD	0.34	0.75	0.57	0.29	0.52	0.45	0.20	0.72	0.26
Maximum	2.05	2.81	2.60	1.67	2.20	1.74	1.11	2.45	1.36
Minimum	0.24	0.38	0.30	0.31	0.46	0.48	0.39	0.46	0.73

DB = single distobuccal; MB = single mesiobuccal; MB1 = mesiobuccal one; MB2 = mesiobuccal two; P = single palatal; P1 and P2 = multiple foramina.

TABLE 4. Accessory foramen frequency of the mesial and distal roots in mandibular molars (%)

	First			Second			Third		
	M	MB	ML	M	MB	ML	M	MB	ML
0	94.59	70.27	64.65	88.67	75.47	77.94	85.36	84.62	61.53
1	5.41	25.30	23.70	9.33	19.12	17.65	12.20	7.69	7.69
2	—	4.02	8.84	2.00	2.94	2.94	2.44	7.69	15.39
3	—	0.41	2.01	—	1.47	1.47	—	—	15.39
4	—	—	0.80	—	—	—	—	—	—
<i>n</i>	37	249	249	160	64	64	49	15	15

	D			DB			DL		
	D	DB	DL	D	DB	DL	D	DB	DL
0	82.21	76.64	72.89	93.48	85.71	71.43	93.48	85.71	71.43
1	14.11	14.95	18.69	3.26	14.28	28.57	4.35	14.29	28.57
2	2.45	4.67	7.48	2.17	—	—	2.17	—	—
3	1.23	2.80	0.94	—	—	—	—	—	—
4	—	0.94	—	—	—	—	—	—	—
<i>n</i>	163	123	123	148	76	76	56	8	8

D = single distal; DB = distobuccal; DL = distolingual foramen; M = single mesial; MB = mesiobuccal; ML = mesiolingual foramen.

TABLE 5. Accessory foramen frequency of the mesiobuccal, distobuccal, and palatal roots in maxillary molars (%)

	First			Second			Third		
	MB	MB1	MB2	MB	MB1	MB2	MB	MB1	MB2
0	73.33	65.41	58.38	84	61.96	63.96	87.19	68.63	54.16
1	20	20.54	30.81	10	24.42	26.74	7.69	25	37.50
2	4	10.27	9.19	4	9.30	8.14	2.56	8.03	4.17
3	2.67	3.24	1.08	1	2.33	1.16	2.56	—	4.17
4	—	0.54	—	1	—	—	—	—	—
5	—	—	0.54	—	1.16	—	—	—	—
6	—	—	—	—	1.16	—	—	—	—
<i>n</i>	66	194	194	107	80	80	47	29	29

	DB			DB			DB		
	DB	DB	DB	DB	DB	DB	DB	DB	DB
0	87.05	84.80	87.30	87.05	84.80	87.30	87.05	84.80	87.30
1	9.45	10.33	12.70	9.45	10.33	12.70	9.45	10.33	12.70
2	2.27	3.80	—	2.27	3.80	—	2.27	3.80	—
3	0.39	0.54	—	0.39	0.54	—	0.39	0.54	—
4	—	—	—	—	—	—	—	—	—
5	0.39	0.54	—	0.39	0.54	—	0.39	0.54	—
<i>n</i>	260	187	76	260	187	76	260	187	76

	P			P			P		
	P	P1	P2	P	P1	P2	P	P1	P2
0	85.83	70.60	76.47	87.86	92.86	71.43	93.55	100	88.89
1	10.18	26.47	20.59	8.09	7.14	28.57	4.84	—	11.11
2	2.66	2.94	2.94	2.31	—	—	1.16	—	—
3	1.33	—	—	1.16	—	—	—	—	—
4	—	—	—	0.58	—	—	—	—	—
<i>n</i>	224	36	36	173	14	14	67	9	9

DB = single distobuccal foramen; MB = single mesiobuccal; MB1 = mesiobuccal one; MB2 = mesiobuccal two foramen; P = single palatal; P1 and P2 = multiple foramina.

TABLE 6. Physiological foramina number in the mesial and distal roots of mandibular molars (%)

Foramen	First	Second	Third
Single (m)	12.94	68.81	75.93
Two (mb and ml)	87.06	31.19	24.07
Single (d)	39.63	87.32	87.79
Two (db and dl)	60.37	12.86	13.21
<i>n</i>	286	224	64

d = Distal; m = mesial.

used, allowing accurate measurements in a simple manner and in a large number of teeth.

The physiological foramen or apical constriction is considered the narrowest diameter of the root canal and is located at the cementodentinal junction (3). It is also considered the apical limit of the root canal preparation (1). It is also known as the *histological foramen*, because it is located at the junction between the pulpal connective and interstitial loose connective tissues of the periodontal ligament. The anatomical foramen is usually located at the root



surface, whereas the physiological foramen is considered located away from the root surface by approximately 0.5 to 1 mm (3, 10). The anatomical foramen was defined in this study as the one with the widest diameter, taking into consideration that the number of anatomical foramina in one root should possibly be in accordance with the most commonly found molar root canal configuration (5, 15–18). In this study, the presence of one anatomical or physiological foramen is not necessarily indicative of the existence of one

root canal, because two or more root canals that apically merge and end as one root canal is also a probability. On the contrary, the presence of two anatomical or physiological foramina may indicate the presence of two separate root canals, one root canal that divides into two, or an apical delta. Because of the study design, it was not possible, at this point, to determine the relationship between the number of anatomical foramina present and the root canal configuration in the same root. The presence of two anatomical foramina in the mesial (87%) and distal (40%) roots of mandibular molars was higher than the ones reported by other authors (5, 18), and similar in the mesial root of mandibular second molars (18). In the mesiobuccal roots of maxillary molars, the frequency of two anatomical foramina was higher (18) and in agreement (5, 17) with the frequencies reported by other authors. The presence of two root canals with two anatomical foramina in the palatal root of maxillary molars is uncommon. However, the present study revealed that approximately 13% of palatal roots of maxillary first and third molars and 8% of second molars had two anatomical foramina of similar dimensions. This finding may indicate the presence of two root canals or one root canal with an apical ramification in the palatal roots of maxillary molars (19). Further palatal root canal

**TABLE 7. Physiological foramina number in the mesiobuccal, distobuccal, and palatal roots of maxillary molars (%)**

Foramen	First	Second	Third
Single (mb)	28.85	53.76	61.90
Two (mb1 and mb2)	71.15	46.24	38.10
Single (db)	100	100	100
Two (db)	—	—	—
Single (p)	86.92	92.51	87.32
Two (p1 and p2)	13.18	7.49	12.68
<i>n</i>	260	187	76

db = Distobuccal; mb = mesiobuccal; p = palatal.

**TABLE 8. Shape of the mesial and distal physiological foramina of mandibular molars (%)**

Shape	First			Second			Third		
	M	MB	ML	M	MB	ML	M	MB	ML
Oval	56.76	58.23	50.20	67.33	48.53	48.53	78.05	61.54	46.15
Round	32.42	39.36	47.39	25.34	47.06	50.0	19.51	30.77	46.16
Irregular	10.82	2.41	2.41	7.33	4.41	1.47	2.44	7.69	7.69
<i>n</i>	37	249	249	160	64	64	49	15	15

Shape	D			DB			DL		
	D	DB	DL	D	DB	DL	D	DB	DL
Oval	62.58	57.01	57.93	60.22	40.74	40.74	63.04	28.57	57.14
Round	29.45	36.45	39.25	33.87	51.86	55.56	36.96	71.43	42.86
Irregular	7.97	6.54	2.82	5.92	7.40	3.70	—	—	—
<i>n</i>	163	123	123	145	79	79	56	8	8

D = single distal; DB = distobuccal; DL = distolingual; M = single mesial; MB = mesiobuccal; ML = mesiolingual.

**TABLE 9. Shape of the mesiobuccal, distobuccal, and palatal physiological foramina of maxillary molars (%)**

Shape	First			Second			Third		
	MB	MB1	MB2	MB	MB1	MB2	MB	MB1	MB2
Oval	74.67	72.97	68.11	76.00	70.93	72.09	82.05	79.17	70.83
Round	13.33	23.78	24.87	16.00	18.61	16.28	7.69	16.67	25.00
Irregular	12.00	3.25	7.02	8.00	10.46	11.63	10.26	4.16	4.17
<i>n</i>	75	185	185	107	80	80	47	29	29

Shape	DB			DB			DB		
	DB	DB	DB	DB	DB	DB	DB	DB	DB
Oval	73.93	73.93	73.93	67.39	67.39	67.39	76.19	76.19	76.19
Round	18.29	18.29	18.29	24.46	24.46	24.46	15.87	15.87	15.87
Irregular	7.78	7.78	7.78	8.15	8.15	8.15	7.94	7.94	7.94
<i>n</i>	260	260	260	260	260	260	260	260	260

Shape	P			P			P		
	P	P1	P2	P	P1	P2	P	P1	P2
Oval	76.10	79.41	82.35	66.47	78.57	57.14	72.58	55.56	88.89
Round	12.83	14.71	8.82	20.81	14.29	28.58	16.13	33.33	11.11
Irregular	11.07	5.88	8.83	12.72	7.14	14.28	11.30	11.11	—
<i>n</i>	224	36	36	173	14	14	67	9	9

DB = single distobuccal; MB = single mesiobuccal; MB1 = mesiobuccal one; MB2 = mesiobuccal two; P = single palatal; P1 and P2 = multiple foramina.

TABLE 10. Narrow and wide diameters of the mesial and distal physiological foramina of mandibular molars (mm)

	First						Second						Third					
	M		MB		ML		M		MB		ML		M		MB		ML	
	N	W	N	W	N	W	N	W	N	W	N	W	N	W	N	W	N	W
Mean	0.21	0.31	0.19	0.25	0.17	0.23	0.21	0.33	0.19	0.25	0.16	0.22	0.24	0.34	0.17	0.23	0.16	0.21
SD	0.06	0.10	0.06	0.08	0.05	0.07	0.06	0.10	0.05	0.07	0.05	0.07	0.08	0.10	0.05	0.06	0.03	0.05
Maximum	0.34	0.59	0.39	0.64	0.31	0.52	0.37	0.59	0.29	0.48	0.31	0.47	0.50	0.56	0.30	0.37	0.21	0.34
Minimum	0.10	0.17	0.09	0.12	0.07	0.10	0.07	0.13	0.08	0.14	0.09	0.10	0.12	0.16	0.13	0.17	0.12	0.14
	D		DB		DL		D		DB		DL		D		DB		DL	
	N	W	N	W	N	W	N	W	N	W	N	W	N	W	N	W	N	W
	Mean	0.24	0.34	0.19	0.26	0.17	0.23	0.23	0.32	0.19	0.24	0.18	0.23	0.23	0.30	0.18	0.21	0.18
SD	0.07	0.10	0.06	0.08	0.05	0.08	0.06	0.10	0.06	0.07	0.04	0.06	0.08	0.10	0.08	0.07	0.03	0.07
Maximum	0.44	0.64	0.35	0.51	0.30	0.51	0.43	0.60	0.36	0.45	0.28	0.46	0.48	0.61	0.29	0.30	0.23	0.36
Minimum	0.07	0.15	0.08	0.12	0.08	0.12	0.12	0.13	0.09	0.13	0.11	0.13	0.10	0.17	0.10	0.13	0.15	0.16

D = single distal; DB = distobuccal; DL = distolingual; M = single mesial; MB = mesiobuccal; ML = mesiolingual; N = narrow; W = wide.

TABLE 11. Narrow and wide diameters of the mesiobuccal, distobuccal, and palatal physiological foramina of maxillary molars (mm)

	First						Second						Third					
	MB		MB1		MB2		MB		MB1		MB2		MB		MB1		MB2	
	N	W	N	W	N	W	N	W	N	W	N	W	N	W	N	W	N	W
Mean	0.21	0.32	0.19	0.24	0.16	0.21	0.21	0.30	0.18	0.24	0.16	0.22	0.19	0.27	0.20	0.26	0.16	0.21
SD	0.06	0.12	0.05	0.08	0.04	0.07	0.06	0.09	0.06	0.08	0.05	0.07	0.06	0.09	0.09	0.12	0.04	0.06
Maximum	0.35	0.73	0.37	0.53	0.28	0.52	0.37	0.60	0.47	0.54	0.29	0.44	0.31	0.56	0.52	0.60	0.25	0.34
Minimum	0.10	0.14	0.07	0.11	0.07	0.11	0.08	0.15	0.09	0.09	0.08	0.11	0.09	0.11	0.10	0.12	0.09	0.12
	DB						DB						DB					
	N			W			N			W			N			W		
	Mean	0.19		0.26		0.19		0.25		0.17		0.23		0.17		0.23		
SD	0.05		0.08		0.06		0.08		0.05		0.07		0.05		0.08			
Maximum	0.38		0.73		0.44		0.52		0.31		0.44		0.31		0.52			
Minimum	0.08		0.09		0.07		0.08		0.07		0.08		0.07		0.08			
	P		P1		P2		P		P1		P2		P		P1		P2	
	N	W	N	W	N	W	N	W	N	W	N	W	N	W	N	W	N	W
	Mean	0.27	0.36	0.23	0.30	0.21	0.27	0.27	0.35	0.21	0.30	0.17	0.22	0.26	0.34	0.18	0.24	0.17
SD	0.08	0.11	0.06	0.09	0.06	0.08	0.07	0.11	0.06	0.10	0.04	0.08	0.08	0.08	0.04	0.07	0.06	0.06
Maximum	0.56	0.69	0.35	0.56	0.33	0.47	0.51	0.83	0.32	0.62	0.23	0.46	0.51	0.59	0.24	0.34	0.28	0.33
Minimum	0.10	0.11	0.15	0.15	0.11	0.12	0.10	0.16	0.11	0.18	0.12	0.13	0.08	0.19	0.13	0.16	0.11	0.16

DB, single distobuccal; MB = single mesiobuccal; MB1 = mesiobuccal one; MB2 = mesiobuccal two; N = narrow; P = single palatal; P1 and P2 = multiple foramina; W = wide.

morphology research in maxillary molars is being undertaken to confirm our speculation. Our results suggest that the frequency of type III and IV root canals may be higher in the Egyptian population because of the relatively high occurrence of two anatomical foramina in the mesial and distal roots of mandibular and mesiobuccal roots of maxillary molars.

In the present study, the mean distance between the physiological foramen and the anatomical apex was 0.86 and 1.00 mm for mandibular and maxillary molars, respectively. These results are higher (3) and in agreement (12) with the results reported by other authors. The differences between various studies may be explained by the different measuring methods and by the different physiological foramen definitions used. Measurements have been made diagonally from the apical root center to the center point of the anatomical foramen (3), from the most apical point of the anatomical apex to the most occlusal point of the anatomical foramen (10), from the midpoint of the anatomical foramen to the highest point

of the anatomical apex (9), and from the most cervical point of the anatomical foramen to the most apical point of the anatomical apex (12). In the present study, a straight line parallel to the root axis from the most apical point of the anatomical foramen to a tangent line at the most apical point of the anatomical apex was used to determine the distance between the physiological foramen and the anatomical apex (Fig. 1). To make objective comparisons between research reports, it would be advantageous to establish precise definitions of the several anatomic entities of the apical region.

To the best of our knowledge, the frequency of accessory foramina close to the main physiological foramen in molars has not been reported in detail. The design of the present study was noninvasive; thus, the foramen was considered accessory when its diameter was narrower than 0.10 mm (11). The highest frequency of accessory foramina observed was in the mesiobuccal root of maxillary molars and in the mesial root of mandibular molars. It was also observed that the incidence of accessory foramina in-

TABLE 12. Mean diameters and SD of the physiological foramina and possible initial apical file sizes for molars

First mandibular molar	Narrow	SD	Wide	SD	Initial apical file
M	0.21	0.06	0.31	0.10	20–30
MB	0.19	0.06	0.25	0.08	20–25
ML	0.17	0.05	0.23	0.07	15–20
D	0.24	0.07	0.34	0.10	20–35
DB	0.19	0.06	0.26	0.08	20–25
DL	0.17	0.05	0.23	0.08	15–25
<hr/>					
Second mandibular molar					
M	0.21	0.06	0.33	0.10	20–35
MB	0.19	0.05	0.25	0.07	20–25
ML	0.16	0.05	0.22	0.07	15–20
D	0.23	0.06	0.32	0.10	25–30
DB	0.19	0.06	0.24	0.07	20–25
DL	0.18	0.04	0.23	0.06	20–25
<hr/>					
Third maxillary molar					
M	0.24	0.08	0.34	0.10	25–35
MB	0.17	0.05	0.23	0.06	20–25
ML	0.16	0.03	0.21	0.05	15–20
D	0.23	0.08	0.30	0.10	25–30
DB	0.18	0.08	0.21	0.07	20
DL	0.18	0.03	0.23	0.07	20–25
<hr/>					
First maxillary molar					
MB	0.21	0.06	0.32	0.12	20–30
MB1	0.19	0.05	0.24	0.08	20–25
MB2	0.16	0.04	0.21	0.07	15–20
DB	0.19	0.05	0.26	0.08	20–25
P	0.27	0.08	0.36	0.11	25–35
<hr/>					
Second maxillary molar					
MB	0.21	0.06	0.30	0.09	20–30
MB1	0.18	0.06	0.24	0.08	20–25
MB2	0.16	0.05	0.22	0.07	15–20
DB	0.19	0.06	0.25	0.08	20–25
P	0.27	0.07	0.35	0.11	25–35
<hr/>					
Third maxillary molar					
MB	0.19	0.06	0.27	0.09	20–25
MB1	0.20	0.09	0.26	0.12	20–25
MB2	0.16	0.04	0.21	0.06	15–20
DB	0.17	0.05	0.23	0.08	15–25
P	0.26	0.08	0.34	0.08	25–35

creases in roots with two main apical foramina. The incidence of accessory foramina in all molars was lower than that reported by Morfis et al. (11). Such differences could be explained through differences in research methodology or sample origin.

In the present study, the shape of the physiological foramen was considered round when the difference between the wide and the narrow diameter was equal to or less than 0.02 mm. This criterion, although arbitrary, was established in consideration of the ISO tolerances for root canal instruments. Our results indicate that the most common shape of physiological foramen is oval, these results are in agreement (20) and disagreement (12) with other reports. These differences may be attributed to racial

factors and definition variations between oval and round shapes. Other forms of physiological foramina such as triangular, kidney, or irregular forms were observed in 5.7% of the total examined physiological foramina. Although the teeth were carefully selected and had a microappearance (40× magnification) and macroappearance of having completely formed roots, these shapes could still be attributed to teeth with immature apices. A physiological foramen with an oval shape could indicate the presence of an oval-shaped root canal. This is clinically relevant, because many oval-shaped root canals, especially long and narrow ones, are difficult to shape completely without perforating or significantly weakening the root.

Our findings regarding the mean diameter of the physiological foramen are lower than (21) and to a great extent in agreement with (11) those reported by other investigations. One of our major concerns when planning this investigation was its possible clinical significance when shaping and cleaning the root canal. The initial apical file size is defined as the smallest instrument that reaches the root or working length and binds at the physiological foramen area. It has been suggested (22) that when the initial file size is known, the area of the root canal at the apical constriction is also known, and that the area of the root canal increases approximately 6.25 times when the apical third of the root canal is prepared three sizes after the initial apical file size. This concept is accurate only in cases in which the physiological foramen and apical root canal are round (23). The results of this study showed that the difference between the wide and narrow diameters was less than or equal to 0.10 mm in 72.86%, less than or equal to 0.15 mm in 86.56%, and greater than 0.15 mm in 13.44%. Therefore, two instrument sizes bigger than the initial apical file in 86.56%, and three or more instrument sizes bigger than the initial apical file in only 13.44%, would have been necessary to shape the physiological foramen area of the teeth included in this study. Contrary to common clinical belief, our results suggest that instruments sizes 10 to 20 often do not have any friction at the physiological foramen area, but rather encounter resistance elsewhere because of root canal irregularities or curvatures. The fact that coronal flaring of the root canal increases the size of the initial apical file that binds at the apex and consequently also increases the size of the master apical file (24, 25) supports this assumption. It is possible to prevent apical transportation in curved root canals by avoiding the use of instruments bigger than size 25 (26). However, according to our results and those reported by Wu et al. (8), in most cases, an instrument size 25 has a diameter similar to the narrow diameter of the physiological foramen; consequently, the physiological foramen will not be able to shape the physiological foramen completely. Based on the results of the narrow diameter of the physiological foramen, the initial apical file size could be tentatively determined before root canal shaping procedures. Yet, the root canal morphology coronally to the physiological foramen and the high SDs obtained in this investigation suggest a relatively high failure percentage when selecting the initial apical file.

Dr. Briseño Marroquín and Dr. Willershausen-Zönnchen are affiliated with the Department of Operative Dentistry, Johannes Gutenberg University, Mainz, Germany; and Dr. El-Sayed is a member of the Faculty of Dentistry, Mansoura University, El-Mansoura, Egypt.

Address requests for reprints to Dr. Briseño Marroquín, Langenbeckstr. 1, 55131 Mainz, Germany; E-mail: briseno@mail.uni-mainz.de.

## References

1. Simon JHS. The apex: how critical is it? *Gen Dent* 1994;42:330-4.
2. Green D. Stereo-binocular microscopic study of the root apices and surrounding areas of mandibular molars: a preliminary study. *Oral Surg Oral Med Oral Pathol* 1955;8:1298-302.
3. Kuttler Y. Microscopic investigation of root apices. *J Am Dent Assoc* 1955;50:544-52.
4. Meyer W. Die Anatomie der Wurzelkanäle, dargestellt an mikroskopischen Rekonstruktionsmodellen. *Dtsch Zahnärztl Z* 1970;25:1064-77.
5. Pineda F, Kuttler Y. Mesiodistal and buccolingual roentgenographic investigation of 7,275 root canals. *Oral Surg Oral Med Oral Pathol* 1972;33:101-10.
6. Blaskovic-Subat V, Smojver B, Maricic B, Sutalo J. A computerized method for the evaluation of root canal morphology. *Int Endod J* 1995;28:290-6.
7. Peters OA, Laib B, Ruegsegger P, Barbakow F. Three-dimensional analysis of root canal geometry by high-resolution computed tomography. *J Dent Res* 2000;79:1405-9.
8. Wu MK, Wesselink PR, Walton RE. Apical terminus location of root canal treatment procedures. *Oral Surg Oral Med Oral Pathol Oral Radiol Endod* 2000;89:99-103.
9. Dummer PM, McGinn JH, Rees DG. The position and topography of the apical root canal constriction and apical foramen. *Int Endod J* 1984;17:192-8.
10. Burch JG, Hulen S. The relationship of the apical foramen to the anatomical apex of the tooth root. *Oral Surg Oral Med Oral Pathol* 1972;34:262-8.
11. Morfis A, Sylaras SN, Georgopoulou M, Kernani M, Proutzos F. Study of the apices of human permanent teeth with the use of a scanning electron microscope. *Oral Surg Oral Med Oral Pathol* 1994;77:172-6.
12. Blaskovic-Subat V, Maricic B, Sutalo J. Asymmetry of the root canal foramen. *Int Endod J* 1992;25:158-64.
13. Kraus BS, Dordan RE, Abrams L. *Dental anatomy and occlusion*. Toronto: Decker, 1988.
14. Wheeler RC. *Atlas of tooth form*. 4th ed. Philadelphia: Saunders, 1969.
15. Green D. Double canals in single roots. *Oral Surg Oral Med Oral Pathol* 1973;35:689-96.
16. Costa Rocha LF, Sousa Neto MD, Fidel SR, da Costa WF, Pecora JD. External and internal anatomy of mandibular molars. *Braz Dent J* 1996;7:33-40.
17. Stropko JJ. Canal morphology of maxillary molars: clinical observations of canal configurations. *J Endodon* 1999;25:446-50.
18. Vertucci FJ. Root canal anatomy of human permanent teeth. *Oral Surg Oral Med Oral Pathol* 1984;58:589-99.
19. Stone LH, Stroner WF. Maxillary molars demonstrating more than one palatal root canal. *Oral Surg Oral Med Oral Pathol* 1981;51:649-52.
20. Carlsen O, Alexandersen V. Root canals in two-rooted maxillary second molars. *Acta Odontol Scand* 1997;55:330-8.
21. Stein TJ, Corcoran JF. Anatomy of the root apex and its histological changes with age. *Oral Surg Oral Med Oral Pathol* 1990;69:238-42.
22. Weine FS. *Endodontic therapy*. 4th ed. St. Louis: CV Mosby, 1989. 219-36.
23. Ponce EH, Vilar Fernandez J. The cemento-dentino-canal junction, the apical foramen, and the apical constriction: evaluation by optical microscopy. *J Endodon* 2003;29:314-9.
24. Laguna Contreras MA, Hinkin Zinman E, Kuttler Kaplan S. Comparison of the first file that fits at the apex, before and after early flaring. *J Endodon* 2001;27:113-6.
25. Schroeder K, Walton R, Rivera E. Straight line access and coronal flaring: effect on canal length. *J Endodon* 2002;28:474-6.
26. Walton RE, Torabinejad M. *Principles and practice of endodontics*. 2nd ed. Philadelphia: Saunders Co., 1996. 204.