
Prevalence of vertical root fractures in extracted endodontically treated teeth

Z. Fuss¹, J. Lustig² and A. Tamse¹

1 Department of Endodontology and 2 Department of Maxillofacial Surgery, The Maurice and Gabriela Goldschleger School of Dental Medicine, Tel Aviv University, Tel Aviv, Israel

Abstract

Fuss Z, Lustig J, Tamse A. Prevalence of vertical root fractures in extracted endodontically treated teeth. *International Endodontic Journal*, 32, 283–286, 1999

Aim The aim of this study was to evaluate the prevalence of vertical root fractures (VRF) in extracted endodontically treated teeth and to correlate the findings to previous studies and surveys.

Methodology Root-canal-treated teeth were referred for extraction from a public dental clinic. The endodontic therapy had been completed by a variety of dentists. Each tooth was evaluated following extraction by the oral surgeon who performed the procedure; the

exact aetiology for the clinical diagnosis that led to the extraction was recorded.

Results The major reasons for extraction were restorative (43.5%) and endodontic (21.1%), followed by vertical root fractures (10.9%).

Conclusions The relatively high prevalence of vertical root fractures in this survey compared with previous clinical and radiographic surveys was probably related to the difficulties in making a clinical diagnosis of vertical fractures before extraction.

Keywords: endodontically treated teeth, tooth extraction, vertical root fractures.

Introduction

Surveys of tooth extraction in various population groups (Murray *et al.* 1996, Hull *et al.* 1997) and success and failure studies of root-canal-treated teeth (Sjögren *et al.* 1990, Lin *et al.* 1992) are numerous. The reported prevalence of vertical root fractures (VRFs) in various populations is between 2 and 5%, based on case reports (Meister *et al.* 1980, Testori *et al.* 1993), recall of patients treated prosthetically (Bergman *et al.* 1989, Torbjörner *et al.* 1995) or evaluation of radiographs from dental records (Morfis 1990). However, those attempting to determine the reasons for extraction of endodontically treated teeth are scarce (Meeuwissen & Eschen 1983, Sjögren *et al.* 1990, Vire 1991).

The purpose of this survey was to evaluate the prevalence of VRFs in extracted endodontically treated

teeth in a public dental clinic and to correlate the findings to previous studies and surveys.

Materials and methods

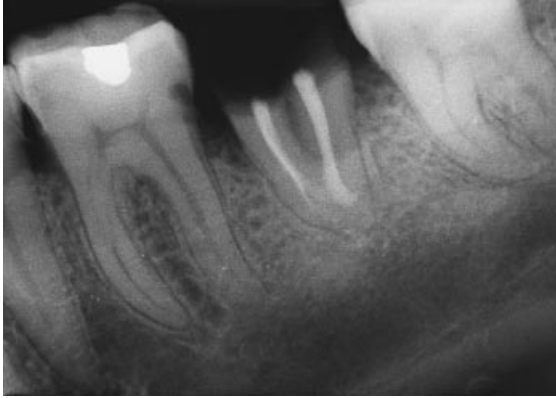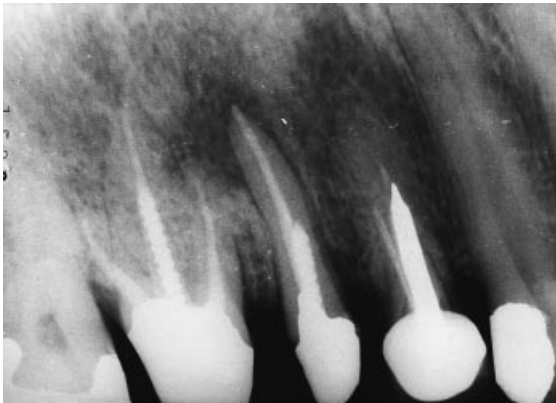
A total of 564 permanent teeth were extracted over 6 months from January to July 1997. Referral for extractions was by 15 general practitioners in a public dental clinic. Of these, 417 were either vital teeth (wisdom teeth, intact premolars for orthodontic reasons) or pulpless teeth without root canal therapy, and 147 had roots filled previously with gutta-percha and AH-26 by various dentists, at different times. Teeth that were not filled with gutta-percha and AH-26 were excluded from the survey. Since excessive pressure during lateral condensation of gutta-percha was mentioned as a major aetiology for VRFs (Meister *et al.* 1980), only those teeth laterally obturated with gutta-percha were included in the study.

The data collected by the oral surgeon (JL) at the time of extraction included tooth type, age of patient, a recent

Correspondence: Dr Zvi Fuss, Department of Endodontology, The Maurice and Gabriela Goldschleger, School of Dental Medicine, Tel Aviv University, Tel Aviv, Israel (fax: + 972 3 6409250).

Table 1 Reasons for the extraction of 147 endodontically treated teeth

Cause	Number of teeth	Percentage
Restorative	64	43.5
Endodontic	31	21.1
Endo-restorative	28	19.1
VRF	16	10.9
Periodontal	6	4.1
Perio-endo	2	1.4
Total	147	100

**Figure 1** This unrestorable mandibular second molar was extracted because of restorative reasons. The tooth was asymptomatic and without a periapical radiolucency.**Figure 2** A maxillary second premolar was treated endodontically and treated restoratively. An acute apical abscess had developed after 3 years. A large periapical radiolucency can be seen around the root apex. The patient preferred tooth extraction to apical surgery. The tooth was included in the endodontic group.

periapical radiograph and presence of signs and symptoms, caries, periodontal defects and presence and type of coronal and intraradicular restoration. The oral surgeon inspected the extracted teeth using a magnifying

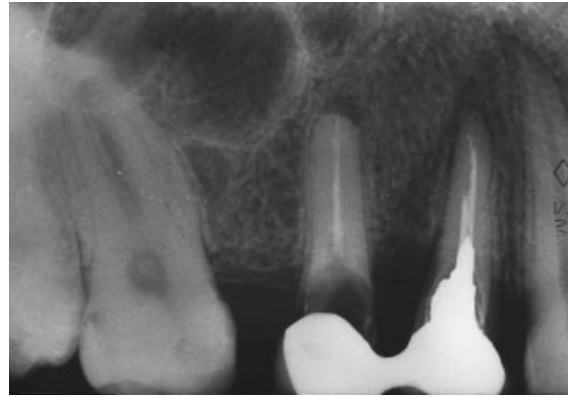
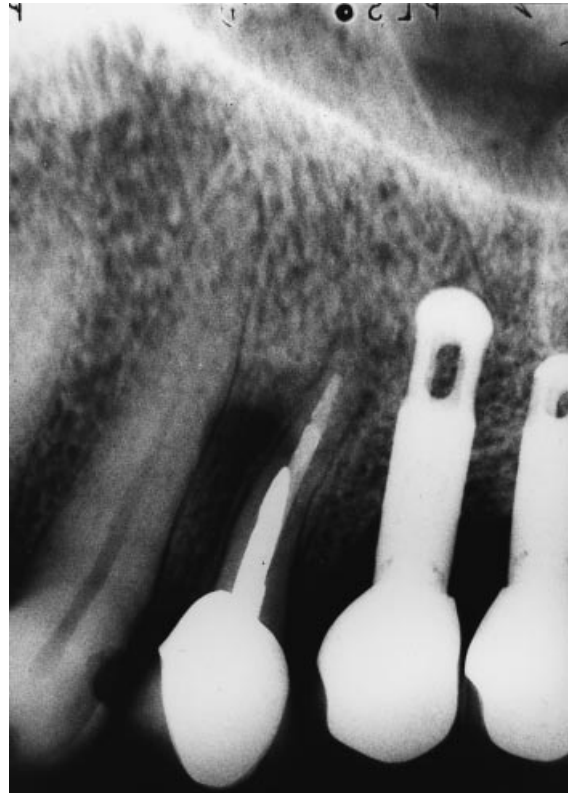
**Figure 3** A large carious lesion and periapical radiolucencies had developed in poorly obturated and restored maxillary first and second premolars. The two teeth were extracted because of combined endodontic-restorative reasons.**Figure 4** A maxillary first premolar was root-canal-treated and restored with a cast post and a crown. The patient complained of 'dull pain' and 'loose tooth' 5 years later. Clinical examination revealed a 13 mm pocket on the buccal surface and a fistula 3 mm apical to the gingival margin and mobility. A periapical radiograph revealed very narrow dentinal walls and a lateral radiolucency. Upon surgical exploration, VRF was observed with a completely resorbed buccal bony plate. The tooth was extracted.

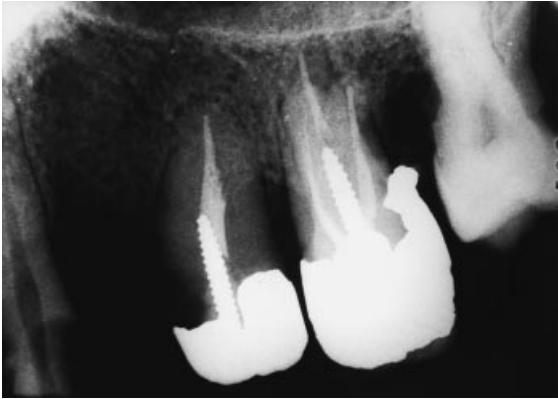

Figure 5 A maxillary first molar was root-canal-treated and restored with a Dentatus post and amalgam. A severe overhang on the distal aspect and poor contact on the mesial aspect resulted in severe bone loss and an 8 mm pocket was found on the distal surface after 2.5 years. The tooth was extracted because of the periodontal problem.

glass after removal of all debris. The diagnosis of VRF was based on the findings from the extracted tooth. All other extracted teeth were classified according to restorative, endodontic and periodontal reasons.

Results

Out of the 564 extracted permanent teeth, 147 had been root-canal-treated previously in this group (one extracted tooth from each patient). Patients ranged in age from 16 to 71 years old, with 51% between 31 and 50 years old.

Table 1 describes the reasons for extraction in the 147 teeth. The restorative group, composed of severely broken down, unrestorable teeth, was the major group (43.5%) (Fig. 1). Restored teeth with signs, symptoms (e.g. periapical abscess, fistula) and/or periapical radiolucency comprised the endodontic group (21.1%) (Fig. 2). A combination of debilitated teeth with signs of an endodontic 'failure' made up the 'endo-restorative' group (19.1%) (Fig. 3). The other three groups consisted of vertical root fractures (Fig. 4), periodontal reasons (Fig. 5) and two teeth with peri-endo involvement.

Discussion

Studies regarding the various reasons for tooth extraction were conducted in different populations by Murray *et al.* (1996) and Hull *et al.* (1997). In these two studies, the major group of extracted teeth,

'caries', included failed root canal treatments, which are not relevant to the present survey. In the present survey, the reasons for extraction in endodontically treated teeth were evaluated and the prevalence of VRFs in these teeth was determined.

More endodontically treated teeth are lost because of inadequate restorations or decay than because of endodontic failure (Weine 1982). Although the surveys of Meeuwissen & Eschen (1983) and Vire (1991) are completely different from our survey in terms of materials and methods used, both conclude that the survival rate of endodontically treated teeth mainly depends on adequate coronal reconstruction, rather than on the quality of the endodontic treatment itself. In the present survey, it was confirmed that the restorative group (43.5%) consisted of endodontically treated teeth with coronal breakdown resulting from caries in which coronal leakage was also involved. The endodontic group, with adequate coronal restoration but chronic or acute periapical involvement, made up only 21.1% of the sample (Table 1).

In many cases with problems in restoring the tooth, there is also endodontic failure. The decision on whether to extract or treat the tooth further is based on the dentist's clinical and radiographic findings in conjunction with the patient's cooperation and socioeconomic background. The combination of endodontic and restorative problems often leads to extraction, as compared with a tooth with just one problem in which further treatment would be preferable. Thus, a separate category – an 'endo-restorative' group – represents this more complex entity (Fig. 3). This category was in addition to the 'true' restorative group, in which there was no endodontic pathology (clinically or radiographically) (Fig. 1), and the endodontic group (Fig. 2).

In six teeth (4.1%) (Table 1), extraction was carried out because of a severe periodontal defect (Fig. 5). When the present results were compared with the survey of Vire (1991), several differences were found. In the latter survey, the number of extractions in the restorative group was much higher (59.4%) than in the present survey (43.5%). However, in our survey, when the restorative group is added to the endo-restorative group, the total percentage is 64.6%, which is similar to that found by Vire (1991). The differences occur in the group of teeth extracted for endodontic reasons only. In the survey by Vire (1991) it was 8.6%, compared with 21% in the present survey. These differences can be related to the better treatment available in the speciality group practice presented in that survey, where there were probably more retreat-

ments or surgical procedures before extraction. All root canal treatments in the present survey were performed by general practitioners, with different qualities of work. Neither of these surveys can be compared with the retrospective survey conducted by Meeuwissen & Eschen (1983) where 45 endodontically treated teeth (by pulpotomy, gutta-percha or silver cones) were extracted because of root canal treatment failure (unlike those in Vire (1991) and the present study). In addition, in this sample, a specific military group was included who were not eligible for a full coverage permanent restoration after endodontic treatment.

In the current survey, the prevalence of vertical root fractures was 10.9% (Table 1), which was close to the 12.9% found by Vire (1991). Sjögren *et al.* (1990) evaluated 635 endodontically treated teeth in a success and failure study for a period of 8–10 years. All teeth were treated by students and sealed with gutta-percha and lateral condensation. During this observation period, 68 teeth were extracted for various reasons, including 21 (30.8%) with VRFs, which is the highest percentage ever reported in an extracted tooth population. This small number of extractions during the long recall period can possibly be explained by the fact that Sjögren *et al.* (1990) conducted their retrospective study at a university clinic where patients receive comprehensive dental care, similar to a speciality clinic (Vire 1991). In the present survey, many patients returned to the public clinic for treatment only at a stage when teeth were unsalvageable restoratively (43.5%). The extremely long recall time and operator variability regarding VRF diagnosis before extraction may explain the relatively high percentage (30.8%) of VRFs in the study of Sjögren *et al.* (1990).

The high prevalence of VRFs found in the present survey and that of Vire (1991) can be explained by the fact that the final diagnosis of VRF was carried out after the tooth/root was extracted and the fracture could be demonstrated visually. Previously reported clinical and radiographic retrospective surveys found lower percentages – 4% (Hansen *et al.* 1990), 3.7% (Morfis 1990), 3.4% (Weine *et al.* 1991) and 2.6% (Torbjörner *et al.* 1995) – most likely related to the difficulties in the clinical diagnosis of vertical root fractures.

Acknowledgements

The authors thank Ms Rita Lazar for editorial assistance.

References

- Bergman B, Lundquist P, Sjögren U, Sundquist G (1989) Restorative and endodontic results after treatment with cast posts and cores. *Journal of Prosthetic Dentistry* **61**, 10–5.
- Hansen EK, Asmussen E, Christiansen NC (1990) *In vivo* fractures of endodontically treated posterior teeth restored with amalgam. *Endodontics and Dental Traumatology* **6**, 49–55.
- Hull PS, Worthington HV, Clerehugh V, Tisirba R, Davies RM, Clarkson JE (1997) The reasons for tooth extraction in adults and their validation. *Journal of Dentistry* **25**, 233–7.
- Lin LM, Skridner JE, Gaengler P (1992) Factors associated with endodontic treatment failures. *Journal of Endodontics* **18**, 625–7.
- Meeuwissen R, Eschen S (1983) Twenty years of endodontic treatment. *Journal of Endodontics* **9**, 390–3.
- Meister F, Lommel TJ, Gerstein H (1980) Diagnosis and possible causes of vertical root fracture. *Oral Surgery, Oral Medicine, Oral Pathology* **49**, 243–53.
- Morfis AS (1990) Vertical root fractures. *Oral Surgery, Oral Medicine, Oral Pathology* **69**, 631–5.
- Murray H, Locker D, Kay EJ (1996) Patterns of and reasons for tooth extractions in general practice in Ontario, Canada. *Community Dentistry and Oral Epidemiology* **24**, 196–200.
- Sjögren U, Höggglund B, Sundqvist G, Wing K (1990) Factors affecting long term results of endodontic treatment. *Journal of Endodontics* **16**, 498–504.
- Testori T, Badino M, Castagnola M (1993) Vertical root fractures in endodontically treated teeth: A clinical survey of 36 cases. *Journal of Endodontics* **19**, 87–90.
- Torbjörner A, Kalsson S, Odman PA (1995) Survival rate and failure characteristics for two post designs. *Journal of Prosthetic Dentistry* **73**, 439–44.
- Vire DE (1991) Failure of endodontically treated teeth: classification and evaluation. *Journal of Endodontics* **17**, 338–42.
- Weine FS (1982) *Endodontic Therapy*, 3rd edn. St Louis, MO: Mosby Co, p. 4.
- Weine FS, Wax AH, Wenekus CC (1991) Retrospective study of tapered, smooth post systems in place for 10 years. *Journal of Endodontics* **17**, 293–7.