

# Mineral Trioxide Aggregate Obturation: A Review and Case Series

George Bogen, DDS\* and Sergio Kuttler, DDS†

## Abstract

Mineral trioxide aggregate (MTA) has emerged as a reliable bioactive material with extended applications in endodontics that include the obturation of the root canal space. This article examines the literature supporting MTA as a canal filling material, suggests methods for its delivery and placement, and presents clinical cases that demonstrate its effectiveness in resolving apical periodontitis under a variety of circumstances. Case reports are presented documenting clinical outcomes after the application of MTA that include retreatment, obturation combined with root-end resection, apexification, internal resorption, dens in dente, and in conventional endodontic therapy. The review introduces clinicians to an alternative treatment strategy that might improve the healing outcomes for patients presenting with complex and challenging endodontic conditions. (*J Endod* 2009;35:777–790)

## Key Words

Gutta-percha, mineral trioxide aggregate, obturation, periapical, retreatment

From \*Private practice, Los Angeles, California; and †Health Professions Division, College of Dental Medicine, Nova Southeastern University, Fort Lauderdale, Florida.

Address requests for reprints to George Bogen, DDS, 321 N Larchmont, Blvd Suite #721, Los Angeles, CA 90004. E-mail address: [rohbogen@sbcglobal.net](mailto:rohbogen@sbcglobal.net). 0099-2399/\$0 - see front matter

Copyright © 2009 American Association of Endodontists. doi:10.1016/j.joen.2009.03.006

The obturation of the prepared radicular space has been achieved by using a wide variety of materials selected for their intrinsic properties and handling characteristics. These core materials have been classified as cements, pastes, plastics, or solids (1). Gutta-percha, in its various forms, has remained the paragon as a root canal filling material during the course of the last century. The development of core materials and delivery techniques has generated carrier-based gutta-percha and resin-based systems. These filling materials are combined with sealers to provide an adequate obturation of the root canal space that ideally prevents the emergence of endodontic disease and encourages periapical healing when pathosis is present (2). This process can only succeed if the sealed root canal space prevents further ingress of bacteria, entombs remaining microorganisms, and prevents their survival by obstructing the nutrient supply (3).

The materials that can be used to fill the root canal space should exhibit certain characteristics that allow for predictable placement and prevent and resolve endodontic disease (1). For endodontic filling and sealing materials to fulfill these ideal requirements, they should be bacteriostatic, seal apically and laterally, be nonirritating to periapical tissues, resist moisture, and provide radiopacity. Furthermore, the material should be sterile, nonshrinking, nonstaining, and easily placed and removed from the root canal system. On the basis of recent advances in endodontic materials, some of these criteria might require considerable reexamination.

Because the obturation of the root canal system demands a material that actually provides a reliable and impervious hermetic seal, it might be a contradiction that the material should be easy to remove. Because restorative procedures that include core buildups and cuspal coverage restorations can be subject to restorative microleakage, it might be necessary to obturate the canal space with materials that demonstrate a greater resistance to leakage as an impediment against oral pathogens. Furthermore, if an obturation material can offer additional properties that decrease bacterial survival and promote bioactive mechanisms necessary for regeneration and healing, then some ideal requirements of the filling material might be viewed as less important when the distinct advantages are considered.

The development of alternative obturation materials can be attributed to multiple studies demonstrating that gutta-percha is highly susceptible to microleakage when a sealed coronal restoration is not provided. When gutta-percha canal obturations are tested *in vitro* by using dye penetration, fluid filtration, or bacterial leakage models, they show vulnerability. Bacterial challenges to exposed gutta-percha with sealer in various *in vitro* experimental models have shown leakage along the material within 3–30 days (4–7). Research indicates that no known method with various techniques of cold or warm compaction of gutta-percha can predictably produce a coronal bacterial-tight seal when the material is exposed to microorganisms and their by-products (8–10). Although gutta-percha presents important advantages in ease of use, handling properties, and biocompatibility, it exhibits inherent weaknesses that make it less than ideal. The ideal material for root canal obturation has yet to be developed.

Coronal microleakage has been identified as a major cause of persistent periradicular disease and failure in orthograde endodontic therapy (11–13). Furthermore, all contemporary provisional materials placed over gutta-percha in obturated teeth have limited effectiveness in protecting the material from microbial contamination for extended periods (14–16). The susceptibility of gutta-percha to contamination and microleakage has led to the recommendation that sealed coronal core materials be placed directly after the completion of orthograde root canal treatment when using gutta-percha (17). A current trend in endodontic research is to explore various alternatives to

gutta-percha to identify suitable filling materials that can provide greater resistance against coronal and apical microleakage and thus protection from bacterial contamination.

Mineral trioxide aggregate (MTA) might have a profound advantage when used as canal obturation material because of its superior physiochemical and bioactive properties. The original material (Pro-Root MTA; Dentsply Tulsa Dental, Tulsa, OK) was introduced to seal pathways of communication from the external surface of the tooth in perforation repair and as a root-end filling material in endodontic surgery (18). When early scientific observations and clinical outcomes demonstrated favorable biologic responses to the material, other uses for MTA were explored and investigated. MTA was found to be effective as a pulp capping and pulpotomy agent for the repair of internal and external resorptive defects and was also shown to promote root-end induction in teeth with immature apices (apexogenesis) (19, 20).

This recently introduced tricalcium silicate cement exhibits many important properties not available in other contemporary materials currently used in endodontics. In conjunction with being sterile, radiopaque, and nonshrinking, the material is not sensitive to moisture and blood contamination. MTA also provides an effective seal against dentin and cementum and promotes biologic repair and regeneration of the periodontal ligament (PDL) (21–26). Because perforation repair, root-end induction, and root-end filling are essentially forms of partial canal obturation, the orthograde filling of the apical region or the entire root canal system with MTA is the next logical progression in the evolutionary application of this material. The use of MTA as an obturation material might ultimately provide long-term benefits that enhance the prognosis and retention of the natural dentition in conventional and complex therapies.

### Physiochemical Properties

MTA exhibits unique physiochemical properties that can provide exceptional outcomes when used for complete or partial canal obturation. Both gray and white MTA can be used for this procedure, despite the fact that the materials vary slightly in composition and characteristics (27). Some of these characteristic properties can be first observed during the hydration process, when calcium silicates react to form calcium hydroxide and calcium silicate hydrate gel, producing an alkaline pH (28). A further reaction forms a high-sulfate calcium sulfoaluminate during the reaction with tricalcium aluminate and calcium phosphate (29). The release of calcium from setting MTA diffuses through dentinal tubules, and the concentration of the calcium ions increases with time as the material cures (30). It appears that the biocompatibility of the cement might be attributable to the release of hydroxyl ions and formation of calcium hydroxide during the hydration process (31).

When mixed MTA is compacted against dentin, a dentin-MTA interfacial layer forms in the presence of phosphates (32). This adherent interstitial layer resembles hydroxyapatite in composition and structure when examined under x-ray diffraction and scanning electron microscopy (SEM) analysis; however, the calcium to phosphorus ratio varies slightly from that reported in actual hydroxyapatite (33). This interface between dentin and MTA has demonstrated superior marginal adaptation compared with amalgam, intermediate restorative material, or Super-EBA under SEM in resin models (34). Moreover, the particle size and dimensional shape of MTA can occlude and penetrate dentinal tubules that might harbor microorganisms after cleaning and shaping (35).

MTA not only fulfills the ideal requirement of being bacteriostatic, but it might have potential bactericidal properties. The release of hydroxyl ions, a sustained high pH for extended periods (36), and

the formation of a mineralized interstitial layer might provide a challenging environment for bacterial survival (37). These antibacterial properties can be a potent inhibitor of bacterial growth against species such as *Enterococcus faecalis* (38), a microorganism prevalent in root canal failures (39–42). Moreover, *Candida albicans*, commonly present in refractory endodontic disease (43), is susceptible to the antifungal activity of freshly mixed MTA (44–46).

The cured cement creates a potentially impervious seal that might be difficult for microorganisms to penetrate. This unique sealing property, combined with an initially high pH that increases to 12.5 after curing, might provide a suitable mechanism for bacterial entombment, neutralization, and inhibition within the canal system. These factors are important when considering nonsurgical treatments for patients with large periapical lesions associated with initial root canal treatment or in cases presenting with refractory endodontic disease diagnosed for retreatment. Orthograde retreatments with MTA might provide comparable or superior healing rates and less morbidity when contrasted against conventional retreatment paired with surgical endodontics (47, 48).

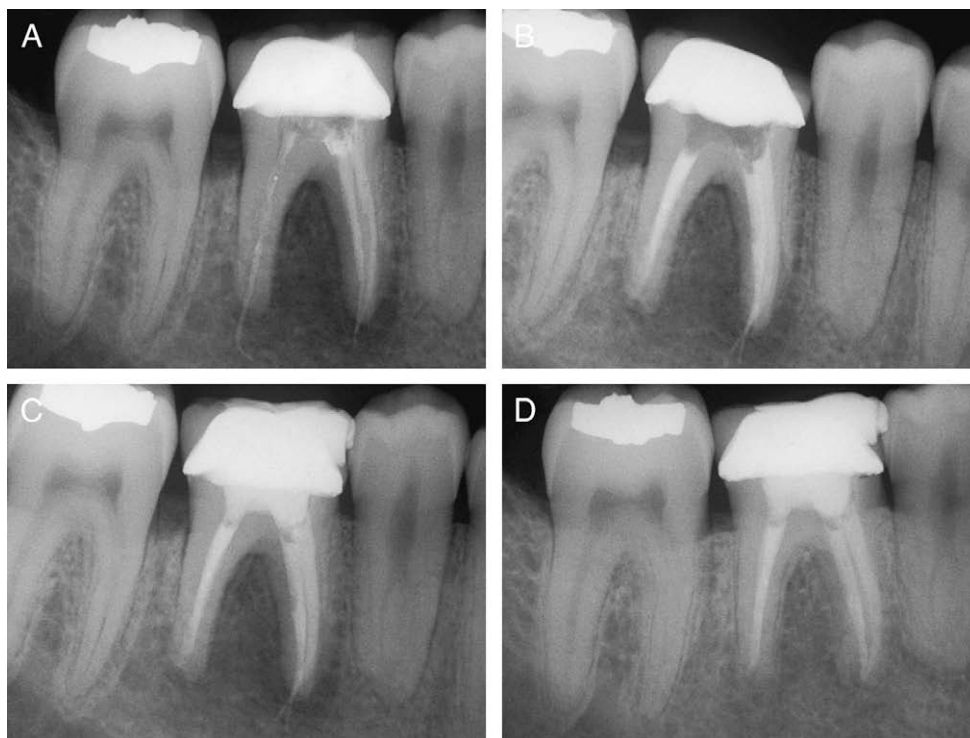
### Case #1: MTA Obturation

A 34-year-old male patient presented to a private endodontic office for evaluation of tooth #30, which had received nonsurgical endodontic treatment 18 months before and was restored with a porcelain fused to metal (PFM) crown (Fig. 1A). The presenting symptoms included swelling in the buccal vestibule and pain overnight. His medical health history was unremarkable, and radiographic examination revealed a poor quality obturation of the distal canal, extrusion of gutta-percha associated with both apices, absence of a discernible core material, and extensive periapical and furcation bone loss. Clinical examination disclosed fluctuant swelling in the vestibule proximal to the molar, grade I mobility, and pain on percussion. The clinical diagnosis was acute periapical abscess, and the patient elected retreatment with MTA obturation after discussion of treatment options. Written consent was obtained.

After anesthesia and rubber dam isolation, the molar was accessed through the crown, and inspection affirmed that no restorative core material was present. After the remaining Cavit (3M ESPE, St Paul, MN) and cotton pellet were removed, 3 canals were located. The previous obturating materials were removed with Gates-Glidden drills and barbed broaches without chloroform irrigation. The canals were chemomechanically debrided with Profile .04 Taper (Dentsply Tulsa Dental) sizes 20–60 to a master apical file (MAF) size 40 in conjunction with 5.25% sodium hypochlorite (NaOCl) irrigation. The canals were flushed with sterile water and dried with paper points, and the canals were filled with vertically compacted gray MTA by using a size 30 stainless steel K-file and 1/3 and 5/7 endodontic pluggers (Fig. 1B). After provisionalization, the patient received incision and drainage at the site and was given analgesics and antimicrobial therapy. He returned for follow-up 30 days after a bonded core was placed by the general dentist (Fig. 1C) and at 4 years, with healing evident radiographically (Fig. 1D). Clinical examination revealed normal mobility, probings, and normal function without symptoms.

This case illustrates the concept of MTA obturation of the entire canal system. In particular, previously endodontically treated teeth that have been subjected to long-term microleakage and bacterial contamination can show improved healing rates without surgical intervention by using MTA obturation, when compared with gutta-percha obturated teeth under the same clinical conditions.

Recent research has demonstrated that root canal treated teeth obturated with MTA exhibit higher fracture resistance than their untreated counterparts (49). Furthermore, it appears that long-term placement of MTA in the canal system not only provides increased resistance to



**Figure 1.** (A) Pre-operative radiograph of a previously treated mandibular right first molar with extensive periradicular and furcation bone loss in a 34-year-old male patient. (B) Retreatments of all canals obturated from apex to pulpal floor with vertically compacted gray MTA. (C) 30-day post-operative radiograph with composite core. (D) Four-year radiographic recall of molar without surgical intervention.

fracture, but the strength of the tooth might increase with time. Recent research on immature tooth models that were obturated with MTA and tested for fracture strength by using an Instron (Norwood, MA) testing machine indicated that at 1 year, MTA showed higher fracture resistance than untreated controls (50, 51). These researchers postulated that MTA might prevent the destruction of collagen by inducing the expression of a tissue inhibitor of metalloproteinase-2 in the dentin matrix.

One investigation has shown that long-term calcium hydroxide use decreases the fracture resistance of teeth in immature tooth models (52). Conversely, teeth experimentally filled with calcium hydroxide for 30 days and reobturated with MTA showed no significant decrease in strength of the roots during a 100-day observation period (53). This result might indicate that the combination of calcium hydroxide therapy followed by the obturation of teeth with MTA and combined with a composite core might increase the long-term prognosis for teeth with open apices and necrotic pulps (54–56).

### Bioactivity

MTA is a bioactive silicate cement that is nonirritating to periapical tissues and also induces the regeneration of cementum and the PDL (57–59). The cement is an osteoinductive and cementogenic agent that stimulates immune cells to release lymphokines required for the repair and regeneration of cementum and stimulates bone coupling factors necessary for the bioremineralization and healing of osseous periapical defects (60). Human osteoblasts show adhesion to the material, indicating favorable biologic responses and biocompatibility (61). The surface topography of cured MTA might provide a mechanism that modulates the osteoblastic phenotype (62). MTA provokes interleukin (IL) production in human osteoblasts that can exhibit raised levels of IL-1alpha, IL-1beta, IL-6, and macrophage–colony-stimulating factor (63–66).

MTA can stimulate hard tissue deposition when used as a root-end filling material (67). When the cement was experimentally placed as

a root-end filling in dogs or nonhuman primates, the histologic regeneration of the periodontal architecture was a frequent finding (68, 69). Several studies have shown that MTA placed as a root-end filling material promotes the regeneration of the PDL through a complex process of biologic repair (59, 70). In an investigation in which MTA was used as a filling material in a canine model and compared against a glass ionomer sealer, MTA induced the closure of the main canals by new cementum deposition in all samples (71). Histologic sections revealed biologic closure by the synthesis of new cementum and the regeneration of the PDL in the absence of inflammation. Furthermore, closure by deposition of cementum at the foramina of accessory canals was also a common finding in this study. Similar histologic findings were observed at 180 days in canine models in which MTA perforation repairs were characterized by cementum formation and regeneration of an attached PDL (71, 72).

In an investigation in which extracted teeth were obturated with MTA and reimplanted in nonhuman primates, histologic analysis of teeth after 180 days showed that half of the specimens exhibited newly formed cementum over surface resorptions (73). Also detected were the biologic sealing and repair of apical lateral canals by cementum deposition. The mechanism for this remarkable reformation might be attributed to the diffusion of calcium ions through dentinal tubules to the root surface that can inhibit bacterial colonization and survival (74). In studies in which set white MTA and gray MTA have been analyzed for cellular metabolic activity, both materials have the potential to induce PDL cell attachment. MTA might stimulate PDL fibroblasts to display the osteogenic phenotype and promote the production of osteonectin, osteopontin, and osteonidogen and increase alkaline phosphatase levels (75, 76). It appears that when MTA is used for obturation purposes, it can induce biologic repair mechanisms more consistently than other traditional canal filling materials such as gutta-percha.

## Sealing Properties of Compacted MTA

The sealing ability of MTA has been shown to be superior to other conventional materials currently used in endodontics (22, 24). A study that compared 3- to 5-mm MTA plugs against complete orthograde MTA obturation of root canals tested with a fluid filtration device revealed no significant difference in sealing ability after 4 weeks (77). The study proposed that the interaction of MTA with phosphate-buffered saline can promote apatite deposition that improves the seal of MTA over time. MTA has also been shown to resist leakage at a higher rate when placed in a moist environment (78). Another investigation suggested that 24-hour set gray MTA demonstrates significantly less leakage than white MTA after leakage analysis and that a 5-mm apical barrier of gray MTA by using a 2-step technique (allowing 24 hours for the MTA to set) provided the best apical barrier (79).

Evidence supports the ability of MTA to provide a reliable bacteria-resistant barrier when used as a retrofilling material. A recent study demonstrated that a 5-mm apical plug of MTA completely resisted microbial leakage when challenged in a model with *Actinomyces viscosus* during a 70-day test period (80). However, in another study, MTA placed without ultrasonic energy and challenged with a bacterial leakage model showed 100% leakage at the end of a 70-day test period (81). Another investigation demonstrated that MTA that is placed by using ultrasonic energy resists bacterial leakage against *E. faecalis*, *Enterobacter aerogenes*, and *Staphylococcus epidermidis* better than MTA compacted with only hand condensation (82). Moreover, 4 mm of ultrasonically placed MTA followed by a flowable self-cured intracanal composite demonstrated a significantly higher resistance to fracture than an MTA plug backfilled with gutta-percha and sealer. On the other hand, one study revealed that hand condensation of gray MTA can show denser compaction of the material than when augmented with ultrasonic energy in straight canals (83). It is clear that MTA resists bacterial leakage to a higher degree than gutta-percha and sealer when used as an obturation material. These findings also demonstrate that the placement of MTA is technique-sensitive, and protocols for proper obturation and condensation must be observed.

Gray MTA appears to be a better sealing agent than white MTA. A recent investigation examined the sealing ability of gray MTA, white MTA, and vertically compacted gutta-percha and sealer against the challenge of human saliva (84). After 42 days, gray MTA showed leakage in 9.1% of samples, white MTA leaked in 36.4% of samples, and all samples of vertically condensed gutta-percha and Kerr Pulp Canal Sealer EWT (Kerr Corp, Orange, CA) leaked after 19 days. MTA produces an excellent seal when the thickness is at least 4 mm (85). Another study conclusively showed that when MTA is used as a sealant in conjunction with gutta-percha placement, it demonstrates inferior resistance to leakage caused by inadequate material thickness (86). MTA has also been shown to provide a superior seal when used as a double-sealing intracoronal material over compacted gutta-percha (87) and is equivalent to glass ionomer as an intraorifice or coronal barrier (88, 89). MTA has shown excellent sealing ability when tested against other root-end filling materials in various experimental models (26, 90–93). The sealing ability of cured MTA, when used as an orthograde filling material, is not affected by root resection (94, 95).

## Case 2: MTA Obturation Combined with Root-End Resection

A 15-year-old male patient presented to the endodontic office for evaluation of tooth #9, which had been previously traumatized 8 years before (Fig. 2A). The presenting symptoms included tenderness to mastication and swelling of the buccal plate. Radiographic examination revealed a large unilocular radiolucency of the maxilla, with the right

central incisor having an incompletely formed apex. A review of the medical history revealed no contraindications to endodontic treatment. Clinical examination showed normal probings, slight incisor mobility, and profound swelling, with sinus tract evident to the mid-buccal plate. Tooth #9 was nonresponsive to cold testing. The clinical diagnosis was chronic apical periodontitis; the patient's guardian was presented with treatment options and elected retreatment with MTA obturation combined with surgical therapy. Written consent was secured.

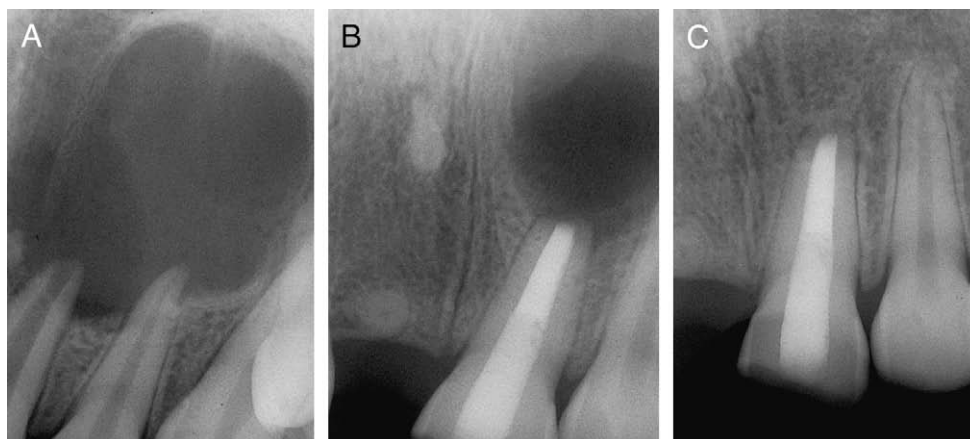
After anesthesia and rubber dam isolation, the tooth was accessed and flared with Peeso reamers, and the canal system was debrided 1 mm short of the radiographic apex. Instrumentation included size 60 and 70 stainless steel K-files to an MAF size of 80 under constant 5.25% NaOCl irrigation. The canal was dried and obturated with 12 mm gray MTA, with some extrusion of the material apically. The obturation method involved size 70 MAF with 5/7 and 7/9 endodontic pluggers. At 30 days after the initial appointment, the patient returned for root-end resection of the set MTA after bonded core placement (Fig. 2B). The histologic diagnosis of the biopsy material was granulation tissue with severe chronic inflammation. A 1-year follow-up radiograph showed complete remineralization of the periapical lesion (Fig. 2C). Clinically there was normal function and an absence of symptoms.

The case report demonstrates the concept of MTA obturation coupled with surgical root resection. Specifically, MTA placed in the root canal system and allowed to cure before surgical endodontics can give operators flexibility where root-end management might be challenging as a result of anatomic barriers, patient concerns, and hemostatic considerations, or if surgical access is compromised. Conversely, in cases that exhibit canal transportation, apical perforations, or stripping, MTA can provide a predictable seal that can promote bioremineralization and healing without post-treatment surgical intervention.

## MTA: An Alternative to Gutta-Percha

Even though the number of dental practices that promote “biological dentistry” has increased in recent years, the concepts of holistic dentistry are contradictory to the biologic basis of modern endodontic therapy. There is no current scientific evidence to support the association of endodontic infections with some physical disorders found in humans. However, uninformed patients concerned with possible “systemic problems” related to the retention of endodontically treated teeth with contemporary filling materials can be offered alternative substances to fill the root canal space. Biocalx (Albuca, Montréal, Québec, Canada), now called Endocalx (Endocal), has been used by dentists internationally as a nontoxic agent for canal obturations as an alternative substance to gutta-percha. It is a compound that contains calcium oxide and zinc oxide and is mixed with a liquid (ethylglycol/water) that reportedly swells into the dentinal tubules. The resultant mixture becomes calcium hydroxide but has a strong potential to induce vertical root fracture over time (96). It is therefore not an acceptable alternative to gutta-percha, and its use should be discouraged.

Another material is Iroot BioAggregate (DiaDent, Burnaby, BC, Canada), a biocompatible pure white powder composed of ceramic nanoparticles. The powder mixes with deionized water to form a nanocomposite network of gel-like calcium silicate hydrate mixed with hydroxyapatite bioceramic that also precipitates calcium phosphate. There is no available research at this time regarding the use of BioAggregate as an obturation material. MTA-Angelus (Angelus, Londrina, Brazil), a new material and very similar to ProRoot MTA, might also exhibit properties suitable for nonsurgical root canal obturation (97, 98). The material is silicate cement composed of several mineral oxides and achieves a rigid set in 10–15 minutes. The material is composed of 80% Portland cement and 20% bismuth oxide. Canal obturation with ProRoot MTA or other similar compounds with new compositions currently being



**Figure 2.** (A) Fifteen-year-old male patient presenting with previously traumatized maxillary left central incisor and large periapical lesion. The incisor was non-responsive to cold testing (B) MTA canal obturation with composite core and surgical root resection after MTA curing. (C) One-year radiographic recall. Histological analysis of biopsy specimen identified a granuloma.

developed might be an acceptable method for root canal obturation, while avoiding the potential for root fractures associated with Endocalex.

Because of its characteristics, MTA might become a viable alternative treatment option compared with gutta-percha-based materials and sealers. MTA exhibits superior sealability against bacterial microleakage, while demonstrating antibacterial and bioinductive properties that can improve treatment outcomes. Furthermore, the material is sterile, radiopaque, resistant to moisture, and nonshrinking and stimulates mechanisms responsible for the bioremineralization and resolution of periapical disease. MTA can be considered the material of choice in preventing the extraction of involved teeth when some protocols might otherwise recommend unconventional alternatives.

### Apexification and Perforation Repair

It has been shown that MTA has cementogenic properties, not only when used as a root-end filling material and in perforation repair but also in the induction of root-end closures (99). There are numerous reports that confirm the superiority of MTA as a perforation repair material (57, 100–105). The sealing ability of MTA in perforation repair is remarkable and is now considered the preferred and routine method of resolving procedural errors in endodontic therapy (20, 106). MTA also induces the formation of apical calcific barriers and resolution of periapical disease of unformed apices in teeth with necrotic pulps, as demonstrated in numerous case reports (107–115). MTA obturations in teeth with immature apices can induce apexogenesis by stimulating the mesenchymal stem cells from the apical papilla to promote complete root maturation in the presence of periapical pathosis or abscesses (116).

### Case 3: MTA Obturation with Open Apices

A 12-year-old female patient presented to a children's dental clinic for emergency treatment of tooth #20. Symptoms included pain and swelling, lymphadenopathy, and an elevated temperature. The medical history was noncontributory. Clinically the premolar exhibited grade 2 mobility, with pain on percussion and no caries. However, a closer inspection revealed an occlusal anomaly consistent with dens evaginatus. The radiographic evaluation revealed an open apex with periapical pathosis, and the case was diagnosed as an acute periapical abscess (Fig. 3A). The patient's parents were presented with various treatment options, and they elected treatment that included MTA obturation after parental consent was secured.

After local anesthesia and rubber dam isolation, purulent exudate was discharged immediately after access completion. Chemomechanical instrumentation was completed by using size 60–100 stainless steel K-files, 6% NaOCl irrigation, and calcium hydroxide intracanal medication (Fig. 3B). The patient was prescribed antimicrobials and returned 1 week later. The root canal was filled with vertically compacted white MTA after irrigation and canal drying with a Glick instrument to gently condense the material apically. The coronal MTA was dried, and a flowable compomer and bonded core restoration were placed. Three-month radiographic recall (Fig. 3C) and 18-month follow-up showed osseous repair and apical closure (Fig. 3D).

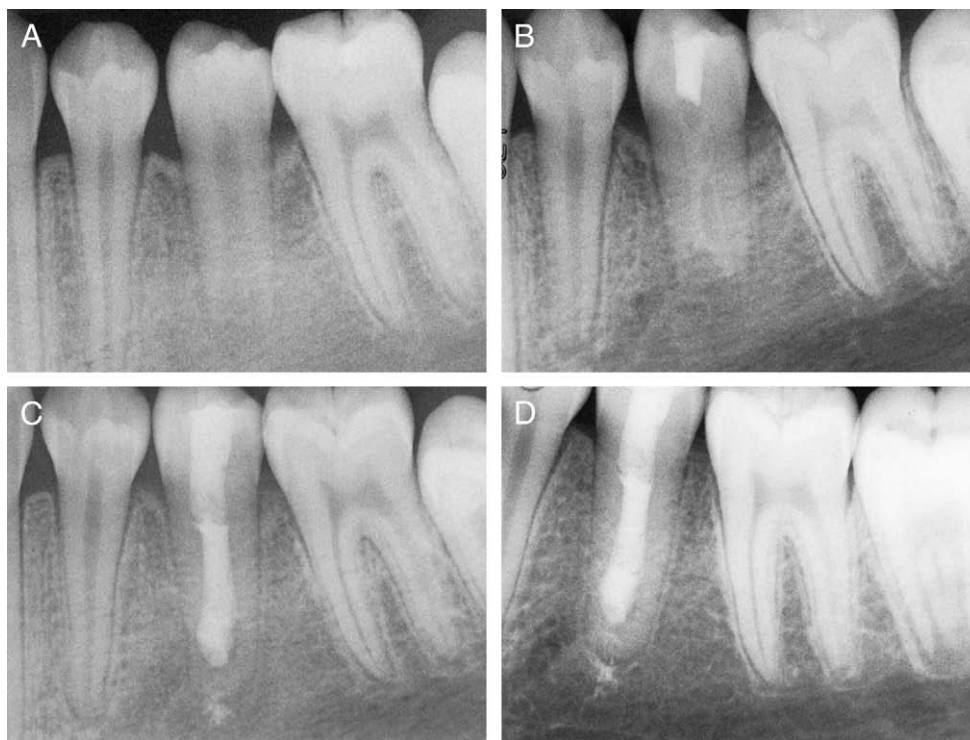
Observations from this case example support MTA as an effective material in regenerating normal periradicular architecture in teeth with immature apices and continued root maturation when pulpal necrosis is present.

In a clinical retrospective outcome study, MTA was used as an artificial barrier in teeth with immature apices (117). By means of a periapical index score, 17 of 20 (85%) teeth showed healing. Also, when the MTA apexification procedure is compared against calcium hydroxide as a control, MTA demonstrated higher clinical and radiographic success at inducing root-end closure (118). In obturation of root canal systems by using MTA, it has been shown that MTA combined with propylene glycol paste is far easier to place in canals in canine models (119). The biologic response in periapical tissues is similar when compared with conventional obturation when MTA is mixed with distilled water.

In a more recent retrospective study, 144 teeth with open apices and no apical barriers were obturated with ultrasonically compacted MTA and completed in a 1- or 2-visit protocol (120). Interim placement of calcium hydroxide was implemented in the 2-visit sequence. Teeth were restored and sealed in the coronal third with bonded composite. With a recall rate of 54% and a mean time to recall of 19.4 months, cases recalled after 1 year or longer showed a favorable outcome, with healing in 93.5% with 1 visit and 90.5% in teeth treated in 2 visits. It was concluded by the investigators that MTA placed in teeth with open apices in 1 visit was a viable alternative to calcium hydroxide therapy before MTA obturation by using 2 visits to promote apical closure.

### Obturation in Endodontic Retreatment

An ongoing challenge in endodontics has been the retreatment of previously treated gutta-percha and sealer cases associated with refractory disease. Root canal fillings associated with long-standing



**Figure 3.** (A) Twelve-year-old female patient with dens evaginatus, open apex, and diagnosed with an acute periapical abscess. (B) Calcium hydroxide intracanal medication. (C) Three-month recall with MTA canal obturation and bonded composite core. (D) Eighteen-month recall showing osseous repair and apical closure.

restorative leakage are often contaminated with gram-positive bacteria that include *E. faecalis* and yeasts such as *C. albicans* (121, 122). Although cleaning and shaping, intracanal medication, ultrasonics, and microscopic examination are helpful in removing contaminated filling materials and reducing the number of microorganisms during retreatment, many bacteria can survive treatment in inaccessible areas of the root canal or between the interface of the previous filling material and dentinal wall (123). Furthermore, some microorganisms and their by-products colonizing dentinal tubules might be difficult to eliminate, even with prolonged exposure to common endodontic irrigants (124–126). Although studies have shown that orthograde retreatment with various forms of gutta-percha followed by surgical endodontics produces higher success rates than retreatment alone (123), the avoidance of surgical treatment by using conservative treatment options that have similar prognostic outcomes should be considered. MTA obturation in retreatment cases offers an alternative method that can possibly reduce the indications for endodontic surgery.

#### Case 4: Retreatment with MTA Obturation

A 27-year-old male patient presented to the private endodontic office for evaluation of tooth #9, which had received conventional endodontic treatment 6 years earlier (Fig. 4A). The patient was informed by his dentist that the prognosis for retreatment therapy or surgery was unfavorable, and he was treatment planned for implant placement. The medical health history was noncontributory, and the patient was asymptomatic. Radiographic examination revealed a previous nonsurgical treatment characterized by a substandard obturation with voids and the presence of a large periapical lesion (>1 cm). Clinical examination showed normal tooth mobility, no pain on percussion with only slight discomfort on palpation, and a normal cold response from the proximal lateral incisor (#10). After a clinical diagnosis of chronic apical periodontitis, the patient was offered various

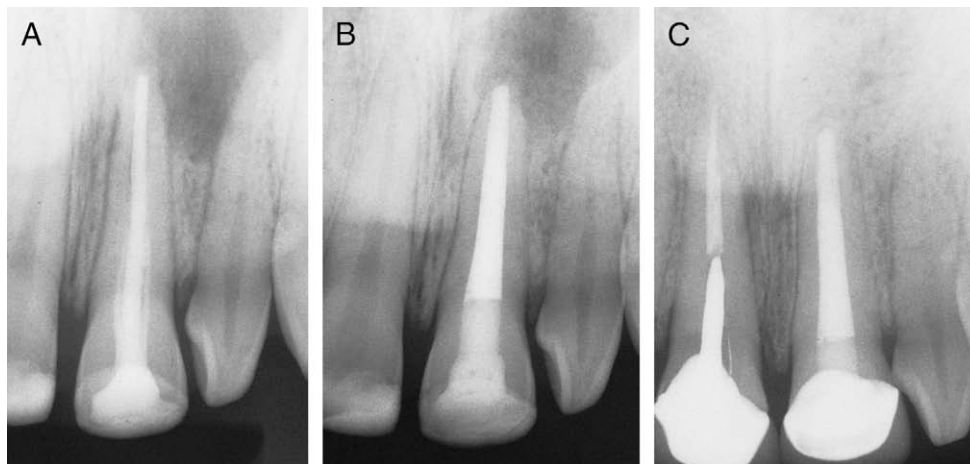
treatment selections and accepted retreatment with MTA obturation after consent forms were signed.

After anesthesia and rubber dam isolation, the incisor was accessed, and previous filling material was removed with Gates Glidden drills and barbed broaches. The root canal was chemomechanically shaped and cleaned with Profile .04 Taper sizes 20–80 by using 6.0% NaOCl and MTAD irrigation. The apical preparation was completed with large K-files to an MAF size 90. The canal was flushed with sterile water and dried with paper points, and the apical 5 mm was obturated with vertically compacted white MTA by using a size 80 stainless steel K-file and a 5/7 endodontic plugger. After drying the coronal aspect of the MTA plug with paper points, the canal was further obturated with thermoplastic gutta-percha and sealer and was restored with a bonded core during the same visit (Fig. 4B). The patient returned for a second recall at 3 years (Fig. 4C), and radiographic examination revealed complete healing of the apical lesion. Clinical examination disclosed the incisor to be firm and functional without symptoms. Also evident was that the right central incisor (#8) was recently treated and restored by a general dentist.

The outcome in this case example demonstrated that previously treated teeth that exhibit large chronic periapical lesions can be retreated by using MTA as an apical plug to achieve periapical healing. Furthermore, MTA apical plug placement with backfilling of a removal material can provide adaptability when considering future restorative requirements.

#### Root Canal Obturation before Endodontic Surgery

A variety of circumstances can either prevent healing or promote periapical bone loss after conventional endodontic treatment. These factors can be iatrogenic, anatomic, or microbial (biofilms or extraradicular bacteria) and can often include restorative or apical microleakage. Obturating the root canal system with MTA in select cases before



**Figure 4.** (A) Periapical radiograph of maxillary left central incisor with previous conventional endodontic treatment and large periradicular lesion on 27-year-old male. The patient was initially treatment planned for implant placement. (B) Single-visit treatment with a 5 mm MTA plug, thermoplastic gutta-percha and sealer and bonded composite core. (C) Three-year recall, the right central incisor was treated and restored recently by a general dentist.

surgical treatment after allowing the material to cure is an option that can have important advantages. Although one study showed a lower incidence of cementum formation in cases in which root resection was performed on canals filled with cured MTA as opposed to freshly placed MTA, no significant difference in cementum formation or osseous healing was observed during a 4-month period in canine models (69). This protocol might be beneficial when surgical access is compromised by anatomic structures to lessen technical demands on the operator or address patient management concerns.

### Case 5: MTA Obturation before and during Surgery

A 42-year-old female patient presented to a private office for evaluation of teeth #7 and #8, which had been previously traumatized and received orthograde treatment at age 12 and retrograde treatment at age 25 (Fig. 5A). The patient was informed by another office that only implant placement could be offered to resolve the ongoing pathosis. The presenting symptoms included tooth mobility, swelling, and presence of a suppurating sinus tract. Radiographic examination revealed a previous silver point treatment of tooth #7, 2 prior amalgam retrofills, and a large periapical lesion. A medical history review indicated the patient was in good health. Oral examination revealed amalgam tattooing of the buccal plate, grade 2+ mobility of both incisors, and exudate associated with the sinus tract. The clinical diagnosis was chronic apical periodontitis. The patient was given treatment options and elected retreatment and surgery with MTA obturation after written consent was acquired. The patient also indicated that she wanted to retain both existing PFM crowns for financial reasons.

After anesthesia and rubber dam isolation, tooth #7 was accessed, and the silver point was removed. The canal was prepared by using size 50–80 stainless steel K-files to an MAF size 80, irrigated with 5.25% NaOCl, dried, and obturated with gray MTA to the level of the amalgam retrofill by using a Glick instrument. Seven days later, the patient returned for surgical removal of the amalgam retrofills (Fig. 5B). Ultrasonics were used to remove gutta-percha in tooth #8 to the level of the cemento-enamel junction (CEJ) by using sterile water as the irrigant, and the canal was obturated with MTA by using an amalgam carrier and amalgam plugger. The root ends were smoothed with a high-speed diamond bur, and 2 MTA root end caps were placed (Fig. 5C). The patient returned for a 6.5-year recall with recently placed PFM crowns, both teeth in normal function without symptoms (Fig. 5D).

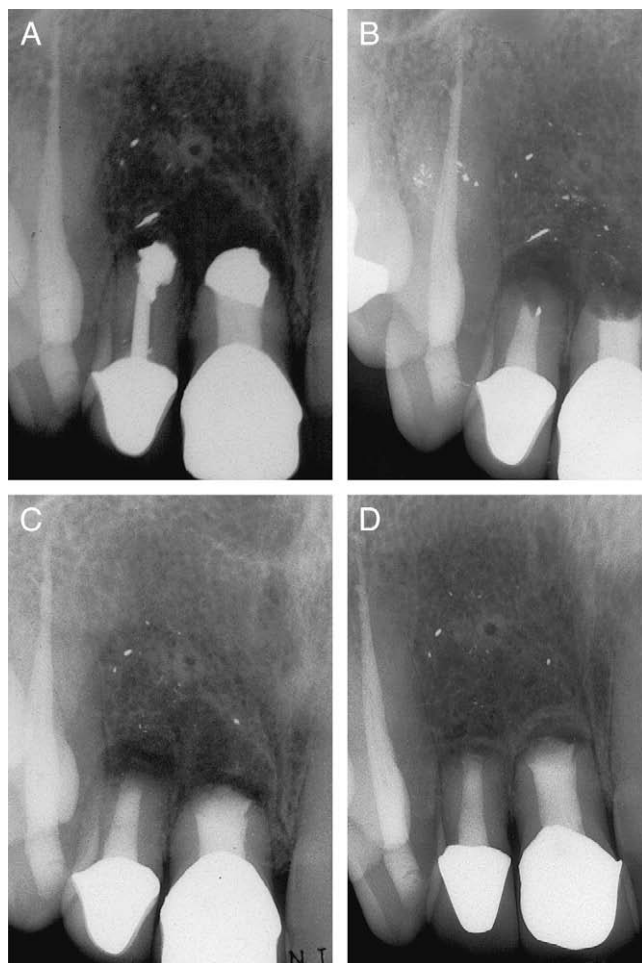This case demonstrates the diverse delivery methods available when obturating with MTA that allow operators flexibility during surgical and nonsurgical treatments. Furthermore, the outcome demonstrates favorable periapical healing in a compromised case in which implant placement was initially treatment planned.

Canals that have been obturated with set MTA before treatment might simplify the procedure when surgical access is difficult. Anatomic restrictions during surgical treatment can include the mylohyoid ridge on mandibular second molars where the mesial or distal canals can be obturated before surgical treatment to avoid the demand for retrofill placement after root resection. Another anatomically challenging area can be the palatal roots of maxillary molars where apicoectomy alone would lessen the technical operator demand for root-end filling placement. Management considerations include physically and mentally compromised patients, intravenous sedation cases, and patients with limited opening. When the canals have been previously obturated, then root resection and examination with magnification of the resected root end can shorten appointment times.

After the initial obturation of canals with MTA, a sealed coronal core restoration can be provided in 1 visit after a flowable compomer is placed over the material within the canal orifices. If the operator wants to confirm MTA curing, then the core material can be placed at the time of surgery on the second visit. In cases that exhibit microleakage and contaminated gutta-percha that are retreated with MTA obturation before surgery, it is important for operators to examine under magnification the resected root end for any remaining gutta-percha between the set MTA and canal walls. Because residual gutta-percha can potentially shelter endodontopathogenic microorganisms, root resections should be completed to a level where only cured MTA is visible. If after resection, contaminated gutta-percha can still be detected between the MTA and canal wall interface, ultrasonic preparation and fresh MTA retrofill placement are recommended.

### Other Indications for MTA Canal Obturation

Complete or partial obturation of the root canal system by using MTA is a viable option for teeth that exhibit extensive internal root resorption (127), open apices, and select cases that show anatomic variations that include dens evaginatus, dens invaginatus, “C” shape canals, fusion, or gemination.



**Figure 5.** (A) Pre-operative radiograph of failed surgical treatment of teeth No. 7 and 8 in 28-year-old female patient. (B) Surgical removal of amalgam retrofills after No. 7 received orthograde retreatment with MTA obturation. (C) Ultrasonic removal of gutta-percha No. 8 with MTA canal filling followed by MTA root end caps placed in both incisors. Neither incisor received smear layer removal. (D) 5-year recall showing remineralization of the previous periapical lesion.

### Case 6: MTA Obturation for Internal Resorption

A 45-year-old male patient was referred for treatment to a private endodontic office after a routine radiographic examination revealed an advanced resorptive defect associated with tooth #8 (Fig. 6A). There were no subjective clinical symptoms, and the health history disclosed no abnormalities. Oral examination demonstrated no tenderness to percussion or palpation with normal probings and mobility. The clinical diagnosis was perforating internal inflammatory root resorption, and the patient was offered various potential treatments and elected MTA obturation. Written consent was obtained.

The patient received local anesthesia and rubber dam isolation followed by access and instrumentation with size 60–120 stainless steel K-files to an MAF size 80 by using 2.75% NaOCl irrigation. After the canal was dried, MTA was obturated by using hand condensation with Schilder pluggers without use of an internal matrix. The patient returned 1 week later for bonded core placement (Fig. 6B). One-year radiographic recall showed osseous repair of the previous periapical pathosis (Fig. 6C). The patient was asymptomatic, with the tooth exhibiting normal probings, mobility, and function.

### Case 7: MTA Obturation for Dens in Dente

An 11-year-old male patient presented to the clinic for evaluation of tooth #10, which clinically exhibited swelling and a suppurating sinus tract. Radiographic evaluation revealed unusual anatomy consistent with dens in dente (dens invaginatus) and a diagnosis of chronic apical periodontitis (Fig. 7A). The patient's health history was noncontributory, and the parents were presented with treatment options and selected retreatment with MTA obturation. Written consent was provided.

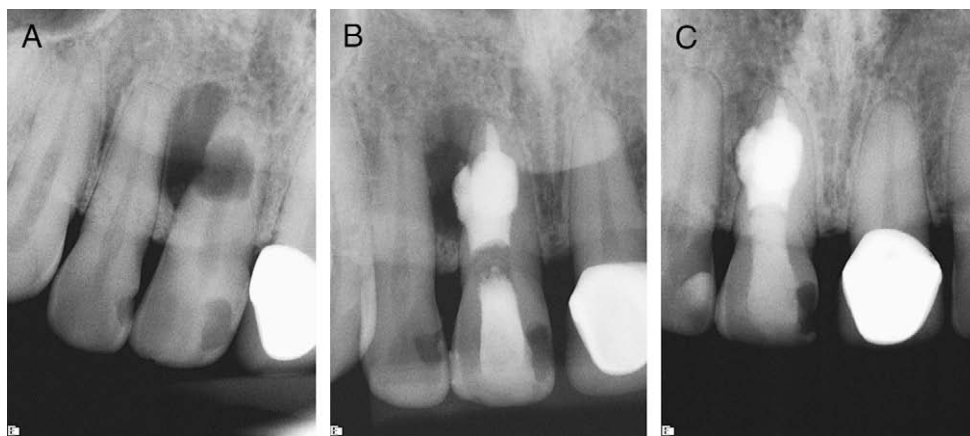
Directly after anesthesia and rubber dam isolation, the tooth was accessed, and the apical compartment was negotiated after ultrasonic penetration of a dentin barrier. Subsequent to chemomechanical debridement with 5.25% NaOCl irrigation, the canal was filled with calcium hydroxide paste. Ten days later, the lateral incisor was accessed, and the canal was prepared to a size 40 MAF with .04 Taper Profiles by using 5.25% NaOCl irrigation without smear layer removal. A second canal was located to the mesiobuccal aspect and prepared to the apex. After the canals were dried, the apical compartment was obturated with gray MTA and the accessory canal with white MTA by using a stainless steel size 35 K-File and 1/3 and 5/7 endodontic pluggers (Fig. 7B). The patient returned for bonded core placement after MTA curing (Fig. 7C), and at 7-year radiographic recall, healing of the apical periodontitis was evident (Fig. 7D). The incisor showed normal mobility, function, and slight discoloration.

These 2 cases substantiate the ability of MTA obturation to fill anatomically complex teeth and effectively seal defects between the canal system and the periodontium. Specifically, the bioinductive properties of the material can generate impressive healing in cases with advanced periapical periodontitis when examined on short-term and long-term radiographic recalls. These features of MTA as an obturation material should be considered when treatment alternatives can predispose teeth to surgical therapy or extraction and implant placement.

In cases in which a supernumerary tooth is removed surgically, MTA can successfully be used to seal communications exposed to the oral environment (128). MTA obturations have been used to seal and retain primary teeth with pulpal involvement where no succedaneous permanent tooth is present (129). The material is also successful in promoting repair and root-end closure in traumatized teeth in which calcium hydroxide therapy is unsuccessful at inducing hard barrier formation (130, 131). Teeth that have undergone traumatic injuries such as luxation, intrusion, or avulsion and replantation can be successfully retained by using MTA as a permanent obturation material (130, 132). MTA is also beneficial in retreatment of failed conventional root canal treatments that have also been subjected to surgical treatment with unresolved healing (133).

In teeth in which perforations occur within the root canal space rather than the pulpal floor, it might be more practical to obturate the entire canal system with MTA. Complete root canal obturation that includes any perforation in the apical, mid-radicular, or coronal area would allow for a thicker layer of MTA and better sealability in the critical perforation area. This should be a consideration in the buccal canals of maxillary molars and the mesial canals of mandibular molars, where post placement if required for a buildup might be contraindicated (134, 135). This procedure also simplifies obturation requirements, because operators will not be required to use 2 different materials to complete the procedure or wait for the MTA to harden. The procedure might also prevent the possibility of dislodging the MTA at the perforation site, when the canal is obturated on the second visit with gutta-percha and sealer.





**Figure 6.** (A) Perforating internal resorptive defect in maxillary left central incisor on 45-year-old male with sinus tract. (B) Complete canal obturation with MTA without matrix placement. (C) One-year radiographic recall with bonded composite core. Courtesy Dr. Mark Olesen, North Vancouver, Canada.

### Obturation Technique

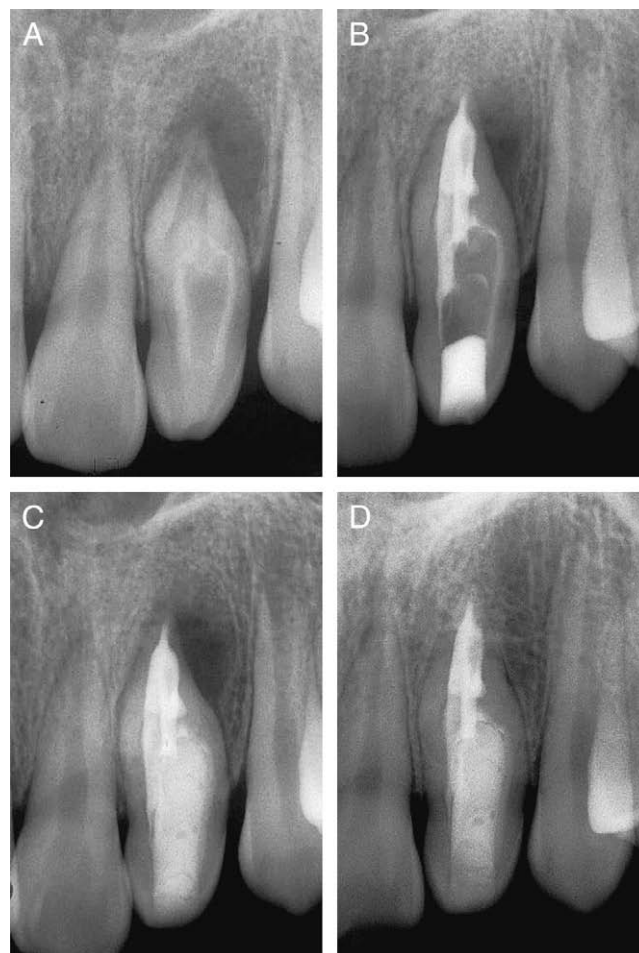Canal obturation with MTA requires the same preparation and irrigation normally executed for gutta-percha placement, although the removal or retention of the smear layer before canal obturation still remains controversial (136). If smear layer removal is not implemented, it does not appear to affect the sealability of MTA materials, and its presence might actually improve the seal over time (137). It has been speculated that the smear layer might act as a “coupling agent” that might enhance MTA bonding to root canal dentin. Because present data are inconclusive regarding smear layer removal, clinicians might choose to leave the smear layer in selected cases and fill canals with MTA, without apparently compromising the outcome.

In conventional nonsurgical root canal treatments in teeth exhibiting closed apices, the main canal apical preparation should be a minimum of size 30; however, a size 35 or 40 MAF is more desirable. White MTA has better handling characteristics and compactibility, attributed to smaller particle sizes, when compared with its counterpart, but gray MTA appears to have superior sealing properties when the material is examined *in vitro* (84). Clinicians should judge which type to use on the basis of an assessment of tooth location, esthetics, and surgical indications.

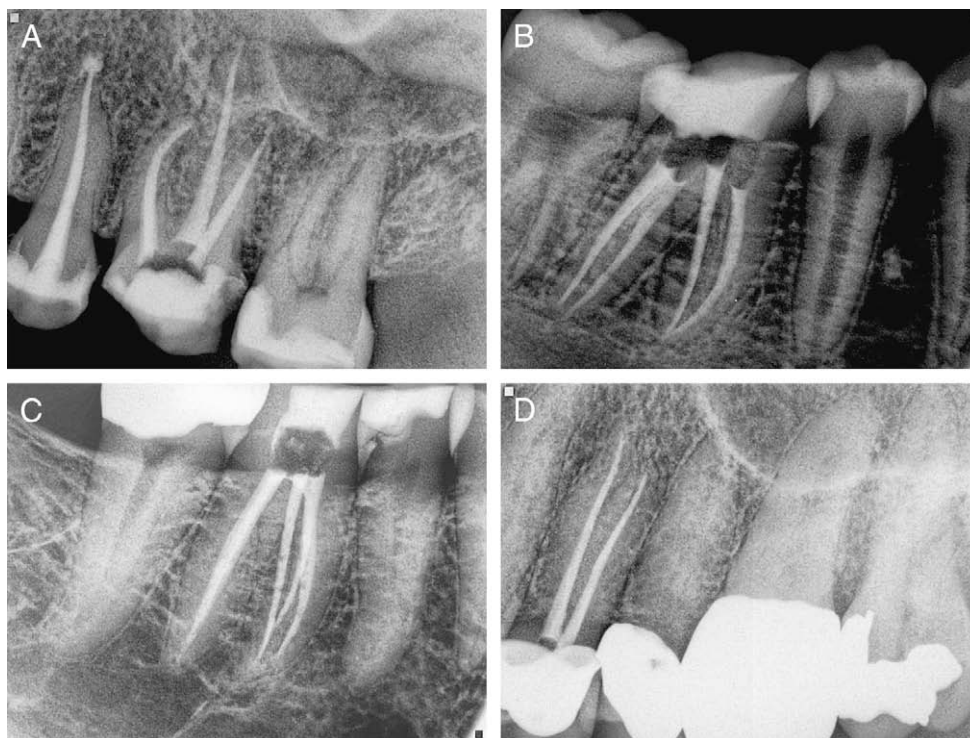
After drying the canal, the mixed MTA is placed in the canal with a carrier gun and advanced apically with an endodontic pluggers, size 9/11, 5/7, 1/3, or a Glick instrument. MTA can be mixed with 0.12% chlorhexidine rather than sterile water or anesthetic solution, which appears to increase its antibacterial properties (138). A stainless steel K-file, 1 or 2 sizes smaller than the MAF, is used to compact the apical 3–5 mm of wet MTA. If the last MAF file size used was a 35, then a size 25 or 30 file (K-file) is used to advance and push the wet MTA apically to the working length. Some clinicians advocate removing the pilot tip to create a flat end before using the instrument for compaction. The first few deliveries of the material will coat the canal walls and the radial lands of the plugging K-file. The file is then directed off the walls circumferentially and pushed with light to moderate pressure. If the tooth apex is closed, firmer pressure can be applied. Hand pluggers can also be used to complete the compaction, but they might be difficult to use in curved canals. Because the MTA condenses apically, the working length will shorten as the compaction of the MTA condenses in the apical 4–5 mm.

An endodontic plunger (size 1/3 or 5/7) can now be placed on top of the MTA after the apical compaction is completed and the top portion of the MTA is visible in the canal. Ultrasonic energy placed against the

plunger can be used to further compress the material by using a low-range setting for the unit. A radiograph is now taken to assess the presence of visible voids. When the clinician is satisfied that the compaction



**Figure 7.** (A) Lateral incisor associated with dens invaginatus (*dens in dente*) and chronic apical periodontitis and sinus tract in 11-year-old male patient. (B) Obturation of apical compartment and accessory canal with white MTA without smear layer removal. (C) Bonded core placement after MTA curing. (D) Seven-year radiographic recall.



**Figure 8.** (A) MTA obturation of maxillary left first molar. (B, C) Mandibular right first molars filled from apex to pulpal floor with white MTA. (D) Maxillary left first premolar with MTA obturation. All cases courtesy Dr. Ingrid Lawaty, Santa Barbara, California.

density is adequate, then fresh MTA can be placed in the canal and compacted from the apical to coronal area by using larger hand files and pluggers.

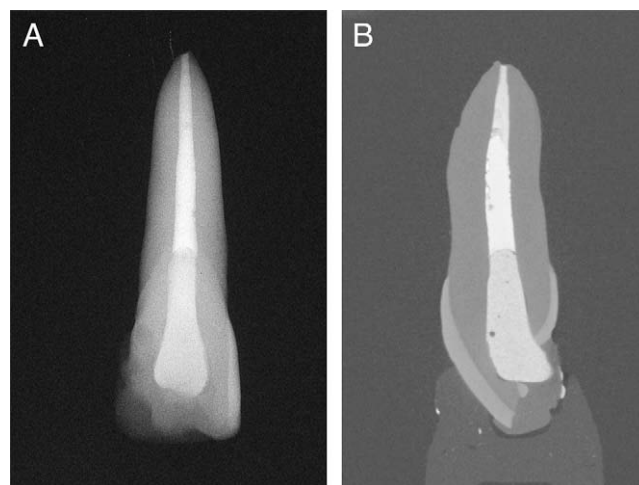
If operators are not satisfied with the obturation density, then the MTA can be recompact by using a smaller K-file (ie, size 20) until an acceptable result is achieved. If visible voids are still present, the MTA can be flushed out with anesthetic or sterile water by using a 27- or 30-gauge needle. If this is unsuccessful, then an ultrasonic size 30 or 35 K-file tip can be used to free up the MTA, and the canal is refilled with a neutral irrigant. In cases in which MTA is packed to the canal orifice and surrounding dentin, a quick spray with both water and air simultaneously from a 2-way syringe will remove any residual material from the access cavity walls and pulpal floor.

Clinicians who elect to backfill the canal with gutta-percha or a resin-based material after placing a MTA plug can irrigate the canal with sterile water by using a side-venting needle. After flushing the canal, it is dried with sterile paper points, and the MTA is packed flat with the end of an appropriately sized endodontic plugger. Minimal force will prevent the extrusion of large amounts of MTA if the root apex is immature or open as a result of apical root resorption. Extruded MTA will not affect periapical healing in most cases (139).

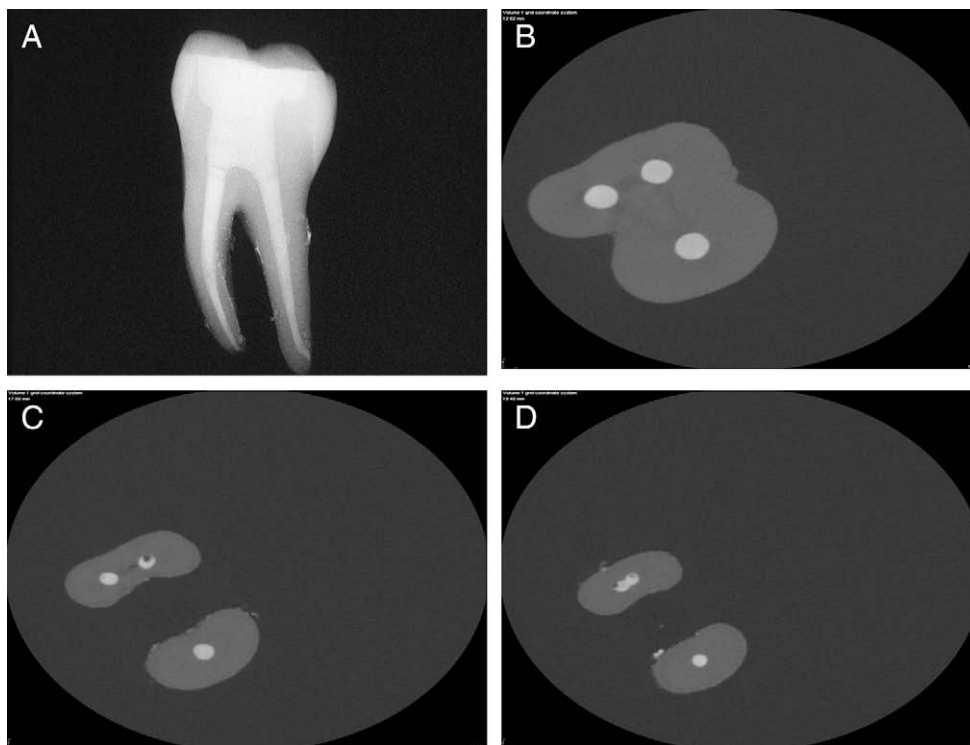
With large open apices, the MTA can be pushed down by using the back end of an extra coarse paper point or Glick instrument. Endodontic pluggers can be used with ultrasonic energy, but the clinician is cautioned to use care with ultrasonics, which can cause large amounts of MTA to extrude apically when open apices are present. Although extruded MTA should not affect the outcome, the esthetics of placement might be a concern for clinicians who are attempting to achieve an ideal result. If extensive hemorrhaging is present with open apices, perforating resorptive defects, or large long-standing perforation sites, the MTA must be placed in larger amounts quickly delivered by using a larger carrier (ie, amalgam carrier) or brought to the canal in bulk. The excess moisture or blood is removed with

dry cotton pellets with or without calcium hydroxide powder pressed over the entire volume of MTA or the back end of an extra coarse paper point until stability of the material is achieved.

The clinician must use their own clinical judgment to control the application of the material in cases of excessive hemorrhaging. If the area has uncontrollable hemorrhaging that cannot be stabilized, then calcium hydroxide placement is recommended until such time that a predictable delivery of the material can be attained. In cases in which post placement might be required as a future treatment option, backfilling the canals with thermoplastic gutta-percha or resin-based



**Figure 9.** (A) Periapical radiograph of extracted right maxillary incisor treated in the laboratory and obturated apically with 5 mm gray MTA, thermoplastic gutta-percha and sealer and composite core. (B) Micro-computed tomography shows voids present in all three filling materials.



**Figure 10.** (A) Periapical radiograph of extracted mandibular right first molar model with complete obturation of all canals using white MTA. (B) Micro-computed tomography of coronal axial section shows dense obturation without voids. (C, D) Mid-root and apical axial sections showing the presence of voids in compacted MTA.

materials and sealers can be implemented. This includes the distal canals of mandibular molars, palatal canals of maxillary molars, the long and straight canals of maxillary premolars, and single canals of anterior teeth. Placement of easily removable obturation materials can be completed after 4–5 mm of MTA is compacted into the apical area. MTA might take considerable time to place in certain teeth, and results will depend on the case requirements and operator experience. Delivery techniques also require patience and practice and are subject to a learning curve.

### Lawaty Technique

The Lawaty technique was introduced by Dr Ingrid Lawaty, Santa Barbara, CA. After cleaning and shaping have been completed, white MTA is mixed in a dappen dish and transferred to the pulpal floor with a Glick instrument. The MTA is placed to half fill the access cavity over the prepared dry canals. The access cavity serves as an MTA reservoir during the compaction process and can be remoistened as needed to maintain a workable consistency of the cement. An apex locator is then attached to a K-file, 1 size smaller than the MAF. This technique can help locate the canal terminus and helps prevent extrusion of the material, although extruded MTA should not negatively affect the outcome of the case. The K-file is moved circumferentially along the canal glide path with an apical pumping motion by using the coronal portion of the canal as a funnel, which allows the MTA to flow from the access cavity reservoir to the canal terminus. The apex locator can be removed as the depth of the canal glide path is reduced, and the apical MTA plug is formed. The MTA can thereafter be circumferentially funneled and pumped more aggressively without substantial risk of extrusion.

Periapical radiographs are taken during the course of the procedure and are recommended for confirmation of dense MTA compac-

tion. This is particularly important for the apical 4- to 5-mm portion of the obturation. A progression of K-files are then used after the formation of the apical MTA plug, sizing upward incrementally to a size 60 K-file. No sizes should be skipped to prevent the potential for void formation. The circumferential funneling and pumping are continued with each file, concluding with the size 60 K-file. After this last file has been used, the canal should be half to two thirds packed. The final coronal portion of the canal might be packed by using Schilder pluggers. Another option available to clinicians, after the apical 4- to 5-mm plug is completed, is to obturate the coronal and mid-root portion of the canal with warm gutta-percha and sealer to facilitate future access for restorative purposes (Fig. 8).

### Disadvantages

MTA does present some disadvantages when used in canal obturation. Gray MTA can discolor teeth if the material is placed in the coronal structure or near the CEJ in anterior teeth. This can be attributed to the reduction of ferrous ions (FeO) into the dentinal tubules that might increase over time (140). This factor is not important if the tooth already has a full coverage metal-based restoration. It might be an important concern in anterior esthetic zones, without PFM restorations, where white MTA can be used as an alternative material. Ceramic crowns and veneers might pose a similar problem if not properly opaqued in the laboratory, and the MTA reaches the level of the CEJ.

Another potential problem with the material can be elective removal after placement and curing. Although removal can be accomplished with the aid of ultrasonics, MTA obturation in curved canals can pose a dilemma (141). The obturation of a curved canal should be considered a permanent filling and therefore treated in the possible event of failure by surgical resection of the root end. Furthermore, operators should inform patients that MTA was used as an alternative

filling material for their endodontic therapy and might complicate treatment options for unknowing future clinicians. Although current obturation techniques with MTA can show dense fills radiographically, micro-computed tomography of extracted teeth reveals small voids present in most experimental specimens (Figs. 9 and 10). Although these voids can be detected when current delivery protocols are used, they appear not to affect biologic mechanisms necessary for favorable healing.

Another minor drawback is the slow setting time of ProRoot MTA. The material can take 2.5–4.0 hours for an initial set, but it requires 21 days for complete curing (142). In younger patients with immature teeth that exhibit wide canals and open apices where management considerations mandate a 1-visit procedure, the top of the MTA can be dried with paper points, and a flowable compomer can be placed over the exposed MTA. A light-cured or self-cured bonded core or glass ionomer material can be placed over the compacted MTA and compomer to complete treatment in 1 visit. Molars or premolars with smaller canals that require treatment in 1 visit can be backfilled after 4–5 mm of MTA is packed apically. The canals are flushed with sterile water by using a side-venting needle and dried with paper points, and thermoplastic gutta-percha and sealer are placed without using a flowable compomer over the unset MTA.

## Conclusion

Scientific investigations in root canal obturation and MTA obturated reimplantation studies have revealed the remarkable potential for this bioactive tricalcium silicate cement to stimulate the biologic mechanisms necessary for repair and retention of involved teeth. Unsuccessful root canal treatments compromised by microleakage, inadequate cleaning and shaping, poor quality obturations, and large periapical lesions can demonstrate superior healing rates when this osteoinductive and cementogenic material is used to fill the root canal system. It appears that teeth obturated with MTA might not only increase their fracture resistance with time, but bacteria might be effectively entombed and neutralized in severely infected teeth. Moreover, if a filling material can substantially improve endodontic outcomes and provide a wide range of treatment options that prolong the retention of the natural dentition and avoid implant placement (143), then some disadvantages might have to be overlooked in favor of the superior physiochemical properties. Although MTA might not exhibit all the characteristics necessary for the ideal filling material, patients requiring complex endodontic treatment might benefit from its bioinductive properties in conventional and surgical therapies.

## Acknowledgments

*The authors thank Dr Leif Bakland, Chairman, Department of Endodontics, and Dr Mahmoud Torabinejad, Director, Advanced Education in Endodontics, Loma Linda University, California and Dr Nicholas Chandler, associate professor, Department of Oral Rehabilitation, School of Dentistry, University of Otago, Dunedin, New Zealand for their support and guidance.*

## References

- Grossman LI. Endodontic practice. 10th ed. Philadelphia: Lea and Febiger; 1982; 279.
- Schilder H. Cleaning and shaping the root canal. *Dent Clin North Am* 1974;18: 269–96.
- Sundqvist G, Figdor D. Endodontic treatment of apical periodontitis. In: Ørstavik D, Pitt Ford TR, eds. *Essential endodontology: prevention and treatment of apical periodontitis*. 1st ed. Oxford, UK: Blackwell; 1998.
- Madison S, Wilcox LR. An evaluation of coronal microleakage in endodontically treated teeth: part III—in vivo study. *J Endod* 1988;14:455–8.
- Chailertvanitkul P, Saunders WP, MacKenzie D. The effect of the smear layer on the microbial coronal leakage of gutta-percha root fillings. *Int Endod J* 1996;29: 242–8.
- Jacobson HL, Xia T, Baumgartner JC, Marshall JG, Beeler WJ. Microbial leakage evaluation of the continuous wave of condensation. *J Endod* 2002;28:269–71.
- Fransen JN, He J, Glickman GN, Rios A, Shulman JD, Honeyman A. Comparative assessment of Activ GP/Glass ionomer sealer, Resilon/Epiphany, and gutta-percha/AH plus obturation: a bacterial leakage study. *J Endod* 2008;34:725–7.
- Khayat A, Lee SJ, Torabinejad M. Human saliva penetration of coronally unsealed obturated root canals. *J Endod* 1993;19:458–61.
- Alves J, Walton R, Drake D. Coronal leakage: endotoxin penetration from mixed bacterial communities through obturated, post-prepared canals. *J Endod* 1998; 24:587–91.
- Siqueira JF Jr., Rôças IN, Favieri A, Abad EC, Castro AJ, Gahyva SM. Bacterial leakage in coronally unsealed root canals obturated with 3 different techniques. *Oral Surg Oral Med Oral Pathol Oral Radiol Endod* 2000;90:647–50.
- Ray HA, Trope M. Periapical status of endodontically treated teeth in relationship to the technical quality of the root filling and the coronal restoration. *Int Endod J* 1995;28:12–8.
- Tronstad L, Asbjørnsen K, Døving L, Pedersen I, Eriksen HM. Influence of coronal restorations on the periapical health of endodontically treated teeth. *Endod Dent Traumatol* 2000;16:218–21.
- Saunders WP, Saunders EM. Coronal leakage as a cause of failure in root canal therapy: a review. *Endod Dent Traumatol* 1994;10:105–8.
- Uranga A, Blum JY, Esber S, Parahy E, Prado C. A comparative study of four coronal obturation materials in endodontic treatment. *J Endod* 1999;25:178–80.
- Balto H. An assessment of microbial coronal leakage of temporary materials in endodontically treated teeth. *J Endod* 2002;28:762–4.
- Weston CH, Barfield RD, Ruby JD, Litaker MS, McNeal SF, Eleazer PD. Comparison of preparation design and material thickness on microbial leakage through Cavit using a tooth model system. *Oral Surg Oral Med Oral Pathol Oral Radiol Endod* 2008;105:530–5.
- Begotka BA, Hartwell GR. The importance of coronal seal following root canal treatment. *Va Dent J* 1996;73:8–10.
- Torabinejad M, Watson TF, Pitt Ford TR. Sealing ability of a mineral trioxide aggregate when used as root end filling material. *J Endod* 1993;19:591–5.
- Shabahang S, Torabinejad M, Boyne PJ, Abedi HH, McMillan P. Apexification in immature dog teeth using osteogenic protein-1, mineral trioxide aggregate and calcium hydroxide. *J Endod* 1999;25:1–5.
- Torabinejad M, Chivian N. Clinical applications of mineral trioxide aggregate. *J Endod* 1999;25:197–205.
- Lee SJ, Monsef M, Torabinejad M. The sealing ability of a mineral trioxide aggregate for repair of lateral root perforations. *J Endod* 1993;19:541–4.
- Torabinejad M, Watson TF, Pitt Ford TR. The sealing ability of a mineral trioxide aggregate as a retrograde root filling material. *J Endod* 1993;19:591–5.
- Torabinejad M, Higa RK, McKendry DJ, Pitt Ford TR. Dye leakage of four root-end filling materials: effects of blood contamination. *J Endod* 1994;20:159–63.
- Torabinejad M, Falah R, Kettering JD, Pitt Ford TR. Comparative leakage of mineral trioxide aggregate as a root end filling material. *J Endod* 1995;21:109–21.
- Torabinejad M, Wilder Smith P, Pitt Ford TR. Comparative investigation of marginal adaptation of mineral trioxide aggregate and other commonly used root end filling materials. *J Endod* 1995;21:295–9.
- Aqrabawi J. Sealing ability of amalgam, super EBA cement, and MTA when used as retrograde filling material. *Br Dent J* 2000;188:266–8.
- Roberts HW, Toth JM, Berzins DW, Charlton DG. Mineral trioxide aggregate material use in endodontic treatment: a review of the literature. *Dent Mater* 2008;24: 149–64.
- Dammashcke T, Gerth HUV, Züchner H, Schäfer E. Chemical and physical surface and bulk material characterization of white ProRoot MTA and two Portland cements. *Dent Mater* 2005;21:731–8.
- Taylor HFN. *Cement chemistry*. 2nd ed. London: Thomas Telford, 1997.
- Ozdemir HO, Özçelik B, Karabucak B, Cehreli ZC. Calcium ion diffusion from mineral trioxide aggregate through simulated root resorption defects. *Dent Traumatol* 2008;24:70–3.
- Camilleri J. Characterization and chemical activity of Portland cement and two experimental cements with potential for use in dentistry. *Int Endod J* 2008;41: 791–9.
- Sarkar NK, Caicedo R, Ritwik P, Moiseyeva R, Kawashima I. Physicochemical basis of the biological properties of mineral trioxide aggregate. *J Endod* 2005;31:97–100.
- Bozeman TB, Lemon RR, Eleazer PD. Elemental analysis of crystal precipitate from gray and white MTA. *J Endod* 2006;32:425–8.
- Torabinejad M, Watson TF, Pitt Ford TR. The sealing ability of a mineral trioxide aggregate as a retrograde root filling material. *J Endod* 1993;19:591–5.
- Komabayashi T, Spångberg LS. Particle size and shape analysis of MTA finer fractions using Portland cement. *J Endod* 2008;34:709–11.

36. Fridland M, Rosado R. MTA solubility: a long term study. *J Endod* 2005;31:376–9.
37. Santos AD, Moraes JCS, Araújo EB, Yukimitu K, Valério Filho WV. Physico-chemical properties of MTA and a novel experimental cement. *Int Endod J* 2005;38:443–7.
38. Molander A, Reit C, Dahlén G, Kvist T. Microbiological status of root-filled teeth with apical periodontitis. *Int Endod J* 1998;31:1–7.
39. Eldeniz AU, Hadimli HH, Ataoglu H, Ørstavik D. Antibacterial effect of selected root-end filling materials. *J Endod* 2006;32:345–9.
40. Torabinejad M, Hong CU, Pitt Ford TR, Kettering JD. Antibacterial effects of some root end filling materials. *J Endod* 1995;21:403–6.
41. Al-Hezaimi K, Al-Shalan TA, Naghshbandi J, Oglesby S, Simon JH, Rotstein I. Antibacterial effect of two mineral trioxide aggregate (MTA) preparations against *Enterococcus faecalis* and *Streptococcus sanguis* in vitro. *J Endod* 2006;32:1053–6.
42. Holt DM, Watts JD, Beeson TJ, Kirkpatrick TC, Ruteledge RE. The anti-microbial effect against *Enterococcus faecalis* and the compressive strength of two types of mineral trioxide aggregate filled with sterile water or 2% chlorhexidine liquid. *J Endod* 2007;33:844–7.
43. Sen BH, Safavi KE, Spångberg LS. Colonization of *Candida albicans* on cleaned human dentin hard tissues. *Arch Oral Biol* 1997;42:513–20.
44. Al-Nazhan S, Al-Judai A. Evaluation of antifungal activity of mineral trioxide aggregate. *J Endod* 2003;29:826–7.
45. Mohammadi Z, Modaresi J, Yazdizadeh M. Evaluation of the antifungal effects of mineral trioxide aggregate materials. *Aust Endod J* 2006;32:120–2.
46. Al-Hezaimi K, Naghshbandi J, Oglesby S, Simon JH, Rotstein I. Comparison of antifungal activity of white-colored and gray colored mineral trioxide aggregate (MTA) at similar concentrations against *Candida albicans*. *J Endod* 2006;32:365–7.
47. Kvist T, Reit C. Results of endodontic retreatment: a randomized clinical study comparing surgical and nonsurgical procedures. *J Endod* 1999;25:814–7.
48. Kvist T, Reit C. Postoperative discomfort associated with surgical and nonsurgical endodontic treatment. *Endod Dent Traumatol* 2000;15:309–12.
49. Bortoluzzi EA, Souza EM, Reis JM, Esberard RM, Tanomaru-Filho M. Fracture strength of bovine incisors after intra-radicular treatment with MTA in an experimental immature tooth model. *Int Endod J* 2007;40:684–91.
50. Hatibović-Kofman S, Raimundo L, Chong L, Moreno J, Zheng L. Mineral trioxide aggregate in endodontic treatment for immature teeth. *Conf Proc IEEE Eng Med Biol Soc* 2006;1:2094–7.
51. Hatibović-Kofman S, Raimundo L, Zheng L, Chong L, Friedman M, Andreasen JO. Fracture resistance and histological findings of immature teeth treated with mineral trioxide aggregate. *Dent Traumatol* 2008;24:272–6.
52. Andreasen JO, Farik B, Munksgaard EC. Long-term calcium hydroxide as a root canal dressing may increase risk of root fracture. *Dent Traumatol* 2002;18:134–7.
53. Andreasen JO, Munksgaard EC, Bakland LK. Comparison of fracture resistance in root canals of immature sheep teeth after filling with calcium hydroxide or MTA. *Dent Traumatol* 2006;22:154–6.
54. Saupé WA, Gluskin AH, Radke RA. A comparative study of fracture resistance between morphologic dowel and cores and a resin-reinforced dowel system in the intraradicular restoration of structurally compromised roots. *Quintessence Int* 1996;27:483–91.
55. Katebzadeh N, Dalton BC, Trope M. Strengthening immature teeth during and after apexification. *J Endod* 1998;24:256–9.
56. Pene JR, Nichols JI, Harrington GW. Evaluation of fiber-composite laminate in the restoration of immature, nonvital maxillary incisors. *J Endod* 2001;27:18–22.
57. Pitt Ford TR, Torabinejad M, McKendry DJ, Hong CU, Kariyawasam SP. Use of mineral trioxide aggregate for repair of furcal perforations. *Oral Surg Oral Med Oral Pathol Oral Radiol Endod* 1995;79:756–63.
58. Torabinejad M, Pitt Ford TR, McKendry DJ, Abedi HR, Kariyawasam SP. Histologic assessment of MTA as a root-end filling in monkeys. *J Endod* 1997;23:225–8.
59. Regan JD, Gutmann JL, Witherspoon DE. Comparison of Diaket and MTA when used as root-end filling materials to support regeneration of the periradicular tissues. *Int Endod J* 2002;35:840–7.
60. Economides N, Pantelidou O, Kokkas A, Tziapas D. Short-term periradicular tissue response to mineral trioxide aggregate (MTA) as a root-end filling material. *Int Endod J* 2003;36:44–8.
61. Zhu Q, Haglund R, Safavi KE, Spångberg LS. Adhesion of human osteoblasts on root-end filling materials. *J Endod* 2000;26:404–6.
62. Zhao G, Zinger O, Schwartz Z, Wieland M, Landolt D, Boyan BD. Osteoblast-like cells are sensitive to submicron-scale surface structure. *Clin Oral Implants Res* 2006;17:258–64.
63. Koh ET, Torabinejad M, Pitt Ford TR, Brady K, McDonald F. Mineral trioxide aggregate stimulates a biological response in human osteoblasts. *J Biomed Mater Res* 1997;37:432–9.
64. Koh ET, McDonald F, Pitt Ford TR, Torabinejad M. Cellular response to mineral trioxide aggregate. *J Endod* 1998;24:543–7.
65. Mitchell PJ, Pitt Ford TR, Torabinejad M, McDonald F. Osteoblast biocompatibility of mineral trioxide aggregate. *Biomaterials* 1999;20:167–73.
66. Yaltirik M, Ozbas H, Bilgic B, Issever H. Reactions of connective tissue to mineral trioxide aggregate and amalgam. *J Endod* 2004;30:95–9.
67. Bernabé PF, Holland R, Morandi R, et al. Comparative study of MTA and other materials in retrofilling of pulpless dogs' teeth. *Braz Dent J* 2005;16:149–55.
68. Torabinejad M, Hong CU, Lee SJ, Monsef M, Pitt Ford TR. Investigation of mineral trioxide aggregate for root-end filling in dogs. *J Endod* 1995;21:603–8.
69. Apaydin ES, Shabahang S, Torabinejad M. Hard-tissue healing after application of fresh or set MTA as a root-end-filling material. *J Endod* 2004;30:21–4.
70. Economides N, Pantelidou O, Kokkas A, Tziapas D. Short-term periradicular tissue response to mineral trioxide aggregate (MTA) as root-end filling material. *Int Endod J* 2003;36:44–8.
71. Holland R, de Souza V, Nery MJ, Otoboni Filho JA, Bernabé PF, Dezan Júnior E. Reaction of dogs' teeth to root filling with mineral trioxide aggregate or a glass ionomer sealer. *J Endod* 1999;25:728–30.
72. Holland R, Filho JAO, de Souza V, Nery MJ, Bernabé PFE. Mineral trioxide aggregate repair of lateral root perforations. *J Endod* 2001;27:281–4.
73. Panzarini SR, Holland R, de Souza V, Poi WR, Sonoda CK, Pedrini D. Mineral trioxide aggregate as a root canal filling material in reimplanted teeth: microscopic analysis in monkeys. *Dent Traumatol* 2007;23:265–72.
74. Ozdemir HO, Özçelik B, Karabucak B, Cehreli ZC. Calcium ion diffusion from mineral trioxide aggregate through simulated root resorption defects. *Dent Traumatol* 2008;24:70–3.
75. Bonson S, Jeansonne BG, Lallier TE. Root-end filling materials alter fibroblast differentiation. *J Dent Res* 2004;83:408–13.
76. Fayad MI, Hawkinson R, Daniel J, Hao J. The effect of CO<sub>2</sub> laser irradiation on PDL cell attachment to resected root surfaces. *Oral Surg Oral Med Oral Pathol Oral Radiol Endod* 2004;97:518–23.
77. Martin RL, Monticelli F, Brackett WW, et al. Sealing properties of mineral trioxide aggregate orthograde plugs and root fillings in an in vitro apexification model. *J Endod* 2007;33:272–5.
78. Chogle S, Mickel AK, Chan DM, Huffaker K, Jones JJ. Intracanal assessment of mineral trioxide aggregate setting and sealing properties. *Gen Dent* 2007;55:306–11.
79. Matt GD, Thorpe JR, Strother JM, McClanahan SB. Comparative study of white and gray mineral trioxide aggregate (MTA) simulating a one-or two-step apical barrier technique. *J Endod* 2004;30:876–9.
80. Al-Kahtani A, Shostad S, Schifferle R, Bhambhani S. In-vitro evaluation of micro-leakage of an orthograde apical plug of mineral trioxide aggregate in permanent teeth with simulated immature apices. *J Endod* 2005;31:117–9.
81. Hachmeister DR, Schindler WG, Walker WA 3rd, Thomas DD. The sealing ability and retention characteristics of mineral trioxide aggregate in a model of apexification. *J Endod* 2002;28:386–90.
82. Lawley GR, Schindler WG, Walker WA 3rd, Kolodrubetz D. Evaluation of ultrasonically placed MTA and fracture resistance with intracanal composite resin in a model of apexification. *J Endod* 2004;30:167–72.
83. Aminoshariae A, Hartwell GR, Moon PC. Placement of mineral trioxide aggregate using two different techniques. *J Endod* 2003;29:679–82.
84. Al-Hezaimi K, Naghshbandi J, Oglesby S, Simon JH, Rotstein I. Human saliva penetration of root canals obturated with two types of mineral trioxide aggregate cements. *J Endod* 2005;31:453–6.
85. Valois CR, Costa ED Jr. Influence of the thickness of mineral trioxide aggregate on sealing ability of root-end fillings in vitro. *Oral Surg Oral Med Oral Pathol Oral Radiol Endod* 2004;97:108–11.
86. Vizgirda PJ, Liewehr FR, Patton WR, McPherson JC, Buxton TB. A comparison of laterally condensed gutta-percha, thermoplasticized gutta-percha, and mineral trioxide aggregate as root canal filling materials. *J Endod* 2004;30:103–6.
87. Barrieshi-Nusair KM, Hammad HM. Intracoronary sealing comparison of mineral trioxide aggregate and glass ionomer. *Quintessence Int* 2005;36:539–45.
88. John AD, Webb TD, Imamura G, Goodell GG. Fluid flow evaluation of Fuji Triage and gray and white ProRoot mineral trioxide aggregate intraorifice barriers. *J Endod* 2008;34:830–2.
89. Tselnik M, Baumgartner JC, Marshall JG. Bacterial leakage with mineral trioxide aggregate or a resin-modified glass ionomer used as a coronal barrier. *J Endod* 2004;30:782–4.
90. Martell B, Chandler NP. Electrical and dye leakage comparison of three root-end restorative materials. *Quintessence Int* 2002;33:30–4.
91. Fischer EJ, Arens DE, Miller CH. Bacterial leakage of mineral trioxide aggregate as compared with zinc-free amalgam, intermediate restorative material, and super-EBA as a root-end filling material. *J Endod* 1998;24:176–9.
92. Torabinejad M, Rastegar AF, Kettering JD, Pitt Ford TR. Bacterial leakage of mineral trioxide aggregate as a root-end filling material. *J Endod* 1995;21:109–12.
93. Tang HM, Torabinejad M, Kettering JD. Leakage evaluation of root end filling materials using endotoxin. *J Endod* 2002;28:5–7.

94. Andelin WE, Browning DF, Hsu GH, Roland DD, Torabinejad M. Microleakage of resected MTA. *J Endod* 2002;28:573-4.
95. Lamb EL, Loushine RJ, Weller RN, Kimbrough WF, Pashley DH. Effect of root resection on the apical sealing ability of mineral trioxide aggregate. *Oral Surg Oral Med Oral Pathol Oral Radiol Endod* 2003;95:732-5.
96. Goldberg RA, Kuttler SA, Dorn SO. The properties of Endocal 10 and its potential impact on the structural integrity of the tooth. *J Endod* 2004;30:159-62.
97. Hashem AA, Hassanien EE. ProRoot MTA, MTA-Angelus and IRM used to repair large furcation perforations: sealability study. *J Endod* 2008;34:59-61.
98. Song JS, Mante FK, Romanow WJ, Kim S. Chemical analysis of powder and set forms of Portland cement, gray ProRoot MTA, white ProRoot MTA, and gray MTA-Angelus. *Oral Surg Oral Med Oral Pathol Oral Radiol Endod* 2006;102:809-15.
99. Shabahang S, Torabinejad M, Boyne PJ, Abedi HH, McMillan P. Apexification in immature dog teeth using osteogenic protein-1, mineral trioxide aggregate and calcium hydroxide. *J Endod* 1999;25:1-5.
100. Krupalini KS, Udayakumar, Jayalakshmi KB. A comparative evaluation of medicated calcium sulphate, hydroxyapatite, mineral trioxide aggregate (MTA) as a barrier and their effect on the sealing ability of furcation perforation repair material: an in vitro study. *Indian J Dent Res* 2003;14:156-61.
101. Ghodduji J, Samaan A, Shahrani F. Clinical and radiographic evaluation of root perforation repair using MTA. *N Y State Dent J* 2007;73:46-9.
102. Nakata TT, Bae KS, Baumgartner JC. Perforation repair comparing mineral trioxide aggregate and amalgam using an anaerobic leakage mode. *J Endod* 1998;24:184-6.
103. Holland R, Filho JA, de Souza V, Nery MJ, Bernabé PF, Junior ED. Mineral trioxide aggregate repair of lateral root perforations. *J Endod* 2001;27:281-4.
104. Main C, Mirzayan N, Shabahang S, Torabinejad M. Repair of root perforations using mineral trioxide aggregate: a long-term study. *J Endod* 2004;30:80-3.
105. Pace R, Giuliani V, Pagavino G. Mineral trioxide aggregate as repair material for furcation perforation: case series. *J Endod* 2008;34:1130-3.
106. de Leimburg ML, Angerett A, Ceruti P, Lendini M, Pasqualini D, Berutti E. MTA obturation of pulpless teeth with open apices; bacterial leakage as detected by polymerase chain reaction assay. *J Endod* 2004;30:883-6.
107. Maroto M, Barberia E, Planells P, Vera V. Treatment of a non-vital immature incisor with mineral trioxide aggregate (MTA). *Dent Traumatol* 2003;19:165-9.
108. Pradhan DP, Chawala HS, Gauba K, Goyal A. Comparative evaluation of endodontic management of teeth with unformed apices with mineral trioxide aggregate and calcium hydroxide. *J Dent Child* 2006;73:72-85.
109. Karp J, Bryk J, Menke E, McTigue D. The complete endodontic obturation of an avulsed immature permanent incisor with mineral trioxide aggregate: a case report. *Pediatr Dent* 2006;28:273-8.
110. Villa P, Fernández R. Apexification of a replanted tooth using mineral trioxide aggregate. *Dent Traumatol* 2005;21:306-8.
111. Erdem AP, Sepet E. Mineral trioxide aggregate for obturation of maxillary central incisors with necrotic pulp and open apices. *Dent Traumatol* 2008;24:e38-41.
112. Giuliani V, Baccetti T, Pace R, Pagavino G. The use of MTA in teeth with necrotic pulps and open apices. *Dent Traumatol* 2002;18:217-21.
113. D'Arcangelo C, D'Amario M. Use of MTA for orthograde obturation of nonvital teeth with open apices; report of two cases. *Oral Surg Oral Med Oral Pathol Oral Radiol Endod* 2007;104:e98-101.
114. Shabahang S, Torabinejad M. Treatment of teeth with open apices using mineral trioxide aggregate. *Pract Periodontics Aesthet Dent* 2000;12:315-20.
115. Gaitonde P, Bishop K. Apexification with mineral trioxide aggregate: an overview of the material and technique. *Eur J Prosthodont Restor Dent* 2007;15:41-5.
116. Huang GT, Sonoyama W, Liu Y, Wang S, Shi S. The hidden treasure in apical papilla: the role in pulp/dentin regeneration and biroot engineering. *J Endod* 2008;34:645-51.
117. Holden DT, Schwartz SA, Kirkpatrick TC, Schindler WG. Clinical outcomes of artificial root-barriers with mineral trioxide aggregate in teeth with immature apices. *J Endod* 2008;34:812-7.
118. El-Meligy OA, Avery DR. Comparison of apexification with mineral trioxide aggregate and calcium hydroxide. *Pediatr Dent* 2006;28:248-53.
119. Holland R, Mazuqueli L, de Souza V, Murata SS, Dezan Júnior E, Suzuki P. Influence of the type of vehicle and limit of obturation on apical and periapical tissue response in dogs' teeth after root canal filling with mineral trioxide aggregate. *J Endod* 2007;33:693-7.
120. Witherspoon DE, Small JC, Regan JD, Nunn M. Retrospective analysis of open apex teeth obturated with mineral trioxide aggregate. *J Endod* 2008;34:1171-6.
121. Waltimo TM, Sen BH, Meurman JH, Ørstavik D, Haapasalo MP. Yeasts in apical periodontitis. *Crit Rev Oral Biol Med* 2003;14:128-37.
122. Stuart CH, Schwartz SA, Beeson TJ, Owatz CB. *Enterococcus faecalis*: its role in root canal treatment failure and current concepts in retreatment. *J Endod* 2006;32:93-8.
123. Friedman S. Expected outcomes in the prevention and treatment of apical periodontitis. In: Ørstavik D, Pitt Ford TR, eds. *Essential endodontology: prevention and treatment of apical periodontitis*. 1st ed. Oxford: UK:Blackwell; 1998.
124. de Oliveira LD, Jorge AO, Carvalho CA, Kago-Ito CY, Valera MC. In vitro effects of endodontic irrigants on endotoxins in root canals. *Oral Surg Oral Med Oral Pathol Oral Radiol Endod* 2007;104:135-42.
125. Buck RA, Eleazer PD, Staat Rh, Scheetz JP. Effectiveness of three endodontic irrigants at various tubular depths in human dentin. *J Endod* 2001;27:206-8.
126. Komorowski R, Grad H, Wu XY, Friedman S. Antimicrobial substantivity of chlorhexidine-treated bovine root dentin. *J Endod* 2000;26:315-7.
127. Jacobovitz M, de Lima RKP. Treatment of inflammatory internal root resorption with mineral trioxide aggregate: a case report. *Int Endod J* 2008;41:905-12.
128. Kim E, Jou YT. A supernumerary tooth fused to the facial surface of a maxillary permanent central incisor: case report. *J Endod* 2000;26:45-8.
129. O'Sullivan SM, Hartwell GR. Obturation of a retained primary mandibular second molar using mineral trioxide aggregate: a case report. *J Endod* 2001;27:703-5.
130. Schmitt D, Lee J, Bogen G. Multifaceted use of ProRoot MTA root canal repair material. *Pediatr Dent* 2001;23:326-30.
131. Maroto M, Barberia E, Planells P, Vera V. Treatment of a non-vital immature incisor with mineral trioxide aggregate (MTA). *Dent Traumatol* 2003;19:165-9.
132. Oliveira TM, Sakai VT, Silva TC, Santos CF, Abdo RC, Machado MA. Mineral trioxide aggregate as an alternative treatment for intruded permanent teeth with root resorption and incomplete apex formation. *Dent Traumatol* 2008;24:565-8.
133. Hayashi M, Shimizu A, Edisu S. MTA for obturation of mandibular central incisors with open apices: case report. *J Endod* 2004;30:120-2.
134. Freno JP Jr.. Guidelines for using posts in the restoration of endodontically treated teeth. *Gen Dent* 1998;46:474-9.
135. Schwartz RS, Robbins JW. Post placement and restoration of endodontically treated teeth: a literature review. *J Endod* 2004;30:289-301.
136. Torabinejad M, Handysides R, Khademi AA, Bakland LK. Clinical implications of the smear layer in endodontics: a review. *Oral Surg Oral Med Oral Pathol Oral Radiol Endod* 2002;94:658-66.
137. Yildirim T, Oruçoğlu H, Cobankara FK. Long-term evaluation of smear layer on the apical sealing of MTA. *J Endod* 2008;34:1537-40.
138. Stowe TJ, Sedgley CM, Stowe B, Fenno JC. The effects of chlorhexidine gluconate (0.12%) on the antimicrobial properties of tooth-colored ProRoot mineral trioxide aggregate. *J Endod* 2004;30:429-31.
139. Felipe MC, Felipe WT, Marques MM, Antoniazzi JH. The effect of the renewal of calcium hydroxide paste on the apexification and periapical healing of teeth with incomplete root formation. *Int Endod J* 2005;38:436-42.
140. Asgary S, Parirokh M, Egbal MJ, Brink F. Chemical differences between white and gray mineral trioxide aggregate. *J Endod* 2005;31:101-3.
141. Boutsioukis C, Noula G, Lambrianidid T. Ex vivo study of the efficiency of two techniques for the removal of mineral trioxide aggregate used as a root canal filling material. *J Endod* 2008;34:1239-42.
142. Torabinejad M, Hong CU, McDonald F, Pitt Ford TR. Physical and chemical properties of a new root-end filling material. *J Endod* 1995;21:349-53.
143. Greenstein G, Cavallaro J, Tarnow D. When to save or extract a tooth in the esthetic zone: a commentary. *Compend Contin Educ Dent* 2008;29:136-45.