

# Effects of Root Canal Preparation on Apical Geometry Assessed by Micro-Computed Tomography

Frank Paqué, Dr med dent,\* Daniel Ganahl, med dent,\* and Ove A. Peters, DMD, MS, PhD<sup>†</sup>

## Abstract

**Introduction:** Previous micro-computed tomography analyses of root canal preparation provided data that were usually averaged over canal length. The aim of this study was to compare preparation effects on apical root canal geometry. **Methods:** Sixty extracted maxillary molars (180 canals) used in prior studies were reevaluated for analyses of the apical 4 mm. Teeth were scanned by using micro-computed tomography before and after canal shaping with FlexMaster, GT-Rotary, Lightspeed, ProFile, ProTaper, instruments or nickel-titanium K-files for hand instrumentation. Apical preparation was to a size #40 in mesiobuccal and distobuccal and #45 in palatal canals except for GT (#20) and ProTaper (#25 in mesiobuccal and distobuccal and #30 in palatal canals, respectively). Data for canal volume changes, the structure model index (quantifying canal cross sections), and untreated surface area were contrasted by using analysis of variance and Scheffé tests. **Results:** Mean mesiobuccal, distobuccal, and palatal canal volumes increased after preparation ( $P < .05$ ), but differences were noted for preparation techniques. GT rendered the smallest ( $0.20 \pm 0.14 \text{ mm}^3$ ); K-files and ProFile showed the largest volume increases ( $0.51 \pm 0.20 \text{ mm}^3$  and  $0.45 \pm 0.21 \text{ mm}^3$ ,  $P < .05$ ). All canals were slightly rounder in the apical 4 mm after preparation indicated by nonsignificant increases in structure model index. Untreated areas ranged from 4%–100% and were larger in mesiobuccal and palatal canals than in distobuccal ones. Preparation with GT left significantly larger untreated areas in all canal types ( $P < .05$ ); among root canal types, distobuccal canals had the least amounts of untreated surface areas. **Conclusions:** Apical canal geometry was affected differently by 6 preparation techniques; preparations with GT instruments to an apical size #20 left more canal surface untouched, which might affect the ability to disinfect root canals in maxillary molars. (*J Endod* 2009;35:1056–1059)

## Key Words

Micro-computed tomography, root canal disinfection, rotary instrumentation

The major goal of root canal therapy is to remove microorganisms from the root canal system to prevent or heal apical periodontitis (1). This is currently done by mechanically shaping and chemically cleaning the root canal system; subsequent root canal filling and an adequate coronal seal prevent coronal leakage and exclude potential remaining microorganisms from nutrients.

Cleaning and shaping of root canals successfully require high volumes of irrigation solutions that can only be applied to the apical root canal third after enlargement with instruments (2–4). Nickel-titanium (NiTi) rotary instruments have become an important adjunct for root canal shaping, and outcomes with these instruments are fairly predictable (5). However, there is no agreement concerning the ideal apical width of preparation (6). It has been proposed to enlarge the apical part of the root canal by 3 sizes more than the first file that bound at length (7). However, this recommendation is a matter of debate for 2 reasons (8). First, the determination of first file that binds does not correlate with the true apical dimension (9). Second, it is unclear whether enlarging by 3 sizes will adequately remove dentin circumferentially from the root canal walls (10).

On the other hand, preparing to small apical dimensions is recommended for prevention of instrumentation errors such as apical transportation and also to preserve as much radicular dentin as possible. There is conflicting evidence regarding the antimicrobial efficacy of small (ie, size #20) apical preparations (11, 12). The relationship of apical size and root canal filling is even less well-understood. Allison et al (13) suggested that a size and taper that allow a spreader to penetrate to about 1 mm from working length were promoting better sealing ability of laterally compacted gutta-percha compared with shorter spreader penetration.

Root canal anatomy was assessed before and after preparation, besides other approaches, from double-exposure radiographs (14), from cross-sections by using the technique of Bramante et al (15), and more recently from micro-computed tomography (MCT) data (16–18). The latter technique allows nondestructive and metrically exact analyses of variables such as volume, surface areas, cross-sectional shape, taper, and the fraction of prepared surface (19).

During the last decade, studies based on MCT have provided data on preparation effects for several different NiTi instruments, averaged for the full root canal length or sometimes split into root canal thirds. Although the effects shown are visually dramatic, the quantitative data are less clear. For example, comparing the instruments, it appeared that despite varying apical enlargement, there was no significant difference concerning the untreated root canal surface (16–18). One possible explanation is that the rendered data were averaged over canal lengths. Taken together with the importance of apical enlargement for canal disinfection, more detailed assessments of the apical canal section are of interest. This analysis can be done by using the existing data sets from earlier studies comparing NiTiFlex (Dentsply Maillefer, Ballaigues, Switzerland), LightSpeed (formerly by LightSpeed, San Antonio, TX), ProFile (Dentsply

From the \*Division of Endodontology, University of Zurich Dental School, Zurich, Switzerland; and <sup>†</sup>Department of Endodontics, Arthur A. Dugoni School of Dentistry, University of the Pacific, San Francisco, California.

Address requests for reprints to Dr Frank Paqué, University of Zurich Dental School, Plattenstr. 11, CH-8028 Zurich, Switzerland. E-mail address: frank.paque@zmk.uzh.ch.

0099-2399/\$0 - see front matter

Copyright © 2009 American Association of Endodontists.

doi:10.1016/j.joen.2009.04.020

Maillefer), GT (Dentsply Tulsa Dental, Tulsa OK) (16), FlexMaster (VDW, Munich, Germany) (17), and ProTaper (Dentsply Maillefer) (18).

Therefore, the aim of this study was to compare apical root canal shapes after preparation with 6 different NiTi instruments. Specifically, apical volumes, surface areas, cross-sectional shape, and fractions of treated surfaces were assessed in the apical 4 mm of maxillary molars.

## Materials and Methods

Sixty extracted maxillary molars with 180 root canals used in previous studies (16–18) were reevaluated for analyses of the apical 4 mm. The teeth had been scanned by using an MCT system at an isotropic resolution of 34 or 39.2  $\mu\text{m}$ . This was done without probing the root canals for patency to avoid modifying the canals' apical anatomy. No attempt was made to locate or shape the second mesiobuccal canals because their anatomy was too variable for the purpose of this study. After root canal preparation the teeth were scanned again, and binary images of the root canals were constructed. The special mounting device ensured a very close approximation of the pre-preparation and postpreparation images; in a second step, iterative software-controlled actions permitted exact superimposition to allow precise evaluation of the matched root canals (19). The preparation of root canals was described earlier in detail (16–18). Briefly, the root canals in each experimental group were treated by using the following NiTi instruments: FlexMaster, GT Rotary, Lightspeed, ProFile, or ProTaper instruments for automated rotary preparation or NiTi K-files for hand instrumentation. All root canals were preflared by using Gates-Glidden burs in descending sizes. Preparation with FlexMaster, GT Rotary, and ProFile instruments was performed in a crown-down fashion. Preparation with Lightspeed and ProTaper instruments was done according to the manufacturers' instructions that were available for these types of instruments. NiTi K-files were used in balanced-force motion and stepped back to size #80 after apical preparation. Apical preparation size was #40 in mesiobuccal and distobuccal and #45 in palatal canals with FlexMaster, Lightspeed, ProFile, and NiTi K-file instruments. Instrumentation with GT Rotary resulted in apical size #20 .06 in mesiobuccal and distobuccal and #20 .08 or #20 .10 in palatal canals. Preparation with ProTaper enlarged the apical root canals to size #25 .08 (F2) in mesiobuccal and distobuccal and #30 .09 (F3) in palatal canals.

In a first step, the earlier collected data for overall volume of the root canals before preparation were statistically compared with each other to exclude any differences between groups. Evaluation of the matched root canals in this study then focused on the apical 4 mm. Increases in volume were calculated by subtracting the scores for the treated canals from those recorded for the untreated counterparts. Matched images of the surface areas of the canals before and after preparation were examined to evaluate the amount of uninstrumented area. This parameter was expressed as a percentage of the number of static voxel surface to the total number of surface voxels. The cross-sectional appearance, round or more ribbon-shaped, was expressed as the structure model index (SMI). This stereologic index varies from 1 (parallel plates) to 4 (perfect ball) and was described earlier in more detail (19). Data for canal volume increase and untreated surface are expressed as means and standard deviations (SDs). Outliers were defined as values that are beyond  $\pm 2$  SDs from the mean (20); statistical comparisons were done with and without these outliers ( $n = 11$ ). There was 1 canal with a retained instrument fragment, which was also excluded from this study. Because normality assumptions were warranted, means were compared by using one-way and two-way analyses of variance (ANOVAs) with Scheffé tests for post hoc comparison.

## Results

There were no differences in preoperative apical canal volumes among experimental groups ( $P > .05$ ). Distobuccal ( $0.29 \pm 0.22 \text{ mm}^3$ ) root canals had the smallest volumes compared with mesio-buccal ( $0.53 \pm 0.32 \text{ mm}^3$ ) and palatal ( $0.69 \pm 0.34 \text{ mm}^3$ ) canals. Canal shape, as indicated by an SMI of  $2.94 \pm 0.31$ , was more ribbon-shaped in the apical 4 mm of mesiobuccal canals than in distobuccal ( $3.1 \pm 0.43$ ) and palatal ( $3.08 \pm 0.46$ ) canals, but these differences were not statistically significant. There were no differences when these calculations were made with and without outliers.

After canal preparation, mean mesiobuccal, distobuccal, and palatal canal volumes increased similarly ( $P < .05$ ) overall, but differences were noted for preparation techniques (Table 1). Preparation with GT Rotary instruments rendered the smallest apical canal volume increase with  $0.20 \text{ mm}^3$ , whereas preparation with K-file and ProFile showed the largest volume increases, with  $0.51 \text{ mm}^3$  and  $0.45 \text{ mm}^3$ , respectively. These differences were statistically significant (Table 1). Regarding different canal types, mesiobuccal and palatal canals were on average enlarged more than palatal canals. A different pattern resulted from ProTaper preparation; this instrument led to more enlargement in palatal canals than the other 5 systems (Table 1).

Overall, apical canal sections were rounder in cross sections after preparation, except after FlexMaster preparation. Mesiobuccal and to a lesser degree distobuccal canals increased in the degree of cross-sectional roundness more than palatal canals (Table 1).

Untreated canal areas for individual canals ranged from 4%–100% and were overall larger in mesiobuccal and palatal canals than in distobuccal ones. Preparation with GT left significantly larger untreated areas compared with the other techniques ( $P < .01$ , Figure 1).

In a two-way ANOVA, both the instrument used ( $P < .001$ ) and the canal ( $P < .004$ ) were significant explanatory variables for the amount of untreated area. Again, GT preparation left more untreated area ( $P < .01$ ); distobuccal canals had less untreated areas compared with mesiobuccal and palatal canals ( $P < .01$ ). A recalculation combining data from earlier studies resulted in statistically similar areas of untreated surfaces if the full canal lengths were compared (Fig. 1).

## Discussion

The main aim of this article was to extend and combine findings on the basis of MCT reconstructions, specifically assessing changes in geometry in the apical-most sections by different instruments used in recommended sequences. Although there were subtle differences in apical volumes after preparation, the amounts of apical untreated surface were significantly higher after GT preparation to an apical size #20 compared with the other 5 techniques used.

Three of the 6 instrument systems used in the current study have undergone some design changes during the last years; GT changed into GTX (Dentsply Tulsa Dental), Lightspeed into Lightspeed LSX, and ProTaper into ProTaper Universal. We would not expect significant differences for the outcome of this study when using these newly designed instruments, because desired overall canal shapes following manufacturers' guidelines are expected to be similar. Moreover, the sparse available information directly comparing these instruments suggests similar shaping potential (14).

The basis for the data presented here was a series of 3 studies (16–18) with identical methodology based on MCT. This allowed a larger number of teeth ( $n = 60$ ) to be compared in one study. However, the number of specimens was still comparably low, and hence we found relatively large SDs. Moreover, for the outcome variables, relative data with

**TABLE 1.** Changes in Canal Volume and SMI Comparing Preoperative and Postoperative Reconstructed Canal Models in the Apical 4 mm (n = 168)

	FlexMaster (N = 25)	GT (N = 30)	Lightspeed (N = 30)	Hand (N = 30)	Profile (N = 30)	ProTaper (N = 23)
ΔVolume (mm <sup>3</sup> )	0.33 ± 0.12	0.20 ± 0.14 <sup>a,b</sup>	0.39 ± 0.24	0.51 ± 0.20 <sup>a</sup>	0.45 ± 0.21 <sup>b</sup>	0.31 ± 0.35
Roots	<i>P</i> < db ≤ mb	<i>P</i> < mb ≤ db	<i>P</i> ≤ mb < db	<i>P</i> < db ≤ mb	<i>P</i> < mb < db	mb ≤ db < <i>P</i>
ΔSMI	0.02 ± 0.22 <sup>c</sup>	0.21 ± 0.37	0.37 ± 0.35	0.35 ± 0.54	0.46 ± 0.38 <sup>c</sup>	0.31 ± 0.25
Roots	mb ≤ <i>P</i> < db	mb ≤ db < <i>P</i>	mb < db < <i>P</i>	mb < db < <i>P</i>	db < <i>P</i> < mb	db ≤ mb < <i>P</i>

Significantly different values are denoted by the same superscript letter (*P* < .01). Ranking of values when data were split into canal types is also indicated. db, distobuccal; mb, mesiobuccal.

preoperative canal geometry as control were reported whenever possible.

Before inclusion in the present study, preoperative root canal volumes had been analyzed and were found to be statistically similar among the groups. In addition, the recalculation addressed specifically the apical-most canal sections; the rationale for this was that disinfection by mechanical and chemical means in this area is considered most predictive for successful endodontic therapy. In fact, microorganisms remaining in apical canal sections are considered the main cause for failing endodontic treatments (21). However, the question as to which size a root canal should be prepared is still unsolved. With respect to the root canal anatomy in human maxillary molars, the palatal canal of each tooth in the current study was prepared to bigger sizes than the buccal canals. Ideally, an apical size would be determined specifically for each individual canal, but such a procedure would not permit any statistical analysis within the framework of the current experiment.

MCT studies are limited by the resolution of the hardware used (39.2 and 34 μm), which sets, for example, the detection limit in this data set regarding untreated surface area. Assuming the canal models before and after instrumentation were perfectly superimposed as shown earlier (19), enlargement by more than 1 voxel has to occur for any change in surface area to be apparent. However, penetration of microorganisms into dentinal tubules to a depth of 80–150 μm has been well-documented (21, 22), and hence dentin removal of more than the detection limit might be considered desirable for optimized canal disinfection.

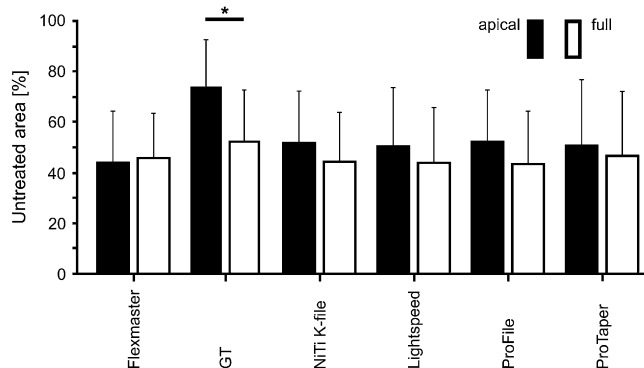
The parameter volume difference has been assessed previously by using MCT. Volume increases for full canal lengths were uniformly demonstrated in our earlier and other experiments (23, 24); the present results are in accordance with these findings. The SMI has

been used in our earlier studies (16–18); in contrast to the present study, significant increases in cross-section roundness were seen specifically for the full lengths of mesiobuccal canals. One explanation for this difference is a rounder cross section in unprepared apical root canal thirds. Data from histologic cross sections (10, 25, 26) might be compared with the parameter unprepared canal surface area. Data from both methods suggest that although complete mechanical canal preparation (ie, 100% prepared surface) might not be attainable, the amount of prepared surface depends on apical canal size.

Root canal disinfection is critical for endodontic outcomes (1) and is provided by a combination of mechanical preparation and irrigation. Both elements depend on canal enlargement, but there is disagreement about the needed degree of enlargement. For example, McGurkin-Smith et al (12) found inferior canal disinfection for canal preparation with GT rotaries to an apical size #20 compared with earlier studies by the same group (27). However, other authors found that apical sizes #20 with taper .10 but not #20 .06 were sufficiently promoting canal debridement (28), and that canal taper was positively correlated with debris removal by using ultrasonically activated irrigation (29). Moreover, current recommendations for the GT system, now available as GTX, include the use of rotaries in apical sizes #30 and #40 whenever preoperative canal anatomy permits. This is in line with our observations indicating limited canal wall preparation with an apical size #20. Rotary instruments with a restricted selection of apical sizes might be complemented with K-files or other instruments in a hybrid technique to more adequately address various apical canal geometries.

Antibacterial efficacy was not directly determined in the present study. Because mechanical preparation might affect bacterial biofilms (30) more than microorganisms in their planktonic state, it seems desirable to quantify the amount of removed biofilm by using MCT. With further improvement in hardware and software, such analyses might be feasible in the near future.

In conclusion, apical canal geometry was affected differently by 6 preparation techniques. Preparations with GT instruments to an apical size #20 left more canal surface untouched, which might affect the ability to disinfect root canals in maxillary molars.



**Figure 1.** Bar charts (means ± SDs) of untreated canal areas for the apical 4 mm (filled bars) and overall canals (empty bars). There were significant differences among techniques in the apical section, with GT leaving significantly more untreated area compared with all other techniques (*P* < .05). There were no significant differences when comparing the techniques for the full canal length. Data for full canal length are recalculated from references 16–18.

## References

- Haapasalo M, Endal U, Zandi H, Coil JM. Eradication of endodontic infection by instrumentation and irrigation solutions. *Endod Topics* 2005;10:77–102.
- Ram Z. Effectiveness of root canal irrigation. *Oral Surg Oral Med Oral Pathol* 1977; 44:306–12.
- Chow TW. Mechanical effectiveness of root canal irrigation. *J Endod* 1983;9:475–9.
- Hsieh YD, Gau CH, Kung Wu SF, Shen EC, Hsu PW, Fy E. Dynamic recording of irrigation fluid distribution in root canals using thermal image analysis. *Int Endod J* 2007;40:11–7.
- Hülsmann M, Peters OA, Dummer PMH. Mechanical preparation of root canals: shaping goals, techniques and means. *Endod Topics* 2005;10:30–76.
- Peters OA. Current challenges and concepts in the preparation of root canal systems: a review. *J Endod* 2004;30:559–97.
- Weine FS. *Endodontic therapy*. 4th ed. St Louis, MO: C V Mosby; 1989.
- Baugh D, Wallace J. The role of apical instrumentation in root canal treatment: a review of the literature. *J Endod* 2005;31:333–40.

9. Wu M-K, Barkis D, Roris A, Wesselink PR. Does the first file to bind correspond to the diameter of the canal in the apical region. *Int Endod J* 2002;35:264–7.
10. Tan BT, Messer HH. The quality of apical canal preparation using hand and rotary instruments with specific criteria for enlargement based on initial apical file size. *J Endod* 2002;28:658–64.
11. Coldero LG, McHugh S, MacKenzie D, Saunders WP. Reduction in intracanal bacteria during root canal preparation with and without apical enlargement. *Int Endod J* 2002;35:437–46.
12. McGurkin-Smith R, Trope M, Caplan D, Sigurdsson A. Reduction of intracanal bacteria using GT rotary instrumentation, 5.25% NaOCl, EDTA, and Ca(OH)<sub>2</sub>. *J Endod* 2005;31:359–63.
13. Allison DA, Weber CR, Walton RE. The influence of the method of canal preparation on the quality of apical and coronal obturation. *J Endod* 1979;5:298–304.
14. Iqbal MK, Banfield B, Lavorini A, Bachstein B. A comparison of LightSpeed LS1 and LightSpeed LSX root canal instruments in apical transportation and length control in simulated root canals. *J Endod* 2007;33:268–71.
15. Bramante CM, Berbert A, Borges RP. A methodology for evaluation of root canal instrumentation. *J Endod* 1987;13:243–5.
16. Peters OA, Schönenberger K, Laib A. Effects of four NiTi preparation techniques on root canal geometry assessed by micro computed tomography. *Int Endod J* 2001;34:221–30.
17. Hübscher W, Barbakow F, Peters OA. Root canal preparation with FlexMaster: canal shapes analysed by micro-computed tomography. *Int Endod J* 2003;36:740–7.
18. Peters OA, Peters CI, Schönenberger K, Barbakow F. ProTaper rotary root canal preparation: effects of canal anatomy on final shape analysed by micro CT. *Int Endod J* 2003;36:86–92.
19. Peters OA, Laib A, Rueggegger P, Barbakow F. Three-dimensional analysis of root canal geometry by high-resolution computed tomography. *J Dent Res* 2000;79:1405–9.
20. Taylor JR. An introduction to error analysis. Sausalito, CA: University Science Books; 1997.
21. Nair PN. On the causes of persistent apical periodontitis: a review. *Int Endod J* 2006;39:249–81.
22. Sen BH, Piskin B, Demirci T. Observation of bacteria and fungi in infected root canals and dentinal tubules by SEM. *Dent Traumatol* 1995;11:6–9.
23. Rhodes JS, Ford TR, Lynch JA, Liepins PJ, Curtis RV. Micro-computed tomography: a new tool for experimental endodontology. *Int Endod J* 1999;32:165–70.
24. Bergmans L, Van Cleynbreugel J, Beullens M, Wevers M, Van Meerbeek B, Lambrechts P. Smooth flexible versus active tapered shaft design using NiTi rotary instruments. *Int Endod J* 2002;35:820–8.
25. Tucker DM, Wenckus CS, Bentkover SK. Canal wall planning by engine-driven nickel-titanium instruments, compared with stainless-steel hand instrumentation. *J Endod* 1997;23:170–3.
26. Wu M-K, Wesselink PR. A primary observation on the preparation and obturation of oval canals. *Int Endod J* 2001;34:137–41.
27. Card SJ, Sigurdsson A, Ørstavik D, Trope M. The effectiveness of increased apical enlargement in reducing intracanal bacteria. *J Endod* 2002;28:779–83.
28. Albrecht L, Baumgartner J, Marshall J. Evaluation of apical debris removal using various sizes and tapers of ProFile GT files. *J Endod* 2004;30:425–8.
29. v.d. Sluis LW, Wu M-K, Wesselink PR. The efficacy of ultrasonic irrigation to remove artificially placed dentine debris from human root canals prepared using instruments of varying taper. *Int Endod J* 2005;38:764–8.
30. Burleson A, Nusstein J, Reader A, Beck M. The in vivo evaluation of hand/rotary/ultrasound instrumentation in necrotic, human mandibular molars. *J Endod* 2007;33:782–7.