
REVIEW

Complications during root canal irrigation – literature review and case reports

M. Hülsmann & W. Hahn

Department of Operative Dentistry, University of Göttingen, Göttingen, Germany

Abstract

Hülsmann M, Hahn W. Complications during root canal irrigation – literature review and case reports. *International Endodontic Journal*, **33**, 186–193, 2000.

Literature review and case reports The literature concerning the aetiology, symptomatology and therapy of complications during root canal irrigation is reviewed. Three cases of inadvertent injection

of sodium hypochlorite and hydrogen peroxide beyond the root apex are presented. Clinical symptoms are discussed, as well as preventive and therapeutic considerations.

Keywords: emphysema, haemorrhage, hydrogen peroxide, irrigation complications, root canal irrigation, sodium hypochlorite.

Received 6 May 1999; accepted 8 July 1999

Introduction

Root canal irrigation plays an important role in the debridement and disinfection of the root canal system and is an integral part of root canal preparation procedures. The most frequently used irrigants are sodium hypochlorite and hydrogen peroxide, or the combined use of both (Grossman 1981). Their benefits, good tissue dissolving and disinfecting capability, have been demonstrated in several investigations (Senia *et al.* 1975, Zielke *et al.* 1976, Byström & Sundqvist 1981, 1983, 1985, Ørstavik & Haapasalo 1990, Jeansonne & White 1994, Heling & Chandler 1998). The concentration of the irrigants is still a matter of debate and remains controversial; many authors recommend a 5.25% concentration of sodium hypochlorite (Harrison 1984), others prefer a lower concentration of 3% or even 0.5% (Spangberg *et al.* 1973, Baumgartner & Cuenin 1992). Hydrogen peroxide is used in a concentration of 3% (Grossman 1981, Harrison 1984).

Sodium hypochlorite has been demonstrated to be an effective agent against a broad spectrum of bacteria and to dissolve vital as well as necrotic tissue (Senia *et al.* 1975). However, it has been shown also that sodium hypochlorite has toxic effects on vital tissues, resulting

in haemolysis, skin ulceration and necrosis (Pashley *et al.* 1985). It has a pH of approximately 11–12 and causes injury primarily by oxidation of proteins.

In the dental literature several mishaps during root canal irrigation have been described, ranging from damage to the patient's clothing, splashing the irrigant into the patient's or operator's eye, to injection through the apical foramen, or air emphysema and allergic reactions to the irrigant.

Damage to clothing

Probably the most common incidents during root canal irrigation concern damage of the patients' clothing. As sodium hypochlorite is a common household bleaching agent, even small amounts may cause severe damage. When using an ultrasonic device for root canal irrigation the aerosol may also cause damage. These mishaps should be prevented by proper protection of the patients' clothing. When using hand irrigation, one should assure that the irrigation needle and syringe are securely attached and will not separate during transfer or irrigation in order to prevent leakage over clothing.

Damage to the eye

Irrigant in contact with the patient's or operator's eyes results in immediate pain, profuse watering, intense burning, and erythema. Loss of epithelial cells in the

Correspondence: PD Dr M. Hülsmann, Department of Operative Dentistry, University of Göttingen, Robert-Koch-Str. 40, D-37075 Göttingen (fax: +551 392037).

outer layer of the cornea may occur. Immediate ocular irrigation with large amounts of tap water or sterile saline should be performed by the dentist and the patient referred to an ophthalmologist for further examination and treatment (Ingram 1990).

Injection of sodium hypochlorite beyond the apical foramen

Inadvertent injection of sodium hypochlorite beyond the apical foramen may occur in teeth with wide apical foramina or when the apical constriction has been destroyed during root canal preparation or by resorption. Additionally, extreme pressure during irrigation or binding of the irrigation needle tip in the root canal with no release for the irrigant to leave the root canal coronally may result in contact of large volumes of the irrigant to the apical tissues. If this occurs, the excellent tissue-dissolving capability of sodium hypochlorite will lead to tissue necrosis.

Several case reports have described the symptomatology of sodium hypochlorite when injected into the periapical tissues. After wedging the irrigation needle in the root canal, 5.25% sodium hypochlorite was forced beyond the apex of a maxillary right cuspid which led to immediate strong reactions with extreme pain (Becker *et al.* 1974). Within a few seconds the patient's cheek and upper lip showed signs of haematoma and ecchymosis inferior to the right zygoma and profuse haemorrhage from the root canal. Wet compresses continuously applied to the face relieved the pain and the burning sensation felt by the patient. The patient was given antibiotics and analgesics, and the root canal was left open for drainage. Although the swelling increased during the next few hours, the pain had diminished. The patient was advised to replace the cold compresses by hot compresses to stimulate local systemic circulation. One month after the incident the patient's face had returned to normal and root canal therapy could be completed.

Following mandibular block anaesthesia with 5.25% NaOCl solution Herrmann & Heicht (1979) reported that immediate severe pain, oedema and trismus developed. The oedema involved the pterygomandibular space and the peritonsillar and pharyngeal areas with the risk of obstruction of the airway. The patient had to be given an opioid analgesic intravenously for pain reduction and was admitted to an intensive care unit of a hospital. Additionally, the patient was set on an antibiotic regimen. Following hospitalization for 4 days, most of the swelling had resolved and after 2 weeks all complications had resolved completely.

After iatrogenic perforation of the root canal of a lateral

maxillary incisor, a 3% NaOCl solution was injected beyond the apex (Grob 1984). The patient experienced 'heavy' spontaneous pain followed by a rapid swelling of the left cheek. Eight days later an abscess had developed, probably due to the spread of infected material from the root canal into the periapical tissue; this had to be treated surgically. Large amounts of pus and necrotic tissue were found. Four years later the patient still reported hyperaesthesia and extreme sensitivity to cold temperatures.

Reeh & Messer (1989) reported on a case of injection of sodium hypochlorite (1%) through a midroot perforation of a maxillary central incisor. The patient experienced the typical symptoms of immediate severe pain and swelling, followed by fistulation and erythema extending to the infraorbital area. Paraesthesia of the floor and ala of the patient's nose persisted for more than 15 months.

In a case report presented by Sabala & Powell (1989) 5.25% sodium hypochlorite was injected into the periapical tissues of a left maxillary second premolar. The patient experienced symptoms of sudden, severe pain and a swelling rapidly developed, followed by ecchymosis of the skin. Root canal treatment was completed at the same appointment. To prevent secondary infection, antibiotics were prescribed and a surgical drainage performed. Nine days later the symptoms had resolved.

Following injection of 5.25% NaOCl during endodontic treatment of a right maxillary central incisor, Gatot *et al.* (1991) reported that the patient immediately experienced severe pain and marked oedema developed extending from the lip to the right eye. The patient received hydrocortisone intravenously and penicillin. Thirty-six h later there was large ecchymosis under the right orbit and diffuse ecchymosis over the upper lip, as well as epithelial necrosis. Surgical debridement with excision of a large amount of necrotic tissue had to be performed under general anaesthesia. Healing took more than 2 weeks, leaving a scar on the right cheek and right infraorbital nerve anaesthesia.

Becking (1991) presented three cases of sodium hypochlorite injection into the periapical soft tissues. In the first case NaOCl of unknown concentration was extruded through the apical foramen of a mandibular left second molar with a perforation at the cemento-enamel junction, resulting in a progressive swelling of the left side of the mandible extending to the patient's neck. After 1 day necrosis of the mucosa and anaesthesia of the mental nerve was apparent. Under antibiotic and analgesic therapy, pain and swelling diminished after 5 days, paraesthesia of the nerve resolved after 10 days, healing of the mucosa took 2 months. In the second case NaOCl of unknown concentration was

Table 1a Symptomatology and therapy after inadvertent injection of NaOCl into the periapical tissues

Symptomatology

Immediate severe pain
 Immediate oedema of neighbouring soft tissues
 Possible extension of oedema over the injured half side of the face, upper lip, infraorbital region
 Profuse bleeding from the root canal
 Profuse interstitial bleeding with haemorrhage of the skin and mucosa (ecchymosis)
 Chlorine taste and irritation of the throat after injection into the maxillary sinus
 Secondary infection possible
 Reversible anaesthesia or paraesthesia possible

Table 1b Symptomatology and therapy after inadvertent injection of NaOCl into the periapical tissues

Therapy

Patient information on cause and severity of complication
 Pain control: local anaesthesia, analgesics
 In severe cases: referral to a hospital
 Extraoral cold compresses for reduction of swelling
 After 1 day: warm compresses and frequent warm mouthrinses for stimulation of local systemic circulation
 Daily recall for control of recovery
 Antibiotics: not obligatory. Only in cases of high risk or evidence of secondary infection
 Antihistamine: not obligatory
 Corticosteroids: controversial
 Further endodontic therapy with sterile saline or chlorhexidine as root canal irrigants

injected into the periapical tissues of a left maxillary second molar, causing irritation behind and below the patient's left eye and severe pain in the left cheek, eye, and temporal region. Additionally, the patient reported a chlorine taste and irritation of the throat. It was presumed that the irrigant had been pressed into the maxillary sinus. In this case no antibiotics were given, only analgesics; the symptoms resolved completely within 2 weeks. In the third case apical overextrusion of NaOCl occurred during root canal preparation of a mandibular left second premolar, resulting in severe pain, swelling, and anaesthesia of the mental nerve. Again, no antibiotics were prescribed initially. Four days later necrosis and infection became evident and antibiotic therapy was initiated. Resolution of pain and swelling took 1 month, anaesthesia changed into hyperaesthesia, which slowly resolved.

Following inadvertent injection of 5.25% NaOCl via the palatal root canal of a maxillary first molar into the maxillary sinus, Ehrich *et al.* (1993) reported that the patient only complained on a taste of sodium hypochlorite but no further symptoms developed. The root canal and the sinus were irrigated with sterile water through the palatal root canal. The water passed through the maxillary sinus into the nasal cavity and then into the pharynx. The patient was prescribed antibiotics and was asymptomatic 4 days later.

A similar case was presented by Kavanagh & Taylor

(1998). During endodontic treatment of a right second maxillary premolar, sodium hypochlorite of unknown concentration was injected beyond the apex. The patient experienced acute severe facial pain and swelling. Occipitomental radiographs demonstrated an air fluid level in the right maxillary sinus. The antrum was drained surgically under general anaesthesia. Three weeks later most of the symptoms had resolved and only the premolar presented with localized discomfort; this led to the decision to extract the tooth. Further healing was uneventful and complete.

Further cases with similar symptoms have been presented by Tronstad (1991), Joffe (1991), Torabinejad & Lemon (1996), and Hülsmann & Denden (1997).

The main symptoms and treatment considerations in cases of periapical sodium hypochlorite injection are summarized in Table 1 a,b.

Allergic reactions to NaOCl

Kaufman & Keila (1989) reported a case of hypersensitivity to sodium hypochlorite. As this reaction was detected before initiation of endodontic therapy, the patient was referred to an allergist. Following a skin patch test, the allergist diagnosed a hypersensitivity to household materials containing NaOCl and recommended not to use NaOCl during root canal treatment. Thus, the root canals were irrigated with Solvidont (DeTrey/Dentsply, Konstanz, Germany) and the procedure

was uneventful. In a second case (Caliskan *et al.* 1994) sodium hypochlorite (1%) was used for irrigation of a maxillary central incisor with midroot horizontal fracture. The patient immediately reported severe pain and a burning sensation, within a few s the upper lip and cheek up to the infraorbital area became swollen, accompanied by ecchymosis and profuse haemorrhage from the root canal. Pain diminished after a few min but the patient complained about problems in breathing and was referred to an emergency care unit. Systemic corticosteroid and antihistamine were administered intravenously and antibiotics were prescribed. Swelling resolved after 3 days, but a paraesthesia on the left side of the face remained for 10 days. Further endodontic therapy was performed with hydrogen peroxide and sterile saline and was uneventful. A skin scratch test was performed some days after the incident and gave a very rapid positive allergic reaction.

Injection of hydrogen peroxide beyond the apex

As a result of insufficient access and a lateral root perforation of a right maxillary central incisor, Bhat (1974) reported that hydrogen peroxide of unknown concentration was injected into the soft tissues. As treatment was performed under local anaesthesia, the patient experienced no pain but complained about a rapidly developing swelling on the upper lip and some difficulty in breathing. The canal was left open, the patient was prescribed antibiotics and instructed to apply cold packs. The emphysema, caused by oxygen liberated from the hydrogen peroxide, subsided in 1 week and root canal treatment was completed.

Walker (1975) presented a case of inadvertent extrusion of 40% hydrogen peroxide through the root canals of a maxillary first molar. A sudden swelling appeared accompanied by mild pain. Examination of the swelling revealed a mildly tender swelling with crepitus. It is probable that a previous infection of the periapical area had provided a pathway for the hydrogen peroxide through the buccal bone to the buccal and facial soft tissues. Under antibiotic therapy the symptoms resolved completely after a few days.

After extrusion of hydrogen peroxide (10%) beyond the apical foramen of a right first maxillary premolar Patterson & McLundie (1989) reported the typical symptoms of sudden, severe pain accompanied by a rapid swelling and erythema in the region of the treated tooth. The tooth was immediately extracted by the general dental practitioner and the patient prescribed antibiotics. Two days later the pain had resolved nearly completely, but oedema and erythema were still present. The patient was instructed to use warm mouthrinses for

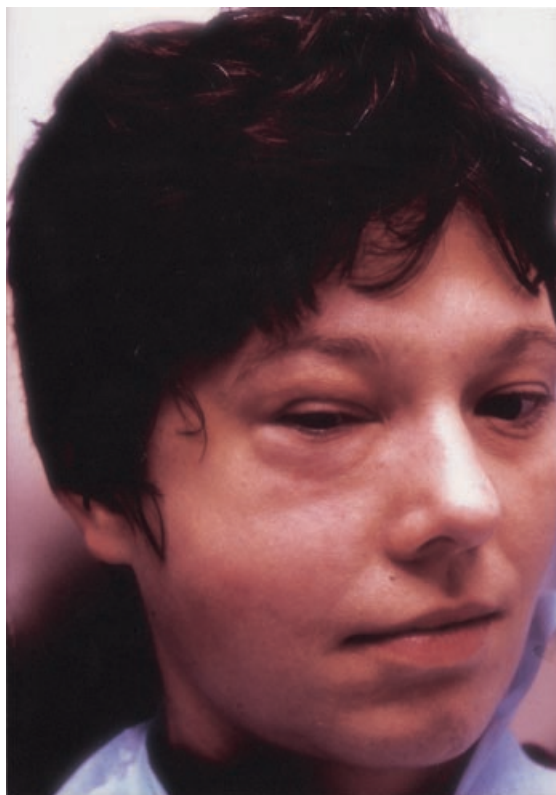

Figure 1 Massive swelling of the right face after air emphysema during root canal treatment of a right maxillary first molar (Case Professor C. Löst, Tübingen, with kind permission).

symptomatic relief and take further antibiotics. After 2 weeks the patient had returned to normal.

Seidner (1938), Pöllmann (1980), and Hülsmann & Denden (1997) presented similar cases of hydrogen peroxide injections into the periapical tissues with identical symptoms.

Air emphysema

Further accidents during endodontic therapy may occur when the root canal is dried with compressed air, which may be expressed through the apical constriction into the periapical tissues. Shovelton (1957) presented 13 cases that had signs of emphysema of the face, the suborbital region, and neck. The main symptom is a crepitus of the swelling. In most cases emphysema during root canal treatment does not require antibiotics or any other therapy; the emphysema in most cases resolves after few days (Figs 1, 2).

Additional reports on air emphysema during endodontic treatment have been published by Nehlsen (1927),



Figure 2 One month after the incident the patient's outlook has returned to normal. No therapy had been performed (Case Professor C. Löst, Tübingen, with kind permission).



Figure 3 Swelling and extraoral ecchymosis following inadvertent extrusion of sodium hypochlorite (3%) through the apical foramen of a maxillary left cuspid.

Berg (1928), Müller-Stade (1931), Salvas (1931), Seidner (1938), Langegger (1950), Glahn (1953), Magnin (1958), Harnisch (1976), Spaulding (1979), Arnold (1979), and Hülsmann & Denden (1997). In an animal study the possibility could not be completely excluded by Rickles & Joshi (1963), that air emphysema during root canal therapy was the reason for the death of four of seven dogs. Similar dramatic sequelae following air emphysema after root canal treatment have not been reported in man.

Case reports

Case 1

During root canal treatment of a left maxillary cuspid in a 55-year-old male patient 3%-sodium hypochlorite was forced through the apical foramen, which had been artificially widened due to incorrect determination of endodontic working length. The patient experienced a sudden acute pain attack in the left maxillary region

accompanied by an increasing oedema and ecchymosis of the left cheek (Fig. 3) and profuse bleeding from the root canal. The patient was given an infiltration anaesthesia, prescribed analgesics and was advised to use cold compresses; the root canal was left open for drainage. The following day the swelling had increased but pain had resolved nearly completely. Intraorally massive ecchymosis was observed (Fig. 4). One week later all symptoms had resolved without additional therapy and root canal treatment was continued.

Case 2

During endodontic treatment of a right mandibular cuspid the irrigation needle inadvertently was wedged through a perforation between the crown and the root and approximately 1 mL NaOCl (3%) and H₂O₂ (5%) were injected into the adjacent tissues. Within s the patient complained of an extremely severe, burning pain in his lower lip. Immediate massive swelling of the lower lip occurred (Fig. 5). The pain rapidly resolved but

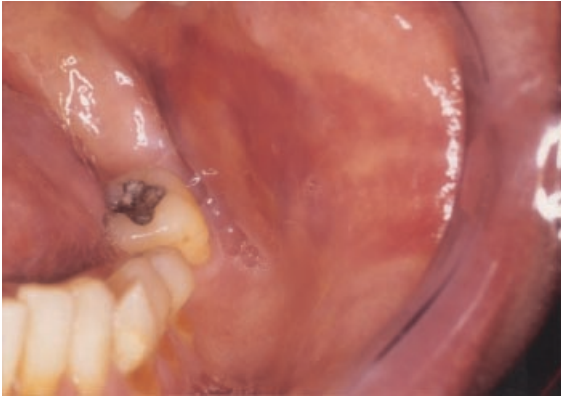

Figure 4 Large intraoral ecchymosis extending to the left cheek.

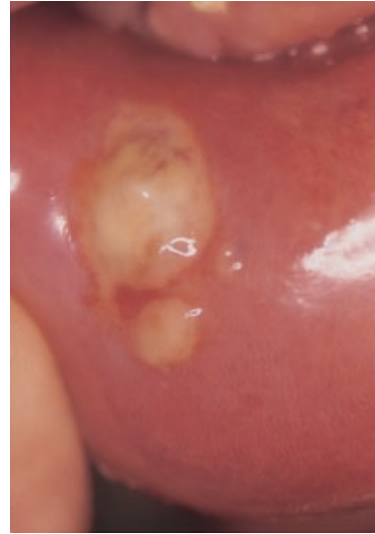


Figure 6 Three weeks after the incident an ulcer in the lower lip has developed.

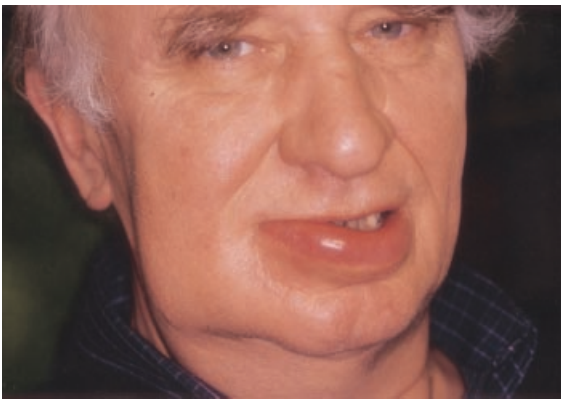


Figure 5 Massive swelling of the lower lip and right cheek region after injection of sodium hypochlorite and hydrogen peroxide through a perforation in a mandibular right cuspid.

the swelling persisted. Additionally, the patient felt a mild paraesthesia in a circumscribed region of the lower lip. One week after the incident an ulcer was observed in the lower lip (Fig. 6). Swelling persisted for 3 weeks and only resolved slowly, the ulcer healed with minor scar tissue formation after 2 months. More than 1 year later a mild paraesthesia of a circumscribed region of the the lip was still reported by the patient.

Case 3

During endodontic treatment of the right maxillary first bicuspid hydrogen peroxide (3%) was inadvertently extruded beyond the apex. The patient felt a sudden sharp pain and immediate swelling of the right side of the face occurred. Profuse watering of the right eye and pressure in the right side of the cheek were also reported by the patient (Fig. 7). The pain diminished after a few min and only a

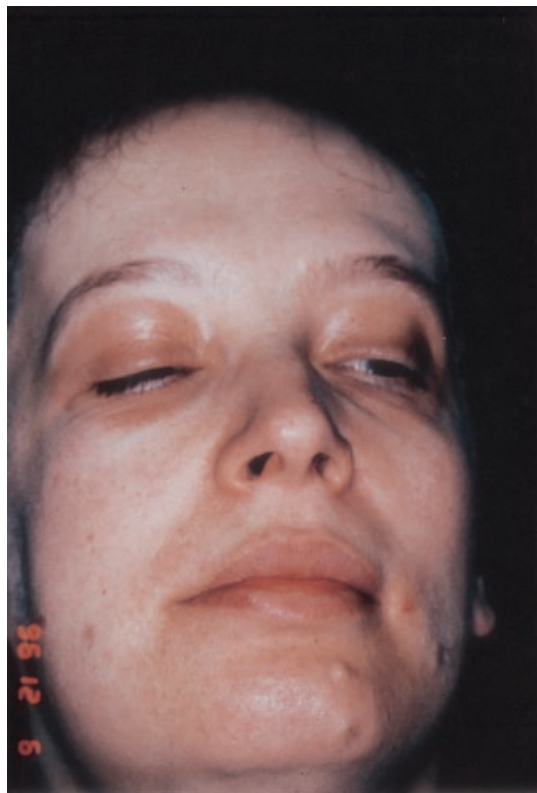

Figure 7 Swelling of the right cheek up to the infraorbital region after inadvertent injection of hydrogen peroxide through the apical foramen of a right maxillary first premolar. On careful palpation the swelling exhibited a crepitus, which is a typical symptom after air emphysema or soft tissue injection with hydrogen peroxide.

mild pressure in the cheek region was felt by the patient over the next 5 days. Palpation of the right cheek during this period produced the sign of crepitus. Healing occurred without any further medication and was uneventful.

Discussion

Although a number of different solutions have been proposed for root canal irrigation, sodium hypochlorite in various concentrations (0.5–5.25%) is the most frequently used irrigant (Grossman 1981, Harrison 1984). This is mainly due to its tissue-dissolving capacity as well as to its antibacterial properties. Hydrogen peroxide also has been widely used for irrigation of the root canal system, although it is less effective in killing microorganisms (Senia *et al.* 1975).

The endodontic literature contains several case reports on complications during root canal irrigation, including inadvertent injection of sodium hypochlorite or hydrogen peroxide into the periapical tissues, air emphysema, and allergic reactions to the solutions. Most of the cases occurred because of incorrect determination of endodontic working length, iatrogenic widening of the apical foramen, lateral perforation, or wedging of the irrigating needle. Clearly, precautions must be undertaken to prevent such mishaps. The patient's clothing should be protected effectively against the irrigant, as well as the patient's and operator's eyes. The irrigating needle has to be fixed to the syringe and must not be wedged into the root canal (Hülsmann 1997). During irrigation a low and constant pressure should be used and the operator must ensure that excess irrigant leaves the root canal coronally via the access cavity. However, it has been shown that contact between the periapical tissues and the irrigant cannot be avoided completely (VandeVisse & Brilliant 1975, Brown *et al.* 1975). Therefore, a dilute concentration of the irrigant that still retains adequate disinfective properties is recommended. In a concentration of 0.5%, NaOCl is nontoxic to vital tissues and immediately washed away by the circulating blood (Spangberg *et al.* 1973, Baumgartner 1992). On the other hand, Harrison *et al.* (1983) demonstrated that the use of 5.25% sodium hypochlorite alone or in combination with 3% hydrogen peroxide did not result in an increased incidence of interappointment pain.

In the reported cases of extrusion of irrigant the patient experienced a sharp, severe pain and a rapidly increasing swelling. The dentist should remain calm and assist the patient, who will inevitably become concerned about the dramatic sequelae. The dentist should

immediately inform the patient of the cause and nature of the incident. No standard therapy for further management of the complication has been described. Any intervention depends on the nature and severity of the incident. In many cases no intervention or only a minimal amount is necessary. To reduce the acute pain, local anaesthesia may be helpful along with the prescription of analgesics. Initially, the swelling should be treated by cold compresses. After 1 day these should be replaced by warm compresses and warm mouthrinses to stimulate local microcirculation. Antibiotics are recommended only in cases where there is a high risk of infection spread; they are not necessary in minor cases. The patient should be informed that healing will take some days, or even weeks, and that symptoms in most cases will resolve completely. When the acute symptoms have resolved or diminished, endodontic treatment may be completed. The use of a mild nonirritating irrigation solution (sterile saline, chlorhexidine gluconate) is recommended in such cases. In the majority of cases there is no need or indication for extraction or surgical treatment of the involved tooth.

References

- Arnold WH (1979) Die Wurzelkanalbehandlung als Kausalfaktor eines Emphysems. *Quintessenz* **30**, 46.
- Baumgartner JC, Cuenin PR (1992) Efficacy of several concentrations of sodium hypochlorite for root canal irrigation. *Journal of Endodontics* **18**, 605–12.
- Becker GL, Cohen S, Borer R (1974) The sequelae of accidentally injecting sodium hypochlorite beyond the root apex. *Oral Surgery, Oral Medicine and Oral Pathology* **38**, 633–8.
- Becking AG (1991) Complications in the use of sodium hypochlorite during endodontic treatment. Report of three cases. *Oral Surgery, Oral Medicine and Oral Pathology* **71**, 346–8.
- Berg A (1928) Emphysembildung im Anschluß an die Behandlung wurzelkranker Zähne. *Zeitschrift für Stomatologie* **26**, 904–16.
- Bhat KS (1974) Tissue emphysema caused by hydrogen peroxide. *Oral Surgery, Oral Medicine and Oral Pathology* **38**, 304–7.
- Brown DC, Moore BK, Brown CE, Newton CW (1975) An *in vitro* study of apical extrusion of sodium hypochlorite during endodontic canal preparation. *Journal of Endodontics* **21**, 587–91.
- Byström A, Sundqvist G (1981) Bacteriological evaluation of the efficacy of mechanical root canal instrumentation in endodontic therapy. *Scandinavian Journal of Dental Research* **89**, 321–8.
- Byström A, Sundqvist G (1983) Bacteriological evaluation of the effect of 0.5% sodium hypochlorite in endodontic therapy. *Oral Surgery, Oral Medicine and Oral Pathology* **55**, 307–12.
- Byström A, Sundqvist G (1985) The antibacterial action of sodium hypochlorite and EDTA in 60 cases of endodontic therapy. *International Endodontic Journal* **18**, 35–40.

- Çalışkan MK, Türkün M, Alper S (1994) Allergy to sodium hypochlorite during root canal therapy: a case report. *International Endodontic Journal* **27**, 163–7.
- Ehrich DG, Brian JD, Walker WA (1993) Sodium hypochlorite accident: inadvertent injection into the maxillary sinus. *Journal of Endodontics* **19**, 180–2.
- Gatot A, Arbelle J, Leibermann M, Yanai-Inbar I (1991) Effects of sodium hypochlorite on soft tissues after its inadvertent injection beyond the root apex. *Journal of Endodontics* **17**, 573–4.
- Glahn M (1953) Akutes Emphysem nach Einblasen von Luft durch den Wurzelkanal. *Deutsche Zahn-, Mund-, Kieferheilkunde* **18**, 252.
- Grob R (1984) Zwischenfall mit Natriumhypochlorit – nur mein Fehler? *Schweizer Monatsschrift für Zahnmedizin* **94**, 661–2.
- Grossman LI (1981) *Endodontic Practice*, 10th edn. Philadelphia, USA: Lea & Febiger.
- Harnisch H (1976) Lidemphysem bei zahnärztlicher Behandlung. *Zahnärztliche Welt/Reform* **27**, 501.
- Harrison JW (1984) Irrigation of the root canal system. *Dental Clinics of North America* **28**, 797–808.
- Harrison JW, Baumgartner JC, Cvec TA (1983) Incidence of pain associated with clinical factors during and after root canal therapy. Part I & II. *Journal of Endodontics* **9**, 384–7 & 434–8.
- Heling I, Chandler NP (1998) Antimicrobial effect of irrigant combinations within dentinal tubules. *International Endodontic Journal* **31**, 8–14.
- Herrmann JW, Heicht RC (1979) Complications in therapeutic use of sodium hypochlorite. *Journal of Endodontics* **5**, 160.
- Hülsmann M (1997) Die Wurzelkanalspülung – Ziele, Mittel und Techniken. *Endodontie* **6**, 47–62.
- Hülsmann M, Denden JM (1997) Iatrogene Zwischenfälle bei der Wurzelkanalspülung – Literaturübersicht und Falldarstellung. *Endodontie* **6**, 191–205.
- Ingram TA (1990) Response of the human eye to accidental exposure to sodium hypochlorite. *Journal of Endodontics* **16**, 235–7.
- Jeansonne MJ, White RR (1994) A comparison of 2.0% chlorhexidine gluconate and 5.25% sodium hypochlorite as antimicrobial endodontic irrigants. *Journal of Endodontics* **20**, 276–8.
- Joffe E (1991) Complications during root canal therapy following accidental extrusion of sodium hypochlorite through the apical foramen. *General Dentistry* **39**, 460.
- Kaufman AY, Keila S (1989) Hypersensitivity to sodium hypochlorite. *Journal of Endodontics* **5**, 224–6.
- Kavanagh CP, Taylor J (1998) Inadvertent injection of sodium hypochlorite into the maxillary sinus. *British Dental Journal* **185**, 336–7.
- Langegger PA (1950) Emphysem bei der Zahnbehandlung. *Zeitschrift für Stomatologie* **47**, 133–6.
- Magnin J (1958) Oedeme palpebral apres insufflation d'air dans le canal d'une incisive centrale superieure. *Schweizer Monatsschrift für Zahnheilkunde* **68**, 437.
- Müller-Stade P (1931) Ausgedehntes Hautemphysem nach Einblasen von Luft in einen Zahnwurzelkanal. *Zeitschrift für Stomatologie* **29**, 880–2.
- Nehlsen B (1927) Ein anderer Fall von Emphysem der Wange bei einer Wurzelkanalbehandlung. *Zahnärztliche Rundschau* **36**, 21–2.
- Ørstavik D, Haapasalo M (1990) Disinfection by endodontic irrigants and dressings of experimentally infected dentinal tubules. *Endodontics and Dental Traumatology* **6**, 142–9.
- Pashley EL, Birdsong NL, Bowman K, Pashley DH (1985) Cytotoxic effects of NaOCl on vital tissue. *Journal of Endodontics* **11**, 525–8.
- Patterson CJ, McLundie AC (1989) Apical penetration by a root canal irrigant: a case report. *International Endodontic Journal* **22**, 197–9.
- Pöllmann L (1980) Emphysem nach Wurzelkanalbehandlung. *Deutsche Zahnärztliche Zeitschrift* **35**, 835.
- Reeh ES, Messer HH (1989) Long-term paresthesia following inadvertent forcing of sodium hypochlorite through perforation in maxillary incisor. *Endodontics and Dental Traumatology* **5**, 200–3.
- Rickles H, Joshi BA (1963) Death from air embolism during root canal therapy. *Journal of the American Dental Association* **67**, 397–404.
- Sabala GL, Powell SE (1989) Sodium hypochlorite injection into periapical tissues. *Journal of Endodontics* **15**, 490–2.
- Salvas C (1931) A case of emphysema. *Dental Cosmos* **73**, 307.
- Seidner S (1938) Durch H₂O₂ hervorgerufenes Emphysem der Gesichtshaut. *Zeitschrift für Stomatologie* **36**, 204–5.
- Senia ES, Marraro RV, Mitchell JL (1975) Rapid sterilization of gutta-percha cones with 5.25 per cent sodium hypochlorite and hydrogen peroxide versus normal saline solution. *Journal of Endodontics* **1**, 136–40.
- Shovelton DS (1957) Surgical emphysema as a complication of dental operations. *British Dental Journal* **102**, 125–9.
- Spangberg L, Engström B, Langeland K (1973) Biologic effects of dental materials. III. Toxicity and antimicrobial effect of endodontic antiseptics in vitro. *Oral Surgery, Oral Medicine and Oral Pathology* **36**, 856–71.
- Spaulding CR (1979) Soft tissue emphysema. *Journal of the American Dental Association* **98**, 587–8.
- Torabinejad M, Lemon R (1996) Procedural accidents. In: Walton RE, Torabinejad M, eds. *Principles and Practice of Endodontics*, 2nd edn. Philadelphia, USA: W. Saunders.
- Tronstad L (1991) *Clinical Endodontics*. Stuttgart, Germany: Thieme, 210.
- VandeVisse JE, Brilliant JD (1975) Effect of irrigation on the production of extruded material at the root apex during instrumentation. *Journal of Endodontics* **1**, 243–6.
- Walker JE (1975) Emphysema of soft tissues complicating endodontic treatment using hydrogen peroxide: a case report. *British Journal of Oral Surgery* **13**, 98–9.
- Zielke DR, Hegggers JP, Harrison JW (1976) A statistical analysis of anaerobic versus aerobic culturing in endodontic therapy. *Oral Surgery, Oral Medicine and Oral Pathology* **42**, 830–7.