

Endo Restorative – The Coronal Seal

Dr. Liviu Steier and Dr. Winfried Zeppenfeld, Germany

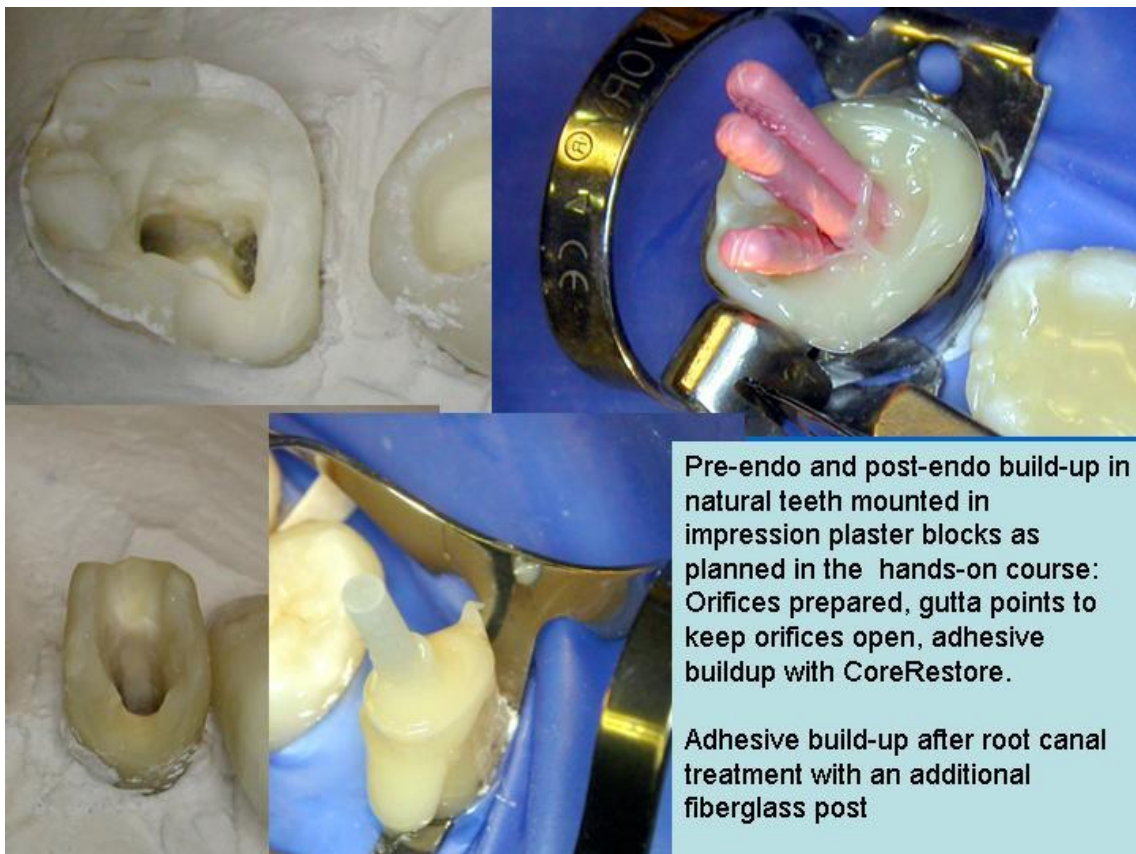
Hands on:

1. Buildup of subgingivally destroyed teeth before endo and transferring the canal orifice to the occlusal surface to allow proper endo treatment .
2. Adhesive buildup including adhesive sealing of canal orifices and placing fiberglass posts in endodontically treated teeth

We will prepare extracted teeth for all participants (max 30, 15pre and 15 postendo build-ups))

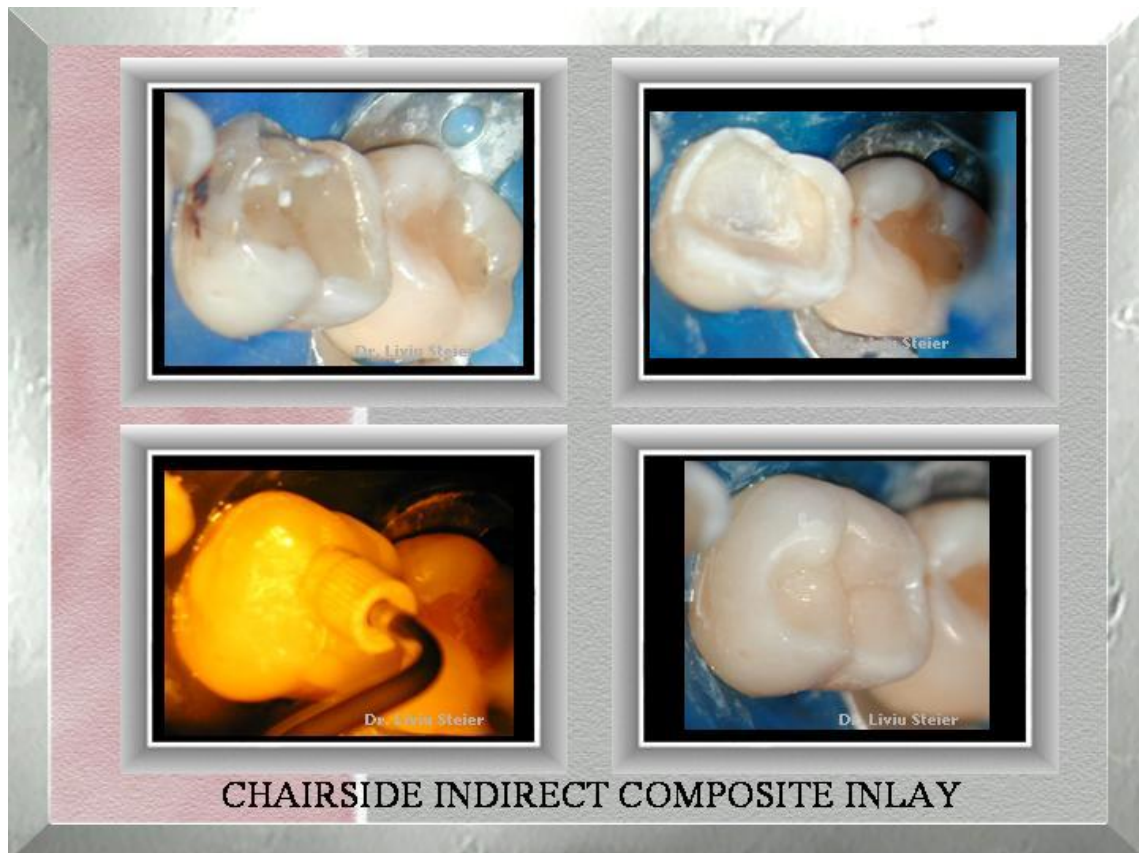
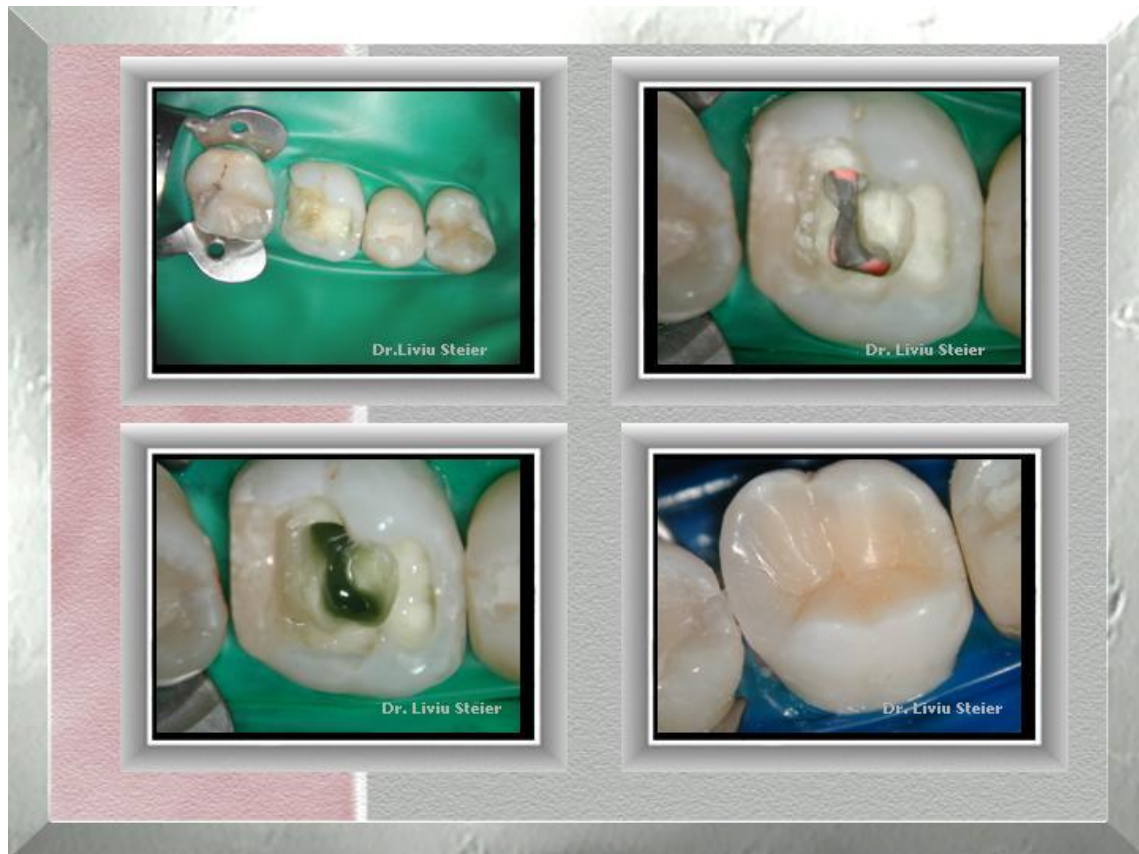A few basic instruments will have to be brought by participants (list will follow)

Restoration materials will be supplied by Kerr

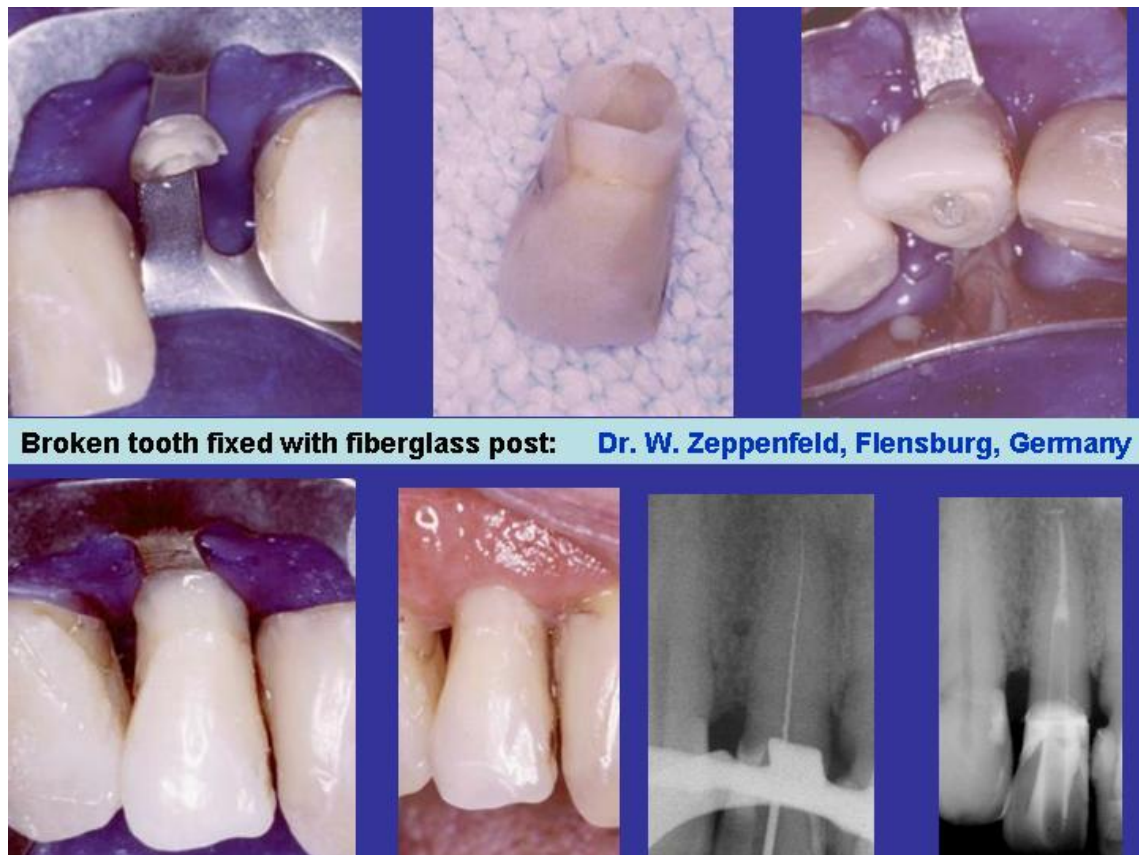
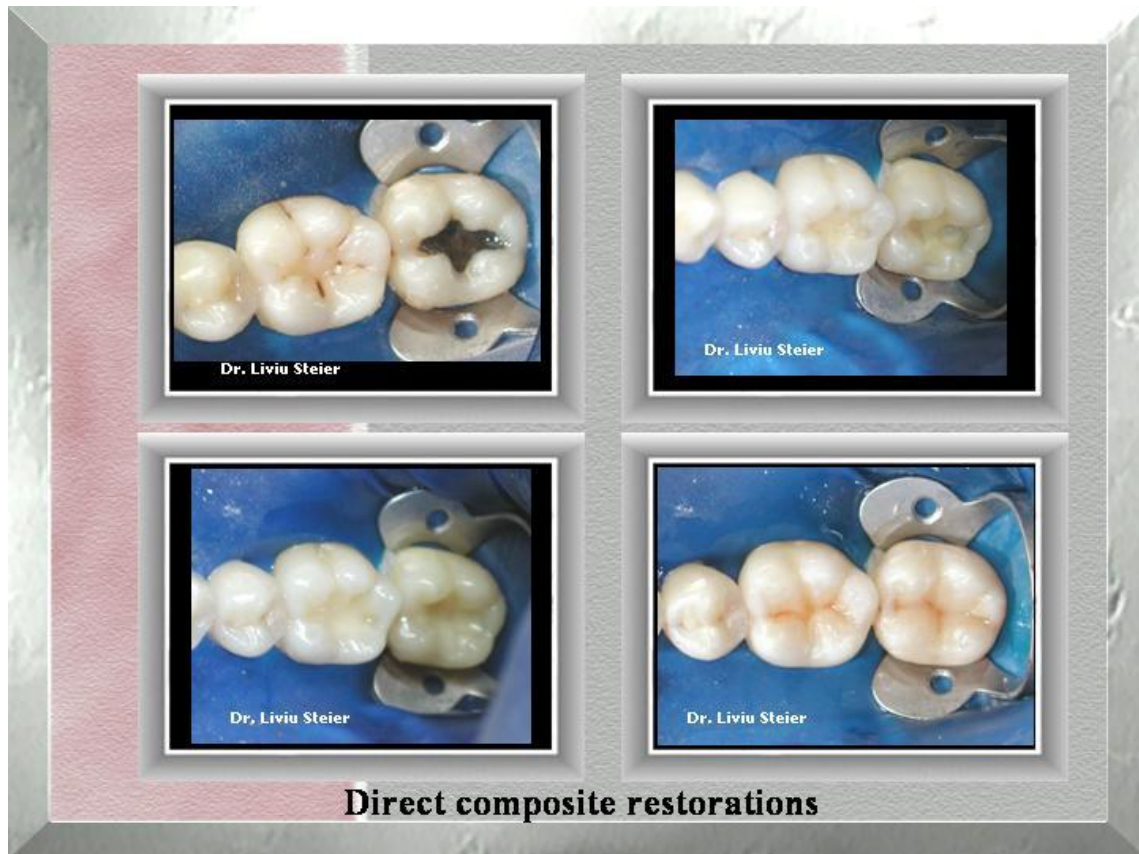
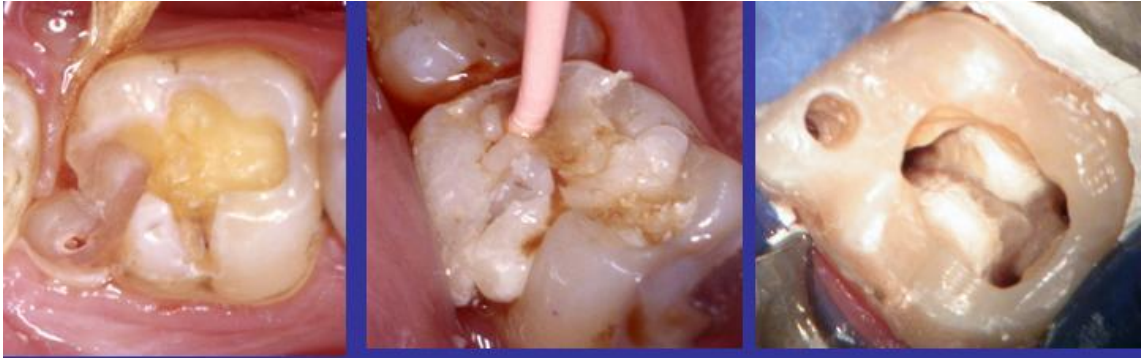Demonstrations (for the GPs, if desired): anterior (modified Vanini's technique) and posterior composites.

Discussion: How can I avoid postoperative sensitivity, open interproximal contacts and open margins?



CHAIRSIDE INDIRECT COMPOSITE INLAY

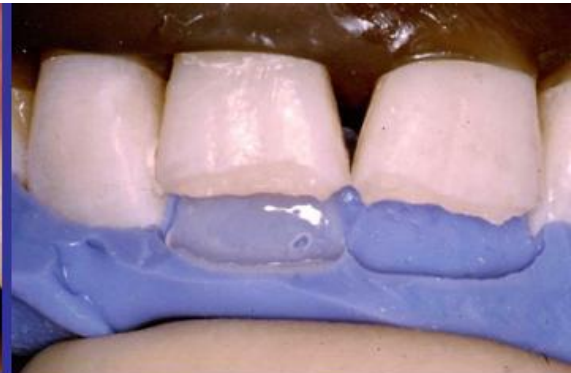
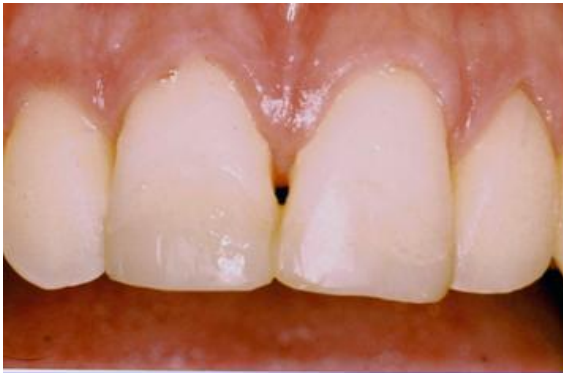
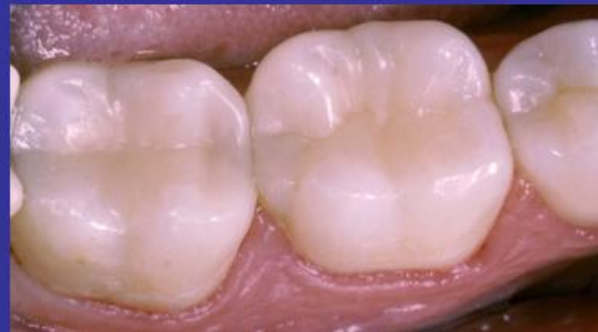
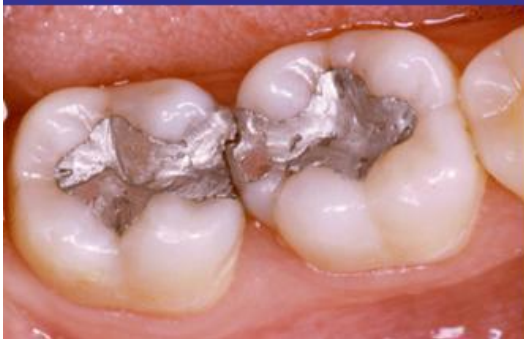
Buildup of tooth #31 before endo

Dr. W. Zeppenfeld, Flensburg, Germany

Posterior composite 3 years postop



Anterior restoration with Vanini's technique:

Dr. W. Zeppenfeld, Flensburg, Germany

