

# Avulsions and Intrusions: The Controversial Displacement Injuries

- David J. Kenny, BSc, DDS, PhD •
- Edward J. Barrett, BSc, DDS, MSc •
- Michael J. Casas, DDS, MSc •

## A b s t r a c t

*Avulsions and intrusions are the most complicated and controversial displacement injuries of permanent teeth. Clinical guidelines published by authorities such as the American Association of Endodontists, the Royal College of Surgeons of England and the International Association of Dental Traumatology are inconsistent. While a certain amount of inconsistency might be expected, some of these guidelines recommend treatments that are experimental or have not incorporated research information from the past 5 years, and in one case the guidelines incorrectly describe the nature of Hank's balanced salt solution. Recent laboratory studies support previous clinical outcome studies in emphasizing that only for teeth replanted within 5 minutes of avulsion is there a chance of regeneration of the periodontal ligament and normal function. Teeth replanted beyond 5 minutes will take another path, that of repair followed by root resorption, ankylosis and eventual extraction. Dentists should explain these outcomes at the time of the replantation decision. Severe intrusions also have predictable outcomes. Teeth intruded beyond 6 mm cannot regenerate a functional periodontal ligament and so are prone to root resorption and eventual extraction as well. In this situation the decision is one of immediate extraction or repositioning, with the understanding that it is inevitable that the tooth will eventually be extracted. Authoritative clinical guidelines available on the Internet provide the clinician with useful outlines for treatment. However, individual inconsistencies stimulate academic controversies and, in some cases, clinical misdirection.*

**MeSH Key Words:** *incisor/injuries; root resorption/prevention & control; tooth avulsion/therapy*

© J Can Dent Assoc 2003; 69(5):308-13  
This article has been peer reviewed.

**A**vulsions and severe intrusions are associated with poor post-treatment outcomes. Management of both avulsions and intrusions is controversial: avulsions present the dilemma of whether or not to replant, whereas intrusions have the widest choice of treatment options. Every trauma intervention should be guided by application of the best scientific evidence integrated with the clinician's expertise and the values and expectations of patients and their parents. Yet dentists may be "rusty" in both clinical techniques and application of research-based information, primarily because of the rarity of such events. Clinical guidelines should incorporate the best research evidence and techniques, as well as the means to explore the expectations of patients and their parents. This review of recent research and the changing management of avulsions and intrusions identifies the controversies and clarifies clinical options.

## Avulsions

### Guidelines

Guidelines for replantation have been published by a number of organizations such as the American Association of Endodontists (AAE),<sup>1</sup> the Royal College of Surgeons of England (RCSE)<sup>2</sup> and the International Association of Dental Traumatology (IADT).<sup>3</sup> Although there are similarities among them, it is obvious that personal opinion, anecdotal information and caprice are woven into these documents.<sup>4</sup> For example, the guidelines for the management of avulsions have not addressed outcomes, the "drive for normalcy" that produces requests for replantation of teeth for which the prognosis is hopeless, the orthodontic implications of replantation into mouths with associated malocclusions and, finally, the direct and indirect costs of the replantation decision.<sup>1-3</sup> The guidelines just described

are “trailing edge” documents that at best provide consensus interpretation of research evidence published more than 5 years ago. Nevertheless, such guidelines may reduce the number of inappropriate or cavalier treatments of trauma.<sup>5</sup> The advent of computer-assisted training packages provides yet another means of disseminating consensus-based treatment methods.<sup>6</sup> The AAE,<sup>1</sup> RCSE<sup>2</sup> and IADT<sup>3</sup> guidelines are also available online.

### Extra-alveolar Time

Despite evidence that immediate replantation (i.e., within 5 minutes) is required for regeneration of the periodontal ligament (PDL) and its return to normal function,<sup>7</sup> more than three-quarters of school teachers, coaches and caregivers would be reluctant to replant teeth if the circumstance arose.<sup>8,9</sup> The reasons for this reluctance reportedly included inadequate training, reluctance to induce pain or fear in the child, personal fear of bloodborne infection, fear of replacing the tooth incorrectly and fear of possible legal consequences.<sup>9</sup> Recently, attention has focused on the fact that the avulsed tooth (which is essentially a free graft) is often exposed to air or held in tissue or cloth (dry storage) while first aid caregivers search for milk. Laboratory studies have supported earlier clinical studies demonstrating that after dry storage for more than 15 minutes, precursor cells on the root-side PDL are unable to reproduce and differentiate into fibroblasts. Several authors have shown that with 30 minutes of dry storage, virtually all root-side PDL cells have died.<sup>10–14</sup>

Why is it, then, that teeth replanted many hours after avulsion remain in the mouth, often “look good” and are functional? In these cases of delayed replantation, healing occurs by repair rather than by regeneration. Root-side PDL cells that are immediately stored in appropriate media can retain their vitality for extended periods, but become disabled. They lose their ability to become fibroblasts and to perform the normal functions of PDL cells. Consequently, healing is by repair and little or no PDL is regenerated. In addition, PDL cells on the alveolar side are affected by damage associated with physical tearing of the ligament and loss of the tooth, so they too have limited ability to contribute to the regeneration of new PDL.

### Storage Media and Root Treatments

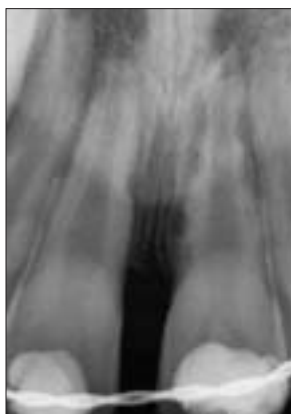For the past decade, laboratory studies of PDL cell vitality have focused on a search for the Holy Grail of storage media, often without consideration of issues of practicality or the blood, tears and confusion that take place when a person is injured by a fall, collision or other misadventure. If the tooth is transferred to a liquid medium such as the patient’s own saliva, milk or saline within the first 15 minutes, some of the cells in the PDL and cementum will survive and may play a role in regeneration. Inevitably, however, storage in a liquid medium before

replantation results in ankylosis, root resorption and eventual extraction.<sup>15</sup> The patient’s own saliva, which is always available, is preferable to desiccation and can be an effective storage medium for up to 30 minutes.<sup>11</sup> If the tooth is transferred to a liquid medium beyond 15 minutes of desiccation, the surviving cells will be increasingly limited in both number and function.<sup>13</sup> Cool milk will maintain the ability of PDL precursor cells to reproduce for almost twice as long as milk that is allowed to warm to room temperature.<sup>11</sup> Clearly, milk packed in ice should be considered the primary extended-time storage medium for avulsed teeth intended for delayed replantation, and ice is almost always available where cold milk is found. Guidelines for the choice of storage media and prereplantation “treatment” of avulsed teeth suggest exotic solutions and treatments for which there is limited scientific evidence. Few dental practices stock saline, still fewer have Hank’s balanced salt solution, and virtually none have ViaSpan (DuPont Pharmaceuticals Co., Wilmington, Del.), a tissue culture medium.

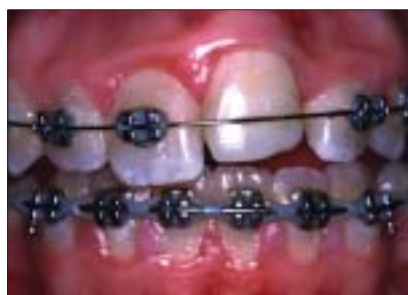For teeth that have undergone an extended extra-alveolar period, most guidelines advocate prereplantation “treatment” of the root surface with fluoride.<sup>1–3</sup> This recommendation is based on a limited number of animal studies and a single case report and is directed toward increasing the resistance of the root to replacement resorption through the formation of fluorapatite on the root surface.<sup>16–18</sup> This treatment has never been tested in a human outcome study, and its clinical utility remains unknown, yet it appears in all 3 guidelines.<sup>1–3</sup> Another treatment that is still advocated on the home page of the AAE Web site<sup>1</sup> and subsequently disproved involved placing teeth with prolonged extra-alveolar time in Hank’s balanced salt solution, a balanced isotonic salt solution, before replantation, with the intent of reconstituting depleted cellular metabolites.<sup>19</sup> Subsequent in vitro experiments have proven (not surprisingly) that root-side cells that are already dead cannot be resurrected by rehydrating them in media such as Hank’s balanced salt solution.<sup>20</sup> Some reputable animal studies (in dogs and monkeys) have supported the use of topical doxycycline “treatment” of teeth before replantation.<sup>21,22</sup> However, topical application is mentioned in one set of guidelines<sup>2</sup> and systemic treatment in another.<sup>3</sup> Furthermore, there are no human outcome studies to support the recommendation of doxycycline treatment for trauma. These treatments, which are only marginally supported by scientific research, are controversial and needlessly complicate clinical management.

### Root Resorption

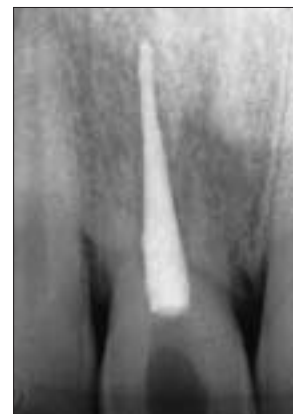Obtaining a precise and accurate post-trauma, prereplantation history is paramount, as postreplantation outcomes are directly related to extra-alveolar time.<sup>7,14</sup> Careful history-taking may reveal, for example, that a tooth



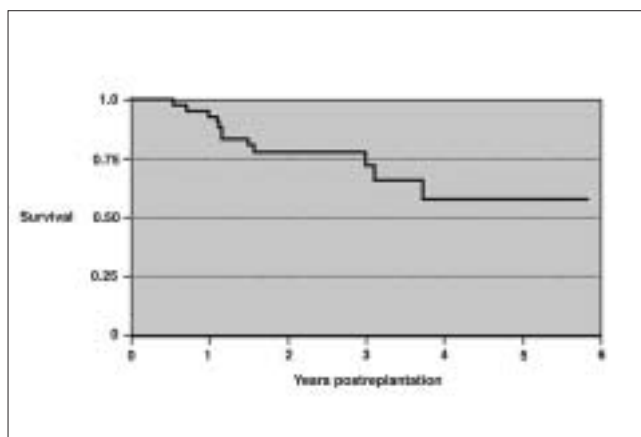
**Figure 1:** Two replanted central incisors affected by inflammatory root resorption. The process, characterized by bowl-shaped radiolucent areas, is initiated by infected dental pulp.



**Figure 2:** Infraocclusion of tooth 21 following replantation more than 3 hours after the initial trauma. Infraocclusion occurs when replacement root resorption (ankylosis) affects the teeth of young people with incomplete skeletal growth. Fusion between the teeth and the alveolus prevents the affected teeth from drifting with growth of the maxilla and thus distorts gingival architecture.



**Figure 3:** Radiograph of a central incisor affected by replacement root resorption. In the absence of infection, the process is progressive and results in eventual loss of the tooth.



**Figure 4:** Survival rates after replantation. If a patient presents with an avulsed permanent incisor that has been stored dry for 60 minutes, the 5-year survival for the tooth is estimated at 0.56. This means that if the replanted tooth is retained for 5 years, there is a probability of 0.56 that the tooth will be retained beyond that point. It does not mean that there is a 56% chance the tooth will be retained for 5 years.<sup>29</sup>

that has arrived in milk was desiccated in a paper napkin for 15 minutes while someone went for the milk. The clinician should strive for a replanted tooth that is free of infection by early removal of the necrotic pulp and timely completion of endodontic treatment. Elimination of infection and prevention of pulp necrosis represent the best means of preventing inflammatory root resorption (Fig. 1). Replacement resorption and ankylosis may be considered acceptable outcomes, as replanted teeth can survive for a number of years. If, in addition, the patient has achieved physical maturity, infraocclusion and gingival irregularity due to surrounding alveolar growth (Fig. 2) will be minimal. Almost all replanted teeth exhibit replacement resorption and ankylosis, as immediate replantation is achieved only rarely.

Replacement resorption leads to fusion of the tooth root with the adjacent alveolar bone (Fig. 3). In older children and adults this process produces bony replacement of root cementum and dentin, followed by loss of the crown either spontaneously or by surgical intervention. In children who have not achieved skeletal maturity, replacement resorption leads to progressive infraocclusion during the adolescent growth spurt. Adolescents and parents often do not want to have these incisor(s) extracted, yet the alveolar and gingival architecture becomes increasingly distorted with growth. Thus, the decision to replant a permanent tooth initiates a number of sequelae, including some that affect socioeconomic aspects of family life.<sup>23,24</sup>

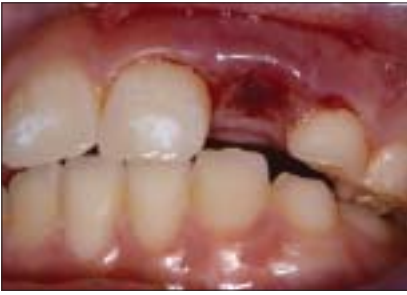Evidence that regeneration of a normal PDL is not expected beyond 5 minutes of extra-alveolar dry storage has produced a paradigm shift in understanding the outcomes of replantation. Avulsed teeth fall into 1 of 2 categories: less than 5 minutes of extra-alveolar dry storage, where the likelihood of regeneration of a functional PDL is maximized,<sup>7,25</sup> and beyond 5 minutes of dry storage, where healing is by repair and tooth loss is inevitable (although survival may be prolonged if the patient is a young adult).<sup>25</sup>

### **Tooth Survival**

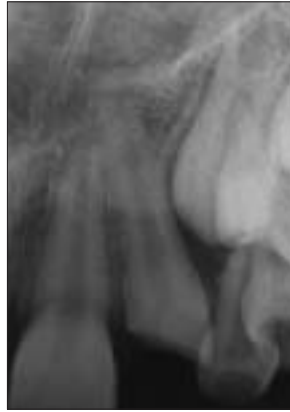A previous study<sup>26</sup> produced survival curves illustrating tooth survival after replantation in a population of adolescents (Fig. 4). Use of this information in conjunction with a thorough discussion of the financial, temporal and emotional costs of replantation will help clinicians, parents and patients arrive at a rational treatment plan.

### **Bioactive Substances**

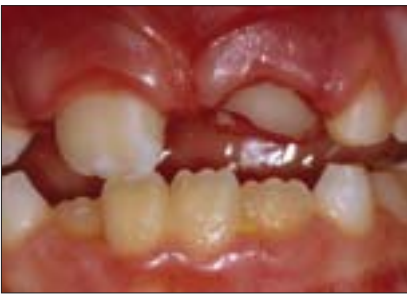Investigators are now working with an enamel matrix derivative, Emdogain (Biora AB, Malmo, Sweden), designed



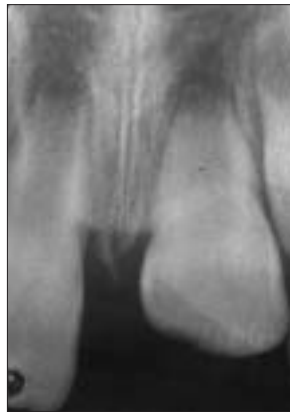**Figure 5a:** Clinical appearance after severe (> 6 mm) intrusion of tooth 22 in a 12-year-old girl. The tooth was surgically repositioned and splinted, and endodontic treatment was completed at the time of initial presentation.



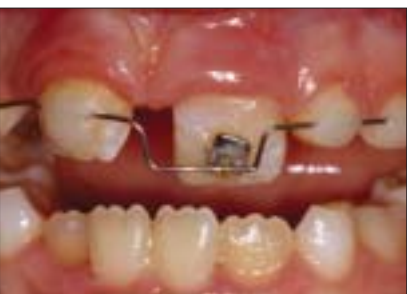**Figure 5b:** Radiographic appearance after severe intrusion of tooth 22 in the same patient.



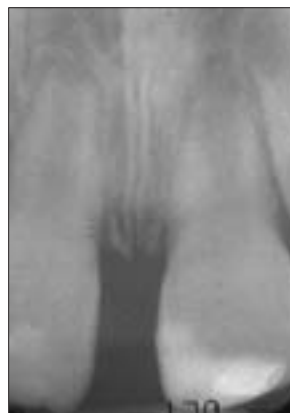**Figure 6a:** Clinical appearance of tooth 21 intruded 4 mm at the time of initial presentation. A tooth with this much intrusion will not predictably reposition without traction.



**Figure 6b:** Radiographic appearance of intruded tooth 21 in the same patient, also at the time of initial presentation.



**Figure 6c:** The appliance employed for active repositioning of intruded tooth 21 in the same patient. Treatment was initiated at the time of initial presentation, and repositioning was accomplished over a period of 6 weeks. Restoration of the crown fracture was completed 7 days after the initiation of treatment.



**Figure 6d:** Final radiographic appearance of the tooth after 6 weeks of treatment.

that a differentiation factor such as Emdogain could promote migration, proliferation and differentiation of PDL fibroblasts<sup>30</sup> within the adjacent alveolus to repopulate the PDL.<sup>31</sup>

There are no published outcome data for Emdogain in the acute management of avulsed teeth. Nevertheless, this material is mentioned in the IADT guidelines<sup>3</sup> as a treatment for replantation. Although the performance of Emdogain on replanted permanent incisors is as yet unknown, the use of such bioactive substances marks the beginning of the use of pharmacotherapeutics in dental trauma management.

## Intrusions

### Guidelines

Clinicians have noted discrepancies in the recommendations of Andreasen and Andreasen,<sup>32</sup> the RCSE,<sup>2</sup> and Andreasen and others.<sup>33</sup> Even the terminology used to describe the treatment of intrusions and subsequent outcomes lacks precision and consistency. The term *spontaneous eruption* gives a falsely optimistic impression, as tooth movement after injury is both unpredictable and pathological rather than developmental, as it would be in normal eruption. Another imprecise term is *orthodontic repositioning*. The traction forces used to move intruded incisors exceed those of conventional orthodontic treatment, and severely intruded teeth do not have a functional PDL, a prerequisite for orthodontic movement (Figs. 5a, 5b). These terms imply that an intruded tooth will return to its original location with time or that it can be moved there by the same mechanics and with the same predictability as conventional orthodontic treatment, neither of which is necessarily true. Current management strategies include surgical reduction (immediate repositioning), repositioning with traction (active repositioning) and waiting for the tooth to return to its preinjury position (passive repositioning).

### Amount of Intrusion as Most Critical Factor

Along with avulsions, intrusions are the other most complicated and controversial luxation injuries. A severe intrusion produces catastrophic injury to the alveolar bone, shears and destroys PDL cells and the ligament itself, and crushes the apical vascular system. Previously it was thought that the stage of root development was the determining factor for the outcome of intruded teeth.<sup>32</sup>

Now it appears that the amount of intrusion is the critical determinant of pulp and tooth survival. Some studies have shown that intrusions of up to 3 mm have an excellent prognosis, whereas the prognosis of incisors with severe (> 6 mm)

to facilitate PDL regeneration and thus inhibit replacement resorption. One group is involved in a prospective outcome case series,<sup>27</sup> while others have undertaken animal studies<sup>28</sup> and described unconventional applications.<sup>29</sup> It is speculated

**Table 1 Treatment options for intrusions by amount of intrusion**

Amount of intrusion (mm) <sup>a</sup>	Treatment options
Mild < 3	Passive repositioning (observation)
Moderate 3–6	Passive repositioning (observation) Active repositioning (immediate traction)
Severe > 6	Extraction Immediate repositioning (surgical reduction) Extraction, immediate root canal treatment, removal of periodontal ligament, replantation

<sup>a</sup>Categories of the Royal College of Surgeons of England.

intrusion is hopeless because of inflammatory root resorption and pulp necrosis.<sup>34,35</sup>

Although the categories for severity of intrusion used by the RCSE are arbitrary, they approximate the results of a number of studies and provide a framework for outcome prediction (Table 1). Incisors intruded less than 3 mm (RCSE category 1) are best left to reposition themselves (passive repositioning) and have very good prospects for survival, although obturation of the pulp canal and early pulp necrosis are common outcomes.<sup>32,34</sup> Incisors intruded between 3 and 6 mm (RCSE category 2) (Figs. 6a, 6b) are unpredictable and can be complicated by crown fractures and pulp necrosis, which lead to inflammatory resorption. Clinicians who use active repositioning or wait for passive repositioning of teeth intruded between 3 and 6 mm must ensure that they can obtain endodontic access within 1–2 weeks to remove the dental pulp and prevent the development of inflammatory root resorption, an unnecessary complication. If active repositioning is chosen, early application of forces is required. Orthodontic brackets or simple composite anchors to a stainless steel wire splint will provide a traction point for active repositioning of the tooth (Figs. 6c, 6d). Incisors intruded beyond 6 mm (RCSE category 3) are firmly held by compressed bone and do not respond predictably to active repositioning. Attempts to actively reposition these intrusions can delay the removal of necrotic pulp, which could lead to inflammatory resorption. Teeth with intrusion beyond 6 mm can be extracted or immediately repositioned, followed by root canal treatment. For severe intrusions, there is no chance of PDL regeneration, as the tooth has essentially been extracted (i.e., there is no PDL) and is held in compressed bone. This presents another option: extraction, removal of the damaged PDL, immediate extraoral root canal treatment and replantation. The outcome here is predictable: ankylosis accompanied by replacement root resorption and eventual loss of the tooth, the same result as would be obtained for an avulsed tooth treated the same way. Although there have been no outcome studies of intruded teeth treated in

this manner, the situation is analogous to replantation of avulsed teeth.<sup>36</sup>

### **Treatment Equivalence**

Presently no one treatment method has been demonstrated as superior to the others, and the incidence of pulp necrosis with all methods ranges between 45% and 96%.<sup>34,35</sup> However, if active repositioning is chosen, it should begin immediately. The patient and the parents must understand the requirement for compliance with additional appointments and must also accept that success cannot be assured.

### **Knowledge Base**

The mechanism of passive repositioning of intruded teeth is unknown. However, it has been established that appropriate, timely removal of a necrotic pulp followed by conventional root canal treatment will prevent inflammatory root resorption, whereas failure to remove a necrotic pulp stimulates inflammatory root resorption.

The mechanism of PDL regeneration after replantation is not well understood. Teeth replanted after 5 minutes of desiccation will ultimately have to be extracted. The resultant partially or completely resorbed roots will probably be associated with abnormal bone and produce an atypical implant site. Finally, the effects of avulsion and intrusion injuries and the resulting clinical decisions will be a burden on these patients for the rest of their lives.

### **Prevention**

Although the evidence supports the importance of immediate replantation, first aid caregivers are often shy or frightened about replacing a tooth in an upset child. Dentists may be present at some organized sports events, where such injuries often occur, but the steps taken by lay caregivers will determine survival for the majority of avulsed teeth. Dental assistants and hygienists should have the confidence to replant teeth immediately at the scene of an accident, and coaches should be trained and empowered to do the same, through direct education or technique posters.

Parents perceive a shared responsibility with coaches to ensure compliance with mouthguard use.<sup>37</sup> One study showed that 40% of dentists favoured stock or “boil and bite” mouthguards, even though they are inferior.<sup>38</sup> Investigators are attempting to identify important parameters for protection by standardizing testing (impact) devices and tooth-jaw models. Regardless of the method of testing, laboratory-produced mouthguards of similar thickness provide better cushioning and dissipation of forces than user-fitted “boil and bite” mouthguards, yet even laboratory-produced mouthguards show considerable variation.<sup>39</sup>

Immediate replantation can affect the survival of an avulsed tooth, and properly fitted mouthguards reduce the severity of dental injury. Dentists can educate and empower

all members of their team to provide first aid care for avulsions and to be vigilant for opportunities to encourage the use of custom mouthguards. ♦

*Dr. Kenny is director of dental research and graduate studies and senior associate scientist, Research Institute, The Hospital for Sick Children, and professor, University of Toronto, Toronto, Ontario.*

*Dr. Barrett is coordinator of dental trauma research, The Hospital for Sick Children, and assistant professor, University of Toronto, Toronto, Ontario.*

*Dr. Casas is manager of dental trauma research, Bloorview MacMillan Children's Centre, and assistant professor, University of Toronto, Toronto, Ontario.*

*Correspondence to: Dr. David J. Kenny, Department of Dentistry, The Hospital for Sick Children, 555 University Ave., Toronto, ON M5G 1X8. E-mail: dkenny@sickkids.ca.*

*The authors have no declared financial interests in any company manufacturing the types of products mentioned in this article.*

## References

1. Treatment of the avulsed permanent tooth: recommended guidelines of the American Association of Endodontists. Chicago, Ill. 1995. Available from: URL: <http://www.aae.org/ws94ecfe.html>.
2. Treatment of avulsed permanent teeth in children. Royal College of Surgeons of England. London, 1997. Available from: URL: [http://www.rcseng.ac.uk/dental/fds/clinical\\_guidelines](http://www.rcseng.ac.uk/dental/fds/clinical_guidelines).
3. Flores MT, Andreasen JO, Bakland LK, Feiglin B, Gutmann JL, Oikarinen K, and others. Guidelines for the evaluation and management of traumatic dental injuries. *Dent Traumatol* 2001; 17(5):193–8. Available from: URL: [http://www.iadt-dentaltrauma.org/Trauma/guide\\_opena.htm](http://www.iadt-dentaltrauma.org/Trauma/guide_opena.htm).
4. Barrett EJ, Kenny DJ. Avulsed permanent teeth: a review of the literature and treatment guidelines. *Endod Dent Traumatol* 1997; 13(4):153–63.
5. Kahabuka FK, Ntabaye MK, van't Hof MA, Plasschaert A. Effect of a consensus statement on initial treatment for traumatic dental injuries. *Dent Traumatol* 2001; 17(4):159–62.
6. McCracken GI, Nunn JH, Hobson RS, Stephenson JJ, Jepson NJ. Evaluation of a computer-assisted learning package on the management of traumatized incisors by general dental practitioners. *Endod Dent Traumatol* 2000; 16(1):40–2.
7. Andreasen JO, Borum MK, Jacobsen HL, Andreasen FM. Replantation of 400 avulsed permanent incisors. 4. Factors related to periodontal ligament healing. *Endod Dent Traumatol* 1995; 11(2):76–89.
8. Hamilton FA, Hill FJ, Mackie IC. Investigation of lay knowledge of the management of avulsed permanent incisors. *Endod Dent Traumatol* 1997; 13(1):19–23.
9. Blakytyn C, Surbutts C, Thomas A, Hunter ML. Avulsed permanent incisors: knowledge and attitudes of primary school teachers with regard to emergency management. *Int J Paediatr Dent* 2001; 11(5):327–32.
10. Lekic P, Kenny D, Moe HK, Barrett E, McCulloch CA. Relationship of clonogenic capacity to plating efficiency and vital dye staining of human periodontal ligament cells: implications for tooth replantation. *J Periodontol* 1996; 31(4):294–300.
11. Lekic PC, Kenny DJ, Barrett EJ. The influence of storage conditions on the clonogenic capacity of periodontal ligament cells: implications for tooth replantation. *Int Endod J* 1998; 31(2):137–40.
12. Layug ML, Barrett EJ, Kenny DJ. Interim storage of avulsed permanent teeth. *J Can Dent Assoc* 1998; 64(5):357–63, 365–9.
13. Lin DG, Kenny DJ, Barrett EJ, Lekic P, McCulloch CA. Storage conditions of avulsed teeth affect the phenotype of cultured human periodontal ligament cells. *J Periodontol* 2000; 35(1):42–50.
14. Kenny DJ, Barrett EJ. Pre-replantation storage of avulsed teeth: fact and fiction. *J Calif Dent Assoc* 2001; 29(4):275–81.
15. Donaldson M, Kinirons MJ. Factors affecting the time of onset of resorption in avulsed and replanted incisor teeth in children. *Dent Traumatol* 2001; 17(5):205–9.
16. Barbakow FH, Cleaton-Jones PE, Austin JC, Vieira E. Effects of thyrocalcitonin, acidulated sodium fluoride, and neutral sodium fluoride on the mobility of experimentally replanted teeth. *J Endod* 1980; 6(11):823–8.
17. Selvig KA, Bjorvatn K, Bogle GC, Wikesjo UM. Effect of stannous fluoride and tetracycline on periodontal repair after delayed tooth replantation in dogs. *Scand J Dent Res* 1992; 100(4):200–3.
18. Duggal MS, Toumba KJ, Russell JL, Paterson SA. Replantation of avulsed permanent teeth with avital periodontal ligaments: case report. *Endod Dent Traumatol* 1994; 10(6):282–5.
19. Krasner P, Person P. Preserving avulsed teeth for replantation. *J Am Dent Assoc* 1992; 123(11):80–8.
20. Doyle DL, Dumsha TC, Sydiskis RJ. Effect of soaking in Hank's balanced salt solution or milk on PDL cell viability of dry stored human teeth. *Endod Dent Traumatol* 1998; 14(5):221–4.
21. Cvek M, Cleaton-Jones P, Austin J, Lownie J, Kling M, Fatti P. Effect of topical application of doxycycline on pulp revascularization and periodontal healing in replanted monkey incisors. *Endod Dent Traumatol* 1990; 6(4):170–6.
22. Yanpiset K, Trope M. Pulp revascularization of replanted immature dog teeth after different treatment methods. *Endod Dent Traumatol* 2000; 16(5):211–7.
23. Glendor U, Halling A, Bodin L, Andersson L, Nygren A, Karlsson G, and other. Direct and indirect time spent on care of dental trauma: a 2-year prospective study of children and adolescents. *Endod Dent Traumatol* 2000; 16(1):16–23.
24. Glendor U. On dental trauma in children and adolescents. Incidence, risk, treatment time and costs. *Swed Dent J Suppl* 2000; 140:1–52.
25. Andersson L, Bodin I, Sorensen S. Progression of root resorption following replantation of human teeth after extended extraoral storage. *Endod Dent Traumatol* 1989; 5(1):38–47.
26. Barrett EJ, Kenny DJ. Survival of avulsed permanent maxillary incisors in children following delayed replantation. *Endod Dent Traumatol* 1997; 13(6):269–75.
27. Kenny DJ, Barrett EJ, Johnston DH, Sigal MJ, Tenenbaum HC. Clinical management of avulsed permanent incisors using Emdogain: initial report of an investigation. *J Can Dent Assoc* 2000; 66(1):21. Available from: URL: <http://www.cda-adc.ca/jcda/vol-66/issue-1/index.html>.
28. Iqbal MK, Bamaas NS. Effect of enamel matrix derivative (EMDOGAIN) upon periodontal healing after replantation of permanent incisors in beagle dogs. *Dent Traumatol* 2001; 17(1):36–45.
29. Filippi A, Pohl Y, von Arx T. Treatment of replacement resorption with Emdogain — preliminary results after 10 months. *Dent Traumatol* 2001; 17(3):134–8.
30. Lowenberg B, Thibault J, Lawrence C, Sodek J. The influence of chemically-induced modifications of root surfaces on cell migration, attachment, and orientation. *J Dent Res* 1986; 65(7):1010–5.
31. Nyman S, Houston F, Sarhed G, Lindhe J, Karring T. Healing following replantation of teeth subjected to root planing and citric acid treatment. *J Clin Periodontol* 1985; 12(4):294–305.
32. Andreasen FM, Andreasen JO. Luxation injuries. In: Textbook and color atlas of traumatic injuries to the teeth. 3rd ed. Copenhagen: Munksgaard; 1994. p. 315–78.
33. Andreasen JO, Andreasen FM, Bakland LK, Flores MT. Intrusive luxation. In: Traumatic dental injuries — a manual. 1st ed. Copenhagen: Munksgaard; 1999. p. 38–9.
34. Kinirons MJ, Sutcliffe J. Traumatically intruded permanent incisors: a study of treatment and outcome. *Br Dent J* 1991; 170(4):144–6.
35. Al-Badri S, Kinirons M, Cole B, Welbury R. Factors affecting resorption in traumatically intruded permanent incisors in children. *Dent Traumatol* 2002; 18(2):73–6.

36. Andreasen JO. The effect of pulp extirpation or root canal treatment on periodontal healing after replantation of permanent incisors in monkeys. *J Endod* 1981; 7(6):245-52.
37. Diab N, Mourino AP. Parental attitudes toward mouthguards. *Pediatr Dent* 1997; 19(8):455-60.
38. Maestrello CL, Mourino AP, Farrington FH. Dentists' attitudes toward mouthguard protection. *Pediatr Dent* 1999; 21(6):340-6.
39. Warnet L, Greasley A. Transient forces generated by projectiles on variable quality mouthguards monitored by instrumented impact testing. *Br J Sports Med* 2001; 35(4):257-62.