

Managing the care of patients with bisphosphonate-associated osteonecrosis

An American Academy of Oral Medicine position paper

CESAR A. MIGLIORATI, D.D.S., M.S., Ph.D.;
JEFFREY CASIGLIA, D.M.D.; JOEL EPSTEIN, D.M.D.,
M.S.D., F.R.C.D.(C.); PETER L. JACOBSEN, Ph.D.,
D.D.S.; MICHAEL A. SIEGEL, D.D.S., M.S.;
SOOK-BIN WOO, D.M.D.

Recently, a new oral complication of cancer treatment was identified: bisphosphonate-associated osteonecrosis (BON). In this position paper, our goals are to educate the community of practicing dentists about bisphosphonates, the medications associated with this oral complication; the patient population at risk and the diseases being treated with this class of medications; the clinical presentation of the oral lesions of BON; the guidelines for the management of care of patients who develop BON; the prevention of this complication based on current knowledge; and recommendations for the routine dental treatment of patients receiving bisphosphonate therapy. These recommendations are based on expert opinion because at this time, there are no available randomized controlled trials that support any effect on patient management and outcomes.

The oral lesions associated with bisphosphonates are similar in appearance to those of radiation-induced osteonecrosis. Clinically, they appear as ragged oral

Background. This position paper addresses the prevention of bisphosphonate-associated osteonecrosis (BON) and the management of care of patients with cancer and/or osteoporosis who are receiving bisphosphonates and who have BON or are at risk of developing it.

Methods. The authors reviewed the literature available on this newly described oral complication. Information of interest included bisphosphonates, the medications associated with this oral complication; the patient population at risk of developing BON and the diseases being treated with this class of medications; the clinical presentation of the oral lesions; guidelines for managing the care of patients who develop BON; the prevention of this complication based on current knowledge; and recommendations for routine dental treatment of patients receiving bisphosphonates.

Results. There is strong evidence that bisphosphonate therapy is the common link in patients with BON. The pathobiological mechanism leading to BON may have to do with the inhibition of bone remodeling and decreased intraosseous blood flow caused by bisphosphonates. People at risk include patients with multiple myeloma and patients with cancer metastatic to bone who are receiving intravenous bisphosphonates, as well as patients taking bisphosphonates for osteoporosis. The risk of developing complications appears to increase with time of use of the medication. There are no guidelines based on evidence, and the clinical management of the oral complication is based on expert opinion.

Conclusion. Prevention of BON is the best approach to management of this complication. Existing protocols to manage the care of patients who will receive radiation therapy or chemotherapy may be used until specific guidelines for BON are developed.

Key Words. Osteonecrosis; bisphosphonates; jaw; cancer metastasis; skeletal metastasis; oral complication; osteoporosis.



Prevention of bisphosphonate-associated osteonecrosis is the best approach to management of this complication.

mucosal ulcerations that expose underlying bone and often are extremely painful.^{1,2} The lesions are persistent and do not respond to conventional treatment modalities such as débridement, antibiotic therapy or hyperbaric oxygen therapy. The presence of these lesions complicates the oncological, nutritional and oral management of affected patients.

BACKGROUND

A review of bisphosphonates. Bisphosphonates are synthetic analogues of inorganic pyrophosphate that have a high affinity for calcium. They clear rapidly from the circulation, bind to bone mineral and concentrate selectively in bone. If not incorporated into the bone's mineral matrix, bisphosphonates are eliminated in urine.³⁻⁷

Bisphosphonates are potent inhibitors of osteoclastic activity.⁶ All bisphosphonate compounds accumulate over extended periods of time in mineralized bone matrix. Depending on the duration of the treatment and the specific bisphosphonate prescribed, the drug may remain in the body for years.⁸ During bone resorption, bisphosphonates are released from the bone and may be either reincorporated into newly formed bone or phagocytized by osteoclasts.⁶ The latter process results in loss of osteoclasts' ability to resorb bone and promote apoptosis or programmed cell death. Osteoblast-induced osteoclastic bone resorption is another important action that may be affected by bisphosphonates.⁹⁻¹¹ Therefore, physiologic bone deposition and remodeling are severely compromised in patients receiving bisphosphonate therapy.^{12,13} Additionally, bisphosphonates have antiangiogenic properties and may be directly tumoricidal, making them an important agent in cancer therapy.^{14,15}

Bisphosphonates are used to treat osteoporosis, Paget's disease of bone and hypercalcemia of malignancy. In patients with osteoporosis, it is expected that bisphosphonates will arrest bone loss and increase bone density, decreasing the risk of pathologic fracture resulting from progressive bone loss.¹⁶ Bisphosphonates are given to patients with cancer to help control bone loss resulting from metastatic skeletal lesions.^{3,6} They reduce skeletal-related events associated with multiple myeloma (such as fractures) and metastatic solid tumors (such as breast, lung and prostate cancers) in the bones.^{6,17-23} The physician's decision regarding which type of bisphos-

phonate to use depends on the type of medical condition being treated and the potency of the drug required. For example, orally administered bisphosphonates often are used in patients with osteoporosis, while the injectable bisphosphonates are used in patients with cancer who develop primary lesions of bone or skeletal metastasis.

Chemical structure and antiresorptive potencies. Bisphosphonates structurally resemble naturally occurring polyphosphates (pyrophosphates) and have demonstrated similar physicochemical effects. It is known that the parachlorophenol moiety central to the chemical structure of bisphosphonates is essential for binding to hydroxyapatite and for affinity to the skeleton.⁶ Chemical variations of the lateral side chains R¹ and R² are one of the examples that can be observed in Figure 1.

As seen in Table 1, the presence of either an amino-terminal group or a cyclic nitrogen-containing side chain increases resorptive potency logarithmically.

PATHOBIOLOGICAL MECHANISM OF BIPHOSPHONATE-ASSOCIATED OSTEONECROSIS

The exact mechanism that leads to the induction of BON is unknown. However, risk factors have been recognized and may be classified as systemic and local (Table 2, page 1661).

Bone remodeling is a physiologic function that occurs in normal bone. It removes microdamage and replaces damaged bone with new elastic osseous tissue.⁸ This function takes place within small compartments called "bone multicellular units" (BMUs).²⁴ These units are composed of osteoblasts (pre-bone-producing cells), osteoclasts (bone-resorbing cells) and blood vessels. Bisphosphonates bind to bone and incorporate in the osseous matrix. During bone remodeling, the drug is taken up by osteoclasts and internalized in the cell cytoplasm, where it inhibits osteoclastic function and induces apoptotic cell death.⁴ It also inhibits osteoblast-mediated osteoclastic resorption and has antiangiogenic properties.^{3,7,25} As a result, bone turnover becomes profoundly suppressed and, over time, the bone shows little physiologic remodeling.^{8,13} The bone becomes brittle and unable to repair physiologic microfractures that occur in the human skeleton with daily activity.^{26,27} In the oral cavity, the maxilla and mandible are subjected to constant stress from masticatory forces.¹³ Thus, it is expected that

physiologic microdamage and microfractures occur daily in the oral cavity. It is theorized that in a patient taking a bisphosphonate, the resulting microdamage is not repaired, setting the stage for oral osteonecrosis to occur.

The need for repair and remodeling is increased greatly when there is infection in the maxilla or mandible, and/or when an extraction is performed. In some patients using bisphosphonates, the bone is unable to meet these increased needs, both because of its reduced ability to remodel and turn over and because of hypovascularity, which results in osteonecrosis.^{28,29} Therefore, BON results from a complex interplay of bone metabolism, local trauma, increased demand for bone repair, infection and hypovascularity (Figure 2).

Patients receiving bisphosphonates intravenously clearly are more susceptible to BON than are those receiving the drug orally. Other comorbid factors may play a role, but the extent of their influence has yet to be determined. These include systemic factors such as the presence of diabetes mellitus, overall tumor burden and stage

of disease; extent of skeletal involvement; the patient's overall systemic health; the degree of immunosuppression; the patient's history of stem cell transplantation; and the patient's current and historical use of other medications such as chemotherapeutic agents or corticosteroids. In addition, patients with multiple myeloma are treated with other antiangiogenic agents such as thalidomide, glucocorticoids and bortezomib.³⁰⁻³³ Local comorbid factors include oral health status, presence of infection (acute or chronic), history of radiation therapy and the presence of myeloma or metastatic cancer at the BON site.

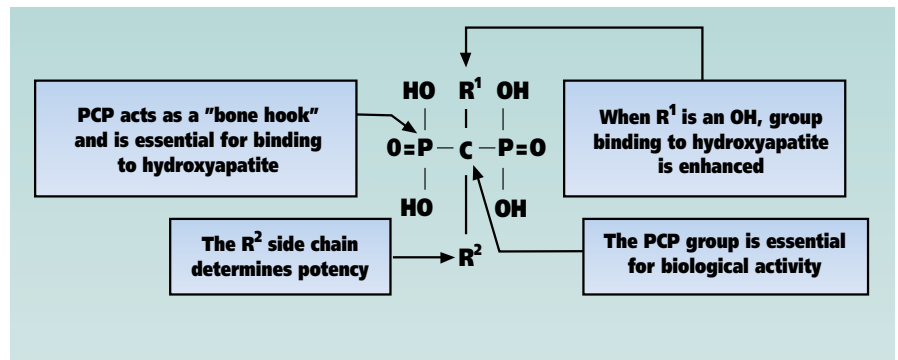


Figure 1. Chemical structure of bisphosphonates demonstrating that the manipulation of the basic structure will change the biological activity and the potency of the drug. Adapted with permission of Harvey Whitney Books from Licata.⁶

TABLE 1

ANTIRESORPTIVE POTENCY OF BISPHTHONATES OBSERVED IN HUMAN CLINICAL TRIALS.*

COMPOUND	PRECLINIC ANTIRESORPTIVE RELATIVE POTENCY	ROUTE OF ADMINISTRATION
Short Alkyl or Halide Side Chain Etidronate (Didronel [†])	1	Oral (O)/ Intravenous (IV)
Cyclic Chloro Side Chain Tiludronate (Skelide [‡])	10	O
Aminterminal Group Pamidronate (Aredia [§]) Alendronate (Fosamax [¶])	100 100-1,000	IV O
Cyclic Nitrogen-Containing Side Chain Risedronate (Actonel [#]) Ibandronate (Boniva ^{**}) Zoledronic acid (Zometa ^{††})	1,000-10,000 1000-10,000 ≥ 10,000	O O IV

* Adapted from Watts.¹⁶
[†] Didronel is manufactured by Procter & Gamble Pharmaceuticals, Cincinnati.
[‡] Skelide is manufactured by Sanofi-Aventis Bridgewater, N.J.
[§] Aredia is manufactured by Novartis Pharmaceutical Co., East Hanover, N.J.
[¶] Fosamax is manufactured by Merck, Whitehouse Station, N.J.
[#] Actonel is manufactured by Procter & Gamble Pharmaceuticals.
^{**} Boniva is manufactured by Roche Pharmaceuticals, Nutley, N.J.
^{††} Zometa is manufactured by Novartis Pharmaceutical Co.

THE CLINICAL SIGNS AND SYMPTOMS OF BISPHTHONATE-ASSOCIATED OSTEONECROSIS

Recently, investigators have reported cases of BON in the medical and dental literature describing patients with various types of cancer receiving intravenous bisphosphonates to control and treat metastatic bone disease^{29,34-53} (Table 3, page 1662). The patients used pamidronate and zoledronic acid. Additionally, investigators have reported a few cases of BON in patients taking oral doses of alendronate to treat osteoporosis or osteopenia. The use of bis-

TABLE 2

RISK FACTORS ASSOCIATED WITH BISPHOSPHONATE-ASSOCIATED OSTEONECROSIS.

EXTENT OF RISK FACTOR	RISK FACTOR
Systemic	Intravenous use of bisphosphonates such as pamidronate and zoledronic acid Multiple myeloma Cancer metastatic to bone such as breast, lung and prostate
Local	Dental extractions Surgical bone manipulation* Trauma from dentures Presence of oral infection* Poor oral health*

* While these possibly participate in the process, the mechanisms by which they might do so have not yet been completely identified.

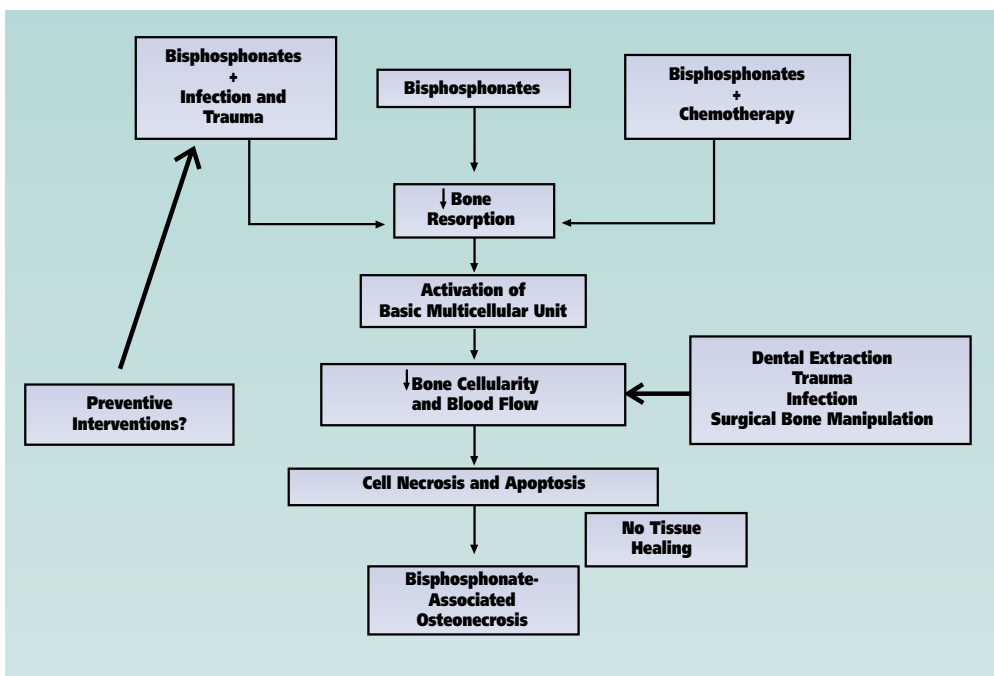


Figure 2. Pathobiological model for the development of bisphosphonate-associated osteonecrosis. Bisphosphonates, alone or in association with oral cavity infection and trauma or systemic chemotherapy, may lead to cell necrosis and apoptosis. Sequence of events would include the decrease in bone resorption and decrease of activation of bone multicellular units, leading to decreased bone cellularity and reduced blood flow. At this point, bone remodeling is severely compromised. All these events combined would predispose the jawbones to osteonecrosis. Adapted with permission of John Wiley & Sons from Migliorati and colleagues.²⁹

phosphonates seemed to be the only common link in all cases reported. Some patients were being treated concomitantly with steroids.^{29,48,49}

The most common clinical history associated with this process is absent or delayed hard- and soft-tissue healing after dental extractions.^{29,36,41} Trauma induced by prosthodontic appliances also has been implicated in the initiation of this

pathological process. In the early stages of oral BON, no radiographic manifestations can be seen. Patients usually are asymptomatic but may develop severe pain because of the necrotic bone becoming infected secondarily after it is exposed to the oral environment. The osteonecrosis often is progressive and may lead to extensive areas of bony exposure and dehiscence. When tissues are acutely infected, patients may complain of severe pain and lack of sensory sensation (paresthesia). This may be an indication of peripheral nerve compression (Figures 3 [page 1664] and 4 [page 1665]).

In patients who develop BON spontaneously, the most common initial complaint is the sudden presence of intra-oral discomfort and the presence of roughness that may progress to traumatize the oral soft tissues surrounding

the area of necrotic bone. Therefore, the diagnosis of BON is based on the medical and dental history of each patient, as well as the observation of clinical signs and symptoms of this pathological process.

Although several case series reports of this drug-associated complication have been published, there have been no documented uniform

TABLE 3

CASES OF BISPHOSPHONATE-ASSOCIATED OSTEONECROSIS REPORTED IN THE LITERATURE.*

AUTHOR	NO. OF PATIENTS	DIAGNOSIS (NO. OF PATIENTS)	PAIN	LOCATION OF OSTEONECROSIS	EXTRACTION (%)	BISPHOSPHONATES INVOLVED	TREATMENT
Migliorati ³⁵	5 (sex unknown)	Unknown	Yes	Mylohyoid ridge (3) Extraction site (2)	2 (40)	Pamidronate Zoledronic acid	Unknown
Marx ³⁶	36 (sex unknown)	Myeloma (18) Breast cancer (17) Osteoporosis (1)	Yes	Mandible (29) Maxilla (5) Both (2)	28 (78)	Pamidronate (24) Zoledronic acid (6) Both (6) Alendronate	Unknown
Wang and colleagues ³⁸	3 (all female)	Breast cancer Diabetes and deep vein thrombosis (1)	1 in 3 had pain	Mandible (1) Maxilla (2), both with oroantral fistulae	2 (67)	Pamidronate Many other agents	Extraction Decortication Débridement
Ruggiero and colleagues ⁴¹	63 (18 male, 45 female)	Myeloma (28) Breast cancer (21) Metastatic cancer (7) Osteoporosis (7)	Yes	Mandible (40) Maxilla (24) (One patient had cancer in both locations) 25 percent of patients had bilateral cancer	54 (86)	Pamidronate Zoledronic acid Alendronate Ongoing chemotherapy	Sequestrectomy (45) Resection (10) Maxillectomy (6) Hyperbaric oxygen (HBO) therapy (2)
Bagan and colleagues ⁴⁸	10 (2 male, 8 female)	Myeloma (4) Breast cancer (6)	Yes	Mandible (10) Maxilla (5) (5 patients had both) 2 patients with fistulae	7 (70)	Pamidronate Zoledronic acid Many other agents	Unknown
Vanunucchi and colleagues ³⁷	1 (male)	Myeloma	Yes (trismus)	Mandible	Unknown	Zoledronic acid	HBO therapy (unsuccessful) Chlorhexidine and antibiotics (reduced symptoms)

Continued on next page

treatment strategies that would yield consistent resolution and healing of BON.⁴¹ In fact, many cases had poor outcomes in spite of therapy, progressing to extensive dehiscence and exposure of bone.^{41,48} Treatment strategies included local surgical débridement, bone curettage, local irrigation with antibiotics and hyperbaric oxygen therapy.^{34,41} However, none of these therapeutic modalities has proven successful. Therefore, the inability to manage lesions of BON compromises the oncological, nutritional and oral management of affected patients. Prevention of this condition

is of paramount importance for these patients so that they receive the anticancer therapies so necessary for the best possible outcome of their neoplastic disease.

TREATMENT MANAGEMENT RECOMMENDATIONS

The treatment of patients receiving oral or intravenous bisphosphonate therapy is principally preventive in nature. Other management considerations involve modification of the dental treatment plan for a patient taking bisphosphonate medica-

TABLE 3

CASES OF BISPHOSPHONATE-ASSOCIATED OSTEONECROSIS REPORTED IN THE LITERATURE (CONT.)

AUTHOR	NO. OF PATIENTS	DIAGNOSIS (NO. OF PATIENTS)	PAIN	LOCATION OF OSTEONECROSIS	EXTRACTION (%)	BISPHOSPHONATES INVOLVED	TREATMENT
Migliorati and colleagues³⁰	18 (14 female, 4 male)	Myeloma (3) Breast cancer (10) Prostate cancer (1) Ovarian cancer (1) Osteoporosis (1)	Yes	Mandible Maxilla	6 (33)	Pamidronate Zoledronic acid Alendronate Ongoing chemotherapy	Sequestrectomy Antibiotic therapy Rinses Periodontal flap
Lugassy and colleagues⁴²	3 (2 male, 1 female)	Myeloma (3)	Yes (trismus)	Mandible	1 (33)	Pamidronate Zoledronic acid Ongoing chemotherapy	HBO therapy (successful) Sequestrectomy and alveoloplasty
Purcell and Boyd⁴⁷	13 (7 male, 6 female)	Myeloma (3) Breast cancer (5) Prostate cancer (4) Osteoporosis (1)	Yes	Mandible Maxilla	5 (38)	Pamidronate Zoledronic acid Alendronate	Unknown
Melo and Obeid⁴⁶	1 (female)	Breast cancer	No	Maxilla	1 (100)	Zoledronic acid Ongoing chemotherapy	Débridement
Schirmer and colleagues⁴⁹	6 (4 male, 2 female)	Myeloma (4) Breast cancer (2)	Unknown	Maxilla Mandible	Unknown	Unspecified Bisphosphonates Ongoing chemotherapy	Débridement Antibiotics
Viale and Lin⁵²	1 (female)	Lung cancer (1)	Yes	Mandible	0	Zoledronic acid	Antibiotic and oral rinse
Maerevoet and colleagues⁵¹	9 (sex unknown)	Myeloma (4) Breast cancer (5)	Unknown	Unknown	Unknown	Zoledronic acid Pamidronate	Unknown
Sarathy and colleagues⁵³	2 (male)	Prostate cancer (2)	Yes	Mandible Maxilla	0	Zoledronic acid Pamidronate	Débridement Antibiotics
Ficarra and colleagues⁵⁴	9 (3 male, 6 female)	Myeloma (3) Breast cancer (3) Prostate cancer (1) Lung cancer (1) Non-Hodgkin's lymphoma (1)	Yes	Mandible (9) Maxilla (2) (2 patients had cancer in both locations)	9 (100)	Zoledronic acid Pamidronate	Débridement Antibiotics

* Does not include cases from abstracts.

tions and institution of a management protocol for the dental patient who develops BON.

Preventive measures. BON is a newly documented oral complication, and consistently effective therapeutic measures have not yet been identified. The authors of one case series of 63 patients⁴¹ reported that several treatment proto-

cols were attempted to treat BON. Treatment modalities included minor débridement under local anesthesia, major surgical sequestrectomies, marginal and segmental mandibular resections, partial and complete maxillectomies and hyperbaric oxygen therapy. Despite the presence of vascularized bone at the surgical mar-

gins, no healing occurred in any of the patients treated in this study.⁴¹ For this reason, preventive measures are of paramount importance. Until prospective studies of BON provide information about effective treatment protocols, the best approach is prevention, with the dentist and the physician working collaboratively.

A dentist should see all patients before intravenous bisphosphonate therapy begins. Patients who have been given oral bisphosphonates within the last three months also should undergo a dental evaluation. Anecdotal evidence points to a low incidence of BON's occurring less than six months after the beginning of bisphosphonate therapy. Therefore, needed dental therapy can be provided to these patients before the risk of developing BON increases.

Medical information that the dentist should obtain from the patient and the physician includes a complete review of all medical diagnoses, the diagnosis for which the patient will receive bisphosphonate therapy, history of cancer treatment and of oral complications associated with that treatment, expected toxicity resulting from the current treatment regimen, complete blood counts, the type of bisphosphonate that is going to be used and the administration protocol (including the expected duration of therapy). This medical information will guide the dentist in the development of a dental treatment plan that is based on the patient's current dental needs and medical health.

It is recommended that dentists follow existing guidelines for a dental consultation for the prevention of oral complications of cancer therapy (chemotherapy, radiation therapy, prehematopoietic stem cell transplantation). Elimination of all potential sites of infection must be the primary objective of this consultation. The goal of therapy should be to attain a state of good oral and dental health so that during the active phase of bisphosphonate therapy, only three to six months of maintenance hygiene appointments will be necessary. In this consultation, the following should occur:

- A comprehensive extraoral and intraoral examination should be performed. A full-mouth radiographic series and a panoramic radiograph will help in the diagnosis of caries and periodontal disease, the evaluation of third molars and the identification of metastatic cancer and other bony pathology.
- The periodontal health status should be determined and appropriate therapy provided. Pocket

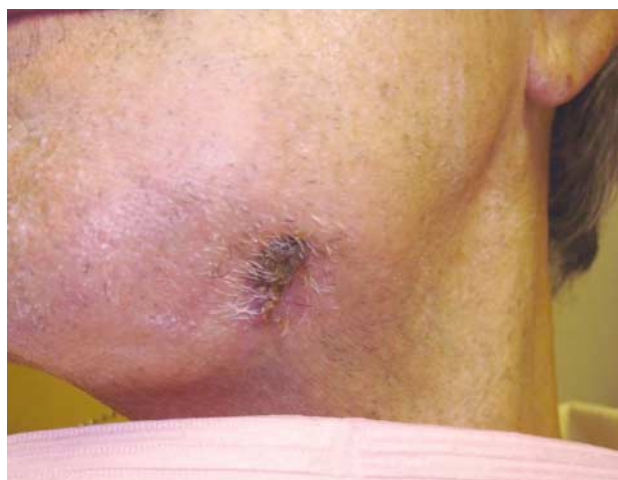

Figure 3 A. Patient with multiple myeloma who used the bisphosphonates pamidronate and zoledronic acid for years developed several areas of oral osteonecrosis. The left mandible had a large area of osteonecrosis that became secondarily infected, leading to the formation of an extraoral fistula.

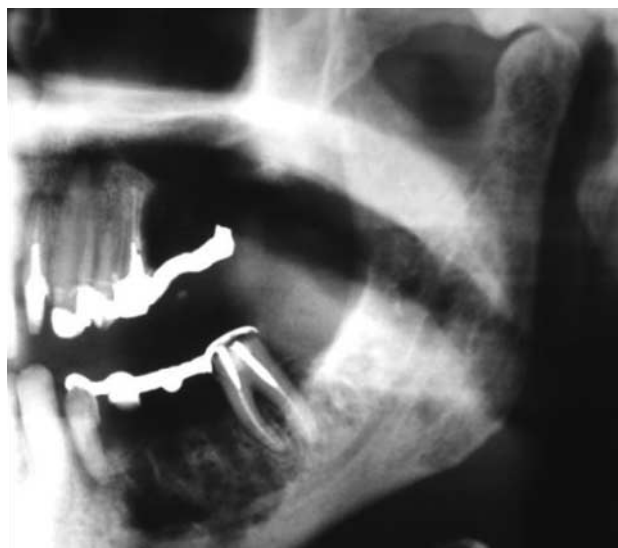

Figure 3 B. The radiographic image of the mandible shows mottled cancellous bone.

elimination is of importance to reduce plaque accumulation, minimize chronic periodontal inflammation and minimize acute periodontal infections.

- Extraction of teeth should be completed as soon as possible.
- Restorative dentistry should be performed to eliminate caries and defective restorations. Crowns and more extensive fixed prosthodontic work may not be appropriate for some patients. Prosthodontic appliances should be evaluated for fit, stability and occlusion. Necessary adjust-

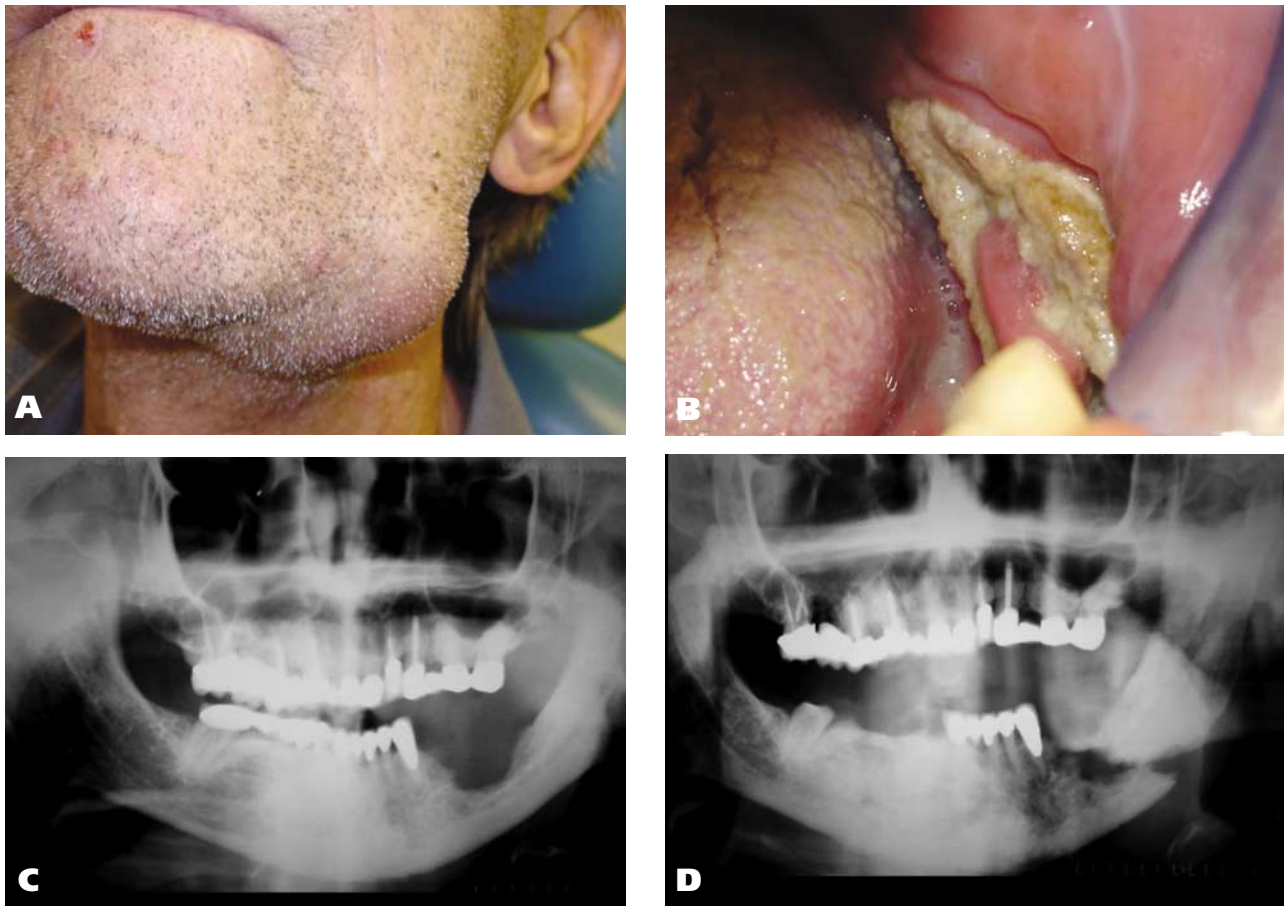


Figure 4. Patient with multiple myeloma who used pamidronate and zoledronic acid for at least four years came to the emergency clinic with severe swelling and pain on the left mandible (A). Palpation of the area suggested a fracture. Intraoral examination revealed an extensive area of osteonecrosis (B) and the panoramic radiograph (C) confirmed a pathological fracture. Observe the progression of the osteonecrosis to fracture in six months. The fracture was surgically stabilized. The presence of a plasmacytoma was confirmed in the area (D). The patient now is receiving hyperbaric oxygen therapy in preparation for radiation therapy. Photos reproduced with permission of Dr. Steven I. Kaltman, Nova Southeastern University, Fort Lauderdale, Fla.

ments should be made.

- Prophylaxis should be performed and oral hygiene instructions given. The patient also should be given information about BON and be made aware of the early signs of development of this condition. Once the active dental treatment is over, periodic follow-up visits should be scheduled to reinforce the importance of oral hygiene maintenance and to conduct a new oral examination.

Management of dental care for patients with BON. Following are recommendations for the management of the dental care of patients with lesion(s) of BON.

- Routine restorative care may be provided. Local anesthetic can be used as necessary.
- Scaling and prophylaxis should be done as atraumatically as possible, with gentle soft-tissue management.

- Avoid dental extractions if possible unless the teeth have a mobility score of 3 or greater. Extractions should be performed as atraumatically as possible. Patients should be followed up weekly for the first four weeks afterward, then monthly until the sockets are completely closed and healed. If there is an indication for antibiotic use, amoxicillin—alone or in combination with clindamycin—may help to reduce the incidence of local infection.

- Teeth that are extensively carious should be considered for endodontic therapy. They should be prepared as overdenture abutments. The crown should be cut off at the gingival margin. This is particularly important in patients in whom a previous extraction had resulted in BON. In these patients, extraction should be avoided whenever possible.

- The area of BON should be treated only with

the objective of eliminating sharp edges of bone that may traumatize soft tissues. This is particularly important when the lingual aspect of the posterior mandibular arch is involved. Superficial débridement may be performed if necessary to eliminate areas that may further traumatize adjacent tissues. Clinicians should follow up with these patients every two to three weeks to re-evaluate the areas and to ensure that they have not become suppurative. If the area around the exposed bone exhibits tender erythema and suppuration and/or sinus tracts, the patient should be treated with antibiotics until the areas resolve. Microbiologic culture and sensitivity tests may be helpful; however, the clinician must realize that culture results do not always guarantee microbiological etiology since host oral flora also can colonize the necrotic bony surface. Use of a chlorhexidine mouthrinse three or four times a day also is recommended to reduce bacterial load and colonization.

A surgical approach with the aim of removing the necrotic bone and closing the site with healthy mucosa may be considered for patients with multiple myeloma who require hematopoietic stem cell transplantation. In a patient with exposed necrotic bone, the risk of undergoing high-dose conditioning chemotherapy in preparation for transplantation is unclear. The necrotic area may act as a portal of entry for bacteria; it may traumatize the adjacent soft tissues and cause ulceration, forming another portal for bacterial contamination. Furthermore, surgical manipulation may not lead to the closure of the necrotic site but to further increase of the osseous breakdown and dehiscence. If a surgical procedure is needed, patients should be informed of the possible risks and benefits. The role of hyperbaric oxygen therapy for the treatment of BON is not known at this time.

- Soft vinyl appliances or obturators may help cover exposed necrotic bone to prevent further trauma to soft tissues. These appliances must not rest on the necrotic tissues. The interior portion of the flanges must be relieved so as not to deliver pressure to the diseased tissues but rather to serve as a barrier to protect them. Therefore, these appliances should not be designed for use during mastication.

- Any existing prosthetic appliances should be re-evaluated to ensure that they fit well. Relining a denture with a soft liner to promote a better fit and to minimize soft-tissue trauma and pressure

points is recommended.

- Odontogenic infections should be treated aggressively with systemic antibiotics. When possible, identification of the responsible microorganisms and respective antibiogram is indicated. If empiric therapy is to be used, although penicillin is the first-choice antibiotic in dentistry, amoxicillin and/or clindamycin provide better bone penetration and a wider spectrum of coverage.

Routine dental treatment of patients taking bisphosphonates. Routine dental treatment of patients taking bisphosphonates is a challenge. There are no prospective scientific studies to support specific recommendations regarding whether providing dental treatment for patients taking a bisphosphonate drug places the patient at any risk of developing BON. A recent Internet-based survey⁵⁴ evaluated the incidence of BON in 1,203 patients receiving intravenous bisphosphonate therapy for the treatment of myeloma (904) or breast cancer (299). The patients were assessed for age, sex, diagnosis, type and duration of bisphosphonate treatment, the presence of a variety of dental problems and dental treatment. Of the 904 patients with myeloma, 62 had a diagnosis of BON and 54 had findings considered suspicious for early BON, giving a total of 116 of 904 patients (12.8 percent). Of the patients with breast cancer, 13 had the diagnosis of BON and 23 had suspicious findings, for a total of 36 of 299 (12 percent). The same study⁵⁰ evaluated the time to onset of BON in patients receiving zoledronic acid or pamidronate. With data censored at 36 months, the researchers estimated that 10 percent of the patients taking zoledronic acid and 4 percent of those taking pamidronate developed BON. Furthermore, without censoring, the mean time to the onset of BON was 18 months for patients receiving zoledronic acid therapy and six years for patients receiving pamidronate therapy. This study showed that 81 percent of the patients with myeloma and 69 percent of the patients with breast cancer who developed BON had underlying dental disease, such as infection, or had had a dental extraction, as compared with 33 percent of the patients who did not develop BON. Another study in Europe reported that the percentage of cases of BON in 194 patients with multiple myeloma and breast cancer treated with zoledronic acid was 4.6 percent.⁵¹

The role of orally administered alendronate. There have been only a few cases of BON in patients receiving alendronate, and it is

unclear if these patients had other systemic or local comorbid factors.^{29,36,41} Questions regarding the viability of dental implants in patients taking alendronate for osteoporosis abound. The risk of developing BON after dental extractions, implant placement, and periodontal and other surgical procedures for patients taking oral bisphosphonates such as alendronate is unknown. The duration of the physiologic effect of these drugs is variable. Evidence shows that severe suppression of bone remodeling may occur during long-term alendronate therapy¹³ and that bone resorption and formation markers may remain suppressed for the time during which the patient is taking the medication.^{8,12} At this time, it appears that the incidence of BON manifesting in patients taking alendronate for osteoporosis is low.

Discontinuation of bisphosphonate therapy. There is no scientific evidence to support discontinuation of bisphosphonate therapy to promote healing of necrotic osseous tissues in the oral cavity. The discontinuation of therapy must be discussed with the oncologist who prescribed the bisphosphonate for the patient. One must consider the risks and benefits of discontinuation. The half-life of intravenous bisphosphonates is reported to be years. Therefore, cessation of bisphosphonate therapy for a few months may have little effect on the bisphosphonate that has already incorporated into bone. However, other effects of bisphosphonates, such as the antiangiogenic activity, may be reduced, and this may help healing of the overlying mucosa. It is unclear whether stopping bisphosphonate therapy for a few months will increase skeletal-related events such as spinal cord fractures. Until prospective studies can be performed, institutions likely will come up with their own policies based on their own experiences and their patient population.

THE ROLE OF THE DENTIST

It is imperative that the general dentist and the dental specialist, as well as other medical professionals, become familiar with this condition.⁵²⁻⁵⁴ It is equally important that dentists take a complete medical and medication history for every patient. Dentists should document carefully any history of cancer treated with bisphosphonates and, if they are unfamiliar with the condition, contact a local dentist familiar with it so that preventive measures as described in this position paper can be instituted promptly. The more information dentists can obtain about this unusual condition, the

better they will be able to serve their patients in the future. Guidelines available are based mostly on individual experience in the management of BON.⁵⁵

CONCLUSION

As new information becomes available and the results of well-designed prospective clinical trials are known, better preventive guidelines and patient management protocols based on scientific evidence will be developed. In the meantime, communication between dentists and medical oncologists must be improved to allow patients to have the best of both dental and medical treatment. Coordination of medical and dental care is of importance in the establishment of measures aimed at preventing the development of BON. Future research must focus on the understanding of the pathobiologic mechanisms that lead to the development of BON. Prospective studies will allow for the identification of significant risk factors that place a patient at risk of developing BON. Because information available regarding the risk of developing BON is based on expert opinion and clinical experience, patients who are receiving bisphosphonate therapy must be informed of the possibility of BON's developing after routine dental treatment. A consensus must be reached among the patient, the dentist and the physician before dental therapy begins. ■

Dr. Migliorati is an associate professor, Department of Diagnostic Sciences, Nova Southeastern University College of Dental Medicine, 3200 S. University Drive, Fort Lauderdale, Fla. 33328-2018, e-mail "migliora@nova.edu". Address reprint requests to Dr. Migliorati.

Dr. Casiglia is a lecturer, Harvard School of Dental Medicine, Boston.

Dr. Epstein is professor and head, Department of Oral Medicine and Diagnostic Sciences, College of Dentistry, University of Illinois at Chicago.

Dr. Jacobsen is a professor, Department of Pathology and Medicine, University of the Pacific School of Dentistry, San Francisco.

Dr. Siegel is a professor and the chair, Department of Diagnostic Sciences, Nova Southeastern University College of Dental Medicine, Fort Lauderdale, Fla.

Dr. Woo is an assistant professor, Department of Oral Medicine, Infection and Immunity, Harvard School of Dental Medicine, Boston.

1. Epstein JB, Wong FL, Stevenson-Moore P. Osteoradionecrosis: clinical experience and a proposal for classification. *J Oral Maxillofac Surg* 1987;45:104-10.

2. Epstein JB, Rea G, Wong FL, Spinelli J, Stevenson-Moore P. Osteonecrosis: study of the relationship of dental extractions in patients receiving radiotherapy. *Head Neck Surg* 1987;10:48-54.

3. Rogers MJ, Watts DJ, Russell RG. Overview of bisphosphonates. *Cancer* 1997;80(supplement 8):1652-60.

4. Russell RG, Rogers MJ, Frith JC, et al. The pharmacology of bisphosphonates and new insights into their mechanisms of action. *J Bone Miner Res* 1999;14(supplement 2):53-65.

5. Lin JH, Russell G, Gertz B. Pharmacokinetics of alendronate: an overview. *Int J Clin Pract Suppl* 1999;101:18-26.
6. Licata AA. Discovery, clinical development, and therapeutic uses of bisphosphonates. *Ann Pharmacother* 2005;39:668-77.
7. Fleisch H. Development of bisphosphonates. *Breast Cancer Res* 2002;4(1):30-4.
8. Ott SM. Long-term safety of bisphosphonates. *J Clin Endocrinol Metab* 2005;90:1897-9.
9. Sato M, Grasser W, Endo N, et al. Bisphosphonate action: alendronate localization in rat bone and effects on osteoblast ultrastructure. *J Clin Invest* 1991;88:2095-105.
10. Xing L, Boyce BF. Regulation of apoptosis in osteoclasts and osteoblastic cells. *Biochem Biophys Res Commun* 2005;328:709-20.
11. Nagashima M, Sakai A, Uchida S, Tanaka S, Tanaka M, Nakamura T. Bisphosphonate (YM529) delays the repair of cortical bone defect after drill-hole injury by reducing terminal differentiation of osteoblasts in the mouse femur. *Bone* 2005;36:502-11.
12. Ensrud KE, Barrett-Connor EL, Schwartz A, et al. Randomized trial of effect of alendronate continuation versus discontinuation in women with low BMD: results from the Fracture Intervention Trial long-term extension. *J Bone Miner Res* 2004;19:1259-69.
13. Odvina CV, Zerwekh JE, Rao DS, Maalouf N, Gottschalk FA, Pak CY. Severely suppressed bone turnover: a potential complication of alendronate therapy. *J Clin Endocrinol Metab* 2005;90:1294-301.
14. Wood J, Bonjean K, Ruetz S, et al. Novel antiangiogenic effects of the bisphosphonate compound zoledronic acid. *J Pharmacol Exp Ther* 2002;302(3):1055-61.
15. Fournier P, Boissier S, Filleur S, et al. Bisphosphonates inhibit angiogenesis in vitro and testosterone-stimulated vascular regrowth in the ventral prostate in castrated rats. *Cancer Res* 2002;62:6538-44.
16. Watts NB. Treatment of osteoporosis with bisphosphonates. *Endocrinol Metab Clin North Am* 1998;27:419-39.
17. Berenson JR, Rosen LS, Howell A, et al. Zoledronic acid reduces skeletal-related events in patients with osteolytic metastases. *Cancer* 2001;91:1191-200.
18. Coleman RE. Future directions in the treatment and prevention of bone metastases. *Am J Clin Oncol* 2002;25(6 supplement 1):S32-8.
19. Ashcroft AJ, Davies FE, Morgan GJ. Aetiology of bone disease and the role of bisphosphonates in multiple myeloma. *Lancet Oncol* 2003;4:284-92.
20. Fleisch H. Bisphosphonates in bone disease: From the laboratory to the patients. 4th ed. San Diego: Academic Press; 2000:34-5.
21. Hillner BE, Ingle JN, Chlebowski RT, et al. American Society of Clinical Oncology 2003 update on the role of bisphosphonates and bone health issues in women with breast cancer [published erratum appears in *J Clin Oncol* 2004;22(7):1351]. *J Clin Oncol* 2003;21:4042-57.
22. Wellington K, Goa KL. Zoledronic acid: a review of its use in the management of bone metastases and hypercalcemia of malignancy. *Drugs* 2003;63:417-37.
23. Berenson JR. Recommendations for zoledronic acid treatment of patients with bone metastases. *Oncologist* 2005;10:52-62.
24. Hauge EM, Qvesel D, Eriksen EF, Mosekilde L, Melsen F. Cancellous bone remodeling occurs in specialized compartments lined by cells expressing osteoblastic markers. *J Bone Miner Res* 2001;16:1575-82.
25. Sietsema WK, Ebetino FH, Salvagno AM, Bevan JA. Antiresorptive dose-dependent relationship across three generations of bisphosphonates. *Drugs Exp Clin Res* 1989;15:389-96.
26. Whyte MP, Wenkert D, Clements KL, McAlister WH, Mumm S. Bisphosphonate-induced osteopetrosis. *N Engl J Med* 2003;349:457-63.
27. Marini JC. Do bisphosphonates make children's bones better or brittle? *N Engl J Med* 2003;349:423-6.
28. Hellstein JW, Marek CL. Bisphosphonate osteochemonecrosis (bis-phossy jaw): is this phossy jaw of the 21st century? *J Oral Maxillofac Surg* 2005;63:682-9.
29. Migliorati CA, Schubert MM, Peterson DE, Seneda LM. Bisphosphate-associated osteonecrosis of mandibular and maxillary bone: an emerging oral complication of supportive cancer therapy. *Cancer* 2005;104:83-93.
30. Munshi NC, Barlogie B, Desikan KR, Wilson C. Novel approaches in myeloma therapy. *Semin Oncol* 1999;26(5 supplement 13):28-34.
31. Clerc D, Ferman JP, Mariette X. Treatment of multiple myeloma. *Joint Bone Spine* 2003;70:173-86.
32. Hussein MA. New treatment strategies for multiple myeloma. *Semin Hematol* 2004;41(4 supplement 7):2-8.
33. Chauhan D, Hideshima T, Mitsiades C, Richardson, Anderson KC. Proteasome inhibitor therapy in multiple myeloma. *Mol Cancer Ther* 2005;4:686-92.
34. Marx RE, Stern D. Oral and maxillo-facial pathology: A rationale for diagnosis and treatment. Hanover Park, Ill.: Quintessence; 2003: 36-8.
35. Migliorati CA. Bisphosphonates and oral cavity avascular bone necrosis. *J Clin Oncol* 2003;21:4253-4.
36. Marx RE. Pamidronate (Aredia) and zoledronate (Zometa) induced avascular necrosis of the jaws: a growing epidemic. *J Oral Maxillofac Surg* 2003;61:1115-7.
37. Vannucchi AM, Ficarra G, Antonioli E, Bosi A. Osteonecrosis of the jaw associated with zoledronate therapy in a patient with multiple myeloma. *Br J Haematol* 2005;128:738.
38. Wang J, Goodger NM, Pogrel MA. Osteonecrosis of the jaws associated with cancer chemotherapy. *J Oral Maxillofac Surg* 2003;61:1104-7.
39. Pogrel MA. Bisphosphonates and bone necrosis. *J Oral Maxillofac Surg* 2004;62:391-2.
40. Estilo CS, Van Poznak CH, Williams T, et al. Osteonecrosis of the maxilla and mandible in patients treated with bisphosphonates: a retrospective study (abstract). *Proc Am Soc Clin Oncol* 2004;22:750.
41. Ruggiero SL, Mehrotra B, Rosenberg TJ, Engroff SL. Osteonecrosis of the jaws associated with the use of bisphosphonates: a review of 63 cases. *J Oral Maxillofac Surg* 2004;62:527-34.
42. Lugassy G, Shaham R, Nemets A, Ben-Dor D, Nahlieli O. Severe osteomyelitis of the jaw in long-term survivors of multiple myeloma: a new clinical entity. *Am J Med* 2004;117:440-1.
43. Schuster MW, Dymek JM. Oral cavity avascular bone necrosis: a newly recognized complication of intravenous (IV) bisphosphonate therapy in cancer patients (abstract 4905). *Blood* 2004;104(11):4905.
44. Zarychanski R, Elphee E, Embil J, Walton P, Johnston JB. Osteonecrosis of the jaw associated with pamidronate therapy (abstract 4908). *Blood* 2004;104(11):4908.
45. Takkar SG, Isada C, Englund K, et al. Bisphosphonate therapy associated with an increased incidence of mandibular/maxillary osteomyelitis in multiple myeloma patients (abstract 4925). *Blood* 2004;104(11):4925.
46. Melo MD, Obeid G. Osteonecrosis of the maxilla in a patient with history of bisphosphonate therapy. *J Can Dent Assoc* 2005;71:111-3.
47. Purcell PM, Boyd IW. Bisphosphonates and osteonecrosis of the jaw. *Med J Aust* 2005;182:417-8.
48. Bagan JV, Murillo J, Jimenez Y, et al. Avascular jaw osteonecrosis in association with cancer chemotherapy: series of 10 cases. *J Oral Pathol Med* 2005;34:120-3.
49. Schirmer I, Peters H, Reichart PA, Durkop H. Bisphosphonates and osteonecrosis of the jaw [in German]. *Mund Kiefer Gesichtschir* 2005;9(4):239-45.
50. Viale PH, Lin A. Exposed bone in oral cavities. *J Clin Oncol Nursing* 2005;9(3):355-7.
51. Maerevoet M, Martin C, Duck L. Osteonecrosis of the jaw and bisphosphonates (letter). *N Engl J Med* 2005;353:100-1.
52. Sarathy AP, Bourgeois Jr SL, Goodell GG. Bisphosphonate-associated osteonecrosis of the jaws and endodontic treatment: two case reports. *J Endod* 2005;31(10):759-63.
53. Ficarra G, Beninati F, Rubino I, Vannucchi A, Longo G, Tonelli P, Pini Prato G. Osteonecrosis of the jaws in periodontal patients with a history of bisphosphonates treatment. *J Clin Periodontol* 2005;32:1123-8.
54. Durie BGM, Katz M, McCoy J, Crowley J. Osteonecrosis of the jaw and bisphosphonates (letter). *N Engl J Med* 2005;353:99.
55. Expert panel recommendations for the prevention, diagnosis, and treatment of osteonecrosis of the jaws, June 2004: Professional education material. East Hanover, N.J.: Novartis Pharmaceutical Company; 2004.