

Invasive cervical resorption

GEOFFREY S. HEITHERSAY

Invasive cervical resorption (cervical resorption) is a relatively uncommon form of external root resorption which has been a source of interest and academic debate by clinicians and researchers for over a century. Clinical, radiologic and pathologic features of invasive cervical resorption provide the basis for a clinical classification which is of use both in treatment planning and for comparative clinical research. Although the etiology of this condition remains obscure, knowledge of potential predisposing factors is important in assessing patients at risk. Treatment, where indicated, should aim at the inactivation of all resorbing tissue and the reconstitution of the resorptive defect either by the placement of a suitable filling material or by the use of biological systems.

Invasive cervical resorption is a clinical term used to describe a relatively uncommon, insidious and often aggressive form of external tooth resorption, which may occur in any tooth in the permanent dentition (1). Characterized by its cervical location and invasive nature, this resorptive process leads to progressive and usually destructive loss of tooth structure. Resorption of coronal dentin and enamel often creates a clinically obvious pinkish color in the tooth crown as highly vascular resorptive tissue becomes visible through thin residual enamel. Essentially, the same resorptive process can occur in other tooth locations: in erupting teeth it may arise through an enamel defect in the tooth crown and may be termed *invasive coronal resorption*, while a more apical source may be termed *invasive radicular resorption*.

Invasive cervical resorption has and continues to be misdiagnosed as a form of internal resorption, a misunderstanding that could possibly be attributed to the descriptions of internal resorption by Gaskill (2) in 1894 and by Mummery (3) in 1920 which included teeth showing 'pink spots'. This pathological process has obviously intrigued clinicians and researchers for over a century, and still remains an enigma judging by the current diversity of opinion regarding possible etiology and pathogenesis. Testimony to this diversity is the nomenclature which has been applied over the years to this periodontally derived form of external tooth resorption. The terms include *odontoclastoma* (4), *idiopathic external resorption* (5), *fibrous dysplasia of teeth* (5), *burrowing resorption* (6), *peripheral cervical resorption*, (7) *late cervical resorption* (8), *cervical external resorption* (9), *extra-canal invasive resorption*

(10), *supraosseous extra-canal invasive resorption* (11), *peripheral inflammatory root resorption* (12), *invasive cervical resorption* (1), *subepithelial inflammatory root resorption* (13, 14), *periodontal infection resorption* (15), or simply, and most commonly, *cervical resorption* (16).

Etiology

Currently, the etiology of invasive cervical resorption is poorly understood and this may explain some of the diversity in terminology as clinicians have applied varying interpretations of the underlying pathogenesis. A basic question to be answered by researchers is whether this resorptive process is purely inflammatory in nature, activated by sulcular microorganisms, or alternatively a type of benign proliferative fibrovascular or fibro-osseous disorder in which microorganisms have no pathogenic role but may become secondary invaders. Current interpretations rely on an assessment of the clinical manifestations, behavioral characteristics and the available histopathological material, but a more accurate determination of the etiology of this disorder will require further molecular biological, enzyme histochemical or microbiological investigations.

Potential predisposing factors

Several potential predisposing factors have been identified and of these intra-coronal bleaching has been the most widely documented following the first report by Harrington and Natkin in 1979 (17) (for a review, see Heithersay et al. (18)). Trauma, orthodontics, orthognathic and other dentoalveolar surgery and

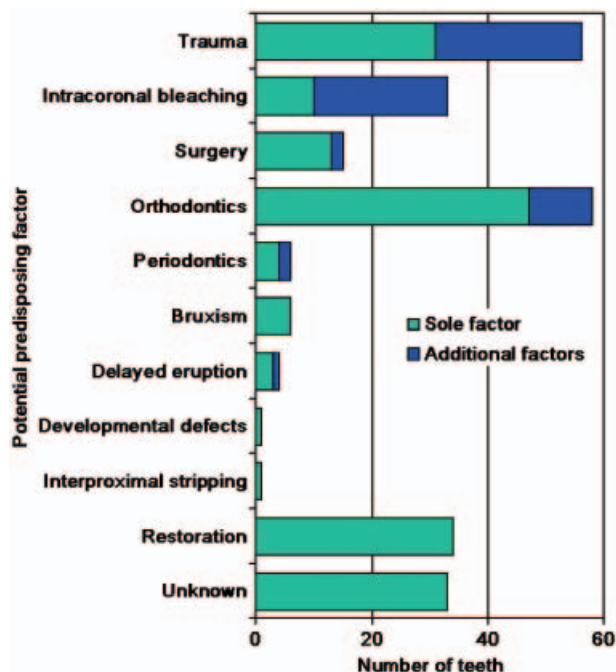


Fig. 1. Invasive cervical resorption: Distribution of potential predisposing factors for patients. From (20). Reproduced with permission from Quintessence Publishing.

periodontal treatment have also been cited (16, 19). A group of 222 patients with a total of 257 teeth displaying varying degrees of invasive cervical resorption have been analyzed by the author for potential predisposing factors (20) and the results are summarized diagrammatically in Fig. 1.

Figure 1 shows the number of subjects who had either a sole potential predisposing factor or a combination of factors. For example of the 33 patients (14.9%) who had a history of intra-coronal bleaching, 10 (4.5%) had bleaching as the sole factor, 17 (7.7%) a history of bleaching and trauma, 2 (0.9%) bleaching and orthodontics and 4 (1.8 %) a combination of bleaching, trauma and orthodontics.

Of the potential predisposing factors identified, orthodontics was the most common sole factor being identified in 47 patients (21.2%) with 62 affected teeth (24.1%), while other factors, principally trauma and/or bleaching, were present in an additional 11 patients (5%) with 11 affected teeth (4.3%). Trauma was the second most frequent sole factor with 31 patients (14.0%) with 39 affected teeth (15.1%). Surgery, particularly involving the cemento-enamel junction area was identified in 13 patients (5.9%) as a sole factor. Somewhat surprisingly periodontal therapy including deep root debridement showed a low incidence as did

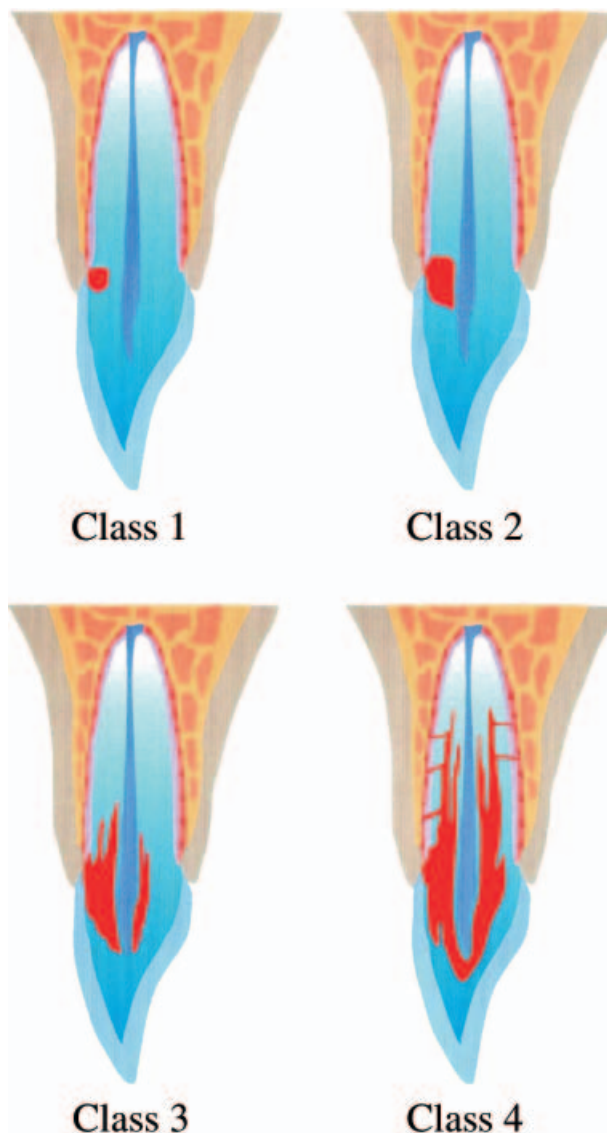


Fig. 2. Clinical classification of invasive cervical resorption. From (20). Reproduced with permission from Quintessence Publishing.

other factors such as bruxism. No potential predisposing factors could be identified in 33 patients (14.9%).

Clinical classification

A clinical classification has been developed by the author both for research purposes and also to provide a clinical guide in the assessment of cases of invasive cervical resorption (20). The diagrammatic representation of this classification is shown in Fig. 2.

- Class 1 – Denotes a small invasive resorptive lesion near the cervical area with shallow penetration into dentine.
- Class 2 – Denotes a well-defined invasive resorptive lesion that has penetrated close to the coronal pulp

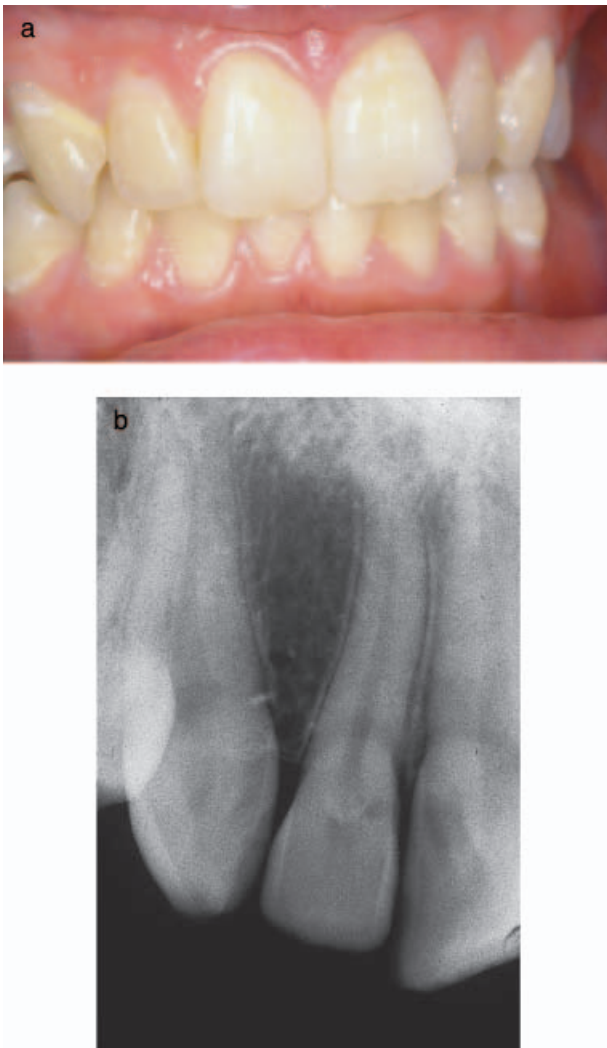


Fig. 3. (a) Labial surface of the dentition of a 19-year-old male. A slight reddish irregularity can be seen at the gingival margin of the maxillary right lateral incisor. (b) Radiograph of the maxillary right lateral incisor. A small radiolucency corresponds to the overlying lesion. From (1). Reproduced with permission from Quintessence Publishing.

chamber but shows little or no extension into the radicular dentine.

Class 3 – Denotes a deeper invasion of dentine by resorbing tissue, not only involving the coronal dentine but also extending into the coronal third of the root.

Class 4 – Denotes a large invasive resorptive process that has extended beyond the coronal third of the root.

Clinical, radiologic and histopathologic features

The clinical presentation of invasive cervical resorption varies considerably depending on the extent of the

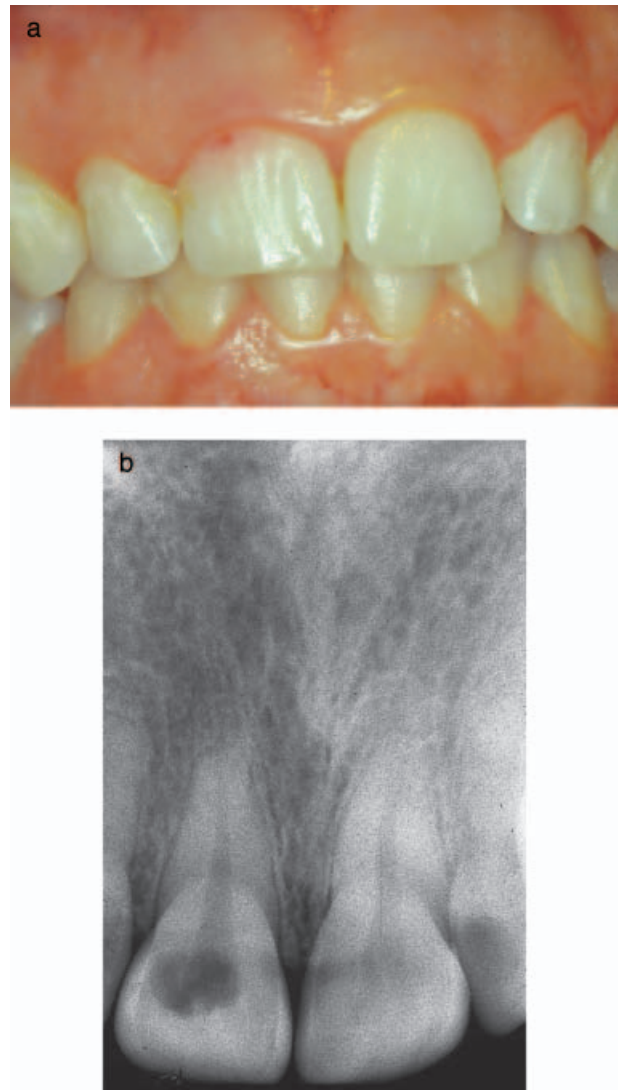


Fig. 4. (a) Labial view of the anterior teeth of a 28-year-old female who had received fixed orthodontic treatment 14 years earlier. The maxillary right incisor shows a pink discoloration near the gingival margin. (b) The radiograph of the maxillary right incisor reveals an irregular radiolucency overlying the root canal outline. From (20). Reproduced with permission from Quintessence Publishing.

resorptive process. The condition is usually painless and while a pink discoloration of the crown indicates the resorptive process, some teeth give no visual signs and diagnosis is usually the result of a routine or sometimes a chance radiologic examination. Multiple resorptions can occur, particularly when there has been a history of orthodontic treatment and a full mouth radiographic examination should follow the identification of any tooth showing evidence of invasive cervical resorption. The study of potential predisposing factors showed that the majority of patients presented at a Class 3 stage of

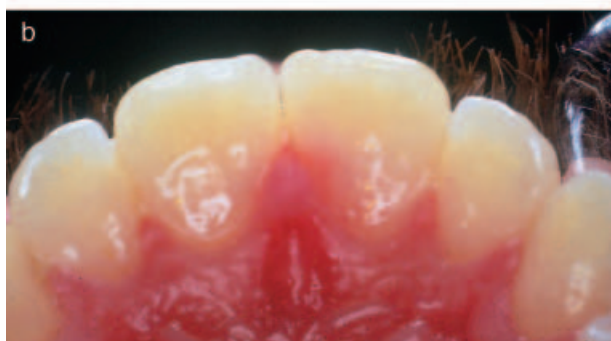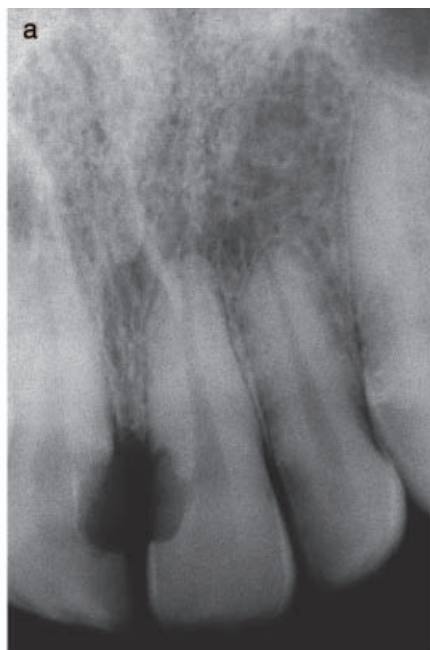


Fig. 5. (a) Radiograph of the maxillary central incisors of a 22-year-old male. Extensive radiolucent areas extend close to the pulp spaces. Although similar in appearance to carious lesions, the margins are somewhat irregular. The pulp space is bordered by a radiopaque line which is more evident in the right incisor. The invasive cervical resorptive lesion is classified Class 2. (b) Palatal surfaces of the maxillary central incisors. Pinkish area are visible near the mesial cervical regions, particularly evident in the right incisor. From (1). Reproduced with permission from Quintessence Publishing.

resorption, which is indicative of the diagnostic difficulties encountered with this resorptive process (20).

The following will outline the clinical, radiographic and histopathologic features of the four Classes of invasive cervical resorption as defined above.

Class 1

Some early lesions which are in this category may show a slight irregularity in the gingival contour associated with a

surface defect containing soft tissue which bleeds on probing (Fig. 3a). A radiograph will usually show a small coronal radiolucency corresponding to the lesion (Fig. 3b).

Class 2

Invasive resorptive lesions of this class may present with a pink discoloration of the tooth crown (Fig. 4a), while the radiographic image usually shows a surprisingly extensive irregular radiolucency extending from the cervical area into the tooth crown and projected over the root canal outline (Fig. 4b). If the lesion is proximally located the radiographic image will show a radiopaque line bordering the pulp space. An example can be seen in a radiograph of the maxillary central incisors of a 22-year-old male who had a history of extensive orthodontic treatment in his teens (Fig. 5a). While this image is similar to that of dental caries, it differs in that the outline is slightly more irregular. The clinical appearance of the palatal surface of this patient

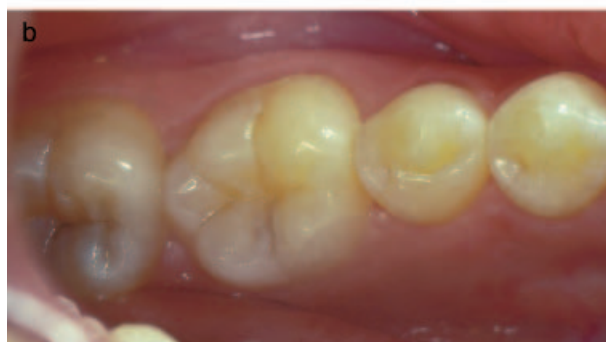
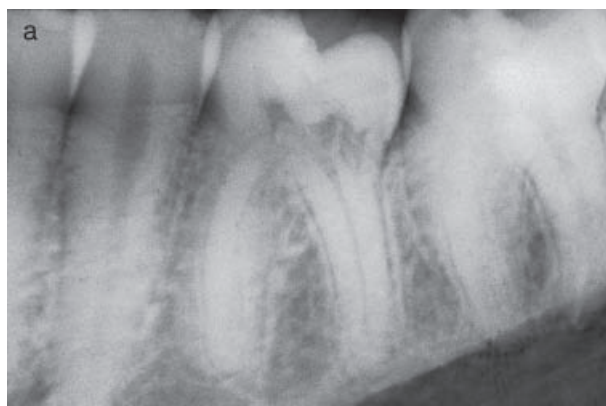
Fig. 6. (a) Radiograph of a mandibular left molar of a 17-year-old male. An irregular mottled radiolucency extends from the distal margin into the crown and adjacent to the pulp space but is separated by a radiopaque line. The invasive cervical resorptive lesion is classified as Class 2. (b) Crown of the mandibular left molar showing no external signs of resorption. From (1). Reproduced with permission from Quintessence Publishing.

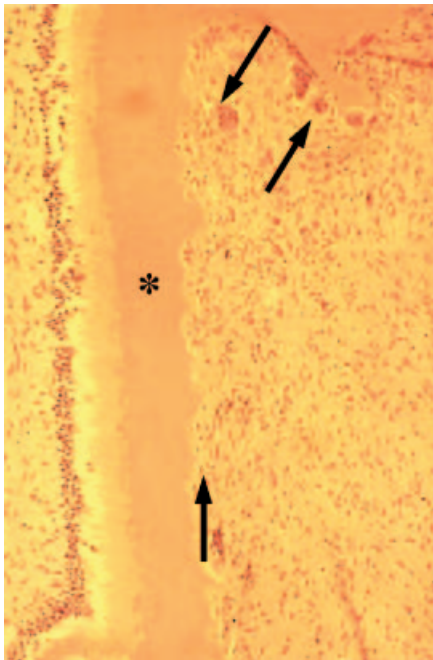


Fig. 7. Histologic appearance of an incisor tooth with invasive resorption. An intact layer of dentine and predentine on the pulpal aspect (*) separates the pulp from the resorbing tissue. The resorption cavity is filled with a mass of fibrovascular tissue with active mononucleated and multinucleated classic cells lining resorption lacunae (*arrows*). (Hematoxylin–eosin stain; original magnification $\times 40$). (Courtesy of Dr John McNamara.) From (1). Reproduced with permission from Quintessence Publishing.

is shown in Fig. 5b. Another example showing the diagnostically important radiopaque line of demarcation between the irregular and mottled image of the resorptive lesion and that of an apparently intact dental pulp can be observed in Fig. 6a, a mandibular first molar of a 17-year-old male who had received orthodontic treatment 3 years earlier. In this instance there was no external sign of the Class 2 resorptive lesion (Fig. 6b).

The histopathologic appearance of a Class 2 resorptive lesion in an incisor is shown in Fig. 7. This specimen shows the resorption cavity filled with a mass of fibrous tissue, numerous blood vessels and clastic resorbing cells adjacent to the dentine surface. A thin layer of dentin and predentin is present, separating the inflammation free pulp from the actively resorbing tissue, which is also devoid of acute or chronic inflammatory cells. The clastic cells observable at the dentin interface in this specimen are predominately mononuclear, but some multinucleated cells can also be seen.

The presence of the apparently protective predentin, dentin layer explains the asymptomatic nature of invasive cervical resorption at this stage and it could be

postulated that pulpitic symptoms only develop when the resorption ultimately penetrates through this barrier and is secondarily invaded by oral microorganisms. Evidence for the presence of an anti-invasion factor in predentin has been presented (21) and provides an explanation for this uniquely interesting protective barrier observed in this active form of tooth resorption.

Class 3

In this category the invasive resorptive process has radicular extensions into, but not beyond, the coronal

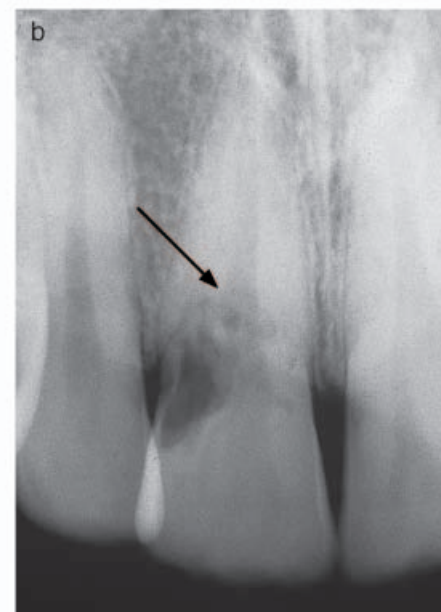
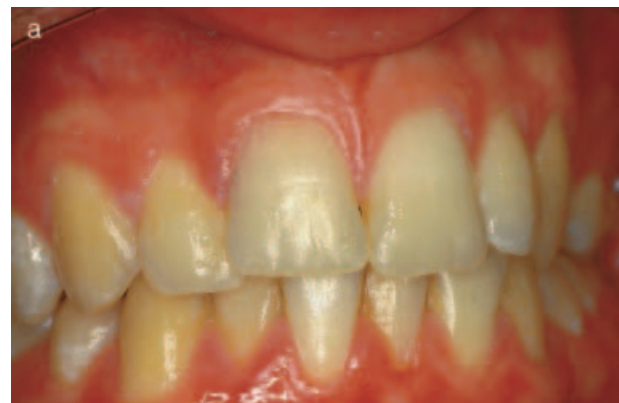

Fig. 8. (a) The maxillary right central incisor of a 24-year-old male shows a pinkish discoloration and slight cavitation near the disto-gingival margin. (b) Radiographic appearance of the maxillary right central incisor reveals an irregular ‘moth-eaten’ radiolucency on the distal aspect of the tooth extending to the outline of the root canal and into the root (*arrow*). The invasive cervical resorptive lesion is classified as Class 3.

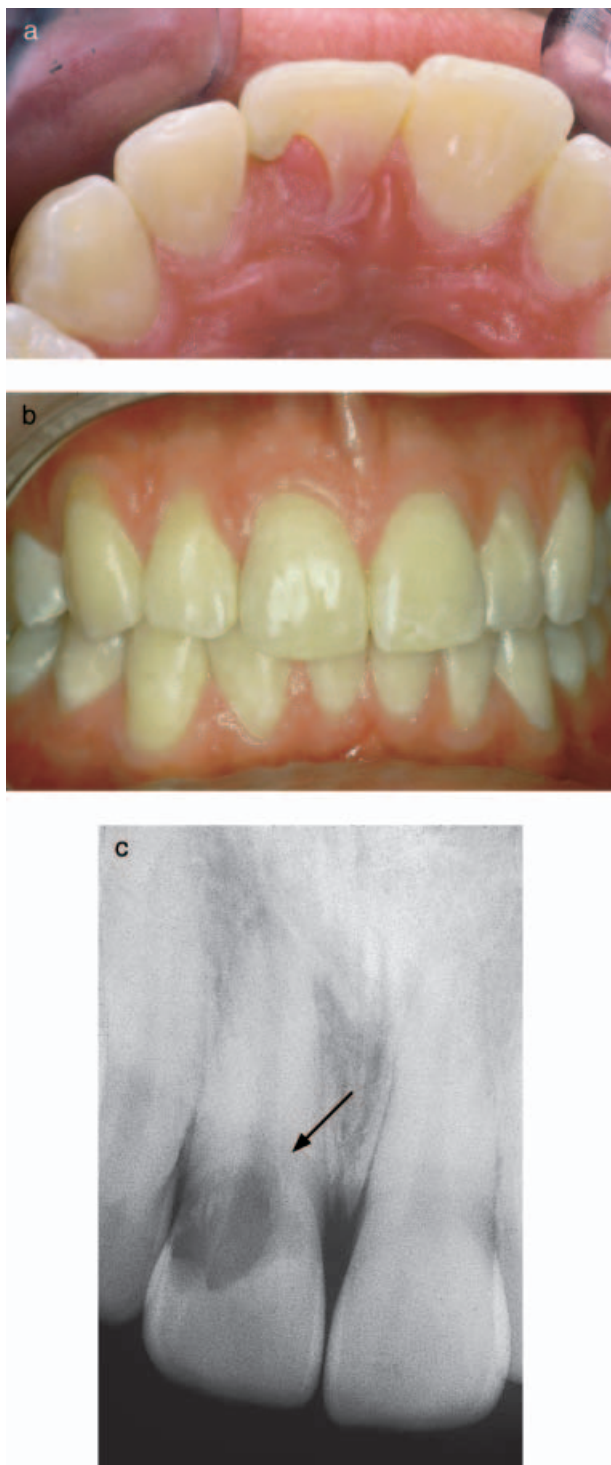


Fig. 9. (a) A mass of soft tissue is evident in a defect on the palatal aspect of the maxillary right central incisor of a 19-year-old male. (b) The labial surface of the patient's dentition shows no external sign of the palatal lesion in the maxillary right central incisor. (c) The radiograph of the maxillary right central incisor shows a large, irregular radiolucency extending both coronally and into the radicular tooth structure (*arrows*). This invasive cervical resorptive lesion is classified as Class 3. From (23). Reproduced with permission from Quintessence Publishing.

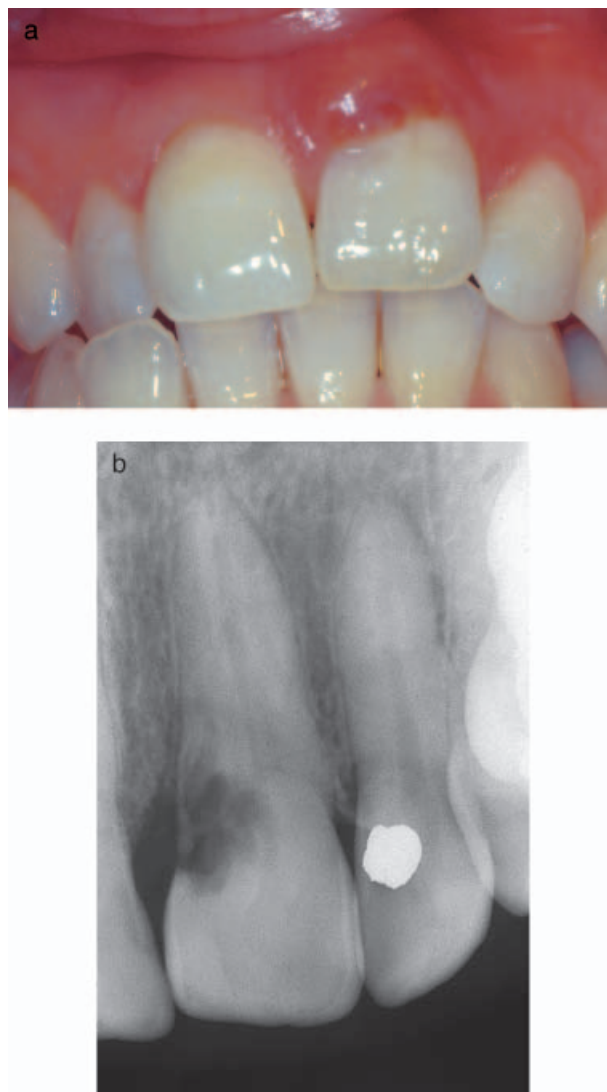


Fig. 10. (a) A labial view of the anterior teeth of a 35-year-old female shows evidence of gingival infection and a pinkish discoloration on the cervical aspect of the maxillary left central incisor. (b) The radiograph of the maxillary left central incisor shows an irregular radiolucency extending coronally and into radicular tooth structure. There is evidence of crestal bone loss.

third of the root. Clinically, the crown of an involved tooth may show a pink discoloration, and there may be cavitation of the overlying enamel. Figures 8a and 9a show degrees of enamel cavitation in two Class 3 cases, the first a 24-year-old-male whose maxillary anterior teeth had been hit by a cricket ball approximately 9 years earlier and the second, a 19-year-old male who had received orthodontic treatment at age 12. In these examples, the teeth were asymptomatic and it was only the changed appearance in the first case and an altered

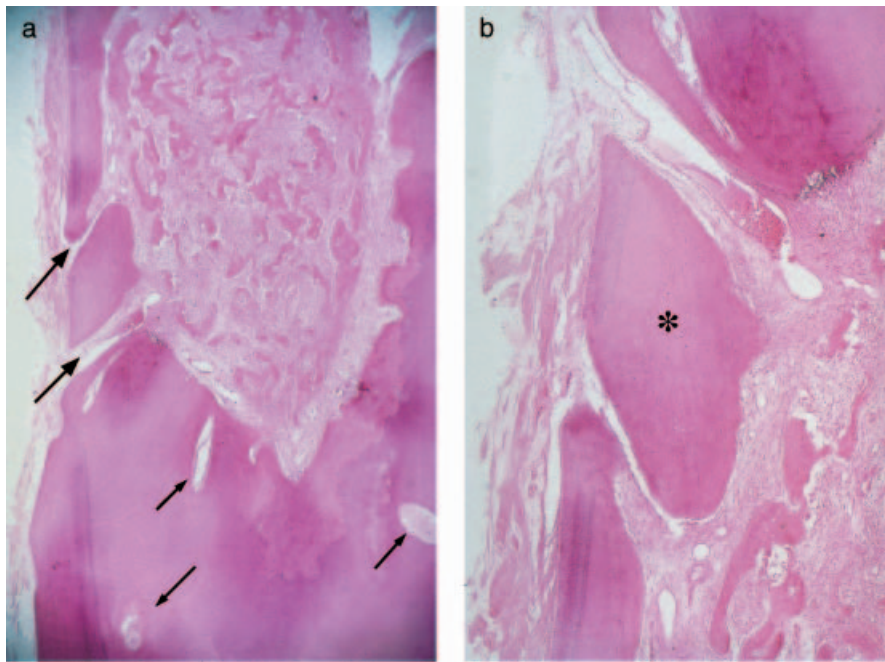


Fig. 11. (a) Histologic appearance of an extensive invasive cervical resorption with radicular extensions. Masses of ectopic calcific tissue are evident both within the fibrovascular tissue occupying the resorption cavity and on resorbed dentin surfaces. In addition, communicating channels can be seen connecting with the periodontal ligament (*large arrows*). Other channels can be seen within the inferior aspect of the radicular dentine (*small arrows*). (Hematoxylin-eosin stain; original magnification $\times 30$.) (b) Higher magnification of (a) showing communication channels from the periodontal ligament to the resorbing tissue. An island of hard tissue remains (*), consisting of an external surface of cementum and cementoid, some residual dentine but the bulk has been replaced with a bone-like material with canalicular structure. Although some red blood cells are evident near the deeper channel no inflammatory cells can be seen. (Hematoxylin-eosin stain; original magnification $\times 50$.) From (1). Reproduced with permission from Quintessence Publishing.

oral perception in the second that prompted dental examinations. Symptoms rarely occur in Class 3 cases unless there has been superimposed infection in the pulp or periodontium.

The radiographic appearance generally shows an irregular mottled, or 'moth-eaten' image in the main lesion area and the outline of the root canal can be seen as a radiopaque line demarcating the root canal from the adjacent irregular radiolucency, the latter being indicative of resorbing tissue. Figures 8b and 9c illustrate these radiographic features. In most instances in the study of 222 patients with 257 affected teeth referred to above, the radiographic appearance of the crestal bone remained unchanged except in a few instances where there was clinical evidence of superimposed infection of the adjacent periodontium. An example of a localized gingival infection associated with invasive cervical resorption can be seen in Fig. 10a, which shows the clinical appearance of a maxillary left central incisor of a 35-year-old female. A radiograph of

the tooth shows radiolucencies in both the tooth and the crestal bone (Fig. 10b).

The histopathologic appearance of a tooth displaying radicular extension of invasive root resorption is shown in Figs 11a, b. The radicular tooth structure shows an extensive resorptive defect containing a mass of fibro-osseous tissue, while at the base of the defect, bone-like tissue has been deposited on resorbed dentin. In addition, there are infiltrating channels containing soft tissue with communications with the periodontal ligament. The entire region is devoid of inflammatory cells, which is consistent with another specimen published by the author (22) and some previous observations (4-7). A cross-sectional view of a tooth with invasive cervical resorption is shown in Fig. 12. The intact pulp is surrounded by a complex network of fibro-osseous tissue which has replaced normal tooth structure. No inflammatory cells can be seen either in the pulp or within the resorption tissue. The walling off of the pulp space in this type of resorption is further

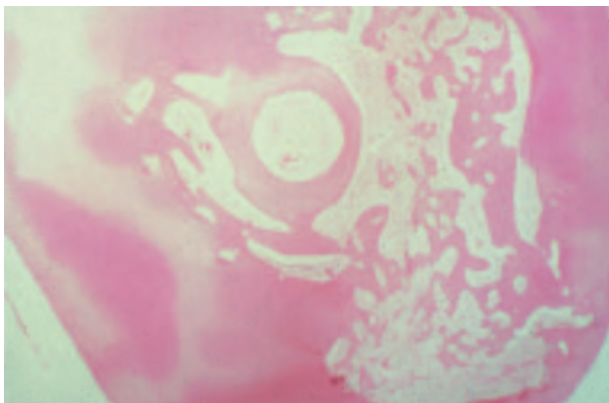


Fig. 12. Histologic appearance of a cross sectional view of an incisor tooth showing an intact pulp encircled by a narrow band of dentin and surrounded by an extensive resorptive lesion containing fibro-osseous tissue. (Hematoxylin and eosin stain. Original magnification $\times 10$).

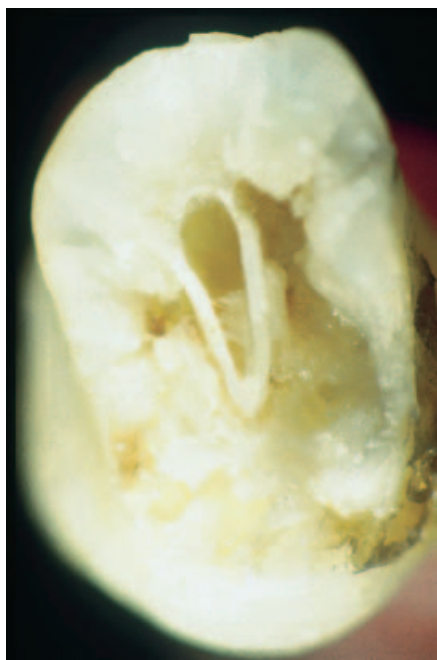


Fig. 13. A low-powered photograph shows the walling off of the pulp space by dentin separating it from the surrounding extensive resorptive process.

illustrated in Fig. 13, which shows a high magnification cross-sectional photograph of a tooth which has been subjected to extensive invasive cervical resorption.

There have been similar histopathologic observations in respect to the presence of irregular calcified deposits within the resorbed areas of teeth displaying invasive cervical resorption, but the presence of minimal to moderate inflammatory cellular infiltrates in some regions have been noted (7, 9, 19). This occurred in one of the two cases reported by Southan (7). A similar

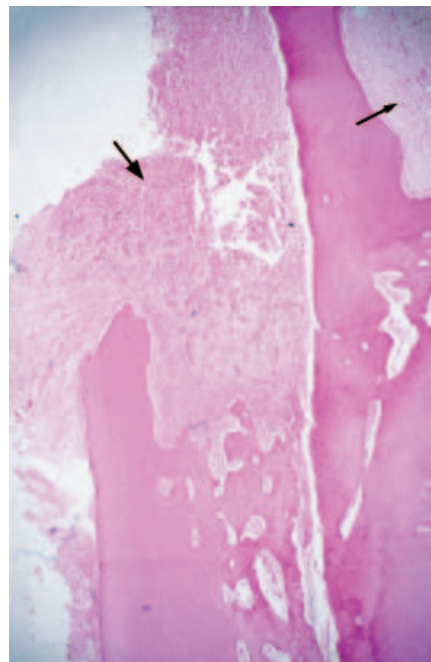


Fig. 14. Mass of fibrovascular tissue infiltrated with inflammatory cells, located within a large resorptive cavity that has a wide connection with the periodontal tissue (*large arrow*). The dentin has been extensively replaced by bone-like tissue. A small section of intact pulp can be seen on the superior aspect of the section (*small arrow*). Hematoxylin–eosin stain; original magnification $\times 30$.) From (1). Reproduced with permission from Quintessence Publishing.

infiltration of inflammatory cells into the resorptive tissue is shown in Fig. 14 taken from a tooth with a large invasive cervical resorptive lesion and an associated periodontitis. Some authors consider the resorptive tissue to be identical with other forms of progressive inflammatory root resorption, which are characterized by the presence of inflammatory cells, multinucleated clast cells, granulation tissue and resorption lacunae in both tooth and bone (13, 14).

Class 4

This category includes invasive resorptive processes that have extended beyond the coronal third of the root and an example is shown in Figs 15a, b: a maxillary left central incisor of a 28-year-old male who had a history of dental trauma some years earlier. While the crown displayed a pink discoloration in the cervical region, the radiograph shows, in addition to the irregular outline of the resorptive process in the tooth crown, radiolucent lines extending alongside the pulp space into the apical third of the root. In a further example of a

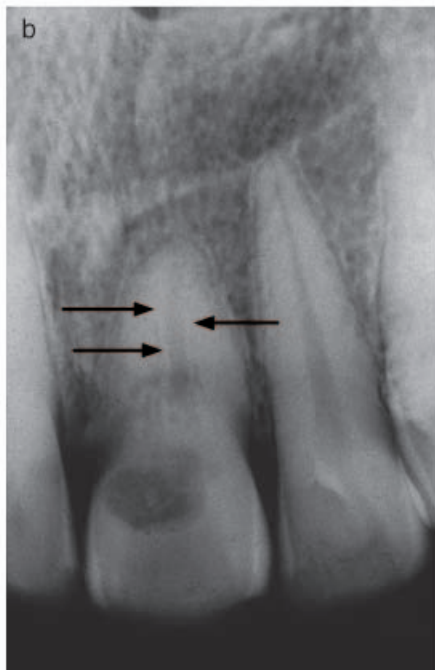
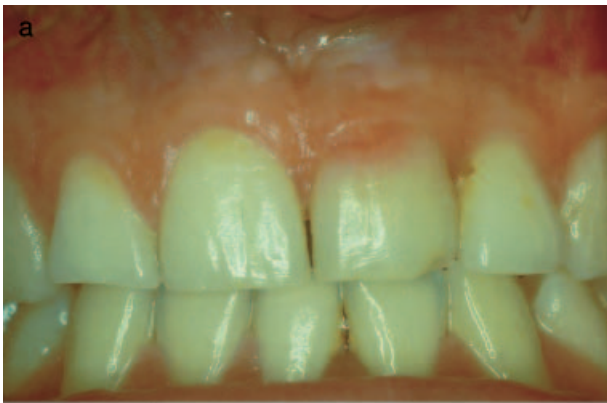

Fig. 15. (a) An extensive pink area can be seen in the cervical region of the maxillary left central incisor of a 28-year-old male. The adjacent soft tissues appear normal. (b) The radiograph of the maxillary left central incisor reveals a large coronal radiolucency and irregular radiolucent lines extending deeply into the root (*arrows*). The outline of the pulp space can be identified by radiopaque lines. This invasive cervical resorptive lesion is classified as Class 4. From (23). Reproduced with permission from Quintessence Publishing.

Class 4 resorption, overt signs and symptoms of an acute periodontal infection (Figs 16a, b) gave the first indication to the 38-year-old female patient of the extensive resorptive process that had developed in her maxillary left central incisor.

One histopathologic specimen of a Class 4 invasive cervical resorption is shown in Figs 17a, b a cross-sectional view of a maxillary incisor showing extensive

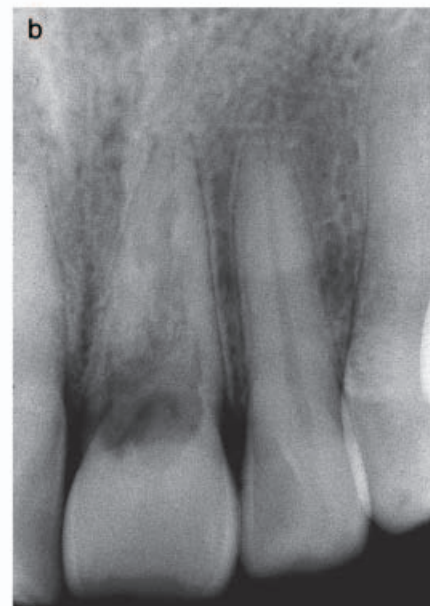
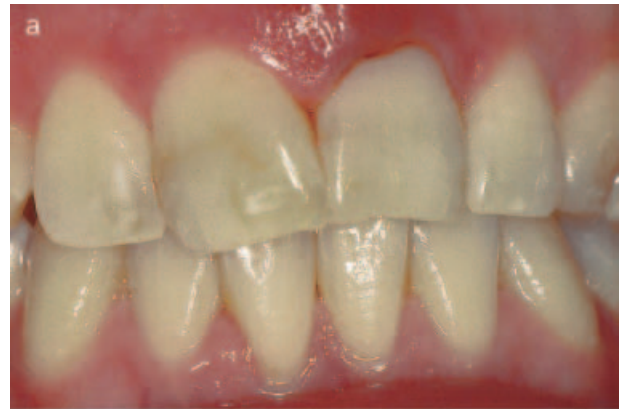
Fig. 16. (a) Maxillary left central incisor of a 38-year-old female. Infection involving the tooth and the periodontium is evidenced by local inflammation with exudation at the gingival margin. (b) Radiograph of the maxillary left central incisor. An extensive but diffuse, irregular radiolucency extends to the crown and deeply into the root (*arrows*). Areas of increased radiolucency appear near the cervical region, corresponding to the location of the periodontal infection. From (1). Reproduced with permission from Quintessence Publishing.

replacement of tooth structure including the dental pulp by bone-like calcified tissue, and spaces containing fibrovascular tissue. No inflammatory cells could be observed in this specimen, but they would be expected if infection were to supervene.

Clinical management

The clinical classification outlined above was developed both as a research tool and a practical guide to allow

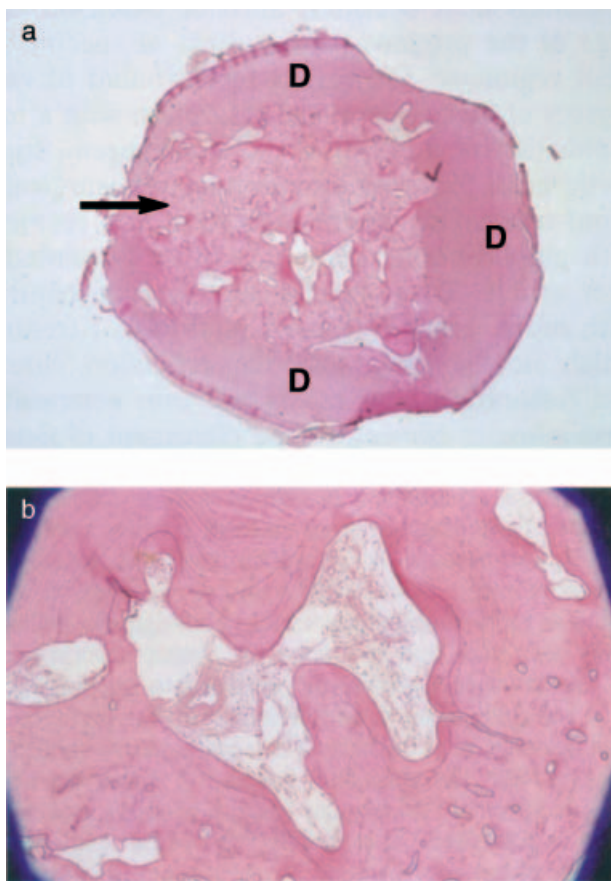


Fig. 17. (a) Cross-sectional view of an incisor tooth, showing complete replacement of the pulp space and surrounding dentin by bone-like tissue with spaces containing fibrovascular tissue. At the periphery, some cementum has also been resorbed (*arrow*). A residual scalloped band of dentin (D) and cementum remains elsewhere. (Hematoxylin–eosin stain; original magnification $\times 10$.) (b) Higher magnification of (a) showing the bone-like structure of the central radicular section. No recognizable pulp space is present, but there are irregular spaces containing fibrovascular tissue. Note the presence of many small concentrically located channels. (Hematoxylin–eosin stain; original magnification $\times 50$.) From (1). Reproduced with permission from Quintessence Publishing.

comparative assessments of the results of various non-surgical or surgical treatment regimens. Clearly as the pathological manifestations of the various classes of invasive cervical resorption become more complex, differing non-surgical or surgical treatment will be required. Nevertheless the basic aim remains the same, namely the inactivation of all active resorbing tissue and the reconstitution of the resorptive defect either by the placement of a suitable filling material or by the use of biological systems such as membranes, so that the tooth may be healthily and aesthetically retained.

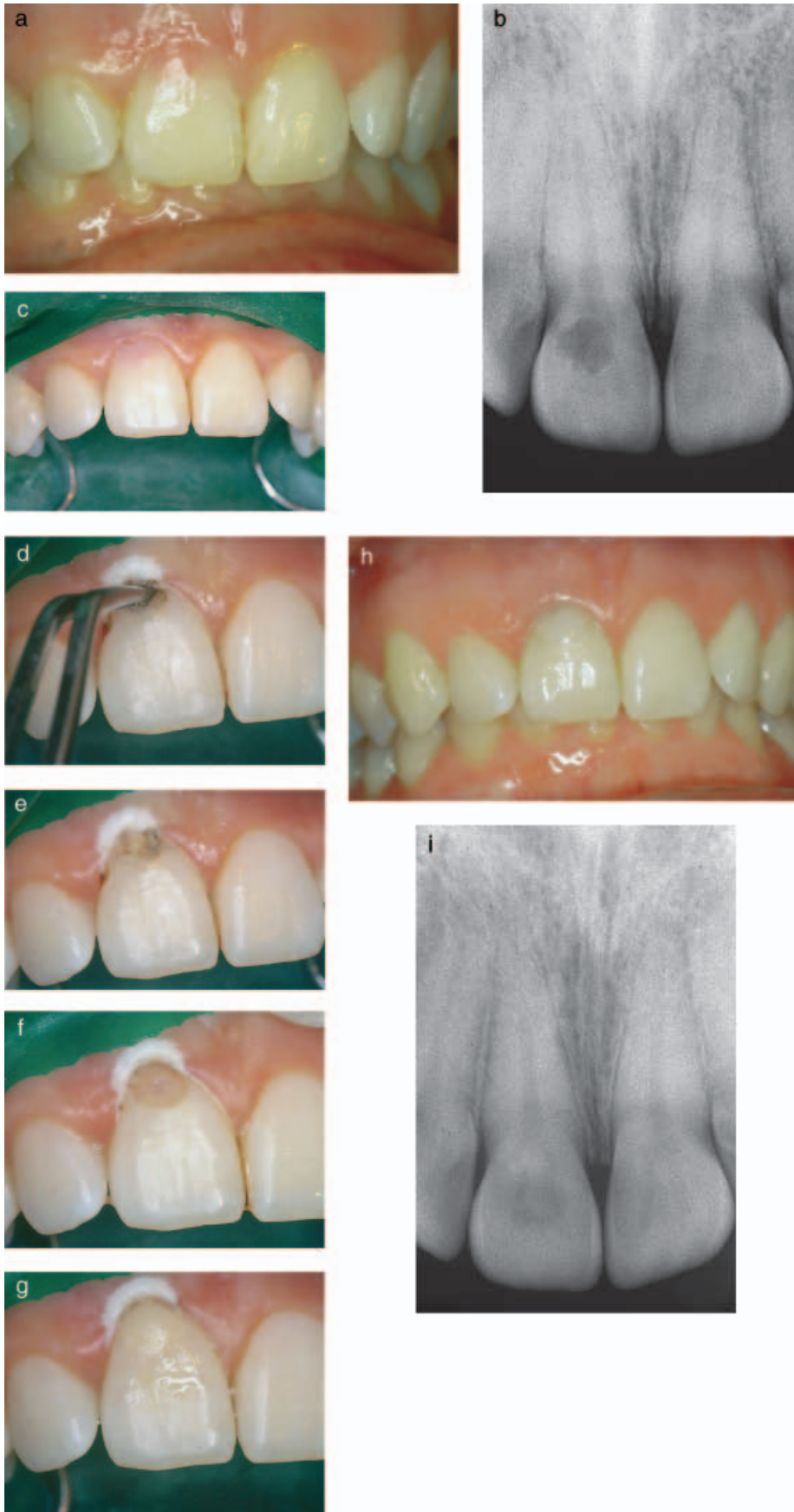
Non-surgical treatment

As a basis for discussion, a treatment regimen proposed by the author will be outlined along with the results of such treatment applied to 101 teeth from 94 patients displaying varying degrees of invasive resorption and followed up for a minimum of 3 years (23). The non-surgical treatment involved the topical application of a 90% aqueous solution of trichloroacetic acid to the resorptive tissue, curettage, endodontic treatment where necessary, and restoration with glass-ionomer cement. Adjunctive orthodontic extrusion was also employed in some advanced lesions. The following case reports illustrate this treatment regimen applied to a Class 2 and a Class 3 category invasive cervical resorption.

Illustrative Class 2 treatment

A 21-year-old female, with a history of dental trauma showed an invasive cervical defect in the coronal aspect

→
 Fig. 18. (a) The maxillary right central incisor of a 21-year-old woman shows a pink discoloration on the labial aspect of the crown. The tooth had been traumatized 9 years earlier. (b) A radiograph of the maxillary right central incisor reveals an irregular radiolucency overlying the root canal with no obvious extensions into the root canal. This invasive cervical resorptive lesion is classified as Class 2. (c) After a protective application of glycerol to adjacent soft tissue, a rubber dam ‘cuff’ has been placed for protection and isolation. This has been supplemented with a glycerol-impregnated cotton roll placed in the labial sulcus. (d) Trichloroacetic acid on a small cotton pellet is applied to the resorptive defect with slowly increasing pressure, so that the resorptive tissue within the cavity undergoes coagulation necrosis. (e) The appearance of the tissue within the resorptive defect following the application of trichloroacetic acid indicates tissue necrosis. The adjacent whitened gingival tissues indicate a limited zone of coagulation necrosis. (f) Following curettage of the avascular tissue from the resorption cavity, the glistening dentinal base of the cavity is revealed. The incisal margin of the cavity has been smoothed with high-speed bur under water spray. (g) A glass-ionomer restoration has been placed in the cavity, and its surface has been protected with a light-activated unfilled bonded resin. (h) Clinical appearance of the tooth 5 years postoperatively. The original glass-ionomer cement has been faced with a resin composite restoration. (i) A 5-year follow-up radiograph of the maxillary right central incisor shows no evidence of periapical pathosis or extension of the treated resorptive lesion. From (23). Reproduced with permission from Quintessence Publishing.



of her maxillary right central incisor which on clinical and radiographic grounds was classified as Class 2 (Figs 18a, b). After protective application of glycerol to adjacent soft tissues and the placement of a glycerol-impregnated cotton roll into the labial sulcus, rubber dam was applied using a cuff technique (Fig. 18c). A small cotton pellet (size 000 divided in half) which had been dipped into a very small quantity of a 90% aqueous solution of trichloroacetic acid and then dampened on gauze, was applied for 1-2 min with gentle pressure to the resorptive lesion which was accessible through an enamel defect near the gingival margin (Fig. 18d). The pressure was slowly increased as the medicament caused progressive coagulation necrosis of the resorptive tissue and there was a collapse of the thin overlying enamel (Fig. 18e). The devitalized avascular tissue was curetted from the resorption cavity, which was then carefully checked under magnification with an enhanced light source. This examination revealed an intact smooth dentine floor cavity with no communication with the dental pulp (Fig. 18f). The cavity margins were then smoothed with a high-speed tungsten carbide bur under water spray and the defect restored with a glass-ionomer cement, protected with a light-activated unfilled bonding resin (Fig. 18g). Follow-up examinations to 5 years did not reveal any evidence of pulpal or periapical pathology or continuation of the resorptive process, and the restoration and adjacent gingival tissues were assessed as most satisfactory (Figs 18h, i).

If there had been obvious pulp involvement on removal of the resorptive tissue, pulpectomy would have been carried out accessing the canal via the resorption cavity to retain as much residual tooth structure as possible. A similar treatment regimen to

the illustrative Class 2 case shown above can be applied to a Class 1 category of invasive cervical resorption.

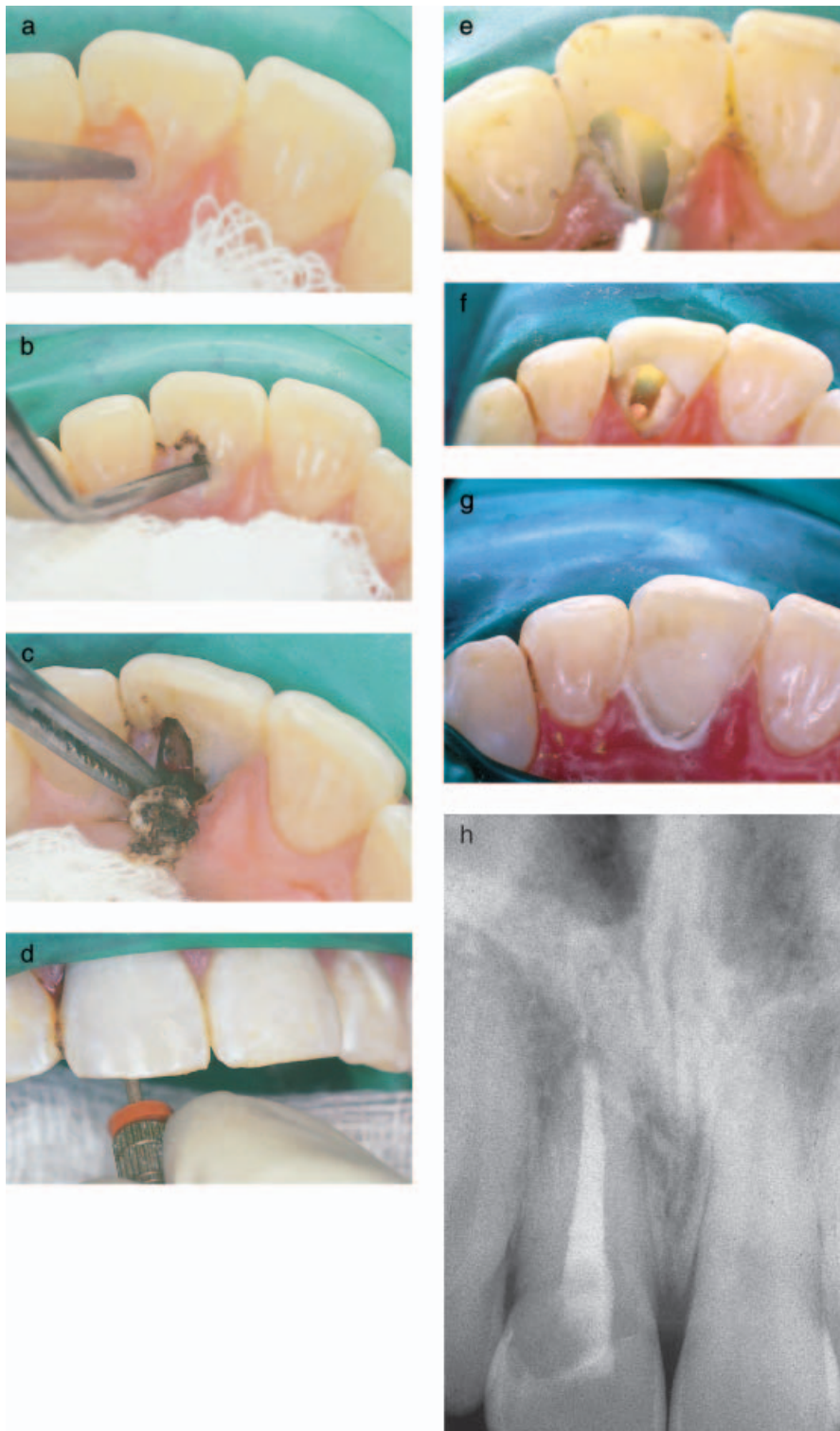
Illustrative Class 3 treatment

The maxillary right central incisor of the 19-year-old male shown earlier in Figs 9a, b & c was treated following the preparation and protection procedures outlined for the illustrative Class 2 case. Trichloroacetic acid was applied on a small cotton pellet to the resorptive tissue on the palatal aspect of the tooth for approximately 3 or 4 min (Fig. 19a): the medicament was replenished on at least two occasions, and the pressure on the cotton pellet was slowly increased as the tissue within the resorption cavity became progressively avascular due to a process of coagulation necrosis (Fig. 19b). In this way, the majority of the coronal component of the resorption cavity could be accessed and then simply removed by curettage (Fig. 19c). Although an apparently sound base was present, elective pulpectomy was carried out to allow access to the more deeply infiltrating tissue encircling the root canal (Fig. 19d). The canal was prepared with hand instruments and then enlarged with Gates–Glidden drills particularly in the coronal third of the root canal to engage the encircling resorptive tissue. Further application of trichloroacetic acid and curettage allowed complete visualization of the resorption defect with the aid of 5.5 magnification and a focussed helium light source (Fig. 19e). The canal was then dressed with a corticosteroid, antibiotic paste (Ledermix paste; Lederle Pharmaceuticals, Wolfratshausen, Germany), a therapeutic combination which has been shown to exhibit anti-clastic activity (24–26),

Fig. 19. (a) The topical application of trichloroacetic acid on a small cotton pellet is carried out with slowly increasing pressure to prevent haemorrhage. (b) Continued application of trichloroacetic acid on a small cotton pellet with pressure allows the deeper regions of the lesion to be rendered avascular by the process of coagulation necrosis. (c) The affected tissue is curetted from the resorptive cavity to reveal the apparent dentinal base. (d) Elective pulpectomy is carried out in the central incisor, to allow access to encircling resorptive tissue. (e) Following pulpal extirpation, the canal has been enlarged in the coronal third with Gates–Glidden drills to exclude any resorptive tissue surrounding the root canal. Topical application of trichloroacetic acid has allowed tissue destruction in the resorptive cavity, which has then been thoroughly curetted. (f) The root canal has been sealed with gutta-percha and AH26 18 days after pulpectomy, intracanal dressing with Ledermix paste, and coronal sealing with Cavit. The gingival tissue show good healing and the margins of the resorption cavity are well defined. (g) A glass-ionomer restoration has been inserted into the resorption cavity following a further topical application of trichloroacetic acid to aid in moisture control. (h) The postoperative radiograph of the maxillary right central incisor indicates satisfactory filling of the resorptive defect. (i) The labial appearance 10 years after treatment shows a satisfactory aesthetic result. (j) After 10 years, the palatal gingival tissues appear healthy. The original glass-ionomer restoration has been refaced because of some surface creasing. (k) A 10-year follow-up radiograph shows no evidence of further resorption or periradicular pathology. From (23). Reproduced with permission from Quintessence Publishing.

and the defect was temporarily restored with Cavit (3m ESPE, Seefeld, Germany). At a subsequent appointment, 18 days later, the temporary filling and intra-canal dressing material were removed by irrigation and sonication. After the canal had been dried, careful

inspection with enhanced vision did not reveal any sign of further vascular channels, the resorption cavity was well defined and the adjacent soft tissues showed satisfactory healing (Fig. 19f). The canal was then obturated with gutta-percha and AH26 (Dentsply/



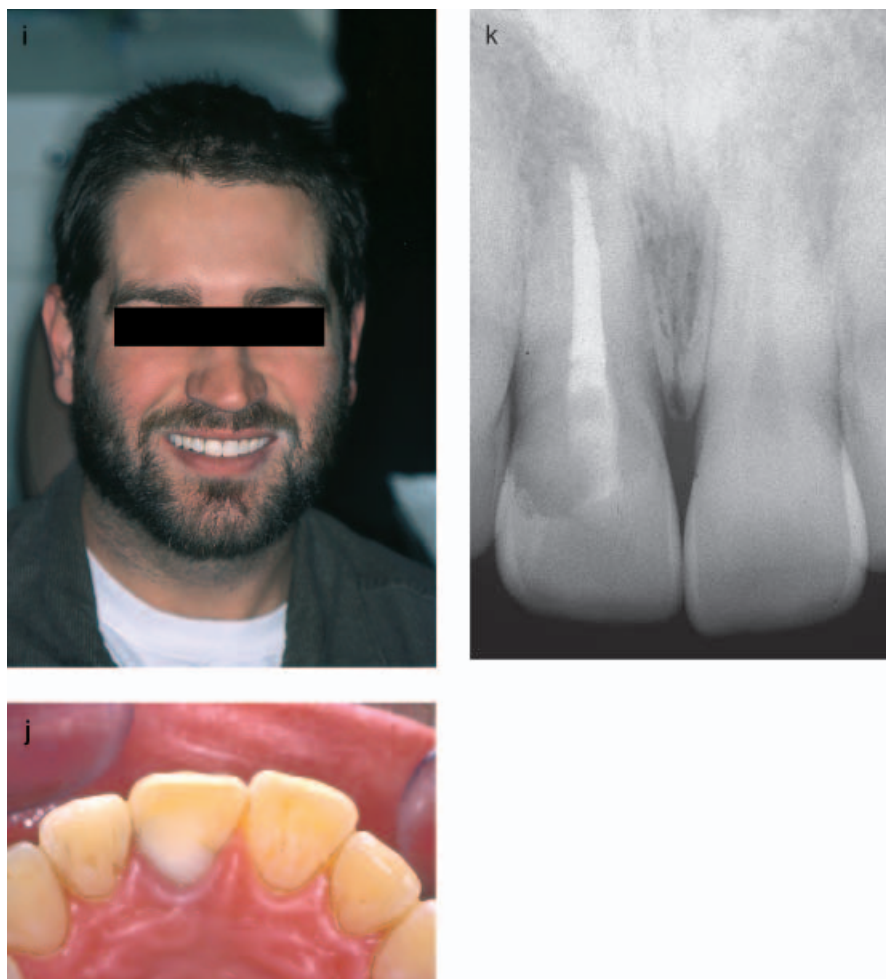


Fig. 19. (Continued)

DeTrey, Konstanz, Germany). A further brief application of trichloroacetic acid ensured a dry field for the insertion of a glass-ionomer cement restoration which was protected with a light-activated unfilled bonding resin (Fig. 19g). The patient has been re-examined at regular intervals and the clinical and radiographic appearance of the tooth 10 years after treatment are shown in Figs 19h–j.

Orthodontic extrusion can be used to advantage in some Class 3 resorptions by improving access to the base of the resorption cavity and providing a supra-gingival margin for the restoration (27–30). Extrusion is usually effected over 4–6 weeks, using a light wire technique, and this is followed by splinting, pericision, gingivoplasty and finally restoration.

An internal approach is possible in some Class 3 resorptions but it is essential that the resorptive tissue be traced to the external point (or points) of entry and inactivated by the topical application of trichloroacetic

acid prior to the internal placement of a glass-ionomer cement. Alternatively, the defect could be filled with the mineral trioxide aggregate material, Pro-Root MTA (Dentsply Tulsa Dental, Johnson City, TN, USA), which would appear to possess ideal properties for this type of repair (31, 32).

The results of the study of the treatment of 94 patients with 101 teeth affected by various degrees (Classes 1–4) of invasive cervical resorption showed complete success in Class 1 and Class 2 resorptions, judged by an absence of resorption and periradicular or periapical pathology. The follow-up periods for the Class 1 cases varied from 3 to 8 years (mean 4.5 years) and Class 2 cases varied from 3 to 12 years (mean 8 years). Of the 63 teeth classified with Class 3 invasive cervical resorption, 61 (96.8%) showed resorption control. Five teeth (7.9%) had been extracted during the review period, which varied from 3 to 12 years (mean 5.5 years), 1 (1.6%) because of continuing root

resorption, 3 (4.7%) because of root fracture and 1 (1.6%) because of previous traumatic bone loss. The mean survival time of the teeth which had been extracted was 5.8 years. The gingival response was clinically satisfactory in 59 teeth (93.7%), but there was evidence of some angular bone loss in 4 teeth (6.3%) and small periapical radiolucencies were observed in 5 teeth (7.9%). When all factors (resorption control, angular bone loss, periapical changes and extraction) were included in the assessment, the overall success rate of Class 3 treatments was 77.8%. Endodontic retreatment of the five cases with evidence of periapical pathology and orthodontic extrusion and periodontal management of the four cases with angular bone loss may have enhanced this success rate.

In Class 4 resorptions 16 teeth were treated and the results showed a survival rate of 50.0% and a success rate as judged above 12.5%. This represents an unsatisfactory outcome for this treatment regimen when applied to Class 4 resorptions, and alternative prosthodontic replacement is generally suggested. However, there are occasions when treatment may be justified, provided it does not compromise supporting bone. Orthodontic extrusion is invariably required as an adjunctive treatment if a successful result is to be achieved. Another option in some cases of Class 4 invasive cervical resorption is to leave the affected tooth untreated; however, this may put at risk the health of the supporting bone as a site for implant placement should superimposed periodontal infection develop. The rate of resorption in Class 4 cases has not been investigated but clinical observations suggest that in the absence of superimposed infection, the progress in older patients is slow.

A non-surgical approach for some resorptions has been suggested by Frank (33) who pioneered many of the early clinical studies of this type of resorption. When the resorption was intra-osseous, Frank emphasized the importance of the removal of all resorptive tissue to what he termed the portal of entry. This was carried out with a large round bur and the cavity was then filled with amalgam.

Surgical management

Surgical treatment of varying degrees of invasive cervical resorption has generally involved periodontal flap reflection, curettage, restoration of the defect with amalgam (10, 11, 16, 34), composite resin (8, 35) or

glass-ionomer cement (8, 22) and repositioning the flap to its original position. Periodontal reattachment cannot be expected with amalgam or composite resin, and is unlikely with glass-ionomer cement, but there is experimental evidence to suggest that this might be possible should MTA be used in this situation (31, 32). An alternative surgical option is to apically position the flap to the base of the resorption repair: However, should this prove aesthetically unacceptable, orthodontic extrusion can be utilized to improve the gingival contour (36).

Rankow has developed innovative treatment methods that utilize a Gortex membrane (W.L. Gore Inc., Elkton, MD, USA) for guided tissue regeneration in various forms of endodontic surgery, including (invasive) cervical resorption (37). In one such case in which the gingival attachment was intact, flap reflection allowed the resorptive lesion to be accessed from the buccal aspect. Following curettage, pulpectomy and root filling of the canal apical to the resorptive defect and composite filling of the coronal access cavity to the level of the defect, a Gortex membrane was placed without any restoration of the resorption cavity. The Gortex membrane was removed after 6 weeks. A follow-up radiograph taken 4 years after this treatment showed evidence of resorption control and no sign of periradicular pathology. Other surgical treatment strategies have recently been outlined including other resorption cases treated using a guided tissue regeneration technique (38).

Discussion

Invasive cervical resorption is a relatively uncommon and clinically challenging condition with an academically debatable pathogenesis. The invasive and somewhat aggressive characteristics of the process, coupled with its histopathologic features, raise questions as to the nature of the lesion. The invading tissue arises from the periodontal ligament but differs from periodontal tissues in both structure and behavior. The precursor cells of the periodontal ligament, being ectomesenchymal in origin, have the potential to differentiate into cells capable of laying down fibrous tissue or calcified tissue (39). For invasion to occur, a defect in the cementum/cementoid layer is a likely prerequisite (7, 40, 41). This may be of developmental origin in a small zone near the cervical area, or the result of physical or chemical trauma. Such a cementum–cementoid

deficiency allows direct contact between dentin and the potentially resorptive cells of the periodontium.

What then causes the activation of resorption and the invasion of this fibrovascular/fibro-osseous tissue? There is one body of opinion that considers sulcular microorganisms to be the activating factors (12, 13, 15, 16, 19). A hypothesis has been advanced to support this etiology and to explain the delayed nature of this process which occurs in some patients. The hypothesis suggests that an inflammatory process in the periodontium at the attachment level does not reach a damaged root surface initially, and that it is only with eruption of the tooth or gingival recession that inflammatory mediators can attract resorbing cells to the root surface (19). Some of the limited published histopathologic material showing inflammatory cellular infiltrates may provide support for this opinion and hypothesis (7, 9, 19).

Nevertheless, there are contrary arguments. The presence of inflammatory cells is not necessarily indicative of a microbiological etiology and there are cases in the literature, which show no inflammation (1, 5, 7, 42). These cases, coupled with the clinical manifestations, indicate that invasive cervical resorption is an aseptic resorptive process, which may on occasions become secondarily invaded with microorganisms.

The reason for an apparent varying lag phase of months to years between a particular insult to the root surface at or near the cemento-enamel junction and the development of invasive cervical resorption remains conjectural. A simple clinical explanation may be that early lesions are not being detected because of inherent difficulties in diagnosis, and their detection at a later stage gives a false impression of a lag time. This was evident in the clinical study of 222 patients where only six patients were diagnosed at a Class 1 stage, while the majority were detected at the relatively advanced Class 3 stage. (20) In addition, the clinical study did not show significant clinical evidence of gingival recession, marginal gingivitis or periodontitis in the majority of patients presenting with various degrees of invasive cervical resorption, contrary to the periodontal infective hypothesis advanced above. Nevertheless, the hypothesis does provide a logical explanation for secondary or superimposed infection of an established lesion as illustrated in the two cases shown in Figs 10a, b and 16a, b. Operative procedures have also been reported as a potential cause of secondary bacterial invasion of these lesions (1).

There may be a non-bacterial explanation for this resorptive process involving a breakdown in an anti-resorptive biologic control mechanism originating in the periodontal ligament and possibly exerted by epithelial cells of the rests of Malassez (43–45). Recent research into clastic cell activity in a model of aseptic root resorption provides additional support for the progression of resorption in the absence of periodontal epithelial rests (46).

It appears that all types of dental resorption share common cellular mechanisms. Resorption of teeth results from the activation of clastic cells, termed odontoclasts, which are morphologically similar, if not identical, to osteoclasts. The structure and function of osteoclasts has been extensively studied and reviewed (47–49). Certain features of dental resorption appear to be common to all the different types. Over recent years, there have been significant advances in the understanding of osteoclast differentiation and activation due to the analysis of a number of factors involved in a RANK (receptor activator of nuclear factor κ B) signalling network in osteoclasts. The factors which have been analyzed include a family of biologically related tumor necrosis factor (TNF), tumor necrosis factor receptor (TNFR)/TNF-like proteins: osteoprotegerin (OPG), RANK and RANK ligand (RANKL) which collectively regulate osteoclast function (49). This system may be activated following physical, chemical or microbiological insults or by a post-zygotic gene (50).

Classical external inflammatory (infective) root resorption has been studied extensively and usually follows tooth luxation or avulsion where there has been cemental damage and pulp necrosis with bacterial invasion (51). The osteolytic inflammatory response to the bacterial products, which pass from the pulp space to the external surface of the root involves the activation of clast cells resulting in resorption of both tooth and bone. This type of resorption is radiographically recognizable as bowl-like radiolucencies in both the involved tooth and the adjacent bone. An example can be seen in Fig. 20 that shows a maxillary central incisor, which had been avulsed and replanted 6 months earlier. The histopathological appearance of a tooth exhibiting external inflammatory root resorption is shown in Fig. 21. Observable features include the presence of multinucleated clast cells at the dentin and bone interface, chronic inflammatory cellular infiltrates, and the scalloped appearance of the resorbed dentin and bone.

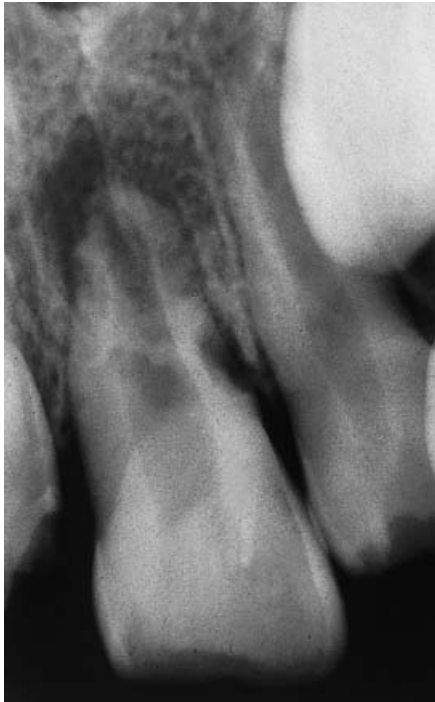

Fig. 20. Radiograph showing evidence of extensive external inflammatory root resorption in a 9-year-old female whose avulsed maxillary left central incisor had been replanted 6 months earlier. She had unfortunately failed to attend follow-up examinations.

There appear to be differences in the behavior, pathology and radiographic features of many cases of invasive cervical resorption to that of the classically described external inflammatory root resorption. In invasive cervical resorption, the pulp survives until late in the resorptive process, being protected by a layer of predentin and dentin, while the pulp is necrotic and infected before external inflammatory root resorption occurs. The progressive resorption in invasive cervical resorption is characterized by the ingrowth of fibrovascular tissue in the early stages and later by fibroosseous tissue, which is also laid down on the resorbed surface of dentin. Resorption channels are created which burrow into dentin and may interconnect with the periodontal ligament. While areas of both resorption and hard tissue repair can be observed in some cases of external inflammatory resorption, the other fibro-osseous responses seen in invasive cervical resorption appear to be unique to this external, periodontally derived tooth resorption.

Invasive cervical resorption was classically described by Wade in 1960 as one in which there were alternating periods of resorption and repair with ultimately the

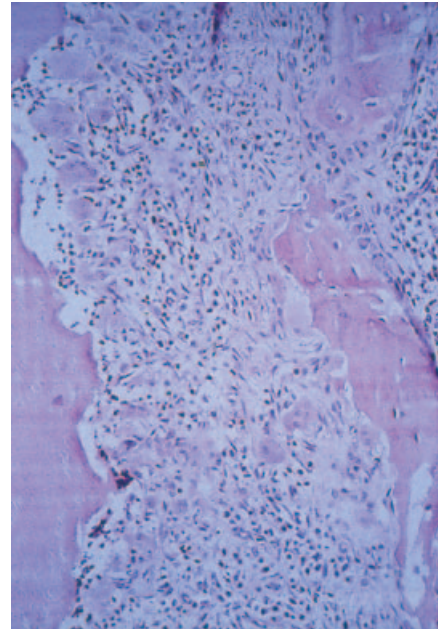


Fig. 21. Histologic appearance of a tooth exhibiting external inflammatory root resorption, showing multinucleated clast cells adjacent to resorbed dentin and bone. A chronic inflammatory cellular infiltrate is also evident in the area. (Hematoxylin and eosin stain. Original magnification $\times 50$.) (courtesy Dr Angela Pierce.)

former outstripping the latter (5). This author also suggested that the process was similar to that found in fibrous dysplasia of bone and, as such, could be regarded as fibrous dysplasia of the tooth. There are indeed similarities between the histopathologic appearance of invasive cervical resorption and that of fibrous dysplasia of bone, giving support to this early concept. Fibrous dysplasia of bone is gene related and classified by the World Health Organisation as a tumor-like lesion (52). In view of the histopathology and behavioral characteristics of invasive cervical resorption, it is suggested that the condition could be labelled as a progressive fibrous or fibro-osseous disorder of teeth.

The radiographic interpretation of invasive cervical resorption is critical to diagnosis and treatment. It is important to differentially diagnose this externally derived resorption from that of internal root canal inflammatory resorption and internal root canal replacement resorption as defined by Andreasen and Andreasen (53). Internal root canal inflammatory resorption can be identified as a uniform enlargement of the root canal. Internal replacement resorption is more difficult to diagnose from external invasive cervical or radicular resorption because the resorptive

tissue has the same histopathologic characteristics and accordingly, has a similar radiographic appearance. Although the lesion has been classified as a form of internal root canal resorption, there has been experimental evidence to suggest the resorbing tissue is also derived from the periodontal ligament (54). In the case of internal replacement resorption, there is an absence of the radiopaque line of demarcation between the root canal and the image of resorption in dentin.

Invasive cervical resorption has often been diagnosed in the past as internal resorption. In 1971 the suggested pathogenesis of some 'internal' resorptive lesions, which clearly had external connections, was an extension of a pulpally derived internal resorption to involve the periodontal ligament (55). Later, a landmark study carried out by Makkes and Thoden Van Veltzen (9) demonstrated an external periodontal source for (invasive) cervical root resorption.

While the exact nature of this interestingly complex pathological process remains debatable, the treatment of invasive cervical resorption poses particular clinical problems. The aggressive nature of this type of resorption varies, and despite apparent complete removal of the resorptive tissue, in some cases it may recur. This may be due to the development of new resorption adjacent to or remote from the original site. Alternatively, there may be a concurrence or continuation of the resorption due to incomplete inactivation of resorptive tissue particularly in the deeply penetrating channels which are a feature of this type of resorption.

The rationale for the topical application of trichloroacetic acid in the treatment of these resorptive lesions was to utilize the proven action of this chemical agent in inducing coagulation necrosis while adjacent tissues remain free of inflammation (42). It was anticipated that this chemical agent would affect not only the resorptive tissue in the body of the lesion, but also the tissue contained in the deeper and often interconnecting channels. The results of the clinical study in which trichloroacetic acid was used as an agent in the treatment of various degrees of invasive cervical resorption (23) can at least provide a basis for comparison with other treatment modalities, which to date have only been detailed in a series of case reports with follow-up periods varying from a few months to a maximum of 10 years (56).

Guided tissue regenerative techniques are attractive treatment alternatives but further clinical research is desirable to assess the overall success of these and other

regenerative methods. Another possible avenue of treatment involves the application of a combination of Emdogain (Biora, AB Malmo, Sweden) and Bio-oss (Osteohealth, Luitpold Pharmaceuticals, Shirley, NY, USA), which has been used to apparent advantage in regeneration of some localized periodontal lesions with bone loss (57, 58). The technique has the advantage that a membrane is not required. The topical application of bisphosphonates, anticlastic agents used in the treatment of osteoporosis, may offer another possible therapy.

Fortunately, invasive cervical resorption is a relatively uncommon condition but for patients affected by this pathological process, it can cause great concern. Identification of potential predisposing factors may allow some preventive measures to be implemented, but hopefully further research into the etiology and pathogenesis of this resorptive process will provide the basis for improved methods of treatment. Invasive cervical resorption also occurs in cats, and as similar clinical, radiologic and histopathologic features have been reported (59, 60), there may be the possibility for other avenues of research into this challenging pathological condition.

Acknowledgements

The author wishes to acknowledge Quintessence International for their permission to reproduce figures from his original publications in that Journal. In addition he wishes to thank Helen Heithersay, Dr Angela Pierce, and Dr Fabrizio Damiani for their valued help in the preparation of this paper.

References

1. Heithersay GS. Clinical, radiologic, and histopathologic features of invasive cervical resorption. *Quintessence* 1999; **30**: 27–37.
2. Gaskill JH. Report of a case of internal resorption. *Dental Cosmos* 1894; **36**: 1019–1024.
3. Mummery JH. The pathology of 'pink spots' on teeth. *Br Dent J* 1920; **41**: 301–311.
4. Fish EW. Benign neoplasia of tooth and bone. *Proc R Soc Med* 1941; **34**: 427–432.
5. Wade AB. *Basic Periodontology*. Bristol, England: Wright @ Sons, 1960: 156–159.
6. Seward GR. Periodontal diseases and resorption of teeth. *Br Dent J* 1963; **114**: 443–449.
7. Southan JC. Clinical and histological aspects of peripheral cervical resorption. *J Periodontol* 1967; **38**: 534–538.

8. Cvek M. Endodontic treatment of traumatised teeth. In Andreasen JO, ed. *Traumatic Injuries to the Teeth*, 2nd edn. Copenhagen: Munksgaard, 1981: 362–363.
9. Makkes PC, Thoden Van Veltzen SR. Cervical external root resorption. *J Dent* 1975; **3**: 217–222.
10. Frank AL. External–internal progressive resorption and its non-surgical correction. *J Endod* 1981; **7**: 473–476.
11. Frank AL, Blakland LK. Supra osseous extra-canal invasive resorption. *J Endod* 1987; **13**: 348–387.
12. Gold SI, Hasselgren G. Peripheral inflammatory root resorption. A review of the literature with case reports. *J Clin Periodontol* 1992; **19**: 523–534.
13. Trope M. Root resorption of dental and traumatic origin: classification based on Etiology. *Pract Periodont Aesthet Dent* 1998; **10**: 515–522.
14. Levin L, Trope M. In: Hargreaves KM, Goodis HE, eds. *Seltzer and Bender's Dental Pulp*, revised edition. Quintessence Publishing Co, Inc, Chicago, London, 2002: 425–447.
15. Fuss Z, Tsesis I, Lin S. Root resorption – diagnosis, classification and treatment choices based on stimulation factors. *Dent Traumatol* 2003; **19**: 175–182.
16. Tronstad L. Root resorption – etiology, terminology and clinical manifestations. *Endod Dent Traumatol* 1988; **4**: 241–252.
17. Harrington GW, Natkin E. External resorption associated with the bleaching of pulpless teeth. *J Endod* 1979; **5**: 344–348.
18. Heithersay GS, Dahlstrom SW, Marin PD. Incidence of invasive cervical resorption in bleached root-filled teeth. *Aust Dent J* 1994; **39**: 82–87.
19. Trope M, Chivian N, Sigurdsson A, Vann WF Jr. In: Cohen S, Burns RC, eds. *Pathways of the Pulp*, 8th edn. St Louis: Mosby, 2002: 626–628.
20. Heithersay GS. Invasive cervical resorption: an analysis of potential predisposing factors. *Quintessence Int* 1999; **30**: 83–95.
21. Wedenberg C, Lindskog S. Evidence for a resorption inhibitor in dentin. *Scand J Dent Res* 1987; **95**: 270–271.
22. Heithersay GS. Clinical endodontic and surgical management of tooth and associated bone resorption. *Int Endod J* 1985; **18**: 72–79.
23. Heithersay GS. Treatment of invasive cervical resorption: an analysis of results using topical application of trichloroacetic acid, curettage, and resorption. *Quintessence Int* 1999; **30**: 96–110.
24. Pierce A, Lindskog S. The effect of an antibiotic/corticosteroid paste on inflammatory root resorption *in vivo*. *Oral Surg Oral Med Oral Pathol* 1987; **64**: 216–220.
25. Pierce A, Heithersay GS, Lindskog S. Evidence for direct inhibition of dentinoclasts by a cortico-steroid/antibiotic endodontic paste. *Endod Dent Traumatol* 1988; **4**: 44–45.
26. Bryson EC, Levin L, Branches F, Abbott PV, Trope M. Effect of *immediate* intra-canal placement of Ledermix Paste® on healing of replanted dog teeth after extended dry times. *Dent Traumatol* 2002; **18**: 316–321.
27. Heithersay GS. Combined endodontic–orthodontic treatment of transverse root fracture in the region of the alveolar crest. *Oral Surg Oral Med Oral Pathol* 1973; **36**: 414–415.
28. Ingber JS. Forced eruption. Part II. A method of treating non-restorable teeth – periodontal and restorative considerations. *J Periodontol* 1976; **47**: 203–216.
29. Heithersay GS. External root resorption. *Ann R Aust Coll Dent Surg* 1994; **12**: 46–59.
30. Antrim DD, Altaras DE. Treatment of subosseous resorption: a case report. *J Endon* 1982; **8**: 18–23.
31. Pitt-Ford TR, Torabinejad M, McHendry DJ, Hong CU, Kariyawasam SP. Use of mineral trioxide aggregate for repair of furcal perforations. *Oral Surg Oral Med Oral Pathol* 1995; **79**: 756–763.
32. Koh ET, Torabinejad M, Pitt Ford TR, Brady K, McDonald F. Mineral trioxide aggregate stimulates a biological response in human osteoblasts. *J Biomed Mater Res* 1997; **5**: 432–439.
33. Frank A, Simon JHS, Abou-Rass M, Glick DH. *Clinical and Surgical Endodontics*. Philadelphia: Lippincott, 1983: 147–154.
34. Lustman J, Ehrlich J. Deep external resorption: treatment by combined endodontic and surgical approach. A report of 2 cases. *Int Dent J* 1974; **24**: 203–206.
35. Goodman JR, Wolfe GN. The treatment of cervical external resorption in adolescents. *Br Dent J* 1980; **149**: 234–236.
36. Francischone CE, Costa CG, Francischone AC, Ribeiro HT, Silva RJ. Controlled orthodontic extrusion to create gingival papillae: a case report. *Quintessence Int* 2002; **33**: 561–565.
37. Rankow HJ, Krasner PR. Endodontic applications of guided tissue regeneration in endodontic surgery. *J Endod* 1996; **22**: 34–43.
38. Trope M. Subattachment inflammatory root resorption: treatment strategies. *Pract Periodont Aesthet Dent* 1998; **10**: 1005–1010.
39. Lindskog S, Blomlof L. Quality of periodontal healing. IV: enzyme histochemical evidence for an osteoblast origin of reparative cementum. *Swed Dent J* 1994; **18**: 181–189.
40. Vincentelli R, Lepp FH, Boyssou M. Les taches to sees de ca cou ronne ('pink spots') – leurs localisation intra et extra camerales. *Schweiz Monatsschr Zahnheilkd* 1973; **88**: 1132–1150.
41. Hammarstrom L, Lindskog S. Factors regulating and modifying dental root resorption. *Proc Finn Dent Soc* 1992; **88**(Suppl 1): 115–123.
42. Heithersay GS, Wilson DF. Tissue responses in the rat to trichloroacetic acid – an agent used in the treatment of invasive cervical resorption. *Aust Dent J* 1988; **33**: 451–461.
43. Lindskog S, Blomlof L, Hammarstrom L. Evidence for a role of odontogenic epithelium in maintaining periodontal space. *J Clin Periodontol* 1988; **15**: 371–373.
44. Leedham MD. The relationship between the epithelial cell rests of Malassez and experimental root resorption and repair in *Macaca fascicularis*. MDS Thesis, University of Adelaide, 1990.

45. Brice GL, Sampson WJ, Sims MR. An ultrastructural evaluation of the relationship between epithelial rests of Malassez and orthodontic root resorption and repair in man. *Aust Orthod J* 1991; **12**: 90–94.
46. Dreyer CW. Clast cell activity in a model of aseptic root resorption. PhD Thesis, University of Adelaide, 2002.
47. Pierce AM, Lindskog S, Hammarstrom L. Osteoclasts: structure and Function. *Electron Microsc Rev* 1991; **4**: 1–45.
48. Pierce AM. Experimental basis for the management of dental resorption. *Endod Dent Traumatol* 1989; **5**: 255–265.
49. Boyle WJ, Simonet WS, Lacey DL. Osteoclast differentiation and activation. *Nature* 2003; **423**: 337–342.
50. Collins MT, Bianco P. Fibrous dysplasia. In: *Primer on the Metabolic Bone Diseases and Disorders of Mineral Metabolism*, 5th edn. Washington, DC: American Society for Bone and Mineral Research, 2003: 466–470.
51. Andreasen JO, Andreasen FM. *Textbook and Color Atlas of Traumatic Injuries to the Teeth*, 3rd edn. Copenhagen: Munksgaard, 1994: 366–370.
52. Schajowicz F. In: *Histological Typing of Bone Tumours*, 2nd edn. Berlin: Springer-Verlag, 1993: 36–42.
53. Andreasen JO, Andreasen FM. *Textbook and Color Atlas of Traumatic Injuries to the Teeth*, 3rd edn. Copenhagen: Munksgaard, 1994: 370–372.
54. Wedenberg C. Development and morphology of internal resorption in teeth – a study in humans, monkeys and rats. PhD Thesis, Karolinska Institute, Stockholm, 1987: 22–23.
55. Rabinowitch BZ. Internal Resorption: conference on the biology of the human dental pulp. *Oral Surg Oral Med Oral Pathol* 1972; **33**: 263–281.
56. Cvek M. Endodontic management of traumatised teeth. In: Andreasen JO, Andreasen FM, eds. *Textbook and Color Atlas of Traumatic Injuries to the Teeth*, 3rd edn. Copenhagen: Munksgaard, 1994: 560–561.
57. Velasques-Plata D, Scheyer ET, Mellonig JT. Clinical comparison of an enamel matrix derivative used alone or in combination with a bovine-derived xenograft for the treatment of periodontal osseous defects in humans. *J Periodontol* 2002; **73**: 433–440.
58. Sculean A, Windisch P, Keglevich T, Chiantella GC, Gera I, Donos N. Clinical and histologic evaluation of human infrabony defects treated with an enamel matrix protein derivative combined with a bovine-derived xenograft. *Int J Periodontics Restorative Dent* 2003; **23**: 47–55.
59. Lyon KF. Subgingival odontoclastic resorptive lesions: classification, treatment and results in 58 cases. *Vet Clin North Am Small Anim Pract* 1992; **22**: 1471–1483.
60. Harvey CE. Feline dental resorptive lesions. *Seminars Vet Med Surg (small animals)* 1993; **8**: 187–196.