

The Healing Socket And Socket Regeneration

by Gregory Gene Steiner, DDS, MS; Warren Francis, DDS; Ronald Burrell, DDS; Melissa P. Kallet, BA; Dainon Michael Steiner, BA; and Roslynn Macias, RDA

Gregory Gene Steiner, DDS, MS

CEO, Steiner Laboratories, Kapolei, Hawaii
Director, The Bone Institute, Santa Rosa, California

Warren Francis, DDS

Private Practice, Santa Rosa, California

Ronald Burrell, DDS

Private Practice, Santa Rosa, California

Melissa P. Kallet, BA

Administrator, Clinical Research, Steiner Laboratories, Kapolei, Hawaii

Dainon Michael Steiner, BA

President, Steiner Laboratories, Kapolei, Hawaii

Roslynn Macias, RDA6

Clinical Specialist, The Bone Institute, Santa Rosa, California

***Abstract:** Tooth extraction is a common procedure in dentistry. The normal healing response to the procedure results in a significant loss of bone and collapse of the surrounding gingiva. In addition to normal healing, a substantial percentage of extraction sites suffer postoperative complications. This article presents histology that supports the concept that the first response to extraction is bone death and resorption of the socket wall. The stages of extraction socket healing also will be discussed. Additionally, the article will present a regenerative method that skips the resorptive phase, the clotting phase, the granulation of tissue phase, and the collagen-producing phase of normal extraction-socket healing, while avoiding extraction-socket complications.*

Only a few studies have documented the histology of extraction-socket healing in humans. The work of Amler and colleagues is an example.¹ Additionally, Boyne studied extraction-socket alveolar bone biopsies² and, more recently, Devon and Sloan studied extraction-socket biopsies harvested during resective cancer surgery.³

The majority of research involving extraction-socket healing has been performed on animals. However, it is well documented that laboratory animals regenerate oral tissues much faster and more completely than humans do. Accordingly, studies of extraction-socket healing in animals cannot be equated to human extraction-socket healing in any

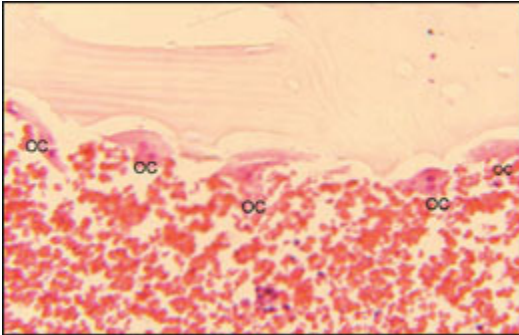


Figure 1—Necrotic bone left exposed after periodontal surgery (original magnification x400). Note the osteoclasts (OC) in their respective resorption lacuna meaningful way.

Amler and colleagues found that after extraction a blood clot filled the socket. After 7 days, the clot was replaced with granulation tissue. After 20 days, the granulation tissue was replaced by collagen, and bone began forming at the base and the periphery of the extraction socket. At 5 weeks, Amler estimated that on average two-thirds of the extraction socket had filled with bone. Epithelium was found to require a minimum of 24 days to completely cover the extraction socket, with some extraction sites requiring up to 35 days to completely cover the socket. The epithelium was found to grow progressively, enveloping islands of granulation tissue, debris, and bone splinters. Amler noted that all stages of bone regeneration progressed from the apex and periphery and proceeded finally to the center and crest of the extraction socket. While the article did not state which teeth were used for the study, the tissue biopsies indicated that the teeth were single-rooted.¹

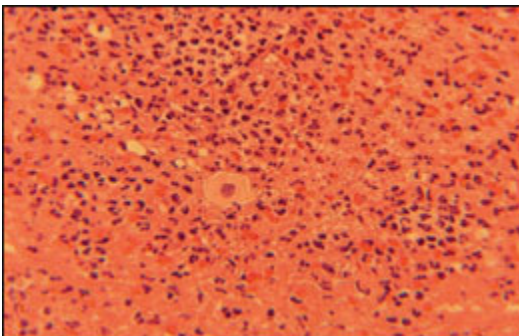


Figure 2—Histological section of tissue taken from a socket 3 days after tooth extraction. The loosely organized and fragile tissue was comprised of a fibrin clot partially

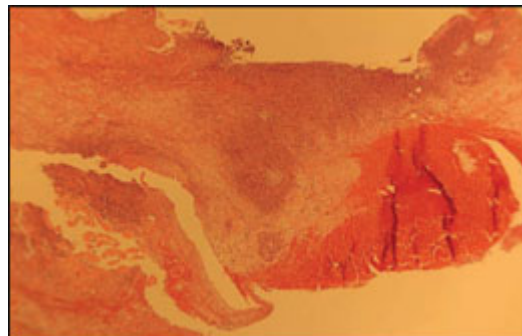


Figure 3—Tissue sample taken from a 1-week-old extraction socket, which was composed of degenerating fibrin and early granulation tissue.

infiltrated with inflammatory cells.

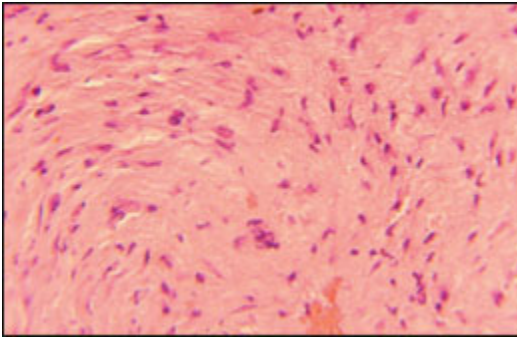


Figure 4—Early collagen plug in tissue taken from the center of an extraction site 1 month after tooth extraction.

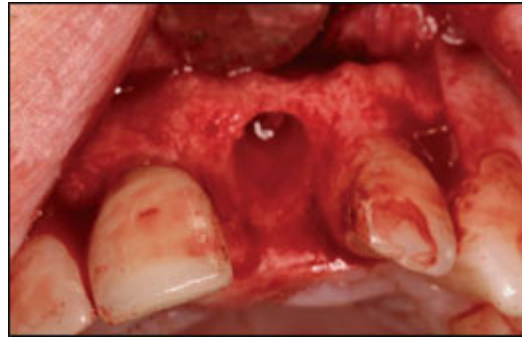


Figure 5—Enlarged socket 1 month after extraction.

Boyne found that after extraction no bone formation occurred for the first week. At 8 days, new bone formation was noted throughout the alveolar bone, particularly under the wall but not on the surface of the bone lining the extraction socket. At 10 days, bone formation was noted on the surface of the socket wall. At 12 days, new bone formation continued along the socket wall and in the trabecular spaces surrounding the extraction site.²

Devon and Sloan harvested healing extraction sockets 2 weeks after extraction. Immunostaining was used to identify new bone growth. In their histological samples, Devon and Sloan noted woven bone trabecula at the periphery of the socket. Osteoprogenitor cells, preosteoblasts, and osteoblasts surrounded the trabecula. They also noted that the periodontal ligament was displaced to the center of the extraction socket and not attached to the socket wall.³

Amler and colleagues noted bone fragments being exfoliated from the healing extraction socket.¹ Boyne found that there was no bone growth for 1 week, and when bone growth was first noted, it appeared under the socket wall, not on the exposed surface.² Devon and Sloan found the periodontal ligament displaced from the socket wall and residing in the center of the socket.³ These findings indicate that, in humans, the first phase of extraction-socket healing is most likely osteoclastic undermining and rejection of the original socket wall into the healing socket.

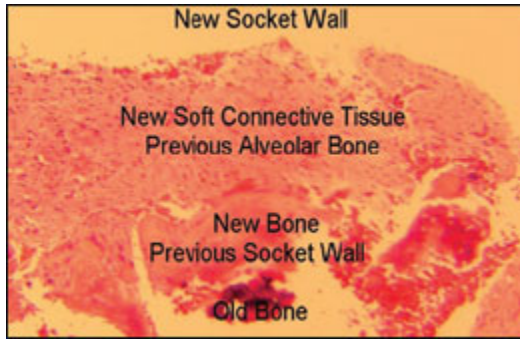


Figure 6—Photomicrograph of the breakdown of the original socket wall.

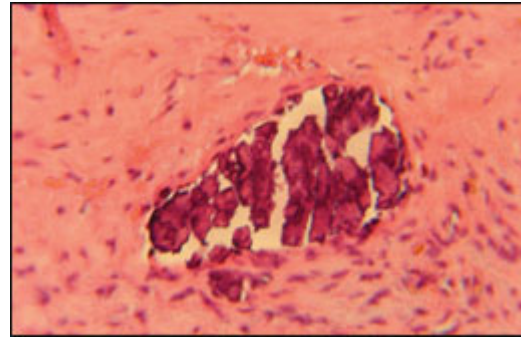


Figure 7—Necrotic bone in the collagen plug of the healing extraction socket.

Descriptions and Examples

When bone is exposed, the body responds aggressively in an effort to prevent osteomyelitis and osteonecrosis. The body has no ability to heal bone that is left exposed. Exposed bone has no mechanism to deal with the inevitable bacterial colonization of the mineralized surface. Therefore, the exposed bone is undermined by osteoclastic resorption and eventually sloughed off, leaving a soft connective-tissue surface that can be defended against bacterial invasion.^{4,5} The authors propose that a similar sequence of events occurs in the extraction socket.

Bone that becomes exposed after oral or periodontal surgery will die and be sloughed into the oral cavity. In the following case bone became exposed on the lingual surface of the lower molars because of gingival sloughing after periodontal surgery. The patient was monitored closely and, after 4 weeks, the exposed bone was removed with cotton pliers, leaving an underlying hemorrhagic surface. The bone was composed of necrotic cortical bone that had been undermined and, over a 4-week period, the exposed bone was being prepared to be sloughed into the oral cavity. Viable osteocytes were absent from the bone. The portion of the bone specimen exposed to the oral cavity was covered by a biofilm. The base of the bone showed resorption lacuna where osteoclasts separated the dead bone from the underlying healthy bone.

Classic osteoclastic resorption lacuna were found where dead bone was separated from vital bone. During the process of separating the exposed dead bone from the underlying vital bone, soft connective tissue formed under the dead bone and the dead bone was expelled from the body. Osteoclasts were noted in their respective resorption lacuna (Figure 1).

Contemporary thought holds that after extraction bone lining the socket wall is stimulated and bone growth occurs. However, this contention is at odds with what is known about how bone responds to trauma and surgical exposure. During gingival flap surgery, raising the soft tissue off the bone will result in resorption of bone from the surface.⁶ Soon after extraction the buccal plate is often significantly resorbed, and the mineralized socket wall is exposed to bacterial colonization while the body attempts to form a fibrin clot.^{1,7-9}

The fibrin clot becomes filled with inflammatory cells programmed to prevent infection. As seen in periodontal and endodontic diseases, bone is resorbed in the presence of inflammatory cells.^{10,11} With the findings of Amler, Boyne, Devon, and Sloan in combination with the authors' understanding of how bone responds to injury and inflammation, the authors believe it is more plausible that the socket wall will proceed through a phase of resorption before regeneration.

Tissue taken from a socket 3 days after tooth extraction was comprised of a fibrin clot partially infiltrated with inflammatory cells, which were loosely organized and very fragile (Figure 2). In another sample, tissue taken from a 1-week-old extraction socket was found to be composed of degenerating fibrin and early granulation tissue (Figure 3).

After the development of a fibrin clot, the tissue becomes granulation tissue, which contains blood vessels, fibroblasts, and chronic inflammatory cells. The granulation tissue eventually matures into a collagen plug. For example, the authors found that, after 1 month, tissue removed from the center of the extraction site was composed of fibrous connective tissue and fibroblasts with some remaining inflammatory cells (Figure 4). The buccal wall and alveolar crest was resorbing with associated gingival collapse and loss of interdental papilla. The socket enlarged to the buccal, and bone on the buccal alveolar surface, and alveolar crest resorbed in the area of the extraction site (Figure 5). In this patient, tooth extraction precipitated a generalized resorptive response in the alveolar bone.

Wound healing in orthopedics is well documented. After orthopedic surgery, bone fragments found in the surgical site are often necrotic and serve as a nidus for new bone formation on their surface. Eventually the bone is remodeled, and the necrotic bone is removed by osteoclastic resorption during the remodeling process.¹² The authors' findings indicate a similar process can occur in the periphery of the healing extraction socket.

In tissue samples of the periphery of the soft tissue removed from extraction sockets, new bone formation occurred on the old necrotic bone of the original socket wall (Figure 6). However, in the same socket, necrotic bone was set free from the underlying vital bone and was sloughed into the socket to be expelled as bone sequestra (Figure 7). The authors propose that after extraction, bone of the original socket wall dies and is undermined by osteoclastic resorption. This necrotic bone can form a nidus for new bone growth, as is found in orthopedic surgery, or the necrotic bone can be expelled from the socket as bone sequestra, as noted by Amler. A portion of the old socket wall will have new bone formed on its surfaces and will become incorporated into bone forming in the extraction socket. However, a significant portion of the old socket wall will be undermined, become necrotic, and be sloughed into the oral cavity through the extraction socket orifice.

If the first stage of extraction-socket healing is resorption and disposal of necrotic bone, then this would explain why tooth extraction in patients on bisphosphonates occasionally leads to osteonecrosis. It is the authors' contention that bisphosphonates prevent osteoclastic undermining and disposal of necrotic bone lining the socket wall. The

inability of the alveolus to dispose of the necrotic bone lining the socket wall could then lead to progressive osteonecrosis.

The histology of the soft tissue near the socket wall indicates that, in this case, bone that lined the socket wall was undermined and handled by the body in a manner similar to bone exposed after gingival sloughing (Figure 1). Another portion of the same extraction socket showed necrotic bone residing in the collagen plug of the healing extraction socket (Figure 7). The authors propose that the only plausible source of this necrotic bone is the original socket wall.

Because of the impact of bone exposure, the postextraction healing process may encompass a number of responses. Our findings suggest that all of the bone on the surface of the socket wall dies and becomes necrotic. The apex of the extraction site may move quickly from extraction to regeneration by reincorporating the necrotic bone by covering it with new bone. More coronal on the socket wall, bone may be undermined and sloughed into the extraction socket. In some instances, the socket wall may be completely resorbed or sloughed into the soft tissue of the socket. Different areas of the socket wall may experience different responses, depending on the trauma of the extraction, the bone health of the patient, and to what degree the blood clot is retained. Independent of what is happening to the socket wall, if normal healing occurs, the fibrin clot will convert into granulation tissue and organize into a collagen plug during the first month. This collagen plug will increase in density until it is gradually replaced from the apex and periphery by bone deposition.

The rate of collagen plug conversion into bone varies significantly. To allow adequate bone formation in the extraction socket, it is common practice to wait 3 months before an implant is placed in the untreated extraction socket. As implantologists are aware, waiting 3 months does not ensure the existence of adequate bone for implant placement.¹³ For example, when the healing socket of an upper molar was biopsied 3 months after extraction, the dense collagen fibers showed very little vascularity, and the socket showed little, if any, bone formation (Figure 8).

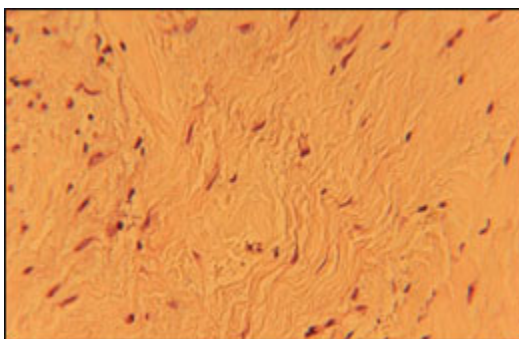


Figure 8—Mature collagen plug with little vascularity and bone formation (original magnification x400).

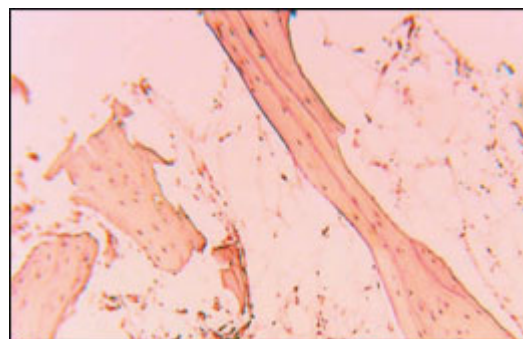


Figure 9—Poor mineralization in an untreated extraction site.

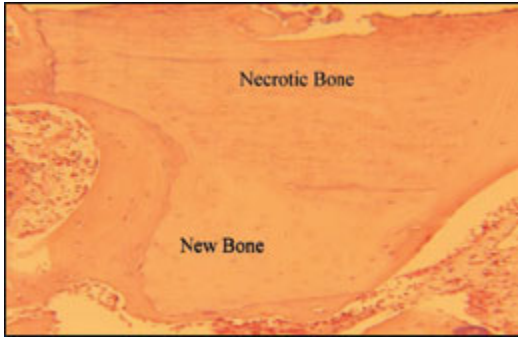


Figure 10—Histological sample taken from a molar socket after 6 weeks of healing in a grafted extraction site (original magnification x100). Note the necrotic bundle bone covered by new bone growth.

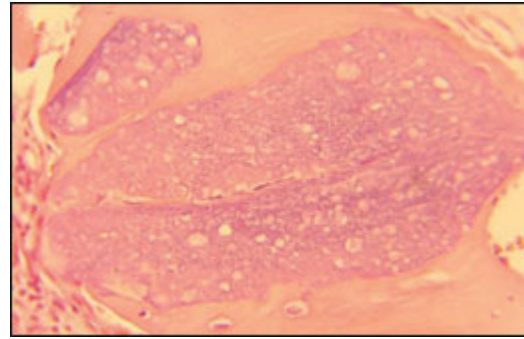


Figure 11—Large graft particle in the same sample as Figure 10 (original magnification x400). Note the nutrient canal.

Further, untreated extraction sites most often are found to have poor mineralization. For example, a fully healed extraction site of a lower bicuspid of a young, healthy woman showed that the bone contained approximately 10% mineralized tissue (Figure 9). Poor mineralization of extraction sites appears to be unrelated to the patient's systemic bone health. It is our finding that patients with normal bone density throughout their skeleton will often present with poor mineralization at fully healed ungrafted extraction sites (authors' unpublished data).

Normal cancellous bone is comprised of between 30% and 50% mineralized tissue. Osteoporosis is defined as cancellous bone containing < 30% mineralized tissue. It is the authors' finding that the majority of fully healed, untreated extraction sites contain < 30% mineralized tissue (authors' unpublished data). It is not uncommon to find fully healed extraction sites that contain < 20% mineralized tissue, which makes these sites difficult to biopsy because the tissue collapses during the procedure.

Even with modern antibiotics, osteomyelitis and osteonecrosis are major medical challenges. To prevent osteomyelitis and osteonecrosis, bone mounts an inflammatory response to protect the host.¹⁴ After extraction, a significant amount of bone is sacrificed by the body, but the host survives.^{7,8} However, with proper treatment, our findings indicate the resorptive, clotting, granulation, and collagen phases of healing can be skipped, and the extraction socket can proceed directly from extraction to regeneration.

To skip the negative phases of extraction-socket healing, a biocompatible material must be placed in the socket after extraction. However, to avoid the resorptive phase of healing, the graft material should not require resorption before bone formation. The graft material should be biocompatible, inhibit bone resorption, and stimulate osteogenesis. Also, to limit bone resorption on the buccal, lingual, and crestal bone surfaces, gingival flaps that expose this bone should not be raised during placement of the graft material.

A Novel Material and Method for Socket Regeneration

Socket Graft™ (Steiner Laboratories, Kapolei, HI) and its method of placement were designed to seal the socket from bacterial invasion and prevent the resorptive, clotting, granulation, and collagen-producing phases of socket healing. Placing Socket Graft can move the socket directly from extraction to bone regeneration.

The US Food and Drug Administration has defined Socket Graft as a bone-graft material with a drug component. According to the manufacturer, the bone-graft material is a dual-phase, nonceramic calcium phosphate based biocement that binds to bone and gingiva. In its early phase, it is a solid, thereby excluding bacterial penetration. After a period of a few days, the first crystalline phase of the graft material is dissolved, leaving the second crystalline phase of the material porous for ingrowth of nutrient canals and osteoconduction. The graft material is not resorbed by osteoclasts. As a nonceramic calcium phosphate based graft material, the components of Socket Graft are available for integration into the newly forming bone.

The drug component in Socket Graft stimulates osteoblasts and inhibits osteoclasts and phagocytes. As the calcium phosphate based component of the bone graft is replaced by bone, the drug component enters the osteoblasts, stimulating osteogenesis. The drug component is retained by the osteoblast and continues to stimulate osteogenesis after the calcium phosphate portion of the graft material has been converted into bone.

Clinical Research

Study Design and Patient Criteria

One hundred consecutive extraction sites were grafted with Socket Graft. The purpose of the study was to evaluate extraction-socket healing and the clinical and histological response to the bone graft material. Each patient required tooth extraction of a hopeless tooth and was treatment planned for implant placement. Any patient who was deemed healthy enough for tooth extraction and implant placement was accepted into the patient pool, including patients who smoked and those with a myriad of health problems.

The clinical criteria for inclusion in the study patient pool were the presence of a buccal wall and complete removal of any foreign objects from the socket. Patients requiring either a sinus lift or buccal-wall ridge augmentation were not included in the patient pool. A complete bony socket was not necessary for inclusion. If the amount of alveolar ridge was deemed adequate to support an implant after regeneration of the bone in the extraction socket, the patient was included. Incisors, canines, bicuspid, and molars were all included in the study with no effort to select or limit the type of tooth to be extracted. The majority of patients had the extraction performed and Socket Graft placed by a general dentist. Dental specialists performed the implant surgery.

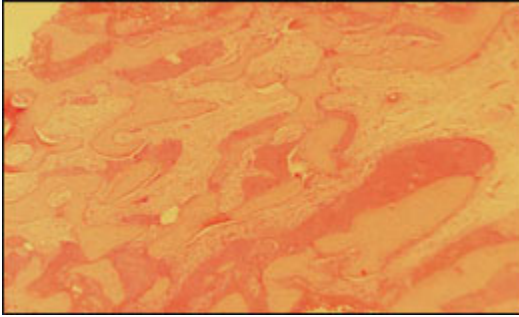


Figure 12—Bone formation 8 weeks after grafting in lower molar extraction site.

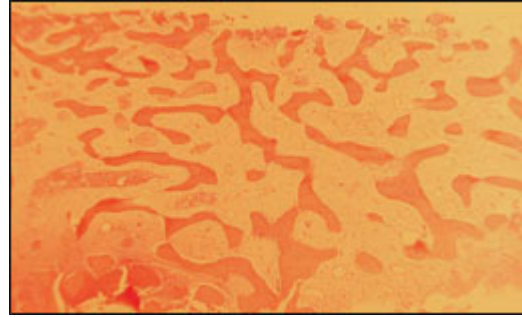


Figure 13—A core sample (halfway through the depth of the core sample on the left with the surface of the alveolar bone on the right) 9 weeks after extraction and grafting.



Figure 14—Apical portion of the core sample in Figure 13. Note the advanced mineralization and lamellar bone (center).

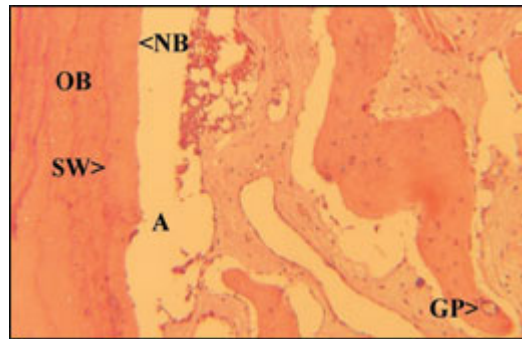


Figure 15—Lower molar extraction site 9 weeks after grafting (original magnification x400). OB = vital old bone; SW = original socket wall; NB = new bone; A = preparation artifact; GP = graft particle.

Treatment and Sample Gathering

After tooth extraction and grafting, patients were scheduled for implant placement. Patients who had incisor, canine, or bicuspid sites grafted were advised to have implant placement 6 weeks after extraction and grafting. Patients who had molar sites grafted were advised to have implant placement 8 weeks after extraction and grafting. However, because the patients were treated in a private practice setting, each chose the date for his or her implant placement. Many patients followed through with implant placement at 6 or 8 weeks, but others took weeks to months longer to have implant placement. This information is reflected in the included histological photomicrographs. The time between graft and implant placement was documented only for those patients who had their grafted sites biopsied at the time of implant placement. The study was to continue until 100 sockets were grafted and implants were placed in the regenerated sockets. Only treatment that was deemed in the patient's best interest was performed; therefore, no ungrafted extraction sites were included in the protocol.

Not all implant sites were biopsied for histological evaluation. The welfare of the patient was the main criterion determining whether the implant site was biopsied. If a site could be biopsied without negative effects on the patient or compromising the success of the implant, the site was biopsied at the time of implant placement. The method of biopsy was to use a 2 mm internal diameter trephine. The cores were taken to a minimum depth of 8 mm.

The bone biopsy was required to be taken from the center of the removed root. However, core samples did on occasion include pre-existing bone at the apex or periphery where the root narrowed or curved. In this manner, core samples were taken only from regenerated bone that would have been removed during implant placement. The implants were scheduled to be restored 3 months after implant placement.

The core samples were fixed in formalin, and demineralized and stained with hematoxylin and eosin. The core samples were mounted and sectioned along the long axis of the core. To limit the inclusion of preparation artifact, the center 4 mm of the core samples was used for photomicrographs under 40x, 100x, and 400x magnification.

Results

All 100 sites grafted with Socket Graft successfully integrated. Of the 100 implants placed, all implants continued to function at the 3-year follow-up.

Histological Samples and Discussion

A histological sample from a molar socket 6 weeks after grafting with the graft material showed significant bone regeneration and some portions of the graft material in the grafted site. While this level of bone development is considered to be too early for implant placement, the histological section serves to outline the healing process of a socket grafted with this material.

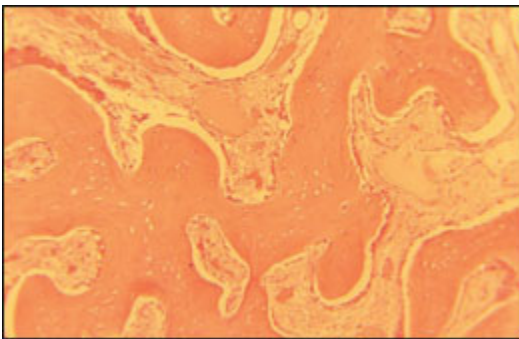


Figure 16—Core sample from a lower molar 13 weeks after extraction and grafting (original magnification x400). The cubical shape of the osteoblasts 13 weeks after extraction and grafting indicates active bone formation.

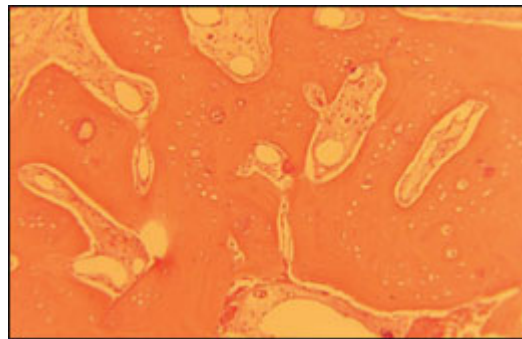


Figure 17—Core sample from an upper bicuspid 14 weeks after grafting with approximately 70% mineralized tissue (original magnification x400). Note the graft particles encased in new bone.

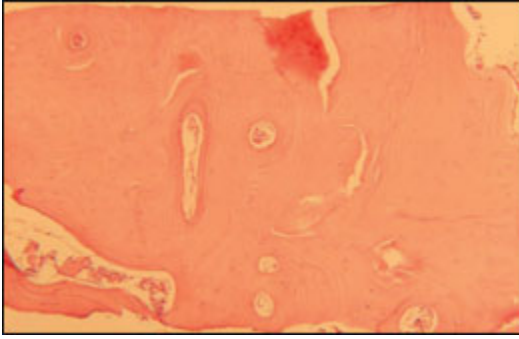


Figure 18—A core sample from a lower molar extraction socket completely filled with mineralized tissue 18 weeks after grafting.

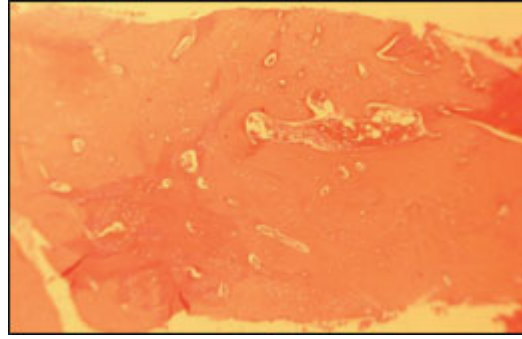


Figure 19—A core sample taken from a lateral incisor maintained complete mineralization 26 weeks after grafting.

The core sample tissue included bundle bone of the cribriform plate of the interradicular bone between the mesial and distal roots. This bone lined the original extraction socket. The bone was necrotic and devoid of osteocytes (Figure 10). This histological sample supports the authors' contention that the bone lining the extraction socket dies and becomes necrotic; however, in sockets treated with Socket Graft, new bone forms over the necrotic bone and osteoclastic resorption of the socket wall does not occur.

At 400x magnification, a graft particle was noted in intimate contact with newly formed bone. A nutrient canal moved from the left of the particle and bifurcated as it exited the particle on the right. The nutrient canal contained nuclei of endothelial cells lining the canal. Dissolution of the first phase of the graft material produced voids (Figure 11). This sample shows that in 6 weeks of healing, a patient's socket can fill with bone, skipping the resorptive, clotting, inflammatory, and collagen-producing phases of extraction-socket healing. Bone formation in sockets grafted with Socket Graft do not appear to proceed from the periphery of the socket inward as is found in ungrafted sites. After grafting with this material, nutrient canals appear to course through the graft material and bone formation appears to develop uniformly throughout the socket. However, in the vertical dimension, bone formation is more rapid in the apex of the extraction site than at the coronal aspect of the extraction site.

A core sample from a lower molar extraction site 8 weeks after grafting with Socket Graft was filled with approximately 50% mineralized tissue, with osteogenesis proceeding rapidly (Figure 12). Because of the vitality of the bone growth at this stage, the authors recommend implant placement at 8 weeks for molar sites grafted with the graft material.

A core sample from a lower bicuspid 9 weeks after extraction showed osteogenesis proceeding rapidly, with significant blood vessel profusion. While bone formation was occurring throughout the core sample, bone formation was more advanced at the apex of the sample, gradually becoming less advanced toward the coronal portion (Figure 13).

The apical portion of the core sample showed more advanced mineralization. In the center of this sample was lamellar bone, which is bundle bone from the original cribriform plate of the extraction socket. This section of bone was necrotic but covered with new bone formation, and was being incorporated into the regenerating extraction socket as a result of the grafting procedure (Figure 14). If the socket is untreated, the bone likely will be undermined and sloughed into the healing socket. When grafted with Socket Graft, the bone lining the socket wall may not become necrotic.

After grafting, the socket wall may become necrotic but new bone will be formed over the necrotic bone and it eventually will be remodeled. The bone lining the socket wall also may retain its vitality. In a molar extraction site 9 weeks after extraction and grafting, bone was formed on the surface of vital bone lining the socket wall (Figure 15).

A core sample taken 13 weeks after grafting a lower molar showed that all of the graft material was removed from the extraction site and active osteogenesis continued to occur throughout the socket. At this stage the socket already had more mineralized tissue than is found in normal cancellous bone.

Higher magnification shows the cubical shape of the osteoblasts lining the newly formed bone indicating rapid bone formation (Figure 16). The drug component in Socket Graft should continue to produce bone formation until the socket site is filled with > 90% mineralized tissue.

At 14 weeks after extraction, a core sample taken from an upper bicuspid extraction site indicated mineralized tissue in the extraction site was approaching 70%. Higher magnification shows small graft particles encased in new bone which will be removed when remodeling occurs (Figure 17).

A core sample taken from a lower molar extraction site 18 weeks after extraction and grafting showed that, at this stage, the extraction socket was solid bone (Figure 18). A core sample taken from a lateral incisor extraction site 26 weeks after extraction and grafting showed that the site was filled with > 90% mineralized tissue (Figure 19).

As grafted extraction sites aged, the percent of mineralized tissue often increased until the extraction socket was filled with only mineralized tissue and the blood vessels that provide nutrients to the bone. In sockets grafted with Socket Graft, the authors noted the following cycle:

- A few days after grafting, the first phase of the graft material dissolved in physiologic conditions.
- The porous material was invaded by nutrient canals and osteoblasts.
- Osteoblasts were stimulated to form osteoid, and the minerals from the graft material deposited in the osteoid to form mineralized tissue.
- Osteogenesis commonly continued until the socket was filled with > 90% mineralized tissue.
- After 6 months, the bone remodeled into cancellous bone with trabecula.

Based on this data, the authors recommend implant placement 6 weeks or later for incisors and bicuspid and 8 weeks or later for molars.

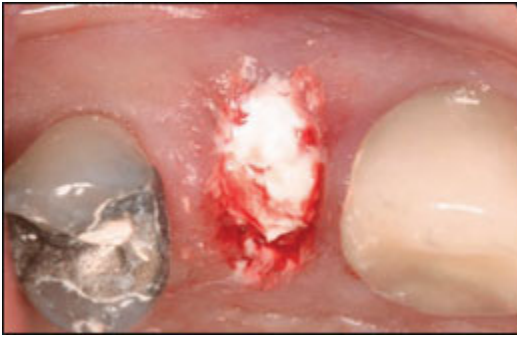

Figure 20—Initial set of graft material.

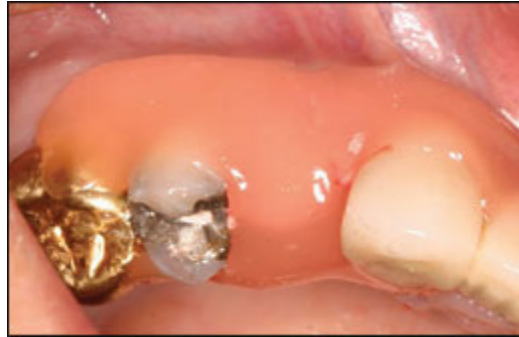

Figure 21—Graft covered and retained with barricade-style packing material.

Grafting Technique

To maximize bone regeneration and minimize bone resorption, the tooth should be removed atraumatically, without elevating gingival flaps. After the tooth is removed, the graft material is injected into the extraction site using a Monoject syringe. When filling the socket, the gingiva and bone should be left undisturbed to avoid trauma to the bone, thereby reducing resorption of the buccal, lingual, and crestal alveolar ridges (Figure 20).

Adhesive foil is provided with each packet of the material to cover the socket orifice. However, many options are available for retaining and protecting the graft material. In the esthetic zone, the graft can be covered by an ovate pontic placed in the extraction site after grafting. This method facilitates maintenance of the gingival margin and papilla during the healing phase. Bone forms around the contours of the ovate pontic and, after implant placement, the ovate pontic is rebonded.¹⁵ For the posterior dentition, supragingival foil barriers can be retained by suturing or packing. For example, a barricade-style, light-cured packing material can be placed directly over the graft without the use of the foil barrier (Figure 21). In this case, care was taken to avoid pressing the packing into the extraction socket.

As the presented histology showed, the percentage of mineralized tissue in a socket grafted with Socket Graft depends on the time period. Incisor and bicuspid grafted sockets exhibit approximately 50% mineralized tissue after 6 weeks. In molars, sockets grafted with this material exhibit approximately 50% mineralized tissue at 8 weeks because of the larger volume. At this stage, the socket is fully prepared for implant placement.

Conclusion

Tooth extraction has not changed since the beginning of dentistry. A tooth is removed and the socket is left open to the oral environment until the body can heal the wound. In addition to the known complications of tooth extraction (alveolar osteitis, surgical wound infection, oral-antral fistula, bacteremia), leaving an open wound in the oral cavity also may serve as a portal for serious pathogenic vectors.¹⁶⁻¹⁸ Knowing the damage that ensues and the potential complications of tooth extraction, modern dentistry is moving toward socket protection and regeneration.

Currently, a significant impediment to socket treatment is the cost and complexity of the surgery. Flap surgery, bone grafts, and membranes increase costs and can require the skill of a dental specialist. A novel dual-phase, nonceramic calcium phosphate based bio cement bone graft material was developed to provide a simple, inexpensive, yet effective method for any dentist to offer socket regeneration to his or her patients. In the future, protecting the wound and regenerating bone will likely become the standard of care for all extractions.

Disclosure

All funding for the development of this study was provided by Steiner Laboratories. Authors Gregory Gene Steiner and Dainon Michael Steiner are principals of Steiner Laboratories, a division of Steiner Healthcare, LLC. Drs. Warren Francis and Ronald Burrell performed many of the extractions and bone grafting, and also assisted in the development of the clinical application of Socket Graft. The clinical research was performed at The Bone Institute, Santa Rosa, California.

About The Authors

Gregory Gene Steiner, DDS, MS: CEO, Steiner Laboratories, Kapolei, Hawaii; Director, The Bone Institute, Santa Rosa, California

Warren Francis, DDS Private Practice, Santa Rosa, California

Ronald Burrell, DDS: Private Practice, Santa Rosa, California

Melissa P. Kallet, BA: Administrator, Clinical Research, Steiner Laboratories, Kapolei, Hawaii

Dainon Michael Steiner, BA: President, Steiner Laboratories, Kapolei, Hawaii

Roslynn Macias, RDA: Clinical Specialist, The Bone Institute, Santa Rosa, California

References

1. Amler MH, Johnson PL, Salman I. Histological and histochemical investigation of human alveolar socket healing in undisturbed extraction wounds. J Am Dent Assoc. 1960;61(7):32-44.

2. Boyne PJ. Osseous repair of the postextraction alveolus in man. *Oral Surg Oral Med Oral Pathol.* 1966;21(6):805-813.
3. Devlin H, Sloan P. Early bone healing events in the human extraction socket. *Int J Oral Maxillofac Surg.* 2002;31(6):641-645.
4. Yamaguchi Y, Sumikawa Y, Yoshida S, et al. Prevention of amputation caused by rheumatic diseases following a novel therapy of exposing bone marrow, occlusive dressing and subsequent epidermal grafting. *Br J Dermatol.* 2005;152(4):664-672.
5. Struijs PA, Poolman RW, Bhandari M. Infected nonunion of the long bones. *J Orthop Trauma.* 2007;21(7):507-511.
6. Pfeifer JS. The reaction of alveolar bone to flap procedures in man. *Periodontics.* 1965;20:135-140.
7. Araújo MG, Sukekava F, Wennström JL, et al. Tissue modeling following implant placement in fresh extraction sockets. *Clin Oral Implants Res.* 2006;17(6):615-624.
8. Covani U, Bortolaia C, Barone A, et al. Bucco-lingual crestal bone changes after immediate and delayed implant placement. *J Periodontol.* 2004;75(12):1605-1612.
9. Stiebe B, Poethe I, Bernhardt H. The bacteriology of normal wound healing following tooth extraction with special reference to anaerobic microorganism diagnosis. *Zahn Mund Kieferheilkd Zentralbl.* 1990;78(3):247-251.
10. Coon D, Gulati A, Cowan C, et al. The role of cyclooxygenase-2 (COX-2) in inflammatory bone resorption. *J Endod.* 2007;33(4):432-436.
11. Taubman MA, Kawai T, Han X. The new concept of periodontal disease pathogenesis requires new and novel therapeutic strategies. *J Clin Periodontol.* 2007;34(5):367-369.
12. Togawa D, Bauer TW, Brantigan JW, et al. Bone graft incorporation in radiographically successful human intervertebral body fusion cages. *Spine.* 2001;26(24):2744-2750.
13. John V, De Poi R, Blanchard S. Socket preservation as a precursor of future implant placement: review of the literature and case reports. *Compend Contin Educ Dent.* 2007;28(12):646-653.
14. Pesanti EL, Lorenzo JA. Osteoclasts and effects of interleukin 4 in development of chronic osteomyelitis. *Clin Orthop Relat Res.* 1998;(355):290-299.
15. Kois JC, Kan JY. Predictable peri-implant gingival aesthetics: surgical and prosthodontic rationales. *Pract Proced Aesthet Dent.* 2001;13(9):691-700.
16. Okabe K, Nakagawa K, Yamamoto E. Factors affecting the occurrence of bacteremia associated with tooth extraction. *Int J Oral Maxillofac Surg.* 1995;24(3):239-242.
17. Christiaens I, Reyckler H. Complications after third molar extractions: retrospective analysis of 1,213 teeth. *Rev Stomatol Chir Maxillofac.* 2002;103(5):269-274.
18. Ren YF, Malmstrom HS. Effectiveness of antibiotic prophylaxis in third molar surgery: a meta-analysis of randomized controlled clinical trials. *J Oral Maxillofac Surg.* 2007;65(10):1909-1921.