

# Periodontally Accelerated Osteogenic Orthodontics Combined with Autogenous Bone Grafting

Hessam Nowzari, DDS, PhD;<sup>1</sup> Frank Kazuo Yorita, DDS;<sup>2</sup> and Hsuan-Chen Chang, PhD, DDS<sup>3</sup>

**Abstract:** This case report documents the first use of particulate autogenous bone graft with the corticotomy-assisted rapid orthodontic procedure known as periodontally accelerated osteogenic orthodontics (PAOO). A 41-year-old man, with class II, division 2 crowded occlusion, was treated with the PAOO procedure. Buccal mucoperiosteal flaps were reflected, and selected vertical and horizontal corticotomy was performed around the roots in both the maxillary and mandibular arches. Particulate bone graft was harvested from the rami and exostosis for alveolar ridge augmentation. Orthodontic movement was initiated immediately after the surgical intervention and adjusted every 2 weeks. Eight months after corticotomy surgery, total active orthodontic treatment was completed. No detrimental periodontal effects or root resorption were observed. The alveolar ridges of both the maxilla and mandible maintained the original thickness and configuration despite facial tipping of the incisors. It was concluded that PAOO is an effective treatment approach in adults to decrease treatment time and reduce the risk of root resorption. Selected corticotomy limited to the buccal and labial aspects also significantly reduces treatment time. More clinical studies with additional patients and long-term follow-up are needed to determine the optimal amount of autogenous bone graft.

## Learning Objectives:

After reading this article, the reader should be able to:

- understand the basics and current developments in periodontally accelerated osteogenic orthodontics (PAOO).
- list the indications for PAOO.
- select cases eligible for PAOO and discuss them with periodontal or oral surgeons before referral.

Currently, many adult patients are seeking orthodontic treatment. However, successful orthodontic treatment can be difficult when treating adult patients because dentoalveolar development ceases after adolescence. The average orthodontic treatment time for adults is considerably longer than for

adolescent patients, ranging from 18.7 to 31 months.<sup>1-3</sup> It is also more likely for adult patients to experience root resorption because of an aplastic, narrow, and less vascular periodontal membrane, as well as denser, avascular, and aplastic bone.<sup>4</sup>

Surgically assisted orthodontic tooth movement has been used since the 1800s. Corticotomy-facilitated tooth movement was first described by L.C. Bryan in 1893, published in a textbook by S. H. Guilford.<sup>5</sup> In the past 50 years, rapid tooth movement without significant root resorption has been reported.<sup>6-9</sup> In these cases, the total treatment time was reduced to one-third to one-fourth that of traditional non-extraction and extraction orthodontic treatments.<sup>9</sup> The current corticotomy procedures adopted or modified by most clinicians are based on Heinrick Köle's combined radicular corticotomy/supraapical osteotomy technique, first described in 1959.<sup>6</sup> Köle's technique consisted of buccal and

<sup>1</sup>Director, Periodontology Program, Associate Professor of Clinical Dentistry, Division of Diagnostic Sciences, University of Southern California School of Dentistry, Los Angeles, California

<sup>2</sup>Clinical Assistant Professor, University of Southern California School of Dentistry, Los Angeles, California

<sup>3</sup>Resident, Periodontology Program, University of Southern California School of Dentistry, Los Angeles, California

lingual interproximal vertical corticotomy cuts limited to cortical layers, with these vertical corticotomy cuts being connected by horizontal osteotomy cuts approximately 1 mm beyond the apices of the roots. Then, in 1991, Suya replaced supraapical horizontal osteotomy with horizontal corticotomy to facilitate luxation of the corticotomized bone blocks.<sup>8</sup>

Wilcko et al<sup>3</sup> further modified the corticotomy-assisted orthodontic technique with the addition of alveolar augmentation and patented the procedure as periodontally accelerated osteogenic orthodontics (PAOO). Before Wilcko's modifications, alveolar augmentation was used to increase the thickness of alveolar bone to reduce the likelihood of dehiscence during rapid orthodontic tooth movement. Wilcko's modified technique used a combination of demineralized freeze-dried bone allograft (DFDBA)/xenograft (Osteograft<sup>®</sup>/N-300, DENTSPLY Friadent CeraMed, Lakewood, CO) or a bioabsorbable alloplastic graft (PerioGlas<sup>®</sup>, NovaBone Products, LLC, Jacksonville, FL) for alveolar augmentation. Buccolingual thickness of overlying buccal bone was increased with coverage of preexisting fenestrations. However, particles of the xenograft were found not incorporated on the superficial surface of augmented sites at reentry.

Köle attributed the accelerated tooth movement by selective corticotomy to moving "blocks of bone."<sup>6</sup> Köle believed that teeth were embedded and moved in "blocks of bone" connected to each other by medullary bone only, instead of today's understanding of how teeth move through alveolar bone. Therefore, he postulated that with less resistance from medullary bone compared with that from the denser cortical plate, rapid tooth movement could be achieved.

Recent evidence suggests a localized osteoporosis state, as a part of a healing event called regional acceleratory phenomenon (RAP), may be responsible for the rapid tooth movement.<sup>3</sup> RAP was first described by Frost in 1983,<sup>10</sup> although this phenomenon has been familiar to many histomorphometrists since 1966. Frost noted that the original injury somehow accelerated the normal regional healing processes. This acceleration is the regional acceleratory phenomenon. RAP usually occurs after a fracture, arthrodesis, osteotomy, or bone-grafting procedure, and may involve recruitment and activation of precursor cells necessary for wound healing concentrated at the site of injury.<sup>10,11</sup> RAP is not a separate healing event, but it can expedite hard- and soft-tissue healing stages two- to tenfold. Shih and Norrdin<sup>12</sup> demonstrated that when intraoral cortical bone was injured by corticotomy, RAP accelerated the normal

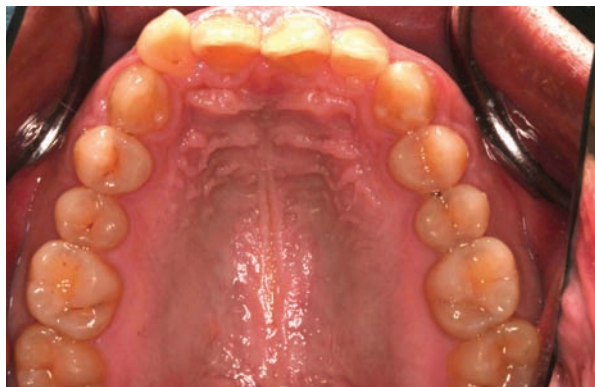


Figure 1 Pretreatment maxillary arch.

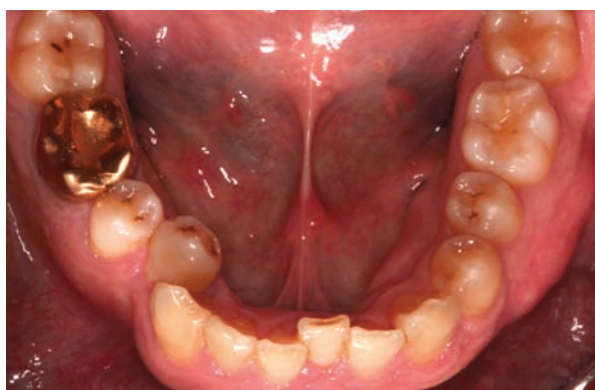

Figure 2 Pretreatment mandibular arch.

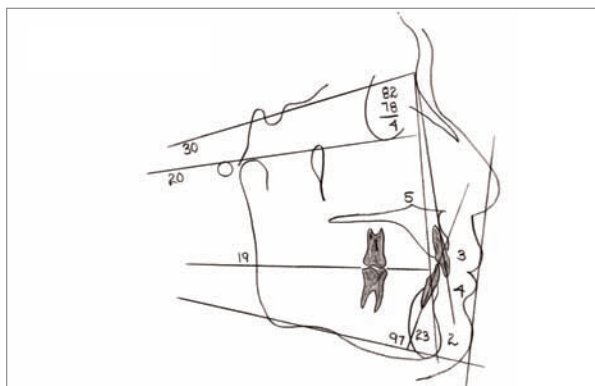
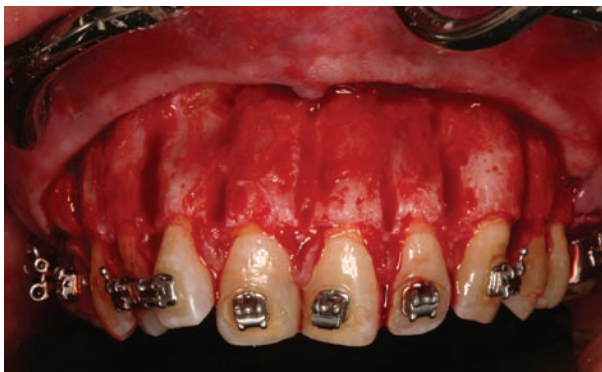

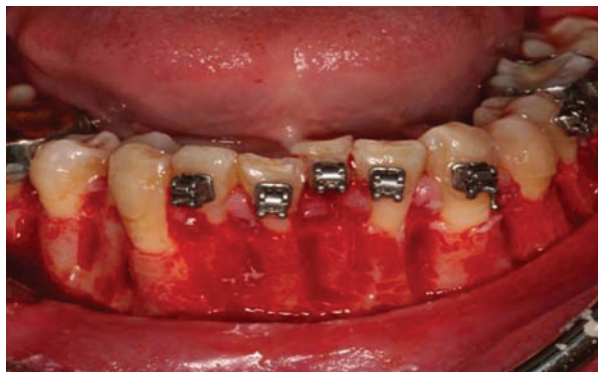Figure 3 Pretreatment cephalometric tracing.

regional healing processes by transient bursts of hard- and soft-tissue remodeling.

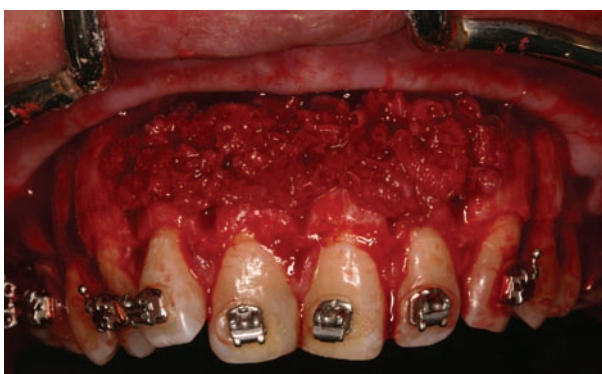The two main features of RAP in bone healing include decreased regional bone density and accelerated bone turnover, which are believed to facilitate orthodontic tooth movement.<sup>13,14</sup> Goldie and King<sup>13</sup> induced an osteoporosis state by depleting calcium intake in lactating rats and found an increase in the orthodontic tooth movement. In addition,



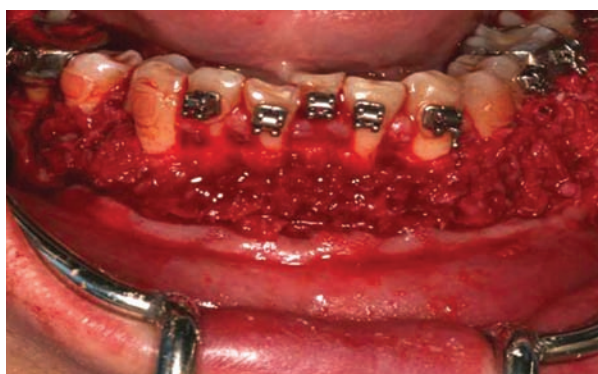**Figure 4** Buccal and facial selected corticotomy with vertical and horizontal cuts in maxilla.



**Figure 5** Buccal and facial selected corticotomy with vertical and horizontal cuts in mandible.



**Figure 6** Particulate autogenous bone graft laid down on maxilla after selected corticotomy.



**Figure 7** Particulate autogenous bone graft laid down on mandible after selected corticotomy.

reduced root resorption was demonstrated.<sup>13</sup> Most recently, Wilcko et al<sup>14</sup> showed radiographic evidence of an osteoporosis state in an alveolar bone treated with corticotomy, a characteristic seen in RAP. Data from computed tomography (CT) scans did not support the concept of “blocks of bone” movement, but suggested a demineralization-rem mineralization phenomenon. Additionally, the researchers found comparable tooth movement acceleration with small, round cortical perforations and with corticotomy cuts in a split-mouth design. This finding further supported that RAP is responsible for rapid orthodontic tooth movement.<sup>14</sup>

The use of particulate autogenous bone graft for alveolar augmentation with corticotomy-facilitated orthodontic tooth movement has never been documented. The purpose of this case report is to present the first clinical study using the corticotomy-facilitated orthodontic procedure combined with alveolar augmentation with autogenous particulate bone graft harvested from the rami and mandibular exostosis, a modified PAOO approach.

## CASE REPORT

The patient, a 41-year-old man, wanted to complete his orthodontic treatment more quickly than the normal treatment time of 2 years. A decision was made to perform PAOO. The patient presented the following malocclusions:

1. Class II, division 2 (maxillary canines were in mild class II position) (Figure 1)
2. 3-mm overjet
3. Severe overbite
4. 6-mm mandibular (Figure 2) and 3-mm maxillary crowding
5. Average profile (Figure 3)

## Surgical Procedures

All surgical procedures were performed after obtaining the consent of the patient. Under local anesthesia, full-thickness envelope flaps were raised with sulcular incisions while preserving interdental papilla on the buccal sides of maxillary and mandibular anterior regions only. No flap elevation or



corticotomy was performed on the palatal or lingual side in this case. Care was taken not to damage neurovascular bundles exiting mental foramina. Vertical corticotomy cuts were performed with round burs with water irrigation and in between roots from the distals of second premolars to the distals of the opposing second premolars on both arches. These vertical cuts were extended approximately 2 mm past the apices of the teeth and connected with horizontal corticotomy cuts. The vertical corticotomy cuts stopped about 2 mm short of the alveolar crests. Both corticotomy cuts and perforations were extended through the entire thickness of the cortical plate, just barely into the cancellous bone (Figure 4 and Figure 5).

Autogenous bone graft was harvested from the rami and mandibular exostosis. The horizontal envelope mucoperiosteal flap was extended to the retromolar areas. Particulate bone was harvested with bone scrapers from both rami and the exostosis on the buccal aspect of the mandibular right premolars and the first molar region. Particulate bone was laid down on the buccal aspects of the maxillary and mandibular anterior regions (Figure 6 and Figure 7). The mucoperiosteal flaps were replaced and sutured with 4-0 silk sutures. The patient was given amoxicillin, 500 mg *t.i.d.* for 10 days and chlorhexidine mouth rinse 0.12% *b.i.d.* for 2 weeks. Over-the-counter ibuprofen as needed was prescribed for postoperative discomfort. The sutures were removed after 1 week.

## Orthodontic Procedures

Full maxillary and mandibular braces (0.018 × 0.025) with self-ligating brackets were placed before periodontal surgery. Surgery was followed by the placement of the first arch wires (0.014 copper nitinol). A nitinol open-coil spring and a power thread were tied to displaced tooth No. 28; 0.016 copper nitinol and 0.016 × 0.022 copper nitinol wires then were placed in sequence to level and align the arches. After approximately 3 months, both maxillary and mandibular rectangular, stainless steel wires were placed (0.016 × 0.022); a rotation wedge was placed on tooth No. 28 to help complete alignment. Eight months after the surgery, detailing of the occlusion was completed and the braces were removed subsequently. Maxillary and mandibular removable Hawley retainers were delivered within 4 days.

The total active orthodontic treatment took 8 months. Routine orthodontic adjustments were made every 2 weeks. The following orthodontic results were achieved:

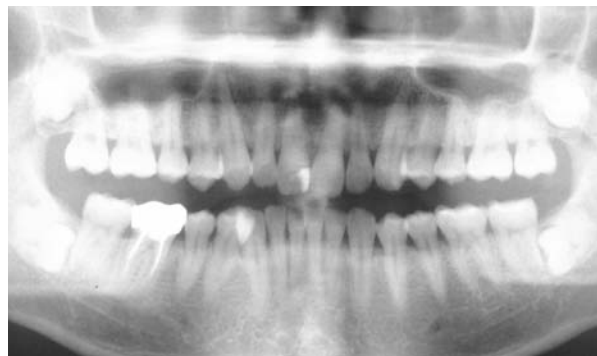


Figure 8 Pretreatment panoramic radiograph.

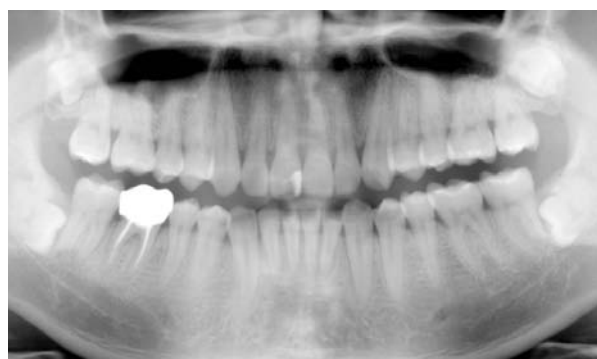


Figure 9 Panoramic radiograph at the completion of orthodontic treatment.

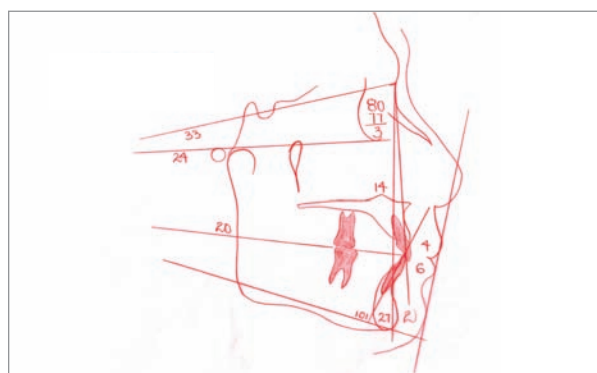
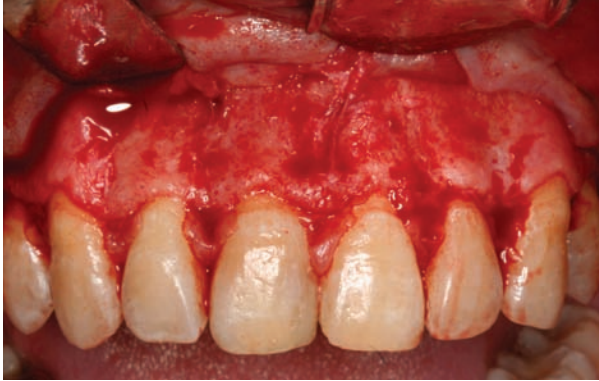
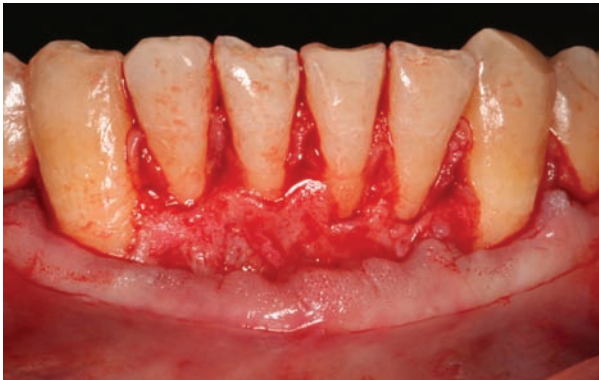
Figure 10 Cephalometric tracing at the completion of orthodontic treatment.

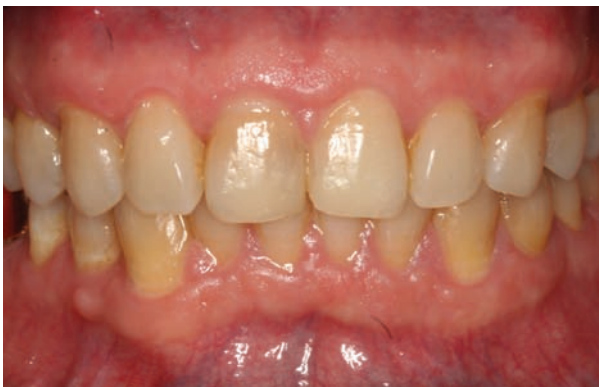1. Ideal class I occlusion obtained.
2. Overjet remained the same—3 mm.
3. Anterior closed bite was opened by 4 mm.
4. Mandibular plane angle increased from 20° to 24°. The 4° change, along with the 2 mm of maxillary incisor intrusion, contributed to the bite opening achieved. The mandibular incisors remained in approximately the same vertical position.



**Figure 11** Buccal alveolar ridge of maxilla 1 year after selected corticotomy.



**Figure 12** Buccal alveolar ridge of mandible 1 year after selected corticotomy.



**Figure 13** Final centric occlusion 1 year after selected corticotomy.

5. Maxillary incisor labial angulation was increased from 5° to 14°.
6. Mandibular incisors tipped labially by 4° (97° to 101°), which indicated that most of the arch length gained occurred through expansion in the buccal segments.

Ideal esthetic and functional results were achieved in 8 months or one-third the average treatment time without detrimental periodontal effects or root resorption (Figure 8 through Figure 10).

### Reentry

One year after the corticotomy surgery, both maxillary and mandibular anterior buccal regions were revisited. Under local anesthesia, full-thickness mucogingival flaps were raised on the buccal aspects. Resorption and remodeling of particulate autogenous bone graft was evident in both arches. The thickness of the buccal plates in the maxilla and mandible remained unchanged. There was no loss in the alveolar height, and no new fenestration or dehiscence on the teeth was observed (Figure 11 through Figure 13).

### DISCUSSION

In this case study, ideal esthetic and functional results were achieved in 8 months (one-third the average treatment time). According to Hajii,<sup>9</sup> an average treatment time for the PAOO procedure was one-third to one-fourth of traditional orthodontic treatment. Wilcko et al<sup>14</sup> reported an average of 6.1 months of treatment time for the PAOO procedure. The authors' case result agreed with these observations. However, unlike the procedures described by Köle<sup>6</sup> and Wilcko et al,<sup>3</sup> corticotomy was performed only at the buccal aspects of both the maxilla and mandible in this case. This was in agreement with Germec et al,<sup>15</sup> who reported rapid tooth movement when corticotomy was performed at the buccal aspects of alveolar bone. The researchers noted that the elimination of palatal and lingual corticotomy reduced the length and the extent of the surgery and avoided the risk of violating vital lingual anatomy.<sup>15</sup>

The authors' case study is the first to report the use of particulate autogenous bone graft with the PAOO procedure. Intramembranous autogenous bone grafts have been used in the restoration of osseous volume as the gold standard of alveolar ridge reconstruction. Intraoral donor sites include the maxillary tuberosity, mandibular symphysis, angle of the mandible, ramus, and exostosis.<sup>16</sup> The advantages of autogenous bone grafts include potential osteogenesis from surviving bone cells, osteoinductivity from cytokines and growth factors, and osteoconductivity from the autogenous bone. The particulate form of autogenous bone graft has been used successfully for filling intrabony periodontal defects, sinus augmentation, and guided bone regeneration.<sup>17,18</sup>

Alveolar augmentation with DFDBA/xenograft (bovine bone) or alloplastic graft (bioactive glass) was described by Wilcko et al<sup>3</sup> to cover any fenestrations and dehiscences and increase bony support for teeth with corticotomy-assisted orthodontic tooth movement. The authors noticed that particles of xenograft were not fully incorporated at reentry. These graft materials, having the advantages of availability and no secondary surgery, are not comparable with autogenous bone graft, which facilitates bone integration. Literature has shown that only 37% of bone-to-graft contact was present for bovine bone xenograft after 6 to 7 months.<sup>19</sup> Biopsies from DFDBA-filled extraction sockets showed dead DFDBA particles embedded in dense connective tissue with little to no new bone formation.<sup>20</sup> Biopsies from bovine bone xenograft showed dead particles surrounded by connective tissue and only isolated sections showed host bone-ovine contact with various degrees of new bone formation.<sup>20</sup> In a different study, it was found that particulate DFDBA remained encapsulated in connective tissue when used for lateral ridge augmentation.<sup>21</sup> A recent study revealed that bioactive glass was not able to contribute to vertical ridge augmentation and only a small gain in horizontal ridge width (average 1.1 mm) occurred 6 months after a guided bone regeneration procedure was used. In spite of being extremely bioabsorbable, the histology revealed encapsulation of residual particles with connective tissue.<sup>22</sup>

In this case, the authors found that, on reentry, bone configuration was maintained for both the maxillary and mandibular arches without significant augmentation. The volume of autogenous bone harvested in this case was significantly less than that recommended by Wilcko et al.<sup>3</sup> Autogenous bone graft is known to undergo extensive resorption when used in a lateral augmentation procedure.<sup>21</sup> In clinical observation, at reentry after 1 year, resorption and remodeling of the autogenous graft was evident in both the maxilla and mandible. The maxillary and mandibular incisors were tipped 14° facially.

Facial tipping of incisors can result in thinning of facial alveolar bone.<sup>23</sup> In this case, however, the thickness of maxillary and mandibular buccal plates was not increased and an anatomically sound alveolar configuration was maintained. This result may be partially attributed to the autogenous bone graft. However, the optimal quantity of bone graft has not been determined and, as this report demonstrates, more clinical research should be undertaken to determine the optimal amount of autogenous bone graft.

## CONCLUSION

Because this study included only one patient, the conclusions reached are limited. It is recommended that more clinical studies be performed with additional patients and long-term follow-up. However, this case suggests the following conclusions:

1. PAOO is an effective treatment approach in adults to decrease treatment time and reduce the risk of root resorption.
2. Using a modified surgical approach and limiting the corticotomy to the buccal and labial aspects produced the RAP needed to significantly reduce treatment time.
3. The reduction of surgery time and patient discomfort are basic advantages to a modified surgical approach.
4. More clinical research is needed to determine the optimal amount of autogenous bone graft.

## REFERENCES

1. Vig PS, Weintraub JA, Brown C, et al. The duration of orthodontic treatment with and without extractions: a pilot study of five selected practices. *Am J Orthod Dentofacial Orthop.* 1990; 97(1):45-51.
2. Kocadereli I. Changes in soft tissue profile after orthodontic treatment with and without extractions. *Am J Orthod Dentofacial Orthop.* 2002;122(1):67-72.
3. Wilcko WM, Wilcko T, Bouqurot JE, et al. Rapid orthodontics with alveolar reshaping: two case reports of decrowding. *Int J Periodontics Restorative Dent.* 2001;21(1):9-19.
4. Reitan K. Biomechanical principles and reactions. In: Graber TM, Swain BF. *Orthodontics: Current Principles and Techniques.* St. Louis, MO: C.V. Mosby Company; 1985:101-192.
5. Guilford SH. *Orthodontia: Or Malposition of the Human Teeth, Its Prevention and Remedy.* Philadelphia, PA: Spangler and Davis; 1893.
6. Köle H. Surgical operations on the alveolar ridge to correct occlusal abnormalities. *Oral Surg Oral Med Oral Pathol.* 1959; 12(5):515-529.
7. Anholm JM, Crites DA, Hoff R, et al. Corticotomy-facilitated orthodontics. *J Calif Dent Assoc.* 1986;14(12):7-11.
8. Suya H. Corticotomy in orthodontics. In: Hösl E, Baldauf A, eds. *Mechanical and Biological Basis in Orthodontics Therapy.* Heidelberg, Germany: Hütlig Buch; 1991:107-226.
9. Hajji SS. The influence of accelerated osteogenic responses on mandibular de-crowding [thesis]. St. Louis, MO; St Louis University; 2000.

## Continuing Education 1

10. Frost HM. The regional acceleratory phenomenon: a review. *Henry Ford Hosp Med J*. 1983;31(1):3-9.
11. Frost HM. The biology of fracture healing. An overview for clinicians. Part I. *Clin Orthop Relat Res*. 1989;(248):283-293.
12. Shih MS, Norrdin RW. Regional acceleration of remodeling during healing of bone defects in beagles of various ages. *Bone*. 1985;6(5):377-379.
13. Goldie RS, King GJ. Root resorption and tooth movement in orthodontically treated, calcium-deficient, and lactating rats. *Am J Orthod*. 1984;85(5):424-430.
14. Wilcko WM, Ferguson DJ, Bouquot JE, et al. Rapid orthodontic decrowding with alveolar augmentation: case report. *World J Orthod*. 2003;4:197-205.
15. Germec D, Giray B, Kocadereli I, et al. Lower incisor retraction with a modified corticotomy. *Angle Orthod*. 2006;76(5):882-890.
16. D'Addona A, Nowzari H. Intramembranous autogenous osseous transplants in aesthetic treatment of alveolar atrophy. *Periodontol 2000*. 2001;27:148-161.
17. Hegedüs Z. The rebuilding of the alveolar process by bone transplantation. *Dental Cosmos*. 1923;65:736.
18. Misch CE, Dietsch F. Bone-grafting materials in implant dentistry. *Implant Dent*. 1993;2(3):158-167.
19. Zitzmann NU, Schärer P, Marinello CP, et al. Alveolar ridge augmentation with Bio-Oss: a histologic study in humans. *Int J Periodontics Restorative Dent*. 2001;21(3):288-295.
20. Becker W, Clokie C, Sennerby L, et al. Histologic findings after implantation and evaluation of different grafting materials and titanium micro screws into extraction sockets: case reports. *J Periodontol*. 1998;69(4):414-421.
21. von Arx T, Cochran DL, Hermann JS, et al. Lateral ridge augmentation using different bone fillers and barrier membrane application. A histologic and histomorphometric pilot study in the canine mandible. *Clin Oral Implants Res*. 2001;12(3):260-269.
22. Knapp CI, Feuille F, Cochran DL, et al. Clinical and histologic evaluation of bone-replacement grafts in the treatment of localized alveolar ridge defects. Part 2: bioactive glass particulate. *Int J Periodontics Restorative Dent*. 2003;23(2):129-137.
23. Wingard CE, Bowers GM. The effects of facial bone from facial tipping of incisors in monkeys. *J Periodontol*. 1976;47(8):450-454.

1. Because dentoalveolar development ceases after adolescence, it is more likely for adult patients to experience:
  - a. a highly vascular periodontal membrane.
  - b. root resorption.
  - c. porous bone.
  - d. all of the above
2. Corticotomy-facilitated tooth movement was first described in:
  - a. 1783.
  - b. 1893.
  - c. 1963.
  - d. 1993.
3. In the past 50 years, rapid tooth movement without significant root resorption has been reported to reduce total treatment time to how much of that of traditional nonextraction and extraction orthodontic treatment?
  - a. two-thirds to one-half
  - b. one-half to one-third
  - c. one-third to one-fourth
  - d. one-fourth to one-eighth
4. K le's combined radicular corticotomy/supraapical osteotomy technique used horizontal osteotomy cuts approximately how far beyond the apices of the roots?
  - a. 0.5 mm
  - b. 1 mm
  - c. 1.5 mm
  - d. 2 mm
5. Wilcko modified the corticotomy-assisted technique with the addition of:
  - a. a connective-tissue graft.
  - b. an autogenous bone graft.
  - c. alveolar augmentation with demineralized freeze-dried bone allograft/xenograft.
  - d. all of the above
6. Which two main features of regional acceleratory phenomenon are believed to facilitate orthodontic tooth movement?
  - a. increased regional bone density and decelerated bone turnover
  - b. decreased regional bone density and decelerated bone turnover
  - c. increased regional bone density and accelerated bone turnover
  - d. decreased regional bone density and accelerated bone turnover
7. In this case, autogenous particulate bone was laid down on what aspects of the maxillary and mandibular anterior regions?
  - a. lingual
  - b. buccal
  - c. palatal
  - d. all of the above
8. In this case, ideal esthetic and functional results were achieved in:
  - a. 6 months.
  - b. 8 months.
  - c. 10 months.
  - d. 12 months.
9. In clinical observation, at reentry after 1 year, what was evident in both the maxilla and mandible?
  - a. resorption and remodeling of the autogenous graft
  - b. tipped incisors
  - c. root recession
  - d. grooves between the roots
10. In this case, the thickness of the maxillary and mandibular buccal plates was:
  - a. increased by 0.5 mm.
  - b. increased by 1 mm.
  - c. increased by 1.5 mm.
  - d. not increased.

Please see tester form on page xx.

This article provides 1 hour of CE credit from Ascend Dental Media, now operated by AEGIS Communications. Record your answers on the enclosed answer sheet or submit them on a separate sheet of paper. You may also phone your answers in to (888) 596-4605 or fax them to (703) 404-1801. Be sure to include your name, address, telephone number, and last 4 digits of your Social Security number.