

## REVIEW ARTICLE

# Bisphosphonate-related osteonecrosis of the jaws: a comprehensive review

Catherine Hewitt and Camile S. Farah

*Oral Medicine and Pathology, School of Dentistry, The University of Queensland, Brisbane, Australia*

**BACKGROUND:** Bisphosphonate-related osteonecrosis of the jaws (BRONJ) presents the clinician with significant management dilemmas. The purpose of this study was to distil information related to this disorder by comprehensively reviewing the literature.

**METHODS:** The structure and function of bisphosphonates, and their role in the development of BRONJ will be discussed, as will the possible mechanisms through which this pathology develops. A review of cases presented in the literature will be undertaken, and suggestions offered as to the management of this pathology in terms of surgical and conservative approaches.

**RESULTS:** Presentation of BRONJ is currently more common in patients taking intravenous forms of bisphosphonates, but there is a fear that the long-term cumulative effects of oral bisphosphonates may see BRONJ increasingly occurring in this patient group.

**CONCLUSIONS:** Prevention is superior to treatment, and the establishment of meticulous oral hygiene and pre-emptive surgical treatment prior to commencement of bisphosphonate therapy is recommended.

*J Oral Pathol Med* (2007) 36: 319–28

**Keywords:** bisphosphonate; jaws; osteonecrosis; review; treatment strategies

## Introduction

Osteonecrosis (ON), death of bone, occurs as a result of impaired blood supply (1). Both cancer and its treatment have been associated with an increase in the risk of ON, with the most common site of presentation being the femoral head (2). Osteonecrosis of the jaws (ONJ) is well documented in patients who have had radiation therapy of the head and neck, and is termed osteoradionecrosis (ORN).

Since the introduction of bisphosphonates, there have been increasing reports in the literature of the occurrence of ON of the jaws in patients taking these medications (1, 3, 4). The intravenous, nitrogen-containing bisphosphonates (pamidronate and zoledronate) have dominated this presentation (5, 6); however, there have also been cases of ONJ in individuals taking long-term oral preparations such as alendronate. A direct correlation has been demonstrated between the use of pamidronate, zoledronate, and less often, alendronate and the painful exposure of the bone in the mandible and maxilla (2, 4). With an increase in bisphosphonate prescriptions there is the potential for a dramatic increase in case presentation (7).

Historically, bisphosphonates date back to the middle of the 19th century, where their use was mainly industrial. Their biological characteristics were first reported in 1968 (8). Bisphosphonates have evolved since the 1970s when these preparations were first used in medicine. In the early 1990s bisphosphonates were employed as a diagnostic agent in various disorders of bone and calcium metabolism (9). Currently, oral bisphosphonates are used widely in the treatment of osteoporosis (10–13). Intravenous regimes are designed to treat the complications of metastatic disease and primary osteolytic pathology of bone (multiple myeloma and Paget's disease). These drugs have been successful in ameliorating the effects of hypercalcaemia of malignancy and associated pain of osteolytic bone pathology (14, 15).

Bisphosphonates appear to express their effects at three levels: tissue, cell and molecular (6). Two broad theories have been articulated to explain the pathogenesis of bisphosphonate-related osteonecrosis of the jaws (BRONJ). One centres on the bisphosphonate induced osteoclast inhibition and the other explains the process in terms of antiangiogenic mechanisms (2). Both try to address the predilection for this occurrence in the jaws. In most cases the development of ONJ in those taking bisphosphonates has been associated with trauma, predominantly dental extraction (3, 4, 16, 17). However, there have been reports of spontaneous occurrences in the absence of overt trauma (18).

Correspondence: Dr Camile S. Farah BSc, MSc, PhD, GCEd (HE), FRACDS (Oral Med), Consultant in Oral Medicine and Pathology, School of Dentistry, The University of Queensland, Brisbane QLD 4072, Australia. Tel: +61 7 3365 8840, Fax: +61 7 3365 8840, E-mail: c.farah@uq.edu.au  
Accepted for publication February 12, 2007

During the course of this paper, the structure and function of bisphosphonates will be discussed. The role these drugs play in the development of ONJ and the possible mechanisms through which this pathology develops will be explored. A review of cases presented in the literature will be undertaken. Finally, suggestions offered as to the management of this pathology in terms of surgical and conservative approaches, and the impact cessation of bisphosphonates has on the course of these treatments will be outlined.

### Structure of bisphosphonates

Bisphosphonates contain a phosphate-carbon-phosphate (P-C-P) backbone with two side chains,  $R_1$  and  $R_2$  attached to a carbon atom (18, 19). The  $R_1$  chain, usually a hydroxyl group, enhances the compounds' affinity for bone, but has no antiresorptive effect (19). The structure and conformation of  $R_2$  confers the antiresorptive potency of the compound and determines its efficiency (18, 19). The location of the two groups on the same carbon atom identifies them as germinal bisphosphonates and analogues of pyrophosphate (20).

Changing the side chain allows enormous variation in structure giving each bisphosphonate its own chemical, physicochemical and biological characteristics, thus implying some caution in extrapolating results of one compound to those of another regarding activity and effect (20). Drug potency has increased with each successive generation, as the  $R_2$  side chain was lengthened, incorporated an amino group, and finally a tertiary amino group giving the third generation a potency 10 000-fold greater than the first (19).

### Mechanism of action

Bisphosphonates are analogues of inorganic pyrophosphate (PPi). The 3D structure of bisphosphonates as discussed above, allows chelation of divalent metal ions such as calcium. This enables the bisphosphonates to be rapidly cleared from the circulation to target hydroxyapatite at sites of active bone remodelling (21). The bound bisphosphonates are released as the pH decreases in the resorptive lacuna beneath the osteoclast (21).

Bisphosphonates can be separated into two general classes according to their chemical structure and molecular mechanism of action (21, 22). Simple bisphosphonates such as clodronate, etidronate and tiludronate which resemble PPi, and as such can accumulate intracellularly in osteoclasts as non-hydrolysable analogues of adenosine triphosphate (ATP) and induce apoptosis (21). Simple bisphosphonates are incorporated into the osteoclasts and undergo condensation with adenosine monophosphate (AMP). The metabolite formed from this condensation reaction accumulates intracellularly. It appears that inhibition of numerous intracellular enzymes ensues, disrupting cellular function and resulting in apoptosis (21). These simple bisphosphonates therefore act as pro-drugs which are converted to active metabolites only following intracellular absorption by osteoclasts. Their cumulative cell

cytotoxicity effectively inhibits bone resorption by causing osteoclast apoptosis (21).

The nitrogen-containing and more potent bisphosphonates (N-BP) such as pamidronate, risedronate, zoledronate and alendronate, inhibit sterol synthesis via the mevalonate pathway, inducing osteoclast apoptosis and therefore inhibiting bone resorption via a mechanism different from those employed by simple bisphosphonates (21). Specifically, the farnesyl diphosphate synthase (FPP) is the enzyme in the mevalonate pathway inhibited in osteoclasts (21). Importantly, only nanomolar concentrations of the N-BP are required to inhibit this enzyme which probably accounts for their greater association with BRONJ than that of the earlier PPI analogues. The more potent N-BPs act as isoprenoid diphosphate lipid analogues inhibiting FPP synthase in the mevalonate pathway. In doing so, these compounds inhibit isoprenoid lipids essential for post-translational farnesylation and geranylation of small GTPase signalling proteins. Loss of these signalling proteins is instrumental in loss of resorptive activity and apoptosis of osteoclasts (21, 22).

Bisphosphonates affect the metabolic activity of bone at the tissue, cell and molecular levels (3, 6). At the tissue level, biochemical markers have demonstrated a reduction in bone turnover and resorption. The alteration in bone formation is dictated by the degree to which bone turnover is inhibited, given the two processes are inextricably linked (3).

Bisphosphonates act at the cell level by targeting osteoclasts and disrupting their function in several ways. They inhibit osteoclast recruitment, reduce osteoclast lifespan and inhibit bone surface activity of these cells. In doing so, bone resorption is affected (3). In molecular terms, studies suggest that the osteoclastic function is altered by the interaction of bisphosphonates with either a cell surface receptor or an intracellular enzyme (3).

There is also evidence that bisphosphonates act on osteoclasts indirectly via their effects on osteoblasts (23). This is thought to occur by altering osteoblast secretion of soluble paracrine factors involved in regulation of osteoclast activity (23). Reinholz et al. studied the effect of bisphosphonates on cell proliferation, gene expression and bone formation by cultured foetal osteoblasts (23). While osteoblast cell proliferation was reduced by pamidronate, a dose-dependent increase was seen in total cellular protein, alkaline phosphatase activity and type I collagen secretion (23).

Comparison between zoledronate, a potent newer analogue and the weaker acting etidronate were also made using the same parameters. Zoledronate was found to have equivalent potency in terms of inhibition of cell proliferation, whereas higher concentrations of etidronate were required to achieve a similar effect (23). This difference was explained by a reduction in free divalent ion concentration by etidronate and actions of the more potent pamidronate and zoledronate were executed by a more direct action on osteoblasts. These more potent analogues also increased the rate of human foetal osteoblast bone formation while etidronate had no effect on this process. This may explain the *in vivo*

differences between the potencies of the newer generation analogues and etidronate (23).

Once integrated into the skeleton, bisphosphonates are only released when bone is destroyed during physiological bone turnover. The skeletal half-life in mice and rats, ranges between 3 and 12 months, but this is > 10 years in humans (20). Additionally, *in vivo* the stability of the P-C-P bond to heat, the effect of chemical agents, and enzymatic hydrolysis ensures that bisphosphonates are not metabolized.

### Indications for bisphosphonate therapy

Bisphosphonates are in widespread use to stabilize bone loss in post-menopausal women. The aim of therapy was to preserve bone density by inhibiting osteoclastic resorption of trabecular bone (2). Oral bisphosphonates such as etidronate, risedronate, tiludronate and alendronate are examples of bisphosphonates commonly used in the management of osteoporosis (2, 3).

Normally, destroyed bone is replaced by bone formation. For adults, this commonly occurs at sites where remodelling in both trabecular and cortical bone surfaces is taking place. The bone modelling unit (BMU) is the dynamic unit of bone turnover, and remodelling starts with the erosion of bone on the surface of the trabeculae and the surface and interior of the cortex. The resorptive path is linear and forms a canal within the cortex and a trench on the surface of the cortex. A tight temporal sequence governs the refilling of these deficits by the osteoblasts, with resorption followed by reformation. In normal situations there is no net deficit in resorption or net gain in formation, thus a change in turnover will have no influence on the total calcium balance (10). The loss of bone and deterioration in trabecular micro-architecture that defines osteoporosis, results from a negative imbalance between bone resorption and formation. During childhood and adolescence, resorption rates are also high; however, bone formation is even higher which results in a net skeletal gain (10). In post-menopausal women, there is an increase in bone turnover which effectively reduces the mean degree of mineralization of bone (MDMB) by disrupting secondary mineralization of basic structure units (BSU). Secondary mineralization is a slow and progressive increase in mineral content that follows the primary deposition of mineral substance on the calcification front. With increased bone turnover post-menopause, some of the BSU are resorbed before undergoing complete secondary mineralization. There is literally insufficient time for completion of crystal maturation (11). Antiresorptive agents such as bisphosphonates reduce bone turnover and thus prolong the duration of secondary mineralization.

In the case of metastatic osteolytic disease of bone and primary resorptive malignancies of bone (multiple myeloma, Paget's disease), more potent intravenous bisphosphonates (pamidronate and zoledronate) are used. The dual outcome of reduced resorptive effects of the disease process, along with correction of severe hypercalcaemia of malignancy, has served to consider-

ably enhance both the quantity and quality of life in these individuals (2). Worldwide, over 3 million patients have been treated with zoledronate and it is currently the mainstay of treatment for hypercalcaemia of malignancy (24).

According to the American Society of Clinical Oncology, bisphosphonate therapy is considered a standard in cases of moderate to severe hypercalcaemia associated with malignancy, metastatic osteolytic lesions associated with breast cancer and multiple myeloma (3). Hypercalcaemia clinically results in confusion, anorexia, abdominal pain, muscular pain and weakness and left untreated can progress to renal failure and death as dehydration occurs (7). Most cases of bisphosphonate-related osteomyelitis and ON of the jaws reported in the literature are associated with the injectable forms of these drugs such as pamidronate and zoledronate (24). The long-term effects of the oral bisphosphonates may yet prove to be of substantial clinical concern given that alendronate, with 17 million prescriptions, was listed as the 19th most common prescription drug in 2003 (24).

### Pathogenesis of BRONJ

Currently, the pathogenesis of BRONJ is not completely defined, but may include bisphosphonate alteration of angiogenesis or bone micro-architecture (25). Alternatively mucosal inflammation in response to oral flora may initiate a cascade of events that culminate in bone necrosis (25). Additionally, genetic predisposition centred on polymorphisms in drug or bone metabolism offer a further possibility in what is likely to be a multifactorial pathogenic model of BRONJ. The unknown incidence of BRONJ in the general population makes the possibility of wider pathogenic mechanisms unclear at this stage (25).

Bisphosphonates are thought to concentrate in the jaws due to the associated physiology of this part of the skeleton. Namely the greater degree of vascularization and the daily remodelling that occurs around the periodontal ligament of the teeth (2). In addition, the chronic nature of invasive dental disease, and the treatment it requires, occurs in a location where adjacent bone is minimally protected by a thin mucosal covering (26). The fragility of this mucosal barrier is demonstrated in cases of lingual mandibular sequestration with ulceration resembling mild cases of BRONJ (27, 28). This serves to explain in part why bisphosphonate-related ON manifests itself mostly in the jaws and not other sites of the skeleton (2).

Currently, two main theoretical positions attempt to explain the mechanism for this complication of bisphosphonate therapy. The first explains the pathology in terms of the osteoclastic-inhibiting effect of this class of drug on the cessation of bone remodelling and bone turnover (2). In the case of osteoporosis, the moderately potent bisphosphonates control, rather than cure, and in doing so have a less restrictive effect on osteoclastic function. Unless these drugs are given over protracted time frames to provide a cumulative effect, there is no

significant prevalence of bone exposure in this treatment group noted at this time (2).

The intravenous preparations used in the treatment of metastatic disease, irreversibly inhibit osteoclasts via interrupting the mevalonate pathway and the resulting toxicity causes osteoclast apoptosis (2). Thus, the malignancies that serve to activate osteoclasts can no longer do so, preventing the malignancy from resorbing bone into which it can then proliferate. Osteoblasts and osteocytes have a 150-day lifespan. If on their demise, there is no osteoclastic resorption of mineral matrix and the resultant release of bone morphogenetic protein and insulin-like growth to induce stem cell production of osteoblasts, the osteon becomes acellular and necrotic (2). There is subsequent involution of blood vessels leaving the bone avascular. Any mechanism that leads to the breakdown of the overlying mucosa will expose the necrotic bone which fails to heal (2).

The second theory states that the inhibition of neo-angiogenesis by bisphosphonates leads to loss of blood vessels in the jaws and avascular necrosis (2). Pamidronate and zoledronate have both been shown to inhibit angiogenesis, inhibit capillary tube formation and inhibit epithelial growth factor and vessel sprouting both *in vitro* and in a rat model (2, 3). Inhibition of the mevalonate biosynthetic pathway essentially inhibits the GTP-signalling pathways that are also involved in epithelial migration (29). These researchers propose that such antiangiogenic effects of bisphosphonates accentuate their use in osteolytic malignancies by having a primary effect on tumour angiogenesis (29). This positive treatment effect may well be instrumental in the increased incidence of ON in patients taking newer generation bisphosphonates (29). Woods et al. demonstrate clear evidence of both *in vitro* and *in vivo* inhibition of angiogenesis by zoledronate in a dose-related manner (29). However, others have argued that drugs such as thalidomide, with far greater antiangiogenic capacity, do not result in ONJ (2). Clearly, the effect of bisphosphonates on angiogenesis in the development of ONJ has yet to be fully elucidated (24).

Polizzotto and Wood share the opinion that ON in the presence of trauma occurs as a result of bisphosphonate-reduced osseous remodelling and blood flow, which prevent an appropriate response to increased physiological demand (29, 30). McMahon et al., equated the bisphosphonates with exogenous steroids and oestrogen as simply another stressor on bone that could shift the balance in favour of ON (31). These authors view these drugs as being just one of the many 'hits' in the multiple-hit thrombosis model currently used to describe ischaemic bone disease. McMahon et al. cautioned against blind acceptance of an apparent 'growing epidemic' of bisphosphonate-related ONJ, implying that a multifactorial process was more likely driving this presentation of ONJ than just the effects of bisphosphonates (31).

The mechanisms involved in the development of BRONJ remain incompletely defined; however, research thus far point towards an alteration of bone metabolism in conjunction with surgical insult or prosthetic trauma

as key factors in the pathological presentation (16). Indeed, Polizzotto et al. have recently reported the first case of proposed bisphosphonate-related ON outside the region of the jaws (30). A 63-year-old male had developed mobile teeth and bilateral exostosis of the auditory canals. Surgical removal of the exostosis of the left auditory canal and extraction of the mobile teeth were undertaken. Painful, non-healing sockets developed post-operatively and a painless ulceration was noted at the operative site of the left auditory canal 6 months post-treatment. Necrotic bone extending well beyond the ulcerative margin was exposed. Both clinical and radiographic examination excluded evidence of malignancy or infection at both sites (30).

Many authors have reported cases where tooth extraction was a precipitating event in the development of BRONJ (3–5, 16, 17); however, reports of non-extraction cases emphasize the gaps in current understanding regarding the spectrum of effects that bisphosphonates have on bone metabolism, vascularization and co-morbid conditions including effects of concurrent medications. These incidences should not serve to discount the potential for devastating post-surgical extraction sequelae in those patients receiving intravenous bisphosphonates, rather the inconclusive data should impel both researchers and practitioners to understand how these drugs affect bone tissue and incite necrosis without obvious mitigating trauma. Although the current incidence of BRONJ is low (0.1–1% of all patients on bisphosphonates) the possibility of a cumulative effect towards a threshold dose is sobering (7).

### Other potential risk factors for osteonecrosis

Although there appears to be increasing evidence supporting the association of bisphosphonates with the development of ONJ, other antiangiogenic drugs along with the systemic effects of the underlying disease need further evaluation to determine what role, if any, they may have in the pathogenesis of this condition (32). It is difficult to determine the individual importance of each variable; however, it is not unreasonable to surmise that several predisposing factors may act concurrently in the development of BRONJ (32). Most patients who develop BRONJ, have also received or are receiving corticosteroids or chemotherapeutic agents (1). It is impossible to analyse the relative contribution of chemotherapy regimes given their considerable diversity and timing (1). Similarly, there is no standardized regime for the use of corticosteroids in the treatment of bony pathology, and a research paradigm aimed at investigating the role these agents play in bisphosphonate-induced ONJ is needed (1).

Potential risk factors for ONJ other than bisphosphonates include corticosteroids, coagulopathy, alcohol abuse, tobacco use, infections and inflammation (25). Sixty-four percentage of the sample presented by Pires et al. had anaemia, leucopenia and/or thrombocytopenia at the time of diagnosis of BRONJ (32). Blood cell counts and the presence of immunosuppression are common findings among cancer patients having

adjunctive bisphosphonate treatment, and each can lead to bone infection and necrosis (32). Likewise, oral infections that lead to a breach in mucosal integrity enhance the risk of ON in the affected area. Sung et al. described a patient with a previous history of herpes simplex virus (HSV) developing ON in the area affected (33). They surmised that the ulceration associated with HSV lesions resulted in the breakdown of the protective mucosa thereby increasing the risk of ON (33).

Lenz et al. described a patient who developed ONJ 6 years following both surgical treatment and two cycles of chemotherapy for breast cancer (9). Six years later the patient presented in an anaemic state with ONJ confirmed on biopsy. Treatment culminated in extended surgery when neither conservative debridement nor antibiotic therapy proved to be successful long term. There is a higher incidence of anaemia in older patients with cancer and this provides support for the possible multifactorial aetiological basis for ONJ (34, 35). The anaemic condition of the patient was not expanded upon in the report, and no conclusions were drawn concerning the possible effect this background state may have had on the development of ONJ. It does, however, emphasize the role that chemotherapeutic agents may play in the development of ONJ in these patients (34, 35).

The research literature remains limited in terms of explicating the role of chemotherapy in the development of BRONJ. The above hints at a possible interaction between immune suppression and the development of BRONJ in those receiving both bisphosphonates and chemotherapy; however, it is not clear whether there exists a synergistic effect between these two drug classes in certain individuals. The lack of ON as a complication of other systemic chemotherapeutic agents for non-haematological malignancy suggests that cancer chemotherapy regimes are less likely to be important in the pathogenesis of ON in non-irradiated jaws than the use of bisphosphonates (36).

### Reported cases of BRONJ

Thirty-six cases of painful bone exposure in the mandible, maxilla or both in patients receiving bisphosphonates for hypercalcaemia of malignancy have been described by Marx (5). Marx was the first to characterize the association of this entity with bisphosphonate treatment (5). Wang et al. reported ONJ in three patients with metastatic breast cancer receiving intravenous bisphosphonates (36), while Migliorati reported five cases of mandibular ONJ (17). In all 63 patients presenting for treatment of ON of the jaw reported by Ruggiero et al., the only common factor was bisphosphonate treatment (3).

Zarychanski et al. reported 12 cases of ONJ associated with intravenous pamidronate therapy for multiple myeloma, breast cancer or renal cell carcinoma involving bone (37). Two presentations were spontaneous, two were proposed to result from ill-fitting prostheses, and the remainder were associated with dental extraction with or without abscess formation. Pires et al. reported 14 cases of ONJ in patients receiving cancer

chemotherapy across five clinic sites in Brazil (32). Of these 14, 12 were also receiving bisphosphonate therapy.

Bamias et al. conducted a prospective study on 252 patients who received bisphosphonates as adjunctive therapy for multiple myeloma, breast or prostate cancer, or other neoplasms (1). Of the 252 subjects, 17 (6.7%) developed ONJ. Farrugia et al. carried out a retrospective 12-month chart review and identified 23 patients with ONJ without evidence of metastatic disease at the site (6). All patients were taking the new generation bisphosphonates (zoledronate, pamidronate, alendronate) and none had received radiation treatment. Of the 23 subjects, 18 with known bone metastasis were treated with the intravenous form and the remainder with a diagnosis of either osteoporosis or Paget's disease were taking oral alendronate (6).

Lenz et al. presented four cases on ONJ in cancer patients. Three were receiving bisphosphonate therapy in conjunction with their cancer chemotherapy, while a fourth developed ONJ without ever having received an osteoclast-inhibiting agent (9). These authors characterize their findings in terms of ONJ being a more generalized side-effect seen in patients undergoing treatment for malignancy, rather than the effect of the bisphosphonate (9). Small sample size erodes the veracity of this conclusion, however, the development of ONJ in the absence of bisphosphonate therapy serves to illustrate that where bisphosphonates are used as adjunctive therapy in patients with malignancy, the pathogenesis remains incompletely defined.

Carter et al. managed five patients with ON of the maxilla and mandible, all of whom were taking the nitrogen-containing bisphosphonates for either Paget's disease or multiple myeloma (38). These same authors reported a further 10 cases where it was noted that this sample contained generally older, medically compromised individuals, that developed disease of the jaw that failed to be eradicated (7). Recurrence was related to the inability to remove necrotic bone, and management centred on control of recurrences with the intermittent use of antibiotics (penicillin and second-generation cephalosporins). Three subjects demonstrated complete resolution within 12 months, all of whom were taking the oral preparation alendronate (7).

Marx et al. reported 119 total cases of bisphosphonate-related bone exposure (2). Sixty-two (52.1%) were treated for multiple myeloma, 50 (42%) for metastatic breast cancer, four (3.4%) for metastatic prostate cancer and three (2.5%) for osteoporosis (2). In this series the presenting findings in addition to exposed bone were 31.1% asymptomatic, 68.9% with pain, 23.5% mobile teeth and 17.6% with non-healing fistulas. Eighty-one bone exposures occurred in the mandible alone, 33 in the maxilla and five occurred in both jaws. The precipitating event that produced the bone exposures were spontaneous (25.2%), tooth removals (37.8%), advanced periodontitis (28.6%), periodontal surgery (11.2%), dental implants (3.4%) and root canal surgery (0.8%) (2).

Bagan et al. reported 10 chemotherapy patients with ON, of which seven had dental extractions preceding painful bone exposure (4). All patients were treated for

malignancy with bisphosphonates, and all had histopathology indicative of chronic osteomyelitis without evidence of malignancy of the jaws. Apart from their presentation with ON, the only commonality was the use of bisphosphonate as part of their treatment for malignant bone disease (4).

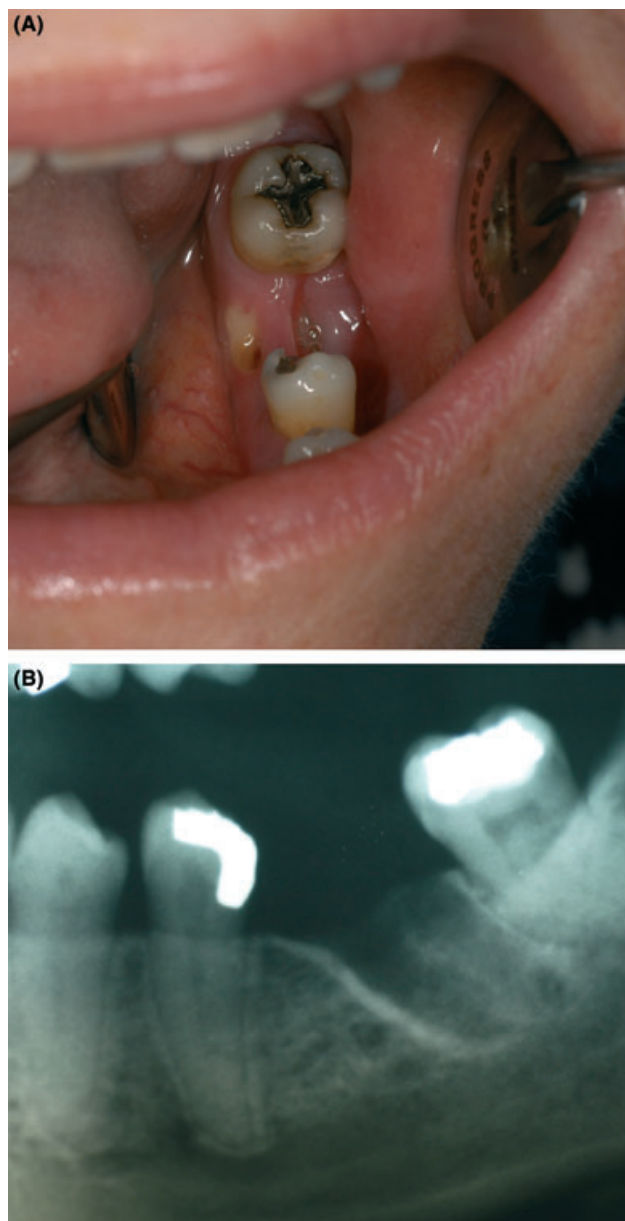
Bisphosphonate-related ON of the jaws can appear spontaneously, although more commonly it is associated with dental extraction, ill-fitting prostheses or overt local trauma (37). Nine of the 12 cases reported by Pires et al. were preceded by dental manipulation (periodontal surgery or dental extraction) and two as having periapical radiolucency or severe periodontal disease prior to the development of ONJ (32). Of the 17 patients presented by Bamias et al., only two did not have a history of dental procedures or prostheses (1). The exposure of the jaw to the oral flora following extraction, coupled with its inability to heal, ultimately leads to infection of the bone producing pain and making it very difficult to treat (4).

Badros et al. recently presented 22 patients with multiple myeloma who developed BRONJ, 12 of whom received dental extractions (39). Interestingly four patients also suffered from avascular necrosis of the hip, but these patients were also concurrently taking corticosteroids. The variables predictive of developing BRONJ in that study were dental extraction, treatment with pamidronate/zoledronate, longer follow-up time and older age at diagnosis of multiple myeloma. These authors concluded that BRONJ appeared to be time-dependent with higher risk after long-term use of bisphosphonates in older multiple myeloma patients often after dental extractions (39).

Other cases of BRONJ have been reported where dental extractions, non-surgical and surgical root canal treatment were precipitating factors (40–47). Furthermore, it has recently been suggested that bisphosphonate therapy is a contraindication to dental endosseous implant placement (48).

### Presentation of BRONJ

Bisphosphonate-related ON of the jaws pathology presents with a clinical and radiographic appearance similar to that of radiation necrosis (Fig. 1; 3, 16). One study reported an increase in referral of patients exhibiting refractory osteomyelitis, typically associated with a non-healing extraction socket (3). The lack of radiation exposure in these patients, who either shared a history of malignancy or osteoporosis, was initially puzzling until it became clear that all patients with malignancies were receiving an intravenous form of bisphosphonate (3). The pathogenicity was consistent with localized vascular insufficiency, and the lesions' clinical similarity to ORN was striking. However, Hellstein and Marek in their interesting article on 'phossy jaws' compare the similarity of this 19th century condition with the current 'bisphossy jaws' (BRONJ; 24). The earlier condition was initially compared with ORN, in much the same fashion as is now occurring with bisphosphonate-associated ON. Suppuration was



**Figure 1** Clinical (a) and radiographic (b) presentation of non-healing extraction site in patient taking bisphosphonates for multiple myeloma.

uncommon in ORN, whereas phossy jaw was inevitably complicated by bacterial infection. It could be argued that bacterial infection acts as a significant co-factor in both phossy and bisphossy jaws (24).

The suspicion of bisphosphonate involvement in the development of 20 cases of osteomyelitis in those treated for breast or prostate cancer or multiple myeloma, also demonstrated bacterial colonization of non-vital bone fragments (24). In the 14 cases of ONJ reported by Bamias et al. all had necrotic bone with surrounding bacteria, but with no evidence of invasion when examined histopathologically (1).

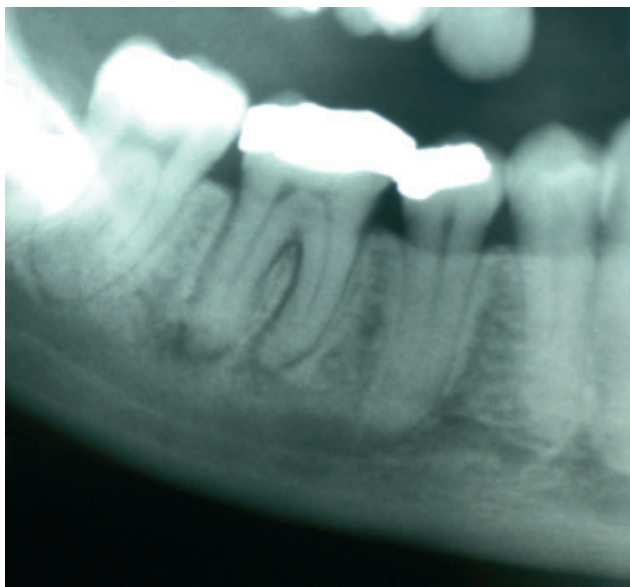
In a recent study by Hansen et al. the similarities between BRONJ and infected osteoradionecrosis (IORN) were described (45). Multicentric and bilateral

involvement was common in the bisphosphonate group. Histologically, the bone revealed diffuse and patchy areas of necrosis in the bisphosphonate group, while in IORN ON was larger and not diffusely distributed. In all cases, they found *Actinomyces* attached to the necrotic bone tissue. In five of eight bisphosphonate cases, and in six of 10 IORN cases, numerous osteoclasts could be detected close to vital bone exhibiting signs of bone resorption. They concluded that *Actinomyces* was involved in the chronic, non-healing inflammatory processes as a characteristic feature of both diseases. Together with the associated presence of increased osteoclast numbers, they suggest that both factors may be involved in osteolytic mechanisms (45).

Radiographic changes associated with BRONJ are generally only evident once there is significant bone involvement. Early on, the condition may not be radiographically detectable or may appear as subtle periodontal ligament widening equal to the findings in periodontal disease (Fig. 2). Advanced cases show a moth-eaten, poorly defined radiolucency, with or without radio-opaque sequestra.

### Duration of bisphosphonate therapy prior to BRONJ

Currently, there is no way to predict which individuals taking bisphosphonates are at greatest risk of developing ONJ, nor is there evidence of prognostic indicators that are predictive of outcomes. Some lesions remain stable, while others will progress (25). Patients reported by Zarychanski et al. were on a monthly dose of 90 mg of the intravenous bisphosphonate from 12 to 77 months prior to presentation (37). Eleven of the 12 were receiving or had received corticosteroids at the time of onset of ONJ. Occurrence appeared directly related to the duration of either pamidronate or zoledronate (37).



**Figure 2** Panoramic radiograph showing widening of the periodontal ligament space on the contralateral side in the same patient illustrated in Fig. 1.

Those receiving bisphosphonates without developing ONJ received a median of 15 infusions over 19 months. In comparison, those 6.7% who did develop ONJ, the median number of cycles and months of exposure were 35 and 39, respectively (1). Notably, the incidence of ONJ rose with the time of exposure, from 1.5% treated for 4–12 months, to 7.7% when treatment time reached between 37 and 48 months (1). The newer generation zoledronate demonstrated a significantly higher cumulative risk compared with pamidronate alone or with sequential treatment of pamidronate and zoledronate (1). Patients who received fewer than 12 cycles of bisphosphonate did not develop ONJ. However, the median exposure to the drugs for those who developed ONJ was twice that of those who did not, suggesting that the incidence of risk increases continuously even after 5 years of exposure (1). The median time of treatment for patients receiving bisphosphonate therapy for multiple myeloma or metastatic breast cancer before developing ONJ is 18 months after commencement of zoledronate and 72 months after initiating pamidronate (25).

### Treatment modalities and treatment response for BRONJ

Presentations of ONJ universally require tissue analysis to exclude the presence of metastatic foci before embarking on treatment, especially those involving invasive procedures (32). Zarychanski et al. reported worsening in symptoms by surgical debridement and attempts at wound closure in all cases (37). On the basis of such results, surgical debridement has been actively discouraged by some (37, 38). Surgical intervention is fraught with difficulty since finding viable bone margins is impossible given the global effect bisphosphonates have on the skeleton. Where aggressive osseous surgery has been performed, the development of an enlarged necrotic area has occurred (49). Equally ineffective is the use of tissue flaps to cover painful exposed bone. In these situations fistulae tend to develop around the flap edges, with complete dehiscence a secondary complication (38).

Significant symptomatic relief may be obtained with the use of antibiotic therapy regardless of culture results; however, this effect is infrequently sustained (37). Pires et al. instituted conservative management with antibiotic therapy, improved local oral hygiene measures, 0.12% chlorhexidine mouthrinses and 2% potassium iodine solution (32). Persistent bone exposure was treated with surgical debridement. Fifty percent reported resolution of pain following treatment and only 21% demonstrated complete resolution of bone exposure. Of note, of the 14 reported cases by Pires et al., two were not receiving bisphosphonate adjunctive treatment, and the only individual who demonstrated complete response to treatment was included in the pair not taking an osteoclast-inhibiting drug (32). In the cases of refractory painful bone exposure such as seen in these patients, surgical debridement becomes the treatment of choice for the management of ONJ.

All patients reported by Zarychanski et al. had their bisphosphonate treatment terminated on presentation

with ONJ; however, improvement in the condition with withdrawal of bisphosphonates has not been a universal finding (37). Most reports of ON associated with bisphosphonate treatment have involved the intravenous nitrogen-containing drugs. The mechanism of these drugs and their protracted release systemically appear to indicate that cessation of bisphosphonates in the event of ON of the jaws affords little clinical benefit. All bisphosphonates accumulate in the mineralized bone matrix and are released over protracted time periods – months to years. The total doses and the duration of bisphosphonate treatment directly influence the degree to which incorporation into, and release from, the adult skeleton occurs (9). In the event of ON, the cessation of bisphosphonate therapy appears unwarranted given the systemic incorporation and long-term bioavailability (12).

Patients presenting with BRONJ reported by Bamias et al. also had their bisphosphonate treatment ceased (1). As with the above cases, treatment included local debridement and the institution of both antibiotics and topical antimicrobials (chlorhexidine), with the additional measure of reducing denture contact. Antibiotics only reached a sustained effect in one of the 17 cases, the rest producing recurrences characterized by a purulent discharge and ongoing pain. The lack of both systemic and radiographic improvement at the 24-month follow up is indicative of the permanency in these bone defects (1).

At this stage it is unclear whether bacteria play a primary role in the pathogenesis of BRONJ or whether the presence of bacterial colonies represents secondary infections (24). The predilection of BRONJ for the mandible and maxilla may be explained by the unique environment the oral cavity presents (7). Other bones within the skeleton are encased in soft tissue. Bone in the mouth, when exposed as a result of dental extraction, is immediately bathed in bacteria. The reduced healing capacity afforded by bisphosphonate preparations, leaves the bone vulnerable to bacterial invasion and colonization, infection and progression to osteomyelitis, and finally necrosis (7). Documented response to topical chlorhexidine may at least help control the surface bacteria to the extent that the body can re-epithelialize the areas of denuded bone (24).

Immediate withdrawal of bisphosphonate therapy upon diagnosis of ONJ is not recommended. This would seem rational given the direct correlation between the total dose and treatment duration, and the systemic incorporation and protracted release of bisphosphonates (9). Little would be gained by cessation of therapy in terms of treatment outcomes for ONJ, and potentially there is much to lose in terms of the pathology for which the drug was originally prescribed. In spite of this, some have cited immediate cessation of bisphosphonate therapy upon presentation with ONJ and have initiated antibiotic treatment to prevent secondary osteomyelitis (37). As yet there is no consensus on the pathogenesis of BRONJ or even if such a diagnosis is warranted, thus not unexpectedly, there is yet to be a universal management protocol for the treatment of ONJ in those taking bisphosphonates.

Recently, however, Ruggiero et al. have recommended a clinical staging system for BRONJ to help with diagnosis and management of this phenomenon (50). Although they acknowledge that the extent of signs and symptoms of clinical disease associated with BRONJ can vary despite similar disease processes, dosage regimens and treatment duration, their system offers a useful guide to clinicians that encounter this problem. Stage I patients who exhibit exposed, necrotic bone that is asymptomatic are advised to use a daily oral antimicrobial rinse or irrigation (0.12% chlorhexidine) with regular clinical follow up as disease activity dictates. Stage II patients who exhibit exposed, necrotic bone associated with pain and infection are advised to undertake antimicrobial therapies based on culture and sensitivity data, in conjunction with analgesia and daily oral rinse or irrigation with 0.12% chlorhexidine. Exposed, necrotic bone in patients with pain, infection and pathological fracture, extraoral fistula, or osteolysis extending to the inferior border are designated as Stage III patients. The treatment regimen for these patients includes surgical debridement of necrotic bone, antimicrobial therapy (either oral or intravenous), analgesia and daily rinses with 0.12% chlorhexidine (50).

### Preventative strategies

Given the many unknowns associated with BRONJ, it would seem prudent to develop a coordinated pre-treatment and intra-treatment protocol aimed at prevention. Prior to commencing bisphosphonate treatment, patients should be versed on the potential adverse effects associated with the therapy (37). Such patient education should aim to reinforce the message of prevention, early detection and non-surgical management of oral conditions as the key to circumventing the development of this debilitating pathology. Preventative strategies such as establishment of meticulous oral hygiene regimes in conjunction with timely surgical procedures should be undertaken prior to commencing therapy (38). During therapy, strict review and maintenance of oral hygiene programmes are essential in order to prevent the development of pathology necessitating surgical management (1, 7, 32, 38). When surgical treatment becomes unavoidable, referral to a specialist oral and maxillofacial surgeon is recommended.

Extractions and all types of surgery to the jaws should be avoided. For those requiring dental extraction, Cheng et al. have used the novel approach of slow extraction using orthodontic bands (7). This essentially allows extrusion and ultimately exfoliation of the tooth to occur over a period of weeks. The oral mucosa migrates apically throughout the extrusion process such that there is no open wound following complete exfoliation of the tooth (7).

### Conclusions

Oral bisphosphonates are used widely in the treatment of osteoporosis, whereas intravenous regimes are designed to treat complications of metastatic disease



and primary osteolytic pathology of the bone, and have been integral in moderating the effects of hypercalcaemia of malignancy and pain associated with bony pathology. Presentation of BRONJ is currently more commonly seen in patients taking the intravenous forms of the drug; however, prescriptions for oral bisphosphonates continue to rise, and there is fear that the long-term cumulative effects of these drugs may see BRONJ occurring in this patient group at a rate equal to that seen in patients undertaking intravenous therapy.

Opinion on both aetiology and management of BRONJ is divided. As yet there is no clinical evidence to support cessation of bisphosphonate therapy once a diagnosis of BRONJ is made. Our present knowledge regarding the activity of these drugs suggests that little benefit would be gained by disrupting the treatment of significant systemic disease states for which the medication is used. This is particularly true given the avidity in which these drugs are incorporated into the skeleton and the limited circumstances in which these compounds are liberated.

Bisphosphonate-related ON of the jaws can appear spontaneously, but more commonly it is associated with local trauma, predominantly dental extraction. Currently, there is no way of predicting which individuals taking bisphosphonates are at greatest risk of developing BRONJ. Equally, there are no prognostic indicators predictive of outcomes. The only persistent finding is a correlation between duration of therapy and occurrence of BRONJ.

Antibiotics have been used in the treatment of BRONJ, but with little sustained effect. Surgical debridement and wound closure worsens symptoms, and excessive osseous surgery has resulted in enlargement of areas of necrotic bone. Simple measures such as the use of topical antimicrobials like 0.12% chlorhexidine may protect denuded areas from surface bacteria. Unfortunately, the symptomatic and radiographic improvement is often not forthcoming, and intermittent, conservative debridement is required.

Prevention is superior to treatment, and as such the establishment of meticulous oral hygiene and pre-emptive surgical treatment prior to commencement of bisphosphonate therapy is recommended. During therapy, strict review and maintenance of oral hygiene practices should occur in order to prevent pathology necessitating surgical management. Patients treated with these drugs need to be aware of complications that can arise in the jaws, especially related to trauma. It should be stressed upon those taking bisphosphonates, especially the intravenous forms, the need to avoid invasive dental management.

## References

1. Bamias A, Kastritis E, Bamia C, et al. Osteonecrosis of the jaw in cancer after treatment with bisphosphonates: incidence and risk factors. *J Clin Oncol* 2005; **23**: 8580–7.
2. Marx RE, Sawatari Y, Fortin M, Broumand V. Bisphosphonate-induced exposed bone (osteonecrosis/osteopetrosis) of the jaws: risk factors, recognition, prevention, and treatment. *J Oral Maxillofac Surg* 2005; **63**: 1567–75.
3. Ruggiero SL, Mehrotra B, Rosenberg TJ, Engroff SL. Osteonecrosis of the jaws associated with the use of bisphosphonates: a review of 63 cases. *J Oral Maxillofac Surg* 2004; **62**: 527–34.
4. Bagan JV, Murillo J, Jimenez Y, et al. Avascular jaw osteonecrosis in association with cancer chemotherapy: series of 10 cases. *J Oral Pathol Med* 2005; **34**: 120–3.
5. Marx RE. Pamidronate (Aredia) and zoledronate (Zometa) induced avascular necrosis of the jaws: a growing epidemic. *J Oral Maxillofac Surg* 2003; **61**: 1115–7.
6. Farrugia MC, Summerlin DJ, Krowiak E, et al. Osteonecrosis of the mandible or maxilla associated with the use of new generation bisphosphonates. *Laryngoscope* 2006; **116**: 115–20.
7. Cheng A, Mavrokokki A, Carter G, et al. The dental implications of bisphosphonates and bone disease. *Aust Dent J* 2005; **50**: S4–13.
8. Fleisch H. Development of bisphosphonates. *Breast Cancer Res* 2002; **4**: 30–4.
9. Lenz J-H, Steiner-Krammer B, Schmidt W, Fietkau R, Mueller PC, Gundlach KKH. Does avascular necrosis of the jaws in cancer patients only occur following treatment with bisphosphonates? *J Craniomaxillofac Surg* 2005; **33**: 395–403.
10. Boivin GY, Chavassieux PM, Santora AC, Yates J, Meunier PJ. Alendronate increases bone strength by increasing the mean degree of mineralization of bone tissue in osteoporotic women. *Bone* 2000; **27**: 687–94.
11. Raisz LG, Rodan GA. Pathogenesis of osteoporosis. *Endocrinol Metab Clin North Am* 2003; **32**: 15–24.
12. Bagger YZ, Tanko LB, Alexandersen P, Ravn P, Christiansen C. Alendronate has a residual effect on bone mass in postmenopausal Danish women up to 7 years after treatment withdrawal. *Bone* 2003; **33**: 301–7.
13. Odvina CV, Zerwekh JE, Rao DS, Maalouf N, Gottschalk FA, Pak CYC. Severely suppressed bone turnover: a potential complication of alendronate therapy. *J Clin Endocrinol Metab* 2005; **90**: 1294–301.
14. Lugassy G, Shaham R, Nemets A, Ben-Dor D, Nahlieli O. Severe osteomyelitis of the jaw in long-term survivors of multiple myeloma: a new clinical entity. *Am J Med* 2004; **117**: 440–1.
15. Olson KB, Hellie CM, Pienta KJ. Osteonecrosis of jaw in patient with hormone-refractory prostate cancer treated with zoledronic acid. *Urology* 2005; **66**: 658.
16. Ficarra G, Beninati F, Rubino I, et al. Osteonecrosis of the jaws in periodontal patients with a history of bisphosphonates treatment. *J Clin Periodontol* 2005; **32**: 1123–8.
17. Migliorati CA. Bisphosphonates and oral cavity avascular bone necrosis. *J Clin Oncol* 2003; **21**: 4253–4.
18. Merigo E, Manfredi M, Meleti M, Corradi D, Vescovi P. Jaw bone necrosis without previous dental extractions associated with the use of bisphosphonates (pamidronate and zoledronate): a four-case report. *J Oral Pathol Med* 2005; **34**: 613–7.
19. Benford HL, Frith JC, Auriola S, Monkkinen J, Rogers MJ. Farnesol and geranylgeraniol prevent activation of caspases by aminobisphosphonates: biochemical evidence for two distinct pharmacological classes of bisphosphonate drugs. *Mol Pharmacol* 1999; **56**: 131–40.
20. Fleisch H. Bisphosphonates: mechanisms of action. *Endocr Rev* 1998; **19**: 80–100.
21. Rogers MJ. From molds and macrophages to mevalonate: a decade of progress in understanding the molecular mode of action of bisphosphonates. *Calcif Tissue Int* 2004; **75**: 451–61.

22. Halasy-Nagy JM, Rodan GA, Reszka AA. Inhibition of bone resorption by alendronate and risedronate does not require osteoclast apoptosis. *Bone* 2001; **29**: 553–9.
23. Reinholz GG, Getz B, Pederson L, et al. Bisphosphonates directly regulate cell proliferation, differentiation, and gene expression in human osteoblasts. *Cancer Res* 2000; **60**: 6001–7.
24. Hellstein JW, Marek CL. Bisphosphonate osteochemonecrosis (Bis-Phossy Jaw): is this phossy jaw of the 21st century? *J Oral Maxillofac Surg* 2005; **63**: 682–9.
25. Van Poznak C. The phenomenon of osteonecrosis of the jaw in patients with metastatic breast cancer. *Cancer Invest* 2006; **24**: 110–2.
26. Woo SB, Hellstein JW, Kalmar JR. Systematic review: bisphosphonates and osteonecrosis of the jaws. *Ann Intern Med* 2006; **144**: 753–61.
27. Farah CS, Savage NW. Oral ulceration with bone sequestration. *Aust Dent J* 2003; **48**: 61–4.
28. Peters E, Lovas GL, Wysocki GP. Lingual mandibular sequestration and ulceration. *Oral Surg Oral Med Oral Pathol* 1993; **75**: 739–43.
29. Wood J, Bonjean K, Ruetz S, et al. Novel antiangiogenic effects of the bisphosphonate compound zoledronic acid. *J Pharmacol Exp Ther* 2002; **302**: 1055–61.
30. Polizzotto MN, Cousins V, Schwarer AP. Bisphosphonate-associated osteonecrosis of the auditory canal. *Br J Haematol* 2006; **132**: 114.
31. McMahon RE, Bouquot JE, Glueck CJ, Spolnik KJ, Adams WR. Osteonecrosis: a multifactorial etiology. *J Oral Maxillofac Surg* 2004; **62**: 904–5.
32. Pires FR, Miranda A, Cardoso ES, et al. Oral avascular bone necrosis associated with chemotherapy and bisphosphonate therapy. *Oral Dis* 2005; **11**: 365–9.
33. Sung EC, Chan SM, Sakurai K, Chung E. Osteonecrosis of the maxilla as a complication to chemotherapy: a case report. *Spec Care Dentist* 2002; **22**: 142–6.
34. Melo M, Qiu F, Sykora K, Juurlink D, Laupacis A, Mamdani M. Persistence with bisphosphonate therapy in older people. *J Am Geriatr Soc* 2006; **54**: 1015–6.
35. Balducci L. Anemia, cancer, and aging. *Cancer Control* 2003; **10**: 478–86.
36. Wang J, Goodger NM, Pogrel MA. Osteonecrosis of the jaws associated with cancer chemotherapy. *J Oral Maxillofac Surg* 2003; **61**: 1104–7.
37. Zarychanski R, Elphee E, Walton P, Johnston J. Osteonecrosis of the jaw associated with pamidronate therapy. *Am J Hematol* 2006; **81**: 73–5.
38. Carter G, Goss AN, Doecke C. Bisphosphonates and avascular necrosis of the jaw: a possible association. *Med J Aust* 2005; **182**: 413–5.
39. Badros A, Weikel D, Salama A, et al. Osteonecrosis of the jaw in multiple myeloma patients: clinical features and risk factors. *J Clin Oncol* 2006; **24**: 945–52.
40. Katz H. Endodontic implications of bisphosphonate-associated osteonecrosis of the jaws: a report of three cases. *J Endod* 2005; **31**: 831–4.
41. Tsai WS, Haghighi K, Placa SJ. Bisphosphonate-induced osteonecrosis of the jaws: a case report and literature review. *Gen Dent* 2006; **54**: 215–9; quiz 20–2.
42. Thakkar SG, Isada C, Smith J, et al. Jaw complications associated with bisphosphonate use in patients with plasma cell dyscrasias. *Med Oncol* 2006; **23**: 51–6.
43. Pastor-Zuazaga D, Garatea-Creglo J, Martino-Gorbea R, Etayo-Perez A, Sebastian-Lopez C. Osteonecrosis of the jaws and bisphosphonates. Report of three cases. *Med Oral Patol Oral Cir Bucal* 2006; **11**: E76–9.
44. Leite AF, Figueiredo PT, Melo NS, et al. Bisphosphonate-associated osteonecrosis of the jaws. Report of a case and literature review. *Oral Surg Oral Med Oral Pathol Oral Radiol Endod* 2006; **102**: 14–21.
45. Hansen T, Kunkel M, Weber A, James Kirkpatrick C. Osteonecrosis of the jaws in patients treated with bisphosphonates – histomorphologic analysis in comparison with infected osteoradionecrosis. *J Oral Pathol Med* 2006; **35**: 155–60.
46. Goodell G. Bisphosphonate-associated osteonecrosis of the jaws and endodontic treatment: two case reports. *J Mass Dent Soc* 2006; **55**: 44–8.
47. Dimitrakopoulos I, Magopoulos C, Karakasis D. Bisphosphonate-induced avascular osteonecrosis of the jaws: a clinical report of 11 cases. *Int J Oral Maxillofac Surg* 2006; **35**: 588–93.
48. Scully C, Madrid C, Bagan J. Dental endosseous implants in patients on bisphosphonate therapy. *Implant Dent* 2006; **15**: 212–8.
49. Migliorati CA, Casiglia J, Epstein J, Jacobsen PL, Siegel MA, Woo S-B. Managing the care of patients with bisphosphonate-associated osteonecrosis: an American Academy of Oral Medicine position paper. *J Am Dent Assoc* 2005; **136**: 1658–68.
50. Ruggiero SL, Fantasia J, Carlson E. Bisphosphonate-related osteonecrosis of the jaw: background and guidelines for diagnosis, staging and management. *Oral Surg Oral Med Oral Pathol Oral Radiol Endod* 2006; **102**: 433–41.