

Botulinum Toxin for Masseter Reduction in Asian Patients

Jeffrey Ahn, MD; Corinne Horn, MD, MS; Andrew Blitzer, MD, DDS

Asian patients frequently seek aesthetic alteration of hypertrophic masseter muscles to reduce a prominent mandibular angle. Surgical reduction is common in Asia, but botulinum toxin offers a less invasive approach. This pilot study evaluated results of aesthetic lower face narrowing in 20 Asian patients. Initially, 25 U of botulinum toxin (5 U/0.1 mL) was injected at each inferior masseter border; an additional 25 U was injected per side as needed at 1-week intervals. Seven patients (35%) required only 1 injection; 10 (50%) required 2; and 3 (15%) required 3 injections. Maximum reduction was seen at 1 to 2 months; more prominent hypertrophy yielded the most impressive results. Maintenance reinjection took place at 6 to 8 months. Up to 12 months of follow-up is reviewed herein. Two patients (10%) complained of mild fatigue after vigorous chewing and 1 developed mild transient buccal weakness. Nineteen of 20 patients were satisfied.

Arch Facial Plast Surg. 2004;6:188-191

Oriental aesthetics favor a delicate ovoid facial shape. Thus, Asian patients frequently seek aesthetic alteration of a hypertrophic masseter muscle and prominent mandibular angle. Although reduction surgery has achieved much success in Asia, many patients desire a less invasive approach. For patients with muscular hypertrophy rather than mandibular bony prominence as the source of lower face widening, botulinum toxin type A (hereinafter "Botox"; Allergan, Irvine, Calif) is a viable alternative. Botox has been used safely and effectively in wide variety of aesthetic procedures and to treat neuromuscular disorders (eg, strabismus, blepharospasm, hemifacial spasm, torticollis, and spasmodic dysphonia); it is also proving to be a new effective method of masseter reduction. The goal of this pilot study was to determine the safety and efficacy of masseter Botox injection for aesthetic lower face narrowing in Asian patients, to refine the dosing and optimal treatment intervals, and to better characterize the ideal candidate.

METHODS

Asian patients presenting with a wide lower face were evaluated in the office of the senior author (J.A.). Patients were asked to clench their

jaws to define areas of masseteric prominence; patients with only bony mandibular prominence were not candidates for Botox reduction. Twenty patients with muscular hypertrophy were identified. Areas of masseteric prominence on clenching were marked, and a 30-gauge needle was used to inject along the inferior border of the masseter. The needle tip was used to palpate the mandible and then retracted 1 to 2 mm prior to injection, thus avoiding the superficial facial musculature. Twenty-five units of Botox (5 U/0.1 mL) was injected per side at previously marked sites (**Figure 1**).

One week after initial injection, patients were reexamined and asked to clench their jaws again. Symptoms of masseter paralysis were evaluated. If no difficulties chewing resulted, but persistent masseteric prominence was present on clenching, then an additional 25 U of Botox was injected per side. Patients were injected up to 3 times at 1-week intervals. Often injection was requested superiorly, toward the zygomatic arch, for further narrowing.

RESULTS

Nineteen patients were women and 1 was a man. Ages ranged from 18 to 35 years (mean age, 27 years). Seven patients (35%) required only 1 injection (25 U of Botox per side); 10 (50%) required 2 (a total of 50 U per side); and 3 (15%) required 3 injections (a total of 75 U per side) at initial therapy. Up to 12 months of follow-up is reviewed herein. Patients with more

From the Departments of Otolaryngology-Head and Neck Surgery of New York Presbyterian Hospital (Drs Ahn and Horn) and St Luke's-Roosevelt Medical Center (Dr Blitzer), New York, NY.

prominent hypertrophy had more dramatic results. Maximum reduction on the lower face width was seen at 1 to 2 months after injection (**Figure 2** and **Figure 3**). Patients presented at 6 to 8 months for maintenance reinjection. Nineteen of the 20 patients were satisfied with their results.

Complications included 1 case of transient buccal weakness after a third injection superiorly toward the zygomatic arch, which resolved 3 weeks later. This was the patient who was dissatisfied and thought the masseter was not satisfactorily reduced. Two patients (10%) complained of mild transient masseter fatigue after vigorous

chewing. Otherwise, no dysphagia, dysarthria, infection, or painful mastication was observed in this series.

COMMENT

The cause of masseteric muscle hypertrophy is unknown. Painless enlargement of the angle of the jaw is the most common presentation, but the literature also describes some patients with localized pain and trismus.¹ Patients are generally in their 20s to 40s, and there is no gender predilection. Unilateral or bilateral enlargement may occur. Muscular hypertrophy is thought to cause secondary bony enlargement of the mandibular angle from functional remodeling where the muscle inserts on bone.^{1,2} Thus, the natural history of this condition suggests that patients with muscular hypertrophy alone may eventually progress to bony prominence.

Since the 1880s, medical options such as sedatives, muscle relaxants, and occlusal splints have been used to treat benign masseteric hypertrophy.³ Surgical masseter reduction via external angle approach was first described in 1947.⁴ Owing to concern over cosmesis and protection of the marginal branch of the facial nerve, an intraoral approach evolved to excise the internal layer of the masseter and thicken bone at the angle.⁵ Subsequent refinements have ranged from localized excisions of the hypertrophic masseter to resection of the lowest insertions followed by leveling of the remaining muscle to avoid a bulge of remaining contractile muscle.⁶

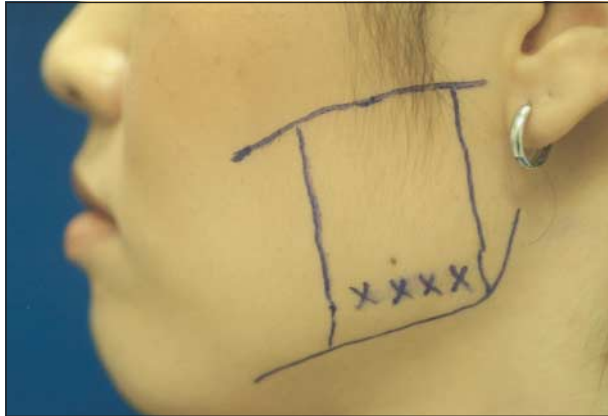


Figure 1. A patient marked for injection at areas of masseteric prominence.

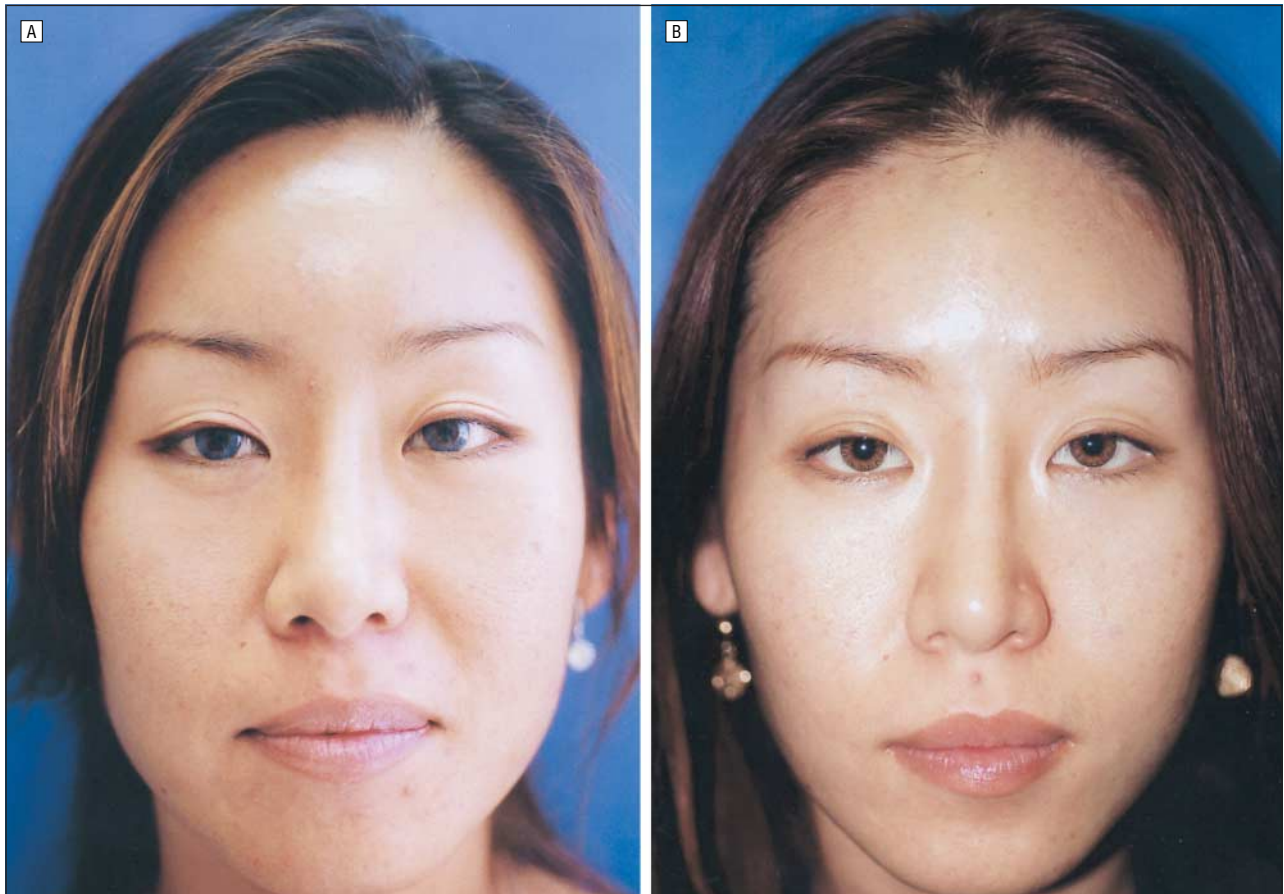

Figure 2. A, Preinjection frontal view of a patient with masseteric prominence. B, Postinjection frontal view after lower face reduction.

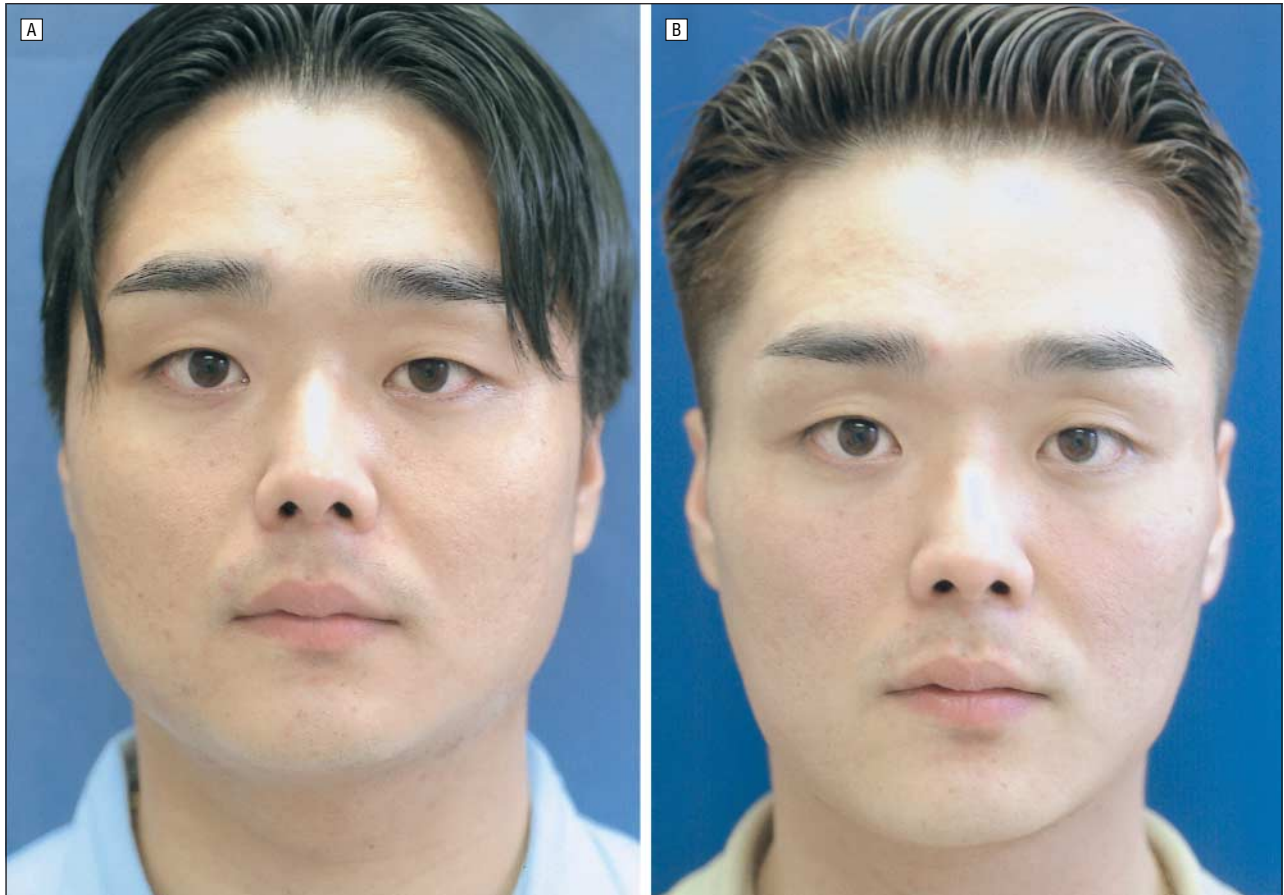


Figure 3. A, Preinjection frontal view of a patient with masseteric prominence. B, Postinjection frontal view after lower face reduction.

Not all patients desire surgery. Inherent risks described in the literature include asymmetry, condylar fracture, inferior alveolar nerve injury, hematoma, facial nerve injury, postoperative trismus, and infection. Patients require a 2- to 3-week recovery period, and contour change may not be evident for 3 to 6 months after surgery (but are permanent).

The primary effects of Botox are well studied: the toxin is taken up by motor neurons and prevents release of vesicle-bound acetylcholine into the neuromuscular junction. Muscles are thus functionally denervated via presynaptic blockade resulting in atrophy and decreased bulk. Function is regained when new axon terminals sprout to form new presynaptic contacts with neighboring muscle fibers. This is considered a limitation of Botox therapy compared with permanent surgical reduction.

Although the patients in the present series were treated for purely aesthetic reasons, there are reports of masseteric hypertrophy leading to functional impairments (ie, trismus, localized painful masseter, and temporomandibular joint pain). Some reports link masseteric hypertrophy to bruxism in about 40% of patients and trauma in about 30%.⁶ Botox has been reported successful in functional treatment of bruxism^{7,8} and has also been used experimentally in the neighboring parotid gland for treatment of chronic sialectasis by inhibiting parasympathetic secretomotor fibers.⁹

Two authors have reported preliminary subjective assessments of Botox in aesthetic masseter reduction in

small numbers of patients with 6-month follow-up.^{10,11} A third study of 5 Asian patients treated with ultrasound-guided percutaneous Botox injection has recently been reported.² Patients had initial ultrasound measurement of masseter thickness and were injected with 100 to 300 U of another preparation of botulinum toxin type A (Dysport; Speywood Pharmaceuticals Ltd, Maidenhead, England), depending on thickness. Maximum reduction in masseter thickness was 30.9% at 3 months, and 3 patients (60%) required reinjection at 1 year to maintain atrophy. Electromyographic results showed no differences between pretreatment and posttreatment patients. This is of interest because in cosmetic conditions and in our study, most patients require reinjection every 6 to 8 months to maintain results.

However, To et al² found that masseteric hypertrophy seemed to be reversible with single-dose therapy. While these findings have been supported by other studies, it not entirely clear why masseteric injection of Botox offers greater longevity than injection elsewhere in the facial musculature.¹² We hypothesize that these patients have habitual chewing or bruxism behaviors and fatigue easily when partially paralyzed. Thus, decreased habitual chewing and masseter use after Botox injection may not immediately rehypertrophy after paralysis resolves. In contrast, patients with oromandibular dystonias due to neurologic lesions need consistent Botox injections every 4 months because their behavior is not voluntary (unpublished data, October 10, 2003).

The reinjection protocol described in the present study at 1 to 2 weeks is not standardized and has not been described elsewhere in the literature. Some authors have reported excellent masseteric reduction without additional Botox injections.¹² However, we believe that a standard dose of 25 U of Botox per side may not be sufficient for every patient. The goal is not complete paralysis of the masseter but rather sufficient paralysis to debulk the lower face. In general, we have noted that greater paralysis leads to greater patient satisfaction. Tailoring the dose over 1 to 2 weeks and only reinjecting patients who have residual masseteric motion and prominence maximizes cosmetic reduction and minimizes complications like neuropraxia and masticatory difficulty.

Although many of the patients described in the literature have predominantly bony changes that require osteotomies, our patient population had excellent aesthetic outcomes with only masseter denervation, which resulted in soft tissue alteration. Given that 1 patient developed mild transient buccal weakness after a third initial treatment injection, we recommend a maximum of 2 injections (a total of 50 U per side). We also recommend avoiding injection in the upper portion of the masseter near the zygomatic arch. The technique presented here allows therapy to be tailored for unilaterally prominent hypertrophy and yields a symmetric result. Furthermore, the advantage to assessing patients weekly at initial injection is that muscular weakness and atrophy can be serially assessed prior to reinjection.

In conclusion, this pilot study revealed that Botox injection in patients with masseter hypertrophy offers a safe and effective medical alternative for masseter reduction surgery. The satisfaction rate with aesthetic results was very high: most patients saw maximum results at 1 to 2 months, and most patients returned at 6 to 8 months for reinjection. The ideal candidate has soft tissue fullness, and men and women of diverse ages can be treated successfully. Although this series is larger than others re-

ported in the literature, limitations of this study include the small number of patients and the short-term follow-up. Future study of this technique with more patients and longer follow-up is under way.

Accepted for publication October 22, 2003.

Corresponding author and reprints: Jeffrey Ahn, MD, Department of Otolaryngology–Head and Neck Surgery, College of Physicians and Surgeons, Columbia University, 180 Ft Washington Ave, Harkness Pavilion, Eighth Floor, New York, NY 10032 (e-mail: jma2@columbia.edu).

REFERENCES

1. von Lindern JJ, Niederhagen B, Appel T, Berge S, Reich RH. Type A botulinum toxin for the treatment of hypertrophy of the masseter and temporal muscles: an alternative treatment. *Plast Reconstr Surg*. 2001;107:327-332.
2. To WH, Ahuja AT, Ho WS, et al. A prospective study of the effect of botulinum toxin A on masseteric muscle hypertrophy with ultrasonographic and electromyographic measurement. *Br J Plast Surg*. 2001;54:197-200.
3. Legg JW. Enlargement of the temporal and masseter muscles on both sides. *Tr Pathol Soc Lond*. 1880;31:361-366.
4. Gurney CE. Chronic bilateral benign hypertrophy of the masseter muscles. *Am J Surg*. 1947;73:137-139.
5. Ginestet G, Freziers H, Merville L. La correction chirurgicale de l'hypertrophie du masseter. *Ann Chir Plast*. 1959;4:787.
6. Beckers HL. Masseteric muscle hypertrophy and its intraoral surgical correction. *J Maxillofac Surg*. 1977;5:28-35.
7. Niamtu J. Aesthetic uses of botulinum toxin A. *J Oral Maxillofac Surg*. 1999;57:1228-1233.
8. Freund B, Schwartz M, Symington JM. The use of botulinum toxin for the treatment of temporomandibular disorders: preliminary findings. *J Oral Maxillofac Surg*. 1999;57:916-920.
9. Guntinas-Lichinus O, Jungehusling M. Treatment of chronic parotid sialectasis with botulinum toxin A. *Laryngoscope*. 2002;112:586-587.
10. Moore AP, Wood GD. The medical management of masseteric hypertrophy with botulinum toxin type A. *Br J Oral Maxillofac Surg*. 1994;32:26-28.
11. Smyth AG. Botulinum toxin treatment of bilateral masseteric hypertrophy. *Br J Oral Maxillofac Surg*. 1994;32:29-33.
12. Park MY, Ahn KY, Jung DS. Botulinum toxin type A for contouring of the lower face. *Dermatol Surg*. 2003;29:477-483.